

UNIVERSITY OF CALIFORNIA
CALIFORNIA COLLEGE OF MEDICINE
LIBRARY

JUN 1 1 1971

IRVINE, CALIFORNIA 92664

B12.410
1000

Dallas B. Kittle

Sept. 22, 1925

Digitized by the Internet Archive
in 2007 with funding from
Microsoft Corporation

http://www.archive.org/details/diagnosisofnervo00purviala

THE DIAGNOSIS OF NERVOUS DISEASES

WITHDRAWN
LIBRARY
COLLEGE OF MEDICAL EVANGELISTS
LOMA LINDA, CALIFORNIA

THE DIAGNOSIS

OF

NERVOUS DISEASES

BY

SIR JAMES PURVES STEWART, K.C.M.G., C.B.

M.D. EDIN., F.R.C.P.

SENIOR PHYSICIAN TO THE WESTMINSTER HOSPITAL
PHYSICIAN TO THE ROYAL NATIONAL ORTHOPÆDIC HOSPITAL
CONSULTING PHYSICIAN TO THE WEST END HOSPITAL FOR NERVOUS DISEASES
MEMBRE CORRESPONDANT DE LA SOCIÉTÉ DE NEUROLOGIE DE PARIS
CORRESPONDING MEMBER OF THE PHILADELPHIA NEUROLOGICAL SOCIETY
COLONEL, ARMY MEDICAL SERVICE

FIFTH EDITION, REVISED AND ENLARGED

LONDON
EDWARD ARNOLD
41 & 43 MADDOX STREET, BOND STREET, W.
1920

[*All rights reserved*]

WL 141
S849d
1920.

PREFACE TO THE FIFTH EDITION

Since the fourth edition of this work was published, three years ago, the European War has happily come to an end. Medical workers, like those in other branches of science, can now again devote their energies to peaceful research, instead of repairing sick and wounded combatants, only to fit them to fling themselves afresh into the murderous arena.

But even during the recent war neurology has not ceased to advance. Numerous new and important facts have been learned with reference to war injuries and diseases, whilst fresh problems have also arisen in civilian neurology, many of them yet unsolved.

The present edition has been revised and in part rewritten. A short chapter upon war neuroses, regarded from the clinical standpoint, has been added, but without attempting to discuss the various metaphysical theories, more or less abstruse, propounded to explain them by eminent psychologists of different schools.

Contemporaneously with the publication of the present volume, a Spanish edition of the work is being published in Barcelona.

From the kindly reception accorded to former editions of this work, it is not unreasonable to infer that it has probably been found of some practical use. Nevertheless, the person who learns most from such a book is not the reader, but the writer himself.

I have to acknowledge my indebtedness to the many co-workers whose observations have been incorporated in the present edition and have helped to remedy some of its deficiencies. I have also to thank my colleague Dr. Hildred Carlill for his kind help in correcting the proof-sheets as they passed through the press.

Fig. 63, p. 135, is borrowed, by kind permission of the author, from Professor Judson Herrick's "Introduction to Neurology."

JAMES PURVES STEWART.

94, Harley Street, London, W. 1.
December, 1919.

CONTENTS

CHAPTER		PAGE
I.	Anatomy and Physiology	1
II.	Anatomy and Physiology (*continued*)	27
III.	Method of Case-Taking	46
IV.	Coma	53
V.	Fits and Other Convulsive Phenomena	65
VI.	Involuntary Movements	77
VII.	Aphasia	95
VIII.	Disorders of Articulation	107
IX.	Cranial Nerves	116
X.	Cranial Nerves (*continued*)	144
XI.	Pain and Other Abnormal Subjective Sensations	166
XII.	Abnormalities of Sensation: Hyperæsthesia, Paræsthesia, Anæsthesia	186
XIII.	Organic Motor Paralysis of Upper Neurone Type	202
XIV.	Organic Motor Paralysis of Lower Neurone Type	217
XV.	Recurrent and Transient Palsies	244
XVI.	Inco-ordination	252
XVII.	Postures and Gaits	262
XVIII.	Tropho-Neuroses	287
XIX.	Reflexes	312
XX.	Affections of the Vegetative Nervous System	334
XXI.	The Neuroses	358
XXII.	Electro-Diagnosis and Electro-Prognosis	400
XXIII.	The Cerebro-Spinal Fluid	413
XXIV.	Disorders of Sleep	433
XXV.	Intra-Cranial Tumours	443
XXVI.	Organic War-Lesions of the Nervous System	466
XXVII.	War Neuroses	536
	Index	558

PLATES

PLATE		TO FACE PAGE
I.	Coloured model, showing cutaneous root-areas	36
II.	Sub-ungual hæmorrhages of the hand	303
III.	Erythromelalgia	352

FIG.		
1.	Simple spinal reflex	2
2.	Voluntary motor act	2
3.	Scheme of cerebral localisation (outer surface)	4
4.	Scheme of cerebral localisation (mesial surface)	4
10.	Cortico-spinal and sub-cortico-spinal tracts	11
11.	The course of the various sensory paths in the spinal cord	14
12.	Chief sensory tracts in spinal cord, medulla, pons, and cerebrum	15
14.	The symptoms resulting from a left-sided hemisection of the spinal cord (Brown-Séquard syndrome)	17
15.	Vertical mesial section through cerebellum, pons and medulla	18
16.	Cerebellum: Upper surface	18
17.	Cerebellum: Posterior surface	19
18.	Cerebellum: Antero-inferior or ventral surface	19
20.	Cerebello-petal and cerebello-fugal paths	20
29.	Visual paths	38
32.	Arterial supply of cortex	42
34.	The course and distribution of the terminal arteries of the spinal cord (after Van Gehuchten)	44
70.	Trigeminal, facial, and glosso-pharyngeal nerves, showing course of taste-fibres	140
75.	Facial nerve, showing course of secretory and of taste-fibres	147
192.	The vegetative nervous system, with its autonomic and sympathetic subdivisions	336

WITHDRAWN
LIBRARY
COLLEGE OF MEDICAL EVANGELISTS
LOMA LINDA, CALIFORNIA

THE DIAGNOSIS OF NERVOUS DISEASES

CHAPTER I

ANATOMY AND PHYSIOLOGY

THERE is no department of medicine in which an accurate knowledge of anatomy is of greater importance than in the diagnosis of nervous diseases. Let us therefore, at the outset, recall some of the main points in the anatomy and physiology of the nervous system.

The nervous system consists of two main divisions:—(1) the **cerebro-spinal,** comprising the brain and spinal cord, together with the cranial and spinal nerves, and (2) the **vegetative**, constituted by two chains of pre-vertebral ganglia, one on each side of the spine, together with other ganglia, situated peripherally. These two systems, the cerebro-spinal and vegetative, intercommunicate.

For teaching purposes it is convenient to regard the nervous system as built up of nerve-cells, and their processes the nerve-fibres. Both are excitable. But whereas the nerve-cell or centron has been commonly assumed to originate impulses as does the cell of an electric battery, the nerve-fibres (axons and dendrons) serving merely as conductors, it is unusual for an impulse to arise within a nerve-cell, except as the result of a transmitted impulse.[1] Each nerve-fibre is made up of a bundle of extremely fine neuro-fibrillæ which traverse the nerve-cell, entering it through one process and leaving it through another. In this way the nerve-cell acts as a convenient shunt for impulses, receiving them from one quarter and transmitting them to another. The nerve-cell also exerts a trophic influence over the nerve-fibre and is intimately concerned with its nutrition, so that the nerve-fibre degenerates if separated from its trophic nerve-cell. Nerve-impulses usually pass through a nerve-fibre and nerve-cell in one direction only, each neuron having one end which is receptive in function and the other end through which it discharges its impulse.

[1] The cardiac and respiratory nuclei in the medulla are exceptions to this rule. These automatic centres can be stimulated, not only by transmitted nerve-impulses, but also by chemical changes in the blood, *e.g.* by deficiency of oxygen and excess of CO_2 or of lactic acid.

In a **reflex motor act,** which is the simplest manifestation of nervous energy, as for example in the plantar reflex, the impulse or stimulus starts from a sensory receptor or end-organ, in this instance the skin of the sole. The impulse is transmitted inwards by a conductor, the afferent or sensory nerve-fibre, through the corresponding posterior nerve-root into the spinal cord. Here it traverses an intercommunicating nerve-fibre and cell in the grey matter of the cord and reaches an adjustor or correlation centre in the anterior cornual cell. From this motor cell an efferent impulse starts, travels outwards along a second or efferent conductor traversing, first, an anterior nerve-root and then a peripheral nerve, finally reaching the effector apparatus, which in this instance is the flexor muscle of the toes innervated by the same segment of the spinal cord. The toe-flexors promptly give a single contraction.

The accompanying diagram (Fig. 1) will serve to recall the chief components of a simple spinal reflex, such as we have just described.

Some reflexes occur unconsciously, as for example the reflex contraction of the pupil when the retina is stimulated by light, or again, the normal movements of the stomach and intestines. But in other cases the afferent impulse, besides exciting a reflex motor action, sends part of its impulse upwards to the higher centres of the opposite cerebral hemisphere, either to the thalamus, where it arouses a general sensation of awareness, or of heat or cold with their associated feeling-tone of comfort or discomfort; or the impulse may pass farther on, to the sensory cortex, where it produces a conscious sensation. This is accomplished by means of a sensory fibre passing upwards in the substance of the spinal cord (as indicated in the other diagram—Fig. 2), through relays of nerve-cells and fibres in the medulla, pons, thalamus, and so on, to the perceiving centre in the cortex.

Moreover, a discharge of motor energy from the motor cell in the anterior cornu can be produced not only reflexly, from below, but also from above in one of two ways. Firstly, a voluntary, isolated synergic movement may be achieved by an impulse arising in the cortical motor centre of the opposite side and descending through the crossed pyramidal tract down the cord to the anterior cornual cell (see Fig. 2). Secondly, a motor impulse of a more primitive nature can be initiated by the corpus striatum, independently of the cerebral cortex. Such an impulse is transmitted downwards along extra-pyramidal paths, to the anterior cornual cells, giving rise to an automatic or associated movement of a group of muscles. The activity of such lower mechanisms is normally controlled and regulated by the higher cortical centres.

Confining ourselves now to the consideration of a cerebro-spinal

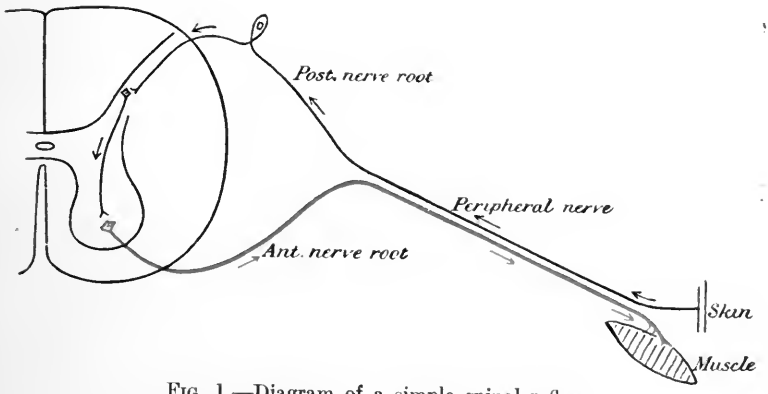

FIG. 1.—Diagram of a simple spinal reflex.

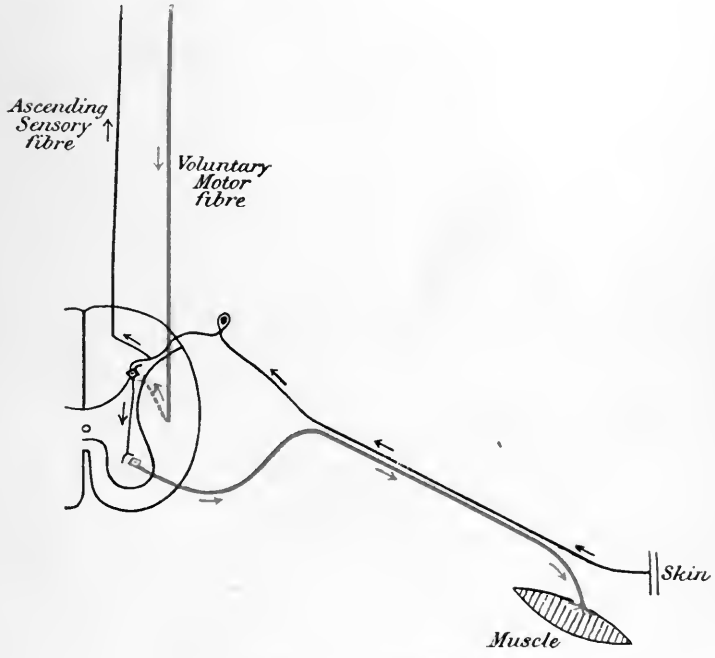

FIG. 2.—Diagram of a voluntary motor act.

To face page 2.

reflex motor action, we must bear in mind that afferent impulses, on reaching the cortical sensory centres, do not necessarily produce a descending impulse along the motor tract. If they do, this is simply an automatic action, a reflex of longer path. There exist in the cortex perceiving centres which take cognisance of the source and nature of the stimulus, and, by an act of discrimination, determine whether or no any active notice shall be taken of it, that is to say, whether a voluntary (and not merely an automatic or strio-spino-muscular) movement shall or shall not take place.

Some reflexes, even though associated with conscious sensory impressions (for example, the vomiting reflex or the sexual reflex), cannot be inhibited. This is possibly owing to the absence of antagonistic muscles which could prevent the reflex. But other reflexes can be inhibited by contracting the opposing muscles and thereby fixing the part which would otherwise make a reflex movement. Or by a process of training, a stimulus which originally induced one particular reflex may be made to associate itself with an entirely different response. (See "Conditional Reflexes," p. 333.)

Finally, by education, a motor impulse can be initiated at the cortical motor centre, without any preceding afferent impulse from the part to be moved. All movements in a new-born infant are either reflex or automatic; they are pre-ordained and admit of no choice. Only gradually does the child learn to use his cerebral cortex, to call in antagonistic muscles, and, by an effort of the will, to inhibit reflex and automatic acts, to initiate voluntary ones, and thereby consciously to adapt himself to his environment.

Certain more complicated reflexes, such as the reflex movements of respiration, have their centres in the medulla; others, such as the reflex movements of the heart and blood-vessels, have their lower reflex centres in the sympathetic ganglia, but can also be influenced by the cerebro-spinal nervous system. Others again, such as the movements of the heart, stomach, and intestine, can be performed independently of the central nervous system.

Cranio-cerebral Topography.—Figs. 3 and 4 are diagrams of the cerebral cortex, on its convex and its mesial aspects. It is unnecessary here to enumerate in detail the various fissures and sulci, or the different lobes and convolutions.

It is important to be able to identify, on the surface of the cranium, the positions of the Sylvian and Rolandic fissures.

The Sylvian fissure corresponds to the posterior part of a line drawn from the fronto-malar junction to the lower part of the parietal eminence. On this line the "Sylvian point," from which the ascending and anterior limbs of the fissure radiate, is identified by drawing a

line from the fronto-malar suture horizontally backwards, parallel to the upper border of the zygomatic arch, for 35 mm., and from the end of this a vertical line for 12 mm. upwards.

The central or Rolandic fissure starts at the middle line above, from a point 1 cm. (or half an inch) behind the mid-point between the nasion (centre of naso-frontal suture) and the external occipital protuberance (or inion). It runs downwards and forwards, along the convex surface of the brain, in the direction of the anterior part of the long posterior limb of the Sylvian fissure, making an angle of about 67½ degrees, *i.e.* three-quarters of a right angle, with the middle line. It is not a straight line but forms a sinuous curve, due to the presence of two buttresses (mesial and lateral) on its anterior wall, producing two

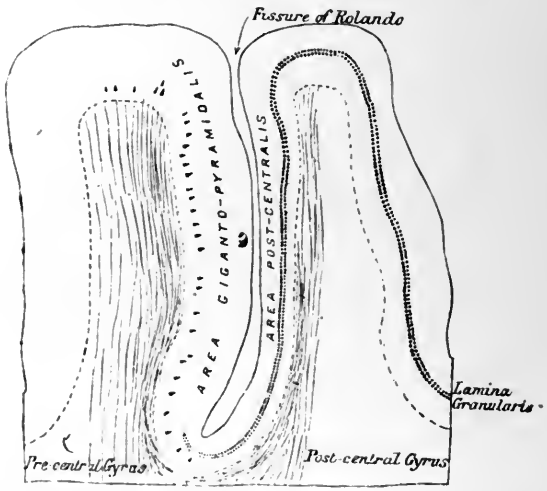

FIG. 5.—Diagram of cellular structure of pre- and post-central convolutions (after Vogt).

anterior concavities.[1] The mesial buttress is a leg-trunk buttress, the lateral buttress is an arm buttress (see Fig. 3).

These two figures also show diagrammatically our present views on cerebral localisation. It should be particularly observed that the motor areas in the pre-central convolution extend back as far as the Rolandic fissure but not behind it. Not only by experimental stimulation in anthropoid apes,[2] and in certain cases in man, but also by histological observation,[3] it has been shown that the posterior or sensory wall of the Rolandic fissure differs in function and structure from

[1] Symington and Crymble, *Journ. of Anat. and Physiol.*, vol. xlvii., 1913, p. 321.
[2] Sherrington and Grünbaum, *Trans. Path. Soc. Lond.*, 1902, vol. liii., p. 127.
[3] Campbell, A. W., *Histological Studies on the Localisation of Cerebral Function*, 1905. Brodmann, K., *Journ. f. Psychologie und Neurologie*, Bd. ii., p. 80.

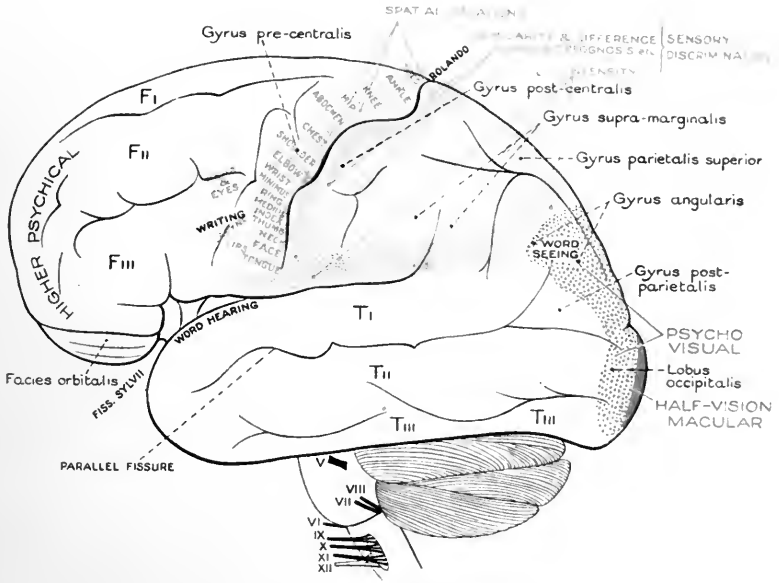

FIG. 3.—Scheme of Cerebral Localisation (outer surface).

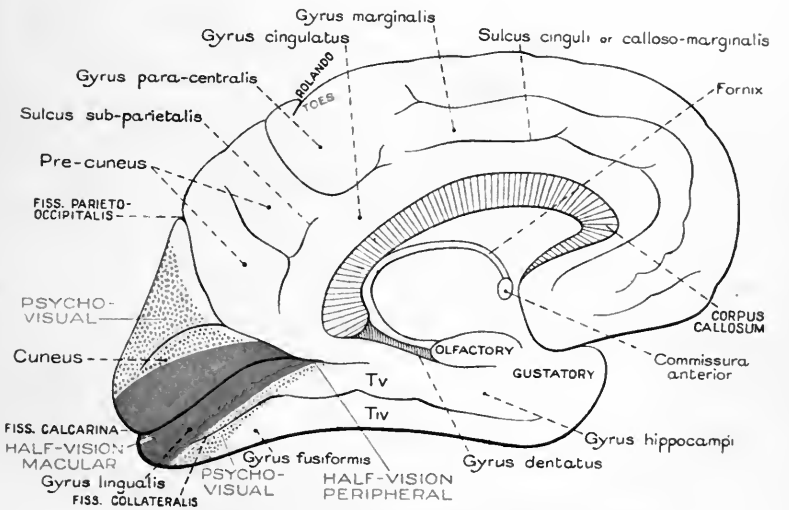

FIG. 4.—Scheme of cerebral localisation (mesial surface).

To face page 4.

the anterior or motor wall. The anterior wall possesses giant pyramidal cells (giving origin to the motor fibres of the pyramidal tract), and has no granular layer, whilst the posterior wall has a distinct granular layer, with no giant cells (see Fig. 5).

Another point to remember is that the several so-called motor areas are not sharply marked off from one another like a mosaic, but overlap; each area in Figs. 3 and 4 signifying that stimulation of that point produces the maximum movement of the particular part mentioned. Moreover, there are minor variations in the extent of the various centres in different individuals.

The chief path by which motor impulses are conducted from the cortical motor areas to the muscles is the **pyramidal tract,** whose course is diagrammatically indicated in Fig. 6. From the motor cells in the cortex the pyramidal motor fibres converge through the *corona radiata* into the great strand of nerve-fibres between the lenticular nucleus externally and the optic thalamus and caudate nucleus internally, namely, the *internal capsule*. Fig. 7 shows a horizontal section through the internal capsule, in which we notice that it has an anterior and a posterior limb, joining each other at an obtuse angle, the *genu* or knee. The motor fibres for the leg and arm occupy the anterior two-thirds of the posterior limb, the fibres for the tongue and mouth are at the genu, those for the face just in front. But the order in which these different strands pass through the internal capsule is not quite the same as that in which they started from the cortex. Thus we notice that immediately behind the fibres for the lips we have, from before backwards, those for the shoulder, elbow, and fingers (not fingers, elbow, shoulder), then for the trunk, and lastly for the hip, knee, and toes.

We also notice, in passing, that the ascending pathway (thalamo-cortical) of the sensory fibres traverses the posterior part of the capsule, and that behind them again are the visual fibres. The sensory fibres probably do not form a separate, compact bundle, but are partially mingled with some of the motor fibres for the leg.

Before leaving Figs. 6 and 7, it is of interest to study briefly, with their help, the different effects produced by lesions of the pyramidal motor tract at various levels.

A lesion in or near the motor cortex, if of moderate size, will produce, according to its situation, a monoplegia of the face, arm, or leg, on the opposite side of the body. A somewhat larger lesion will produce a brachio-facial or a brachio-crural monoplegia. From the proximity to the middle line of the cortical centres for the leg, a mesial, or bilaterally symmetrical, lesion may implicate the leg centres of both sides, producing a diplegia, mainly affecting the legs. (We observe that facio-crural monoplegia without implication of the arm is impos-

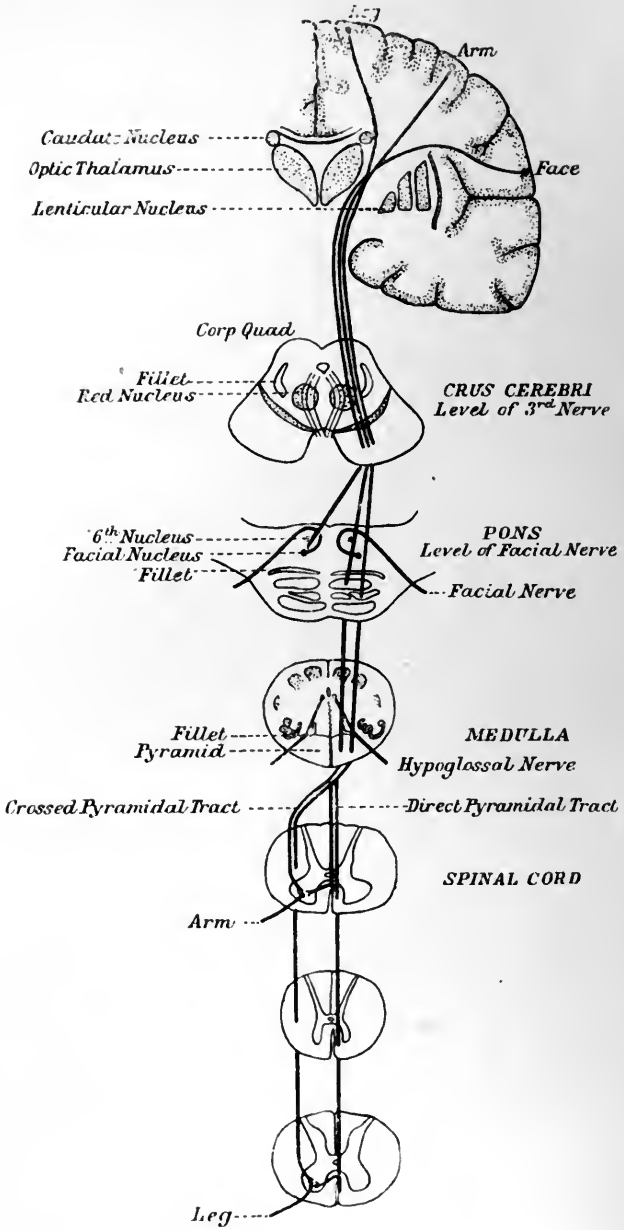

Fig. 6.—Diagram of pyramidal tract and its course through the brain and cord.

sible from a single lesion.) For the production of a complete hemiplegia of face, arm, and leg a cortical lesion must be very extensive. But in the *internal capsule* all these strands are closely crowded together, so that a moderate-sized capsular lesion can produce a complete hemiplegia, whereas a capsular lesion small enough to cause a mere monoplegia is well-nigh impossible.

If the capsular lesion be in the region of the *genu* we have hemiplegia of face, arm, and leg. And moreover, from paralysis of the

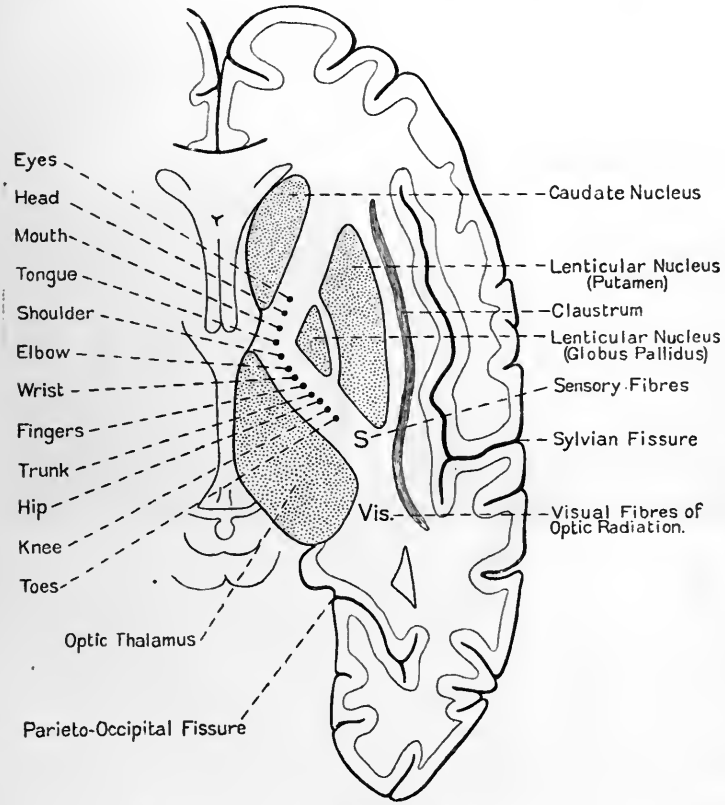

FIG. 7.—Horizontal section through right cerebral hemisphere, showing position of the various strands in the internal capsule. (Modified from Beevor and Horsley.)

muscles which rotate the head and eyes to the opposite side, the patient has "conjugate deviation" of the head and eyes towards the side of the lesion, owing to unopposed action of the muscles supplied by the intact hemisphere.

If, on the other hand, the capsular lesion be farther back along the posterior limb of the capsule, the hemiplegia will affect the leg much more than the arm, and the face only slightly; whilst, owing

to interference with the sensory tract, which lies between the motor and the visual fibres, there will now be hemianæsthesia also.

Lastly, if the lesion be at the extreme posterior end of the capsule, there will be not only hemianæsthesia but also hemianopia from interruption of the visual fibres. Here again we note that it is impossible for a single capsular lesion to produce at the same time hemiplegia and hemianopia without also producing hemianæsthesia. If a patient with hemianopia is also hemiplegic but without hemianæsthesia, we should diagnose two separate lesions.

Figs. 8 and 8A are from such a case, in which a patient with left hemianopia due to a tumour of the right occipital lobe subsequently became totally hemiplegic with only a faint trace of hemianæsthesia.

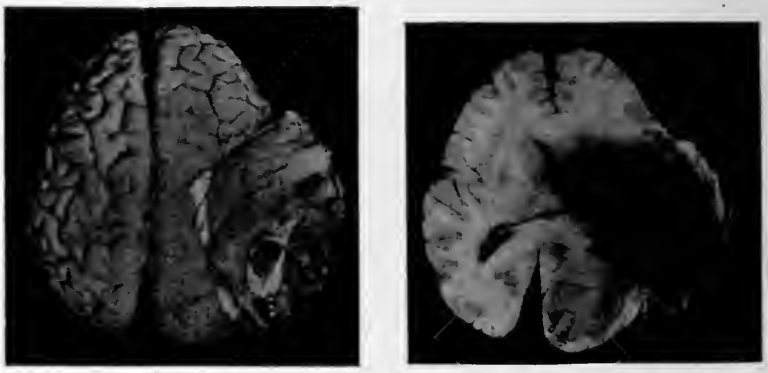

FIGS. 8 AND 8A.—Case of tumour at posterior pole of right occipital lobe, in which decompressive trephining had been performed. A large hernia cerebri developed, and subsequently a hæmorrhage occurred anterior to the tumour, within the substance of the hernia.

The diagnosis of two distinct lesions was confirmed at the autopsy: the original tumour in the posterior end of the occipital region being separated by an intervening healthy zone from a large hæmorrhage farther forward in the hemisphere.

A lesion of the crus cerebri will tend to implicate the third cranial nerve on the side of the lesion, producing at the same time a hemiplegia of face, arm, and leg on the opposite side. This so-called "Weber's syndrome" is one variety of "crossed paralysis."

A unilateral lesion of the pons at the level of exit of the facial nerve will produce another "crossed paralysis," viz.:—facial palsy on the side of the lesion with hemiplegia of the arm and leg of the opposite side. And if at the same time the nucleus of the sixth cranial nerve be implicated (which is not unusual, since the facial nerve hooks round the sixth nucleus within the pons), we have nuclear palsy of the

sixth nerve, facial palsy on the same side, and hemiplegia of the arm and leg on the opposite side:—the "Millard-Gubler syndrome."

Unilateral lesions of the pons or medulla oblongata below the level of the facial nerve leave the face unaffected and produce only a hemiplegia of arm and leg. And a *unilateral lesion of the spinal cord* below the cervical enlargement will produce a monoplegia of the leg on the side of the lesion without affection of the arm. It will also produce

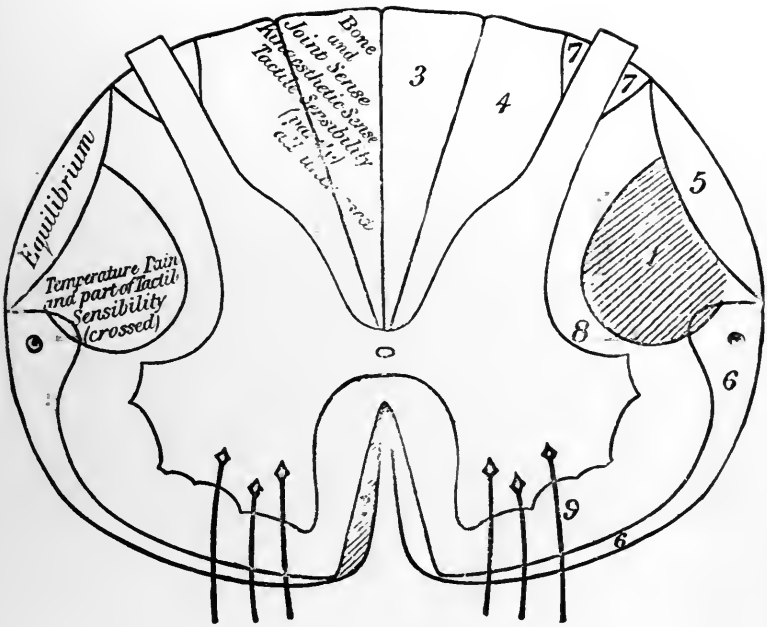

FIG. 9.—Diagram of tracts in the spinal cord.

1. Crossed pyramidal tract (descending) and spino-thalamic tract (ascending).
2. Direct pyramidal tract.
3. Postero-internal tract (Goll).
4. Postero-external tract (Burdach).
5. Direct or dorsal cerebellar tract.
6. Ventral cerebellar tract (Gowers).
7. Lissauer's marginal zone.
8. Lateral ground-bundle.
9. Anterior ground-bundle.

some anæsthesia of the opposite leg. Such motor paralysis of one leg and sensory paralysis of the other is called "Brown-Séquard paralysis," to which we shall return later.

Fig. 9 is a diagram representing the tracts in the spinal cord of chief clinical interest. There are also other ascending and descending tracts of minor importance, which we have omitted from the diagram for the sake of simplicity.

The **pyramidal tracts** are by far the most important descending tracts in the cord, for they convey voluntary motor impulses downwards from the motor cortex towards the anterior cornua. The

pyramidal fibre does not actually join the anterior cornu, but ends in the region of the posterior cornu, whence a short intermediate connecting-cell and fibre run forward, linking it to the anterior cornual cell (see Fig. 2). Most of the voluntary motor impulses decussate at the lower end of the medulla and traverse the crossed pyramidal tract in the lateral column; a few run in the direct pyramidal tract and cross over later within the cord itself. A few pyramidal fibres also run down in the ipso-lateral pyramidal tract (which we might, somewhat paradoxically, call the uncrossed crossed-pyramidal tract). These fibres probably do not cross over, but supply motor impulses to the ipso-lateral leg. They account for the occurrence in hemiplegia of certain phenomena on the opposite, "non-paralysed" side, such as paresis, increased deep reflexes, and sometimes contractures in the "healthy" lower limb.

The **corpus striatum,** made up of two great basal ganglia, the lenticular and the caudate nucleus, separated by sheets of white matter (see Fig. 7, p. 7), constitutes an important infra-cortical centre, whose function is predominantly motor or efferent, just as the function of the thalamus is predominantly sensory or afferent. The corpus striatum is composed of two cellular systems, which differ in structure and in function:—

1. Large ganglion-cells of the **pallidal system.** These are situated mostly in the globus pallidus of the lenticular nucleus, but also occur scattered through other parts of the corpus striatum. These pallidal cells with long axis-cylinders, are motor in function.

2. Small ganglion-cells of the **neo-striate system.** These are situated in the caudate nucleus and in the putamen of the lenticular nucleus. They give origin to short axis-cylinders, terminating in the globus pallidus. Their function is probably inhibitory and co-ordinating.

Destruction of the large-celled pallidal system, *e.g.* by primary degeneration, produces the syndrome of paralysis agitans[1]—viz. muscular rigidity, with tremor, and disturbance of automatic movements (such as the winking reflex) and of associated movements (such as the swing of the arm in walking).

Destruction of the small-celled, neo-striate, or inhibitory system is followed by choreic or athetoid phenomena, as in Huntington's chorea (see p. 85).

The globus pallidus, the motor nucleus of the striate body, is a short, efferent, projection-system which is connected, by short strio-fugal fibres, with various important motor nuclei in the subthalamic region, *e.g.* with the red nucleus, Deiters' nucleus, superior corpus quadrigeminum, etc. These subthalamic centres, in turn, send down **subcortico-spinal motor tracts** which enter the spinal cord from

[1] Ramsay Hunt, *Brain*, 1917, vol. xl., p. 58.

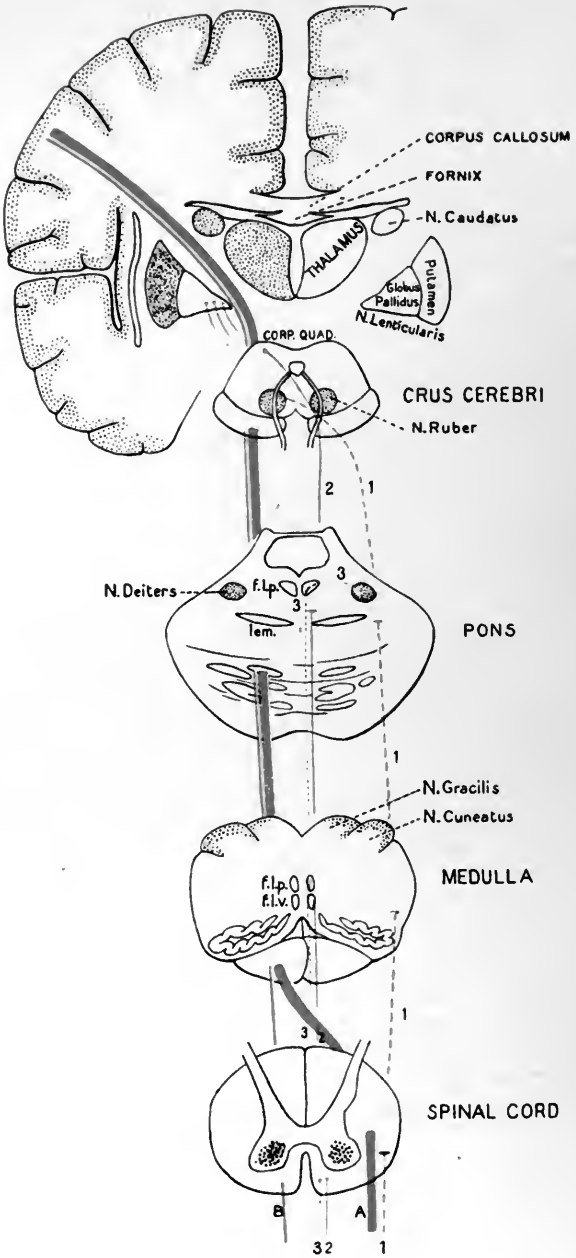

FIG. 10.—Cortico-spinala nd sub-cortico-spinal tracts.

A, Crossed pyramidal tract;
B, Direct pyramidal tract.
1, Rubro-spinal tract;
2, Tecto-spinal tract;
3, Vestibulo-spinal tract.

To face page 11.

above, and constitute the **strio-spinal motor system.** The strio-spinal fibres end among the cells of the anterior horns, and provide a mechanism for the performance of certain automatic acts which may still be possible when voluntary motor power is absent, as in pyramidal disease. Of the subcortico-spinal tracts the most important are the following (see Fig. 10):—

1. The *rubro-spinal* or *pre-pyramidal* tract (Monakow's bundle).—This tract arises in the red nucleus of the crus cerebri, decussates almost at once in the tegmentum, and descends in the contra-lateral side of the pons and medulla to the lateral column of the spinal cord, where it lies ventral to the crossed pyramidal tract.

2. The *tecto-spinal* tract or *ventral longitudinal bundle.*—This arises in the roof or tectum of the mid-brain from the optic and acoustic reflex centres in the anterior corpus quadrigeminum, crosses over in Meynert's "fountain" decussation beneath the Sylvian aqueduct, and then runs down the contra-lateral side of the formatio reticularis to the ventral column of the spinal cord.

3. The *vestibulo-spinal* tract or *dorsal longitudinal bundle.*—This arises from the accessory vestibular nucleus of Deiters within the pons, and passing downwards mainly on the ipso-lateral side of the spinal cord in the ventral column, ends amongst the anterior cornual cells.

In the adult the ventral and dorsal longitudinal bundles are indistinguishable from each other in sections of the medulla or spinal cord, but they myelinate at different periods of development, and can thus readily be differentiated in the fœtus.

4. The *ponto-spinal* tract.—This is derived from cells of the formatio reticularis of the pons. Part of it runs down the ventral column of the ipso-lateral side, whilst part decussates in the raphé of the medulla and enters the opposite lateral column of the spinal cord.

The cells of the pallidal system occupy the same relation to the extra-pyramidal motor tracts as the cells of the motor cortex occupy with regard to the great pyramidal tracts. The globus pallidus mechanism controls automatic and associated movements, whereas the cells of the motor cortex control voluntary isolated and synergic movements. It is interesting to recall the fact that at the eighth month of fœtal life the pyramidal tracts in the spinal cord are imperfectly developed and do not yet contain axis-cylinders. Nevertheless, an infant, even one born prematurely at the seventh month, displays remarkable powers and diversity of movement, all its movements being carried out by means of this strio-spinal motor system, which develops much earlier than the cortico-spinal.

The supremacy of the cortico-spinal system is further evidenced by the fact that complete paralysis of voluntary movement is met with in lesions of this path alone; whereas in extra-pyramidal motor diseases we never see total loss of power. Voluntary movements in strio-spinal lesions may be impeded by tremor, rigidity, or athetosis, but they are not lost.[1]

[1] Walshe, *Brain*, 1919, p. 5.

Both of these systems (pyramidal or cortico-spinal, and extra-pyramidal or strio-spinal), in addition to the function of motor innervation, exercise a controlling effect upon muscular tonus, so that a destructive lesion of either of them produces, as a result, paralysis of a special type, together with an increase of muscular tonus, most easily recognisable in the limbs. Thus in a pure pyramidal lesion, as in ordinary hemiplegia, the extra-pyramidal tracts, being now unopposed, produce tonic rigidity, especially of the extensor muscles of the lower limbs, with a characteristic posture. On the other hand, a pure pallidal lesion, as in progressive lenticular degeneration and in certain types of paralysis agitans, produces rigidity of the voluntary muscles, from unopposed pyramidal innervation, but without the alterations in reflexes which are so characteristic of ordinary pyramidal disease. Phylogenetically, the strio-spinal system is an older and more primitive mechanism than the cortico-spinal system. So, also, the automatic and associated movements controlled by the corpus striatum are phylogenetically older than the isolated synergic movements of cortical origin.

Sensory Paths.—According to Head, Rivers, and Sherren,[1] the various afferent impulses from the periphery, on their way towards the spinal cord, do not run indiscriminately along the afferent nerves but are conducted along several distinct classes of nerve fibres. According to these observers, common sensation is a complex affair, based on three kinds of sensibility:—

1. *Deep sensibility*, a variety which takes cognisance of deep pressure, and which, if that pressure be excessive, is capable of producing a sensation of pain—"pressure-pain." Deep sensibility also includes sensations from muscles and tendons, from joints, and the vibration-sense (see later, pp. 189-190). The sensory fibres conducting deep sensibility run along with the motor nerves of the muscles and tendons. So long as these deep pressure-sense fibres are intact, even though the skin be totally analgesic, the patient is able to appreciate the pressure-touch and pressure-pain of a blunt pencil, the vibration of a tuning-fork, and the position of his joints on passive movement. The fibres for deep sensibility are not destroyed by division of all the sensory nerves to the skin.

2. *Protopathic* cutaneous sensibility, a variety which responds to all painful cutaneous stimuli (pricking, pinching, faradic stimulation), also to extremes of cold and heat, like freezing and burning (temperatures of 45° C. and over, and of 10° C. and under). These protopathic fibres from the skin are the first to regenerate after injury to a cutaneous nerve, so that the protopathic sensations are the earliest to recover as a cutaneous nerve heals. Ranson[2] suggests that protopathic

[1] *Brain*, 1905, pp. 99–115. [2] *Ibid.*, 1915, vol. xxxviii., p. 381.

cutaneous sensations are conducted by the non-myelinated nerve-fibres, whereas the myelinated fibres are responsible for epicritic sensations. It is significant that, exactly at the time when protopathic sensation begins to recover, after a nerve-injury, innervation also returns to the sweat-glands and blood vessels of the affected skin-area, indicating regeneration of the vaso-motor and secretory fibres, which are known to be unmyelinated.

3. *Epicritic* cutaneous sensibility, whose fibres are the slowest to recover after injury. This group includes the appreciation of light touches, of cutaneous localisation (the discrimination of two points of an opened compass as being separate), the recognition of finer differences of temperature—not merely between hot and cold, but between warm and cool. These differences, it should be noted, apply only to the extra-spinal portion of the sensory paths, *i.e.* to the peripheral nerves.

Epicritic sensibility is normally absent over the glans penis which is innervated entirely by protopathic fibres. The internal organs are also supplied from the protopathic system; they possess no controlling epicritic mechanism.

All the sensory impulses, whether conveying sensations of touch, temperature, or pain from the skin, sensation of active muscular contraction from the muscles (kinæsthetic sense), or sensations from the joints or bones, enter the spinal cord through the posterior roots, as indicated in Fig. 11.

Once the afferent impulses enter the spinal cord, it is no longer a question of deep, epicritic, or protopathic sensation; they now become redistributed in simpler fashion. Thus all sensations of temperature run together in one tract, whether they reached the cord by the protopathic or the epicritic route: similarly all sensations of pain run together in the cord, whether they were protopathic, or "deep" in the peripheral nerves, and so on. This is indicated in the following scheme:—

Paths in Spinal Cord.			Paths in Peripheral Nerves.	
Posterior Column, Lateral Column	Tactile	α, β, γ, δ	Deep . .	α Pressure.
			Epicritic . .	β Light Touches.
				γ Localisation.
				δ Differences in Size.
Lateral Column	Temperature	ε, ζ		ε Moderate differences of Temperature.
			Protopathic	ζ Extreme differences of Temperature.
	Pain	η, θ		η Cutaneous Pain (pricks, freezing, burns, electricity).
				θ Pressure-Pain.
Posterior Column	Muscles	ι	Deep . .	ι Lengthening or Shortening of Muscles.
	Joints	κ		κ Joints—passive movements.
	Vibration (Bone).	λ		λ Vibration (tuning-fork).

Of these various impulses, the fibres conveying sensations from the muscles and joints, together with the smaller part of the fibres for

tactile sensation, ascend in the posterior column to the gracile and cuneate nuclei of the same side of the medulla.

Most of the fibres for tactile sense, together with all fibres for temperature and pain, cross in the anterior commissure to the opposite side (these crossed fibres not coming directly from the posterior root, but through the relay of another cell in the posterior horn) and ascend the cord in the opposite lateral column, in the *spino-thalamic tract*. Thus the lateral column conducts not only pyramidal motor impulses coming down, but also spino-thalamic ascending impulses of touch, temperature, and pain.

The upward course of the various sensory fibres through the medulla and pons is somewhat complicated, and not yet entirely settled, but the most probable arrangement is shown in Fig. 12.

Most of the fibres for *touch* cross the middle line in the spinal cord, as already explained, and then pass directly upwards in the spino-thalamic tract of the lateral column and into that part of the medulla called the *formatio reticularis*. The formatio reticularis leads the fibres up through the pons and crus to the ventro-lateral region of the optic thalamus. Thence they pass through the posterior limb of the internal capsule to the sensory cortex behind the fissure of Rolando.

As the sensory tract traverses the pons it passes along the inner side of the sensory spinal root of the trigeminal nerve of the same side. Thus a *unilateral lesion of the formatio reticularis* just below the exit of the fifth or trigeminal nerve will produce a " crossed anæsthesia," *i.e.* anæsthesia of the face on the side of the lesion, and of the arm, leg, and trunk of the opposite side. But higher up the pons the sensory fibres from the face also cross the middle line, so that a lesion of the formatio reticularis in the crus cerebri will now cause complete hemi-anæsthesia of face, arm, and leg (see Fig. 13).

The fibres for *temperature* and *pain*, entering by the posterior root, pass into the grey matter of the posterior cornu. There they start afresh and cross to the opposite side of the cord, ascending in the opposite lateral column near the crossed tactile fibres. On reaching the medulla, they diverge from the tactile fibres and pass to the outer side of the olivary body, close to the lateral margin of the medulla and intermingled with the fibres of Gowers' tract. They then leave the region of Gowers' tract and pass upwards through the pons, gradually inclining towards the other sensory tracts and ultimately ascending with them to the ventro-lateral part of the optic thalamus and thence through the internal capsule to the cortex. Gowers' tract (the ventral cerebellar), now separate from the temperature and pain fibres in the upper part of the pons, hooks sharply backwards and enters the cerebellum from above, through its superior peduncle.

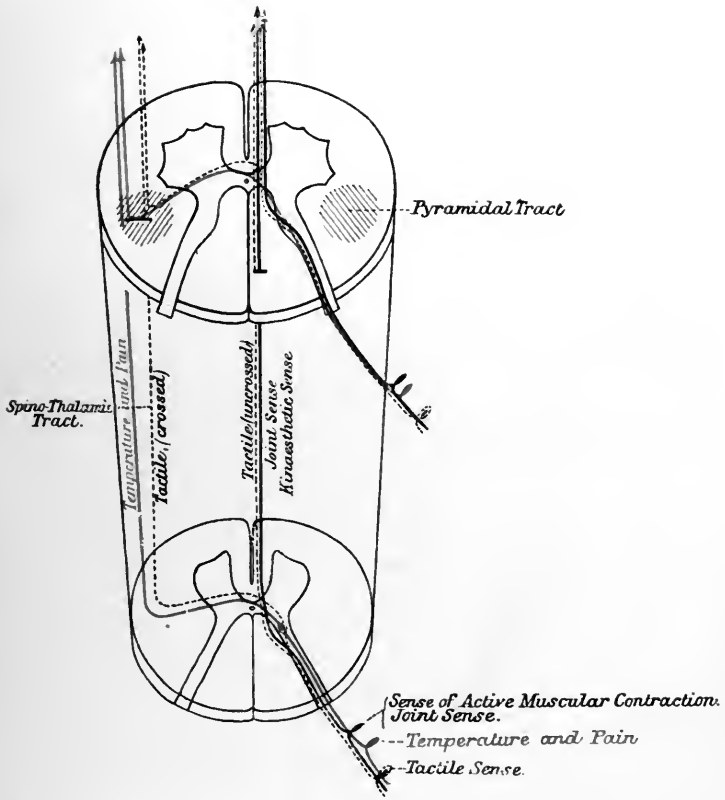

FIG. 11.—Diagram illustrating the course of the various sensory paths in the spinal cord.

To face page 14.

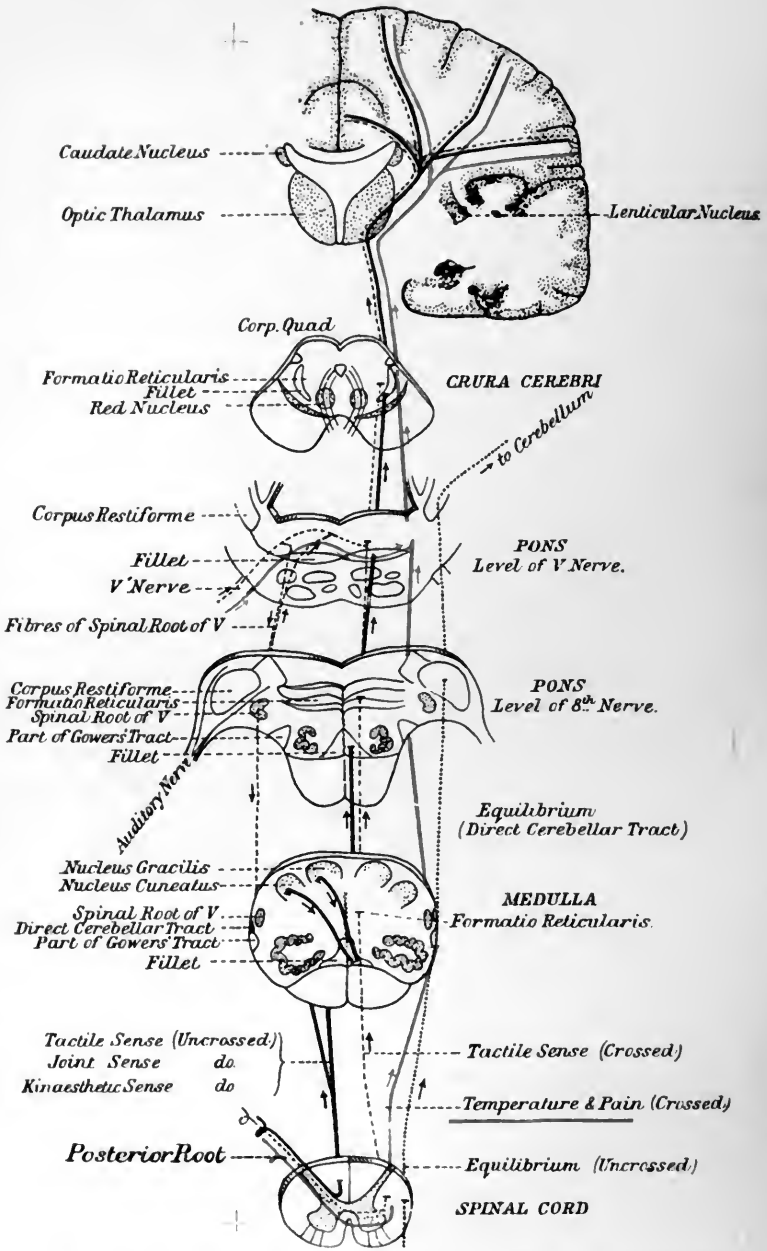

FIG. 12.—Diagram of chief sensory tracts in spinal cord, medulla, pons, and cerebrum.

To face page 15.

The sensory fibres from *muscles* (kinæsthetic sense and pressure-pain sense) and from *bones*, together with the uncrossed minority of tactile fibres, ascend uncrossed in the posterior column of the cord to the nucleus gracilis and nucleus cuneatus, the nucleus gracilis receiving the fibres from the lower limb, the nucleus cuneatus those from the upper limb. Some impulses pass *viâ* the restiform body to the

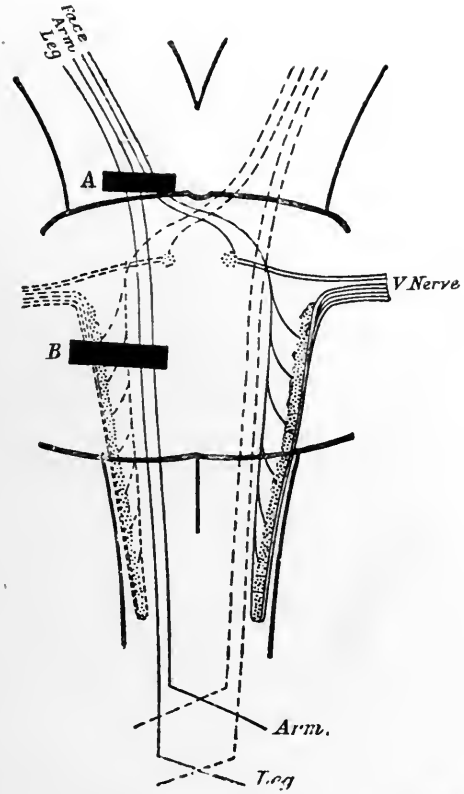

Fig. 13.—Course of sensory fibres in the pons (Starr).

A. Lesion causing right hemianæsthesia.
B. Lesion causing "alternate hemianæsthesia" of left face and right side of body.

cerebellum and although not destined to give rise to conscious sensations, they influence co-ordination and muscular tonus.[1] The remainder of the sensory fibres in the posterior columns, after reaching the nucleus gracilis and nucleus cuneatus, pass upwards, and cross the middle

[1] Muscular tonus, or postural contraction, is a reflex affair dependent upon the integrity of a reflex arc, whose afferent path is in the posterior roots and posterior column fibres, whose centre is in the cerebellum, and whose efferent path is in the vestibulo-spinal and other extra-pyramidal tracts.

line in the internal arcuate fibres, forming the superior sensory decussation of the fillet (contrast this with the spinal decussation of the thermal, pain, and the majority of the tactile fibres). The sensory fibres from the leg, passing through the nucleus gracilis, cross lower down than those from the arm, which go through the nucleus cuneatus. Having crossed to the opposite side and reached the fillet, a flattened strand of fibres, they pass upwards in that tract not far from the thermal and pain fibres.

The main mass of the tactile fibres ascends through the crus cerebri to the **optic thalamus.**

All sensory impulses which reach the thalamus are there grouped afresh and redistributed in two directions. Some impulses ascend higher, to the cortex cerebri; others terminate in the grey matter of the thalamus itself, which thus forms an important subcortical sensory centre, subserving certain primitive, non-discriminative elements of sensation, especially the feeling-tones of *pleasure* and *pain* and of certain *visceral sensations.*

From the thalamus the sensory path ascends to the **sensory cortex.** This comprises the pre- and post-central gyri, the anterior part of the superior parietal lobule, the supra-marginal and the angular gyrus. (See Fig. 3, p. 4.) The anterior part of the sensory cortex thus overlaps the motor areas.

All the afferent impulses to the sensory cortex (with the exception of those from the olfactory organs) reach it through the thalamus, which constitutes a sort of vestibule to the sensory cortical centres.

In the cortex, according to Head's masterly researches,[1] sensory impressions are no longer associated with crude sensations such as touch, pain, heat, and cold; but at this level sensation becomes endowed with three discriminative faculties, viz.:

1. The recognition of *spatial relations.* This comprises the recognition of three-dimensional space (appreciation of passive movements of the affected part), of two-dimensional space (compass-test, whereby the individual recognises two blunt points as being separate at a definite distance apart), and of uni-dimensional space (topognosis or spot-finding).

2. The recognition of differences in *intensity* between different stimuli, *e.g.* the difference between a warm object and a warmer, or between a cold object and one which is merely cool.

3. The appreciation of *similarity and difference* in external objects brought into contact with the surface of the body, including differences of size, weight, form, and texture. This includes *stereognosis*, whereby the patient recognises the shape and nature of common objects placed

[1] Head. "Sensation and the Cerebral Cortex." *Brain*, xli., 1918, p. 57.

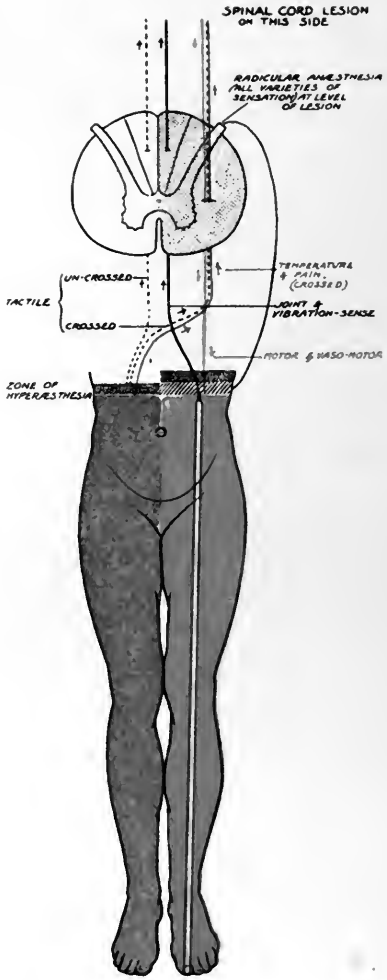

FIG. 14.—Diagram illustrating the symptoms resulting from a left-sided hemisection of the spinal cord (Brown-Séquard syndrome).

To face page 17.

in the contra-lateral hand, without looking at them (*e.g.* a coin, corkscrew, button-hook, or knife). Differences of weight are tested by the comparison of a penny with a half-crown, or a shilling with a sovereign; differences of texture by comparing the feel of silk, cotton, canvas, velvet, etc. So far as lesions of the cortex are concerned, these particular aspects of sensory discrimination—size, shape, weight, and texture, tend to be disturbed all together.

These three great discriminative faculties of the sensory cortex are not disturbed uniformly in lesions of the surface of the brain. Thus, whilst some loss of *spatial* recognition may be produced by a lesion anywhere within the sensory cortical area, the farther *forward* the lesion lies within the sensory cortex, the grosser and more extensive is the disability shown by spatial tests.

The cortical recognition of differences in *intensity* of stimuli, although distributed diffusely throughout the whole sensory cortex, is maximally represented in the *posterior and inferior* portions of the sensory area, *i.e.* the foot of the pre- and post-central gyri, the angular and supra-marginal gyri and the superior parietal lobule.

The *post-central gyrus* is specially associated with the power of recognising *similarity and difference* in the weights and shapes of test-objects placed in the contra-lateral hand.[1]

We have still to consider another tract, which conducts sensory fibres for the *sense of equilibrium*, derived mainly by kinæsthetic impulses from the muscles. This tract does not commence in the posterior root-ganglion but arises as an "endogenous" tract within the cord. Arising from the cells of Clarke's column at the base of the posterior horn, it constitutes the direct (or dorsal) cerebellar tract and ascends, uncrossed, into the restiform body and cerebellum, terminating among the Purkinje cells of the cerebellar cortex.

Before leaving the motor and sensory tracts within the central nervous system it will be useful to mention the symptoms produced by a lesion of one lateral half of the spinal cord. Such a lesion is most commonly the result of a stab in the back; less commonly it is produced by bullet-wounds, fractured spine, caries, or by chronic diseases of the spinal cord itself. The syndrome which results is known as **Brown-Séquard paralysis,** and it will be readily understood by reference to Figs. 11 and 14. The symptoms are as follows:—

(1) *On the side of the lesion* we have, from interruption of the motor tract, motor paralysis of the corresponding leg, with an extensor plantar reflex from the outset and, later on, exaggeration

[1] Faradic stimulation of the post-Rolandic cortex in the human subject produces sensory phenomena which are referred to the contra-lateral limb, or other part of the body, corresponding to the particular cortical centre.

of the deep reflexes. There is a slight and transient elevation of temperature, owing to the interruption of vasomotor fibres which descend in the lateral column. There is loss of sense of position on passive movement of the limb, loss of power of estimating weights, and loss of "vibration sense" (tested by a tuning-fork) in the bones of the paralysed leg, due to interruption of the uncrossed fibres from the posterior roots below the lesion, which ascend in the posterior column. The skin of the paralysed leg is not anæsthetic, but, just at the level of the lesion, there is around the trunk a narrow zone of total anæsthesia (to touch, temperature, and pain) from lesion of the fibres of the posterior root or roots at the level of the injury. Finally, in cases with an abrupt onset, there is a narrow zone of hyperæsthesia above the anæsthetic zone, perhaps due to local irritation of the lowest unsevered posterior-root fibres in the cord, close above the lesion; but this explanation is in dispute.

(2) *On the side opposite to the lesion* there is no motor paralysis. But there is loss of cutaneous sensation to temperature and pain (completely), and to touch (partially), in the non-paralysed lower limb and in the corresponding half of the trunk up to the level of the lesion. There is a zone of hyperæsthesia above the anæsthetic area, as on the side of the injury. Motor power is unimpaired, so also is the sensation of position on active or passive movement of the limb.

Cerebellum.—

The cerebellum consists of two lateral lobes or *hemispheres* joined together by a median lobe or *vermis*. Between the two hemispheres, on the ventral aspect, is a deep median fossa or *vallecula*, whose floor is formed by the projection of the inferior vermis. In the posterior part of this fossa lies the medulla, in front of which are the pons and crura cerebri running forward through the anterior cerebellar notch. The upper surface of the middle lobe (superior vermis) passes into the lateral lobe without any distinct line of demarcation, whereas its under surface (inferior vermis) forms a mesial projection in the vallecula, sharply marked off from the hemispheres by deep antero-posterior groves, one on each side. The cortex of vermis and lateral lobes is deeply folded into fine leaves or laminæ, separated by closely-set fissures running sinuously, more or less parallel with each other, some of them running obliquely between the others.

The vermis, at an early stage of development, is divided by the *primary* (or *preclival*) *fissure* into an *anterior* and a *posterior lobe*. In the adult condition it is still further subdivided into finely laminated lobules, which are best seen on sagittal section (see Fig. 15). In front of the primary fissure we have three lobules: *lingula*, *lobulus centralis*, and *culmen*, from before backwards. Behind the primary fissure, in the posterior lobe, matters are much more complex, and there are six lobules: *clivus*, *folium vermis*, *tuber vermis*, *pyramis*, *uvula*, and *nodulus*. These form, as it were, branches of a tree (*arbor vitæ*) whose trunk is planted on the roof of the fourth ventricle, with its most anterior branch,

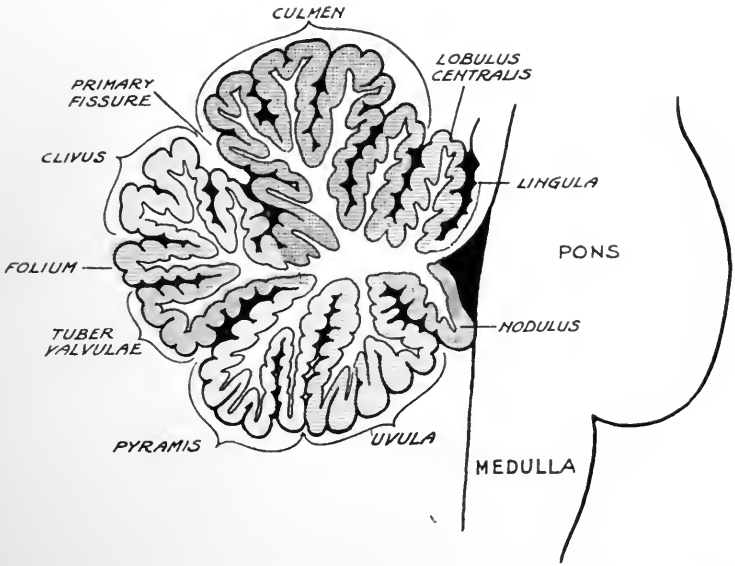

Fig. 15.—Vertical mesial section through cerebellum, pons and medulla.

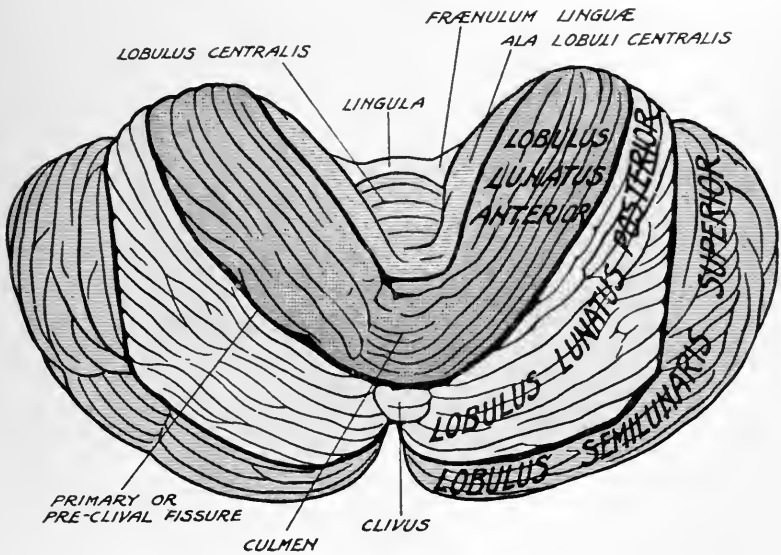

Fig. 16.—Cerebellum: Upper surface.

To face page 18.

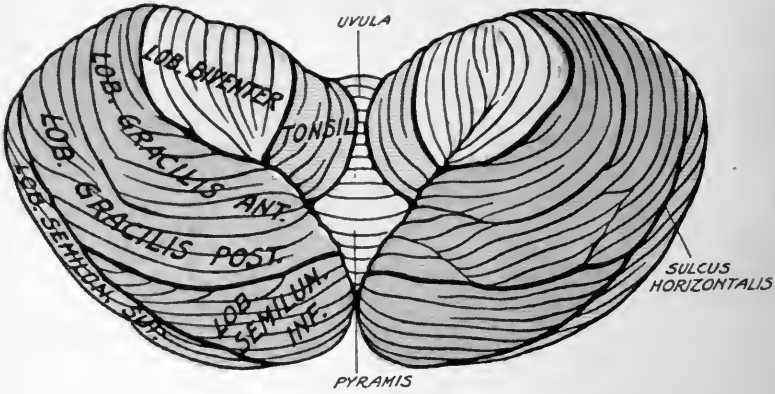

FIG. 17.—Cerebellum: Posterior surface.

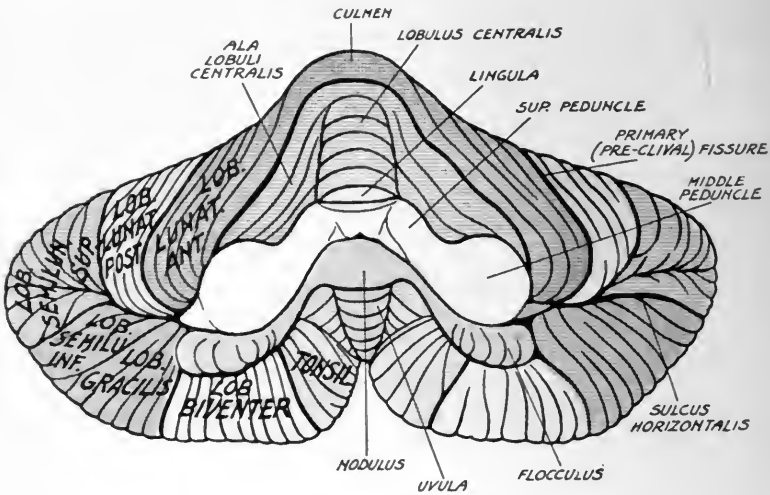

FIG. 18.—Cerebellum: Antero-inferior or ventral surface.

To face page 19

the lingula, on the anterior medullary velum in front, and its most posterior branch, the nodulus, on the posterior medullary velum behind.

The cerebellar hemispheres, like the vermis, are divided by the primary fissure into anterior and posterior lobes, and for each lobule of the vermis there is a corresponding lobule of the hemisphere with which it is continuous. Thus in the *anterior lobe*, on each side from before backwards, there is the *frænulum linguæ*, the *ala lobuli centralis*, and the *lobulus lunatus anterior*, seen on the upper and anterior surfaces (Figs. 16 and 17), whilst the more complex *posterior lobe* has the *lobulus lunatus posterior*, the *lobulus semilunaris superior*, followed, on the posterior and postero-inferior aspects, by the *lobulus semilunaris inferior*, *lobulus gracilis*, *lobulus biventer*, and the *tonsil* (Fig. 18). Laterally situated from the lobulus biventer and tonsil, and lying in a deep sulcus immediately behind the middle peduncle on each side, is a

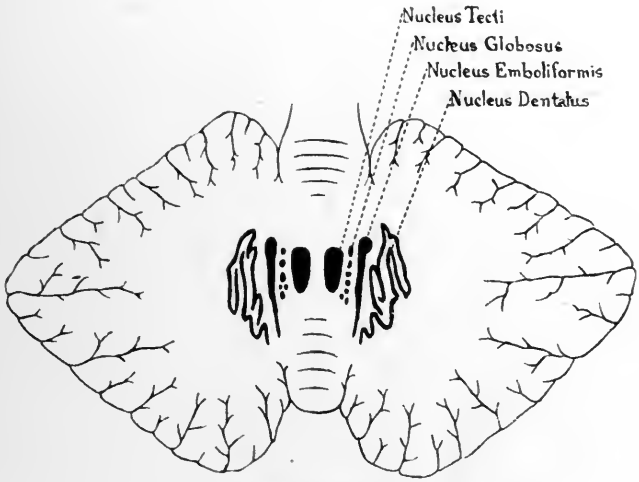

FIG. 19.—Horizontal section through cerebellum.

small irregular lobule, the *flocculus*. The various fissures of the cerebellum are indicated on Figs. 15 to 18.

Within the white matter, at a distance from the cortex and analogous in some respects to the basal ganglia of the cerebrum, there are several important masses of grey matter from which various efferent tracts lead to other parts of the brain. Of these the chief are the *corpora dentata*, two hollow crumpled sacs, one within each lateral lobe; the *roof nuclei* within the middle lobe, so called because they lie in the roof of the fourth ventricle; the *nuclei globosi* and the *nuclei emboliformes*, bilaterally situated, between the roof nucleus and the dentate nucleus (see Fig. 19); and the *nuclei of Deiters*, or accessory vestibular nuclei, within the pons, one on each lateral aspect. Deiters' nucleus is an important reflex centre. It receives afferent impulses, some from the vestibular nerve and the cerebellar cortex; others from the ocular nuclei (third and sixth) *viâ* the dorsal longitudinal bundle. In turn it gives off efferent fibres to the anterior cornual cells of the same side of the cord, through the vestibulo-spinal tract (see later, p. 40).

Each lateral lobe is attached to the brain-stem by three peduncles —superior, middle, and inferior (Fig. 20)—consisting of fibres some of which run towards the cerebellum (cerebello-petal), others away from it (cerebello-fugal).

The **cerebello-petal fibres** terminate around the large Purkinje cells of the cerebellar cortex, which is essentially a receiving platform.

In the inferior peduncle, or restiform body, which connects the cerebellum with the medulla and spinal cord, all the paths are cerebello-petal, leading to the cerebellar cortex. Amongst them the most important is the *dorsal or direct cerebellar tract,* conveying impulses of equilibrium from the ipso-lateral side of the spinal cord, and the *arcuate fibres,* from the posterior column nuclei of both sides, and from the inferior olive of the contra-lateral side (see Fig. 20.)

Another important cerebello-petal path from the spinal cord is the *ventral cerebellar tract* of Gowers, which has a long course within the medulla and pons, traversing them from below upwards and ultimately hooking downwards again, to enter the cerebellum from above, through the superior peduncle.

Cerebello-petal fibres from the frontal, parietal, and, above all, the temporal lobe of the cerebrum, run downwards through the *superior peduncle* in a cortico-pontile path to the pontine nuclei (formatio reticularis) on the ipso-lateral side. From the cells of the pontine formatio reticularis new cerebello-petal fibres start again, constituting the *middle peduncle,* or transverse fibres of the pons, crossing the middle line and ending in the contra-lateral cerebellar cortex.

Other cerebello-petal fibres in the middle peduncle connect Deiters' nucleus (the lateral vestibular nucleus) with the vermis and the corresponding side of the cerebellar cortex in the region of the flocculus, conveying vestibular impulses to the cerebellum from the semicircular canals (see Fig. 30).

The **cerebello-fugal fibres** are derived, not from the cortex but from the intra-cerebellar nuclei, especially the dentate nuclei. The cerebello-fugal fibres of the superior peduncle, arising from the corpus dentatum (or nucleus lateralis) run upwards, ventral to the Sylvian aqueduct and corpora quadrigemina, crossing the middle line to the red nucleus in the crus cerebri of the contra-lateral side (Fig. 20). Starting again from this station, fibres run forwards along the anterior limb of the internal capsule, passing to the optic thalamus and frontal cortex. This constitutes a crossed cerebello-rubro-thalamic and a cerebello-rubro-frontal path.

A small number of cerebello-fugal fibres also run in the middle peduncle, from the corpus dentatum to the contra-lateral pontine nuclei (formatio reticularis), whence new fibres arise and, passing upwards through the crus cerebri and internal capsule, reach the frontal, temporal, and occipital cortex. From the *nucleus fastigii* (roof nucleus or nucleus medialis) the fastigio-bulbar tract, containing both crossed and uncrossed cerebello-fugal fibres, winds around the crus cerebri and reaches to the vestibular nucleus, also to Deiters' nucleus and to most of the sensory bulbar nuclei. The precise connections of the other intra-cerebellar nuclei (nuclei emboliformes and nucleus globosus) are not yet completely identified.

It should be particularly noted that there are no cerebello-fugal paths leading directly downwards to the spinal cord, but only indirect

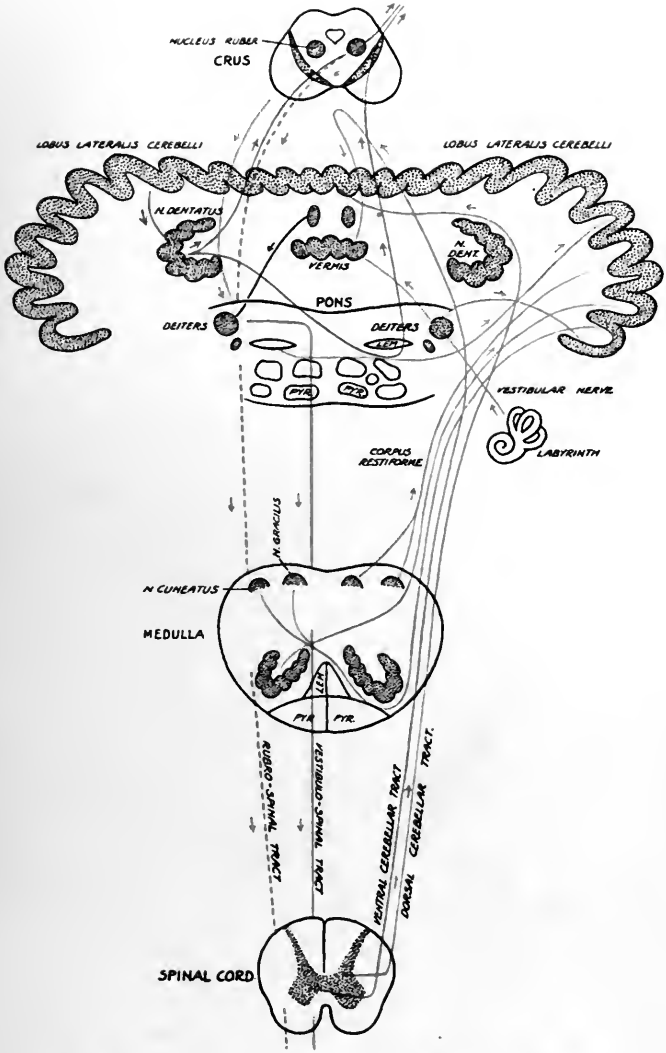

FIG. 20.—Cerebello-petal and cerebello-fugal paths.

To face page 20.

descending paths, one *viâ* the red nucleus and the rubro-spinal tract, and another *viâ* Deiters' nucleus and the vestibulo-spinal (Deitero-spinal) tract.

It will therefore be observed that, broadly speaking, each lateral half of the cerebellum is in connection (1) mainly with the cerebral hemisphere, thalamus, and pontine nuclei of the opposite or contra-lateral side, (2) with both sides of the medulla, and (3) with the same or ipso-lateral side of the spinal cord.

Thus the cerebellum receives impulses from various sources:—(1) from the cerebrum through the superior peduncles; (2) from the skin, joints, and muscles through the inferior peduncles; (3) from most of the cranial nerve nuclei through the middle peduncles; (4) and most important of all, from the semicircular canals, by the vestibular nerve and Deiters' nucleus. And in turn the intra-cerebellar nuclei send efferent impulses along the superior peduncles to the red nucleus, reinforcing the general muscular tonus and helping to co-ordinate voluntary motor impulses proceeding from the cerebrum.

In most voluntary movements the centre of gravity of the body requires to be altered and certain muscular groups have to co-ordinate to maintain equilibrium. For this purpose the tonus of these "anti-gravity" muscular groups has to be augmented, and this is accomplished by the cerebellum, the great centre for co-ordination and equilibration, partly by the action of its dentate, roof, and emboliform nuclei upon the red nuclei and cerebral motor cortex; partly by the influence of the nuclei of Deiters, *viâ* the descending vestibulo-spinal tracts, upon the spinal cord.

Whilst the cerebellum may be regarded as the organ for the sub-conscious synergic regulation of co-ordinated movements of the limbs and trunk, the functions of the cerebellar cortex differ essentially from those of the intra-cerebellar nuclei. Clark[1] and Horsley showed that although the cerebellum as a whole—comprising cortex and nuclei—responds to stimulation, the cerebellar cortex is relatively insensitive to electrical stimuli. On the other hand the subjacent intra-cerebellar nuclei, with their cerebello-fugal fibres, can readily be stimulated, giving rise to various characteristic movements. Nevertheless destruction of localised areas of the cerebellar cortex itself, as shown by the experimental researches of v. Rynbeck, Rothmann, and others, demonstrates the existence of definite cortical co-ordination centres corresponding with various muscle-groups of the limbs, head, and trunks. The following co-ordination centres have been identified in the dog by means of localised extirpations:—

In the anterior lobe of the vermis there are centres for the muscles innervated by the motor cranial nerves (ocular, masticatory, facial, and tongue muscles), and in the anterior and posterior lunate lobules a centre for the neck muscles. Both of these centres are close to the middle line. In the lateral lobe there is a centre for the muscles of the

[1] *Brain*, 1903, p. 45.

ipso-lateral limbs, the upper limb being farther forward (in the lunate lobule), the lower limb more posteriorly (in the lobulus semilunaris superior). In the upper portion of the posterior median lobule (inferior vermis) is a centre for the muscles of the limbs of both sides, whilst the remainder of the cerebellar cortex corresponds to the trunk muscles.

These views have also been supported by Bárány's observations on the human brain. Bárány, by the temporary freezing of small areas of cerebellar cortex, exposed in man during operation, produces transient and localised loss of function in these areas. To identify them clinically he employs what we may call the "target" or **pointing tests.** A normal individual, with closed eyes, can, with any of his limbs, come back accurately to a given mark. Nevertheless, even in him we can produce an artificial vestibular deviation or mis-pointing ("vorbei-zeigen") of all the limbs by inducing vestibular nystagmus. (See later, Vestibular Ataxia.) In localised disease of the cerebellar cortex, however, without provoking any artificial vestibular nystagmus, we have a *spontaneous* "vorbei-zeigen" or mis-pointing. This is present only in the ipso-lateral limbs and in a special direction in each case, corresponding with the area of cerebellar cortex affected.

Bárány maintains the existence in each cerebellar hemisphere of four cortical centres for muscular tonus in the ipso-lateral limbs, viz. for movements outwards, inwards, upwards, and downwards. Thus in the right cerebellar hemisphere the centre for movement of the right arm to the right (*outward tonus*) is believed by Bárány to be near the outer edge of the lateral lobe at the back (in the region of the superior and inferior lobules). When this centre is paralysed, the intact centre in the opposite side of the cerebellum is unopposed and there is failure of outward tonus in the right arm only; with that limb therefore the patient shows spontaneous "vorbei-zeigen" or mis-pointing towards the left. The centre for movement of the right arm towards the left (*inward tonus*) whose paralysis produces spontaneous "vorbei-zeigen" of the arm outwards, towards the right, is on the anterior aspect of the right lateral lobe, in the region of the biventral lobule, *i.e.* close behind the bony labyrinth itself. The centre for *downward tonus* of the upper limb is near the postero-mesial end of the superior and inferior semilunar lobules. Paralysis of this centre produces spontaneous mis-pointing of the ipso-lateral arm upwards. The position of the centre for *upward tonus* of the upper limb is not yet determined. Similar centres also exist for the lower limbs, of which that for inward tonus has been identified on the outer surface of the cerebellar hemisphere, behind the inward tonus arm-centre. The foregoing phenomena are best seen in recent or acute lesions. In old-

standing lesions they are less distinct, probably owing to compensation by the cerebrum.

Further, in cortical cerebellar lesions, in addition to the spontaneous mis-pointing above described, we observe *loss of the normal vestibular deviation* in the ipso-lateral limb, when we induce a vestibular nystagmus (see later, p. 130).

Experimental destruction of the right half of the cerebellum by leaving unopposed the tonic action of the other half, causes the animal to rotate around its own long axis in the direction of screwing in a screw (the animal's head representing the head of the screw). Together with this rotatory lurching, there is *asynergia* of the ipso-lateral arm and leg, together with various ocular phenomena, including *nystagmus* owing to interruption of cerebellar control over the ocular nuclei through Deiters' nucleus.

Destruction of the anterior part of the vermis causes the animal to fall forwards, whilst if the posterior part of the vermis be destroyed the animal tends to fall backwards.

The results of cerebellar stimulation are somewhat difficult to interpret, owing to the relatively high excitability of the sub-cortical nuclei as compared with the cerebellar cortex, and partly also to the difficulty of being sure that a stimulus, even when reaching a particular nucleus, is confined to it and not diffused into adjacent tracts. Horsley and Clark,[1] however, describe stimulation of the upper part of the nucleus dentatus as producing deviation of the eyes and head towards the ipso-lateral side. Stimulation of the basal portion of the nucleus dentatus, and of the upper portion of the para-cerebellar nuclei on the same side, produces flexion of the ipso-lateral elbow; whilst stimulation of the para-cerebellar nuclei alone produces tonic extension of the contra-lateral elbow with hyper-extension of the neck and head and extension of both legs, a condition which closely resembles certain so-called "cerebellar fits" in man.

Luciani, on experimental grounds, considered asthenia and muscular atonia as essential symptoms of cerebellar disease.

As regards cerebellar *asthenia*, clinical observations in the earlier stages of cases of extensive injury to the cerebellum, *e.g.* after bullet-wounds, show a moderate diminution of power in the ipso-lateral limbs, together with slowness in voluntary muscular contractions and relaxations.[2] This form of weakness is unlike the true paralysis or paresis due to lesions of the pyramidal tract, inasmuch as the static strength of the limb (*i.e.* the power of voluntary resistance to forcible passive displacements) is undiminished in cerebellar asthenia. Moreover, in cerebellar asthenia, although all voluntary movements of the

[1] *Brain*, 1908, p. 45.
[2] Gordon Holmes, *Brain*, 1917, vol. xl., p. 461.

limb are weak, none are limited in range; there is an absence of the characteristic changes in the reflexes; and there is no tendency to the development of rigidity or contractures.

As to cerebellar *atonia* or *hypotonia*, one of the most characteristic signs, this consists of loss or diminution of tone in the affected muscles on the ipso-lateral side. This is best seen in recent and acute cerebellar lesions. It is recognised by the presence of abnormal muscular flaccidity and by the readiness with which the affected limbs may be passively placed in abnormal postures. Thus if the affected limb be passively shaken, its distal segments flop about, inertly, in a flail-like fashion; or if both forearms are passively held up in a vertical position, the wrist on the affected side falls passively into a posture of extreme flexion, whereas on the normal side the wrist does not become more than semi-flexed, owing to the normal tone of the extensor muscles. In old-standing lesions this atonia or hypotonia disappears.

Cerebellar catalepsy or excessive static equilibrium, originally described by Babinski, consists in the fact that the cerebellar patient can maintain his limbs immobile in certain fixed positions with greater steadiness than a normal individual. This is best demonstrated by making the patient lie on his back with the hips and knees flexed and then asking him to raise his feet from the couch and hold them in the air without touching each other. During the process of assuming this posture, the limbs and trunk show an initial hypermetria and asynergia, but in a few moments the limbs become immobile and remain fixed, without fatigue, for a number of minutes, showing none of the oscillations observed in healthy persons. In chronic unilateral cerebellar disease the outstretched upper limb on the ipso-lateral side is often steadier than on the healthy side.

The **pituitary gland** is a small oval body whose longest diameter lies transversely. It occupies the sella turcica of the sphenoid bone, being enclosed within a special covering of dura mater, and is connected with the floor of the third ventricle by a narrow, hollow stalk —the infundibulum, which leads upwards through a special aperture in the dura. The pituitary gland consists of two lobes, serving different functions:—(1) a larger *anterior lobe*, purely epithelial and glandular in structure and containing many chromophile cells of active, secreting nature; (2) a smaller *posterior lobe* which is subdivided into a *pars intermedia*, epithelial in structure, but without chromophile cells, and a *pars nervosa*, the continuation of the infundibulum, and consisting of ependymal and neuroglial cells. The pars nervosa is developed by outgrowth from the primitive brain, whereas the pars intermedia and anterior lobe are developed as a backward diverticulum from the primitive ectoderm of the pharynx. In fact, a small longitudinal

patch of pituitary tissue often persists in the submucous tissue of the pharyngeal roof, outside the cranial cavity.[1]

The secretion of the anterior lobe ("tethelin"), an internal secretion which is related to the general growth of the body and especially of the skeleton, enters the blood-stream of the venous sinuses around the gland.

The secretion of the posterior lobe, comprising pars intermedia and pars nervosa, is of a colloid character. It passes directly between the ependymal cells into the cerebro-spinal fluid of the third ventricle, and thence enters the blood-stream, *viâ* the dural sinuses. This secretion of the posterior lobe has a marked effect in raising the general vascular pressure, in producing contraction in all varieties of non-striped muscle (*e.g.* uterus, bladder, intestine, etc.), and also acts as a powerful diuretic and galactogogue. Experimental removal of a portion of the pituitary (total removal is fatal) produces a remarkable effect upon the metabolism of sugar, causing an increased power of retaining sugar in the body. In a normal person, if more than a certain amount of glucose (about 100 grammes) be taken at a dose, some of it will overflow in the urine, producing a temporary glycosuria. But if the posterior lobe of the pituitary body be destroyed, far larger doses can be taken without causing overflow glycosuria.

The pituitary gland undergoes temporary enlargement during pregnancy, chiefly owing to an increase in the chromophile cells of its anterior lobe. This enlargement may even produce bi-temporal hemianopia in pregnant women by pressure on the optic chiasma; transient acromegaly has also been described,[2] whilst glycosuria has been frequently noted, probably resulting from hyper-activity of the posterior lobe.

The **pineal gland** (conarium or epiphysis cerebri) is a small oval body lying mesially in the depression on the dorsal aspect of the superior corpora quadrigemina. It possesses a small cavity, continuous anteriorly with the third ventricle. Involution of the gland begins normally in childhood at about the age of seven years, and is complete at puberty. In the adult brain the gland has already undergone secondary calcareous degeneration, and particles of "brain-sand" are scattered throughout its substance.

The pineal gland was formerly regarded mainly as a "vestigial" organ, a portion of which, in some reptiles, develops into a rudimentary pineal or parietal eye. More recent observations[3], however, show

[1] Civalleri, *Giornale dell'Accademia di Torino*, 1907. Haberfeld, *Ziegler's Beiträge zür path. Anat.*, 1909, xliv.

[2] Marek, *Gynäk. Centralblatt*, 1911, s. 1612.

[3] Münzer, *Berlin. Klin. Wochensch.*, 1911, No. 37. Kidd, *Rev. of Neurol. and Psych.*, 1913, pp. 1 and 55.

that, so far from being a mere vestigial organ, it is a glandular structure whose activity is necessary for normal metabolism in early life, and that prior to the age of puberty at least, the pineal gland is an impotrant organ of internal secretion.

The pineal secretion has a profound influence upon growth and upon certain trophic functions. It inhibits development of the genital glands. Increased secretion, *super-pinealism*, causes excessive adiposity and retards the onset of puberty, whereas diminished secretion, *sub-pinealism* (as in certain teratomata of the gland occurring during childhood), causes precocious and abnormal development of the male genital organs and also of secondary sexual characteristics.

CHAPTER II

ANATOMY AND PHYSIOLOGY (*continued*)

HAVING considered the chief motor and sensory tracts within the central nervous system, let us now pass to the peripheral paths whereby the central nervous system is connected with the various end-organs.

Firstly, as to the motor system. Motor fibres starting in the cortex, and passing down the pyramidal tract, as already described, reach the nuclei of the various motor cranial nerves in the crura, pons, and medulla. Then, passing along the spinal cord, the pyramidal tract gives off fibres to the anterior cornua at various levels all the way down. This portion of the motor tract, from the motor cortex to the extremity of the pyramidal fibres, is called the **upper motor neurone**, and if the cortical motor cell or its axon, the pyramidal motor fibre, be destroyed, we have degeneration of the whole length of the pyramidal fibre below the level of the lesion, stopping short when it reaches the anterior cornual cell. This so-called "descending degeneration" does not, as the name might suggest, begin at the lesion and spread downwards, but affects simultaneously the whole motor fibre below the lesion, on the side remote from the nerve-cell which is its trophic centre.

From each anterior cornual cell a new motor fibre passes out of the cord along an anterior nerve-root, enters into the formation of a peripheral motor nerve, and thereby is conducted to a muscle-fibre. This lower segment of the motor path, starting at the anterior cornual cell and ending in the muscle-fibre, is called the **lower motor neurone.** Here also, if the anterior cornual cell or its axon, the peripheral motor nerve, be destroyed, we again have a "descending degeneration" of the whole fibre on the distal side of the point of injury, and of the muscle-fibre also. We note that degeneration of the upper motor neurone does not spread into the lower neurone, nor *vice versâ*. It is particularly to be remembered that a lesion of the upper motor neurone leaves the lower reflex arc intact, whilst a lesion of the lower motor neurone not only severs the reflex arc, but also causes the muscle-fibre in that reflex arc to degenerate and waste away.

Therefore in diagnosing the position of the lesion, in any given case of motor paralysis due to organic disease, the first question we

must ask ourselves is whether the lesion is in the upper (cortico-spinal) or in the lower (spino-muscular) motor neurone. There is usually little difficulty in answering this question, if we bear the following points in mind:—

Lesion of Upper (Cortico-Spinal) Motor Neurone.	**Lesion of Lower (Spino-Muscular) Motor Neurone.**
1. Motor Paralysis.	1. Motor Paralysis.
2. Spasticity.	2. Flaccidity.
3. No muscular wasting (apart from disuse).	3. Muscular Atrophy.
4. Electrical reactions normal.	4. R.D. (reactions of degeneration).
5. Deep reflexes present and often increased.	5. Deep reflexes absent or diminished.
6. Extensor plantar reflex (if leg affected).	6. Plantar reflex, if present, of normal flexor type (unless lesion paralyses flexor muscles themselves).

Having thus recognised which motor neurone, upper or lower, is affected, we have then to decide at what level in the affected neurone the lesion is situated. To that point we shall come later.

Returning for a moment to the sensory fibres; these may also be regarded as arranged in **sensory neurones.** The lowest sensory neurone starts from a sensory end-organ, in the skin or elsewhere, and extends up to the nerve-cell in the intervertebral ganglion on the posterior spinal root. This ganglion-cell is the trophic centre for the peripheral sensory fibre, and a lesion at or below this cell will cause "descending degeneration" of the distal segment of the fibre and of the peripheral end-organ. There is, however, one sensory end-organ, the muscle-spindle, which is an exception to this rule, and does not degenerate when the afferent fibre leading from it to the ganglion-cell is destroyed. The muscle-spindle thus has its trophic centre within itself.

But the ganglion-cell of the posterior root is also the trophic centre for the fibre which passes upwards from it along the posterior root and enters the posterior column of the spinal cord. And therefore a lesion at or above the intervertebral ganglion-cell, in the posterior root, or in its intra-spinal prolongation in the posterior column, will cause an "ascending degeneration" of the fibre through its whole course within the spinal cord. Here again this so-called "ascending" degeneration occurs simultaneously throughout the entire extent of the nerve-fibre, on the side remote from its trophic centre in the intervertebral ganglion; and this degeneration extends as far as, but does not implicate, the next nerve-cell whose axon leads upwards towards

the brain. Similarly a lesion of this second sensory neurone causes ascending degeneration in the fibre of the fillet above, as far as, but not including, the optic thalamus. There a third neurone starts, leading up to the sensory area of the cerebral cortex. In the case of the ordinary sensory tract, the path traverses the internal capsule.

In the case of an impulse which traverses the cerebellum, the chain of successive neurones is more complex, and consists of (1) a posterior-root neurone, (2) an ascending spino-cerebellar neurone, (3) a cere-

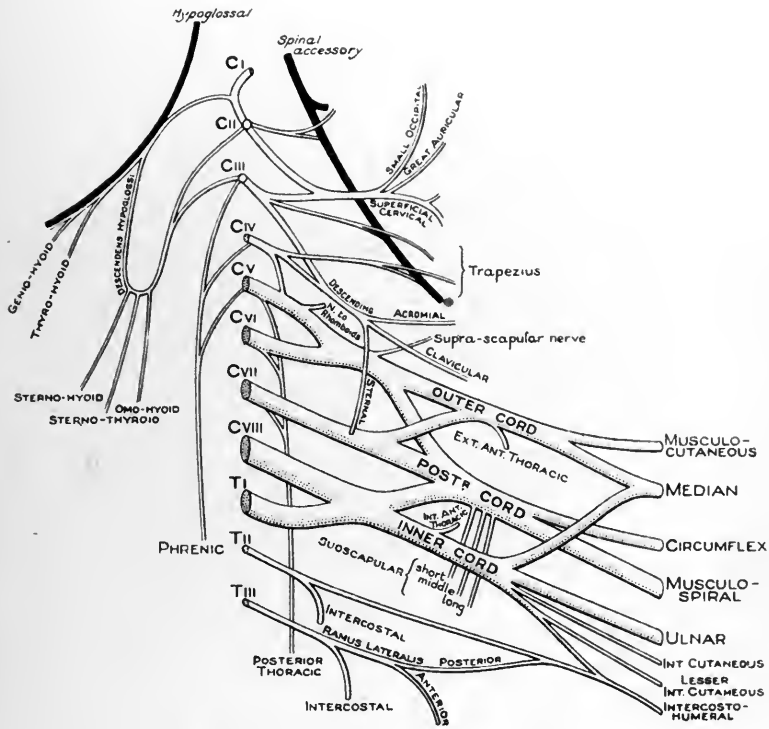

Fig. 21.—The Cervico-brachial plexus and its branches.

bello-dentate, (4) a dentato-thalamic, and (5) a thalamo-cortical neurone.

The so-called "Wallerian degeneration"—"ascending" or "descending" as the case may be—signifies that a nerve-fibre separated from its trophic cell, degenerates on the side remote from that cell. It should also be remembered that after lesions of a cranial or spinal nerve, especially in a young animal, marked chromatolytic changes are produced in the nerve-cells of the corresponding motor nucleus in the bulb or spinal cord.

The anterior and posterior nerve-roots join to form mixed nerve-trunks. These again branch and intermingle to form plexuses in the cervical lumbar, and sacral regions. The distribution of the different nerves, motor and sensory, is represented in Figs. 21, 22, and 23.

Root Lesions.—But what is perhaps less familiar, though of equal diagnostic importance, is the distribution of the anterior and posterior spinal roots. In lesions of the lower motor neurone, we have often to decide whether the distribution of symptoms points to a lesion of a peripheral nerve-trunk, such as the musculo-spiral or sciatic, or whether it points to a lesion of one or more nerve-roots before they have joined to form the trunks of a plexus. Thus, for example, the deltoid is frequently paralysed alone owing to a lesion of the circumflex nerve, but it is never paralysed alone as a result of a lesion of the anterior cornu or anterior nerve-root. Again, a lesion of the musculo-spiral nerve may produce paralysis both of the supinator longus and of the extensors of the wrist and fingers, but these muscles are never affected together by a lesion of a single segment of the spinal cord or of a single anterior root, since their motor cells lie at different levels in the anterior cornu. This will be readily seen on studying the tables on p. 35, which show the nuclear representation of muscles in the anterior cornua at various levels of the spinal cord. For clinical purposes, the distribution of each anterior root may be considered to be the same as that of the spinal segment from which it arises.

In connection with the root distribution of sensory and motor fibres, it is interesting to note that in each embryonic segment or metamere, the muscular territory (myotome) of the segment corresponds more or less closely with the cutaneous distribution (dermatome) and with a zone of the bony skeleton (sclerotome). In the trunk this segmental or metameric arrangement is comparatively easy to recognise, especially in the thorax; and even in the limbs a similar arrangement, though more complex, can be made out. Thus, as Bolk has shown, in the limbs there is for every spinal segment a corresponding dermatome, myotome, and sclerotome, but they are subdivided into a pre-axial and a post-axial division in each case (see Fig. 24).

We observe that comparatively few muscles are confined to a single segment, but that most of them are represented in two or more segments. If, therefore, a cord lesion be limited to one segment, it will cause complete paralysis of the muscles confined to that particular segment and partial paralysis of muscles whose motor nuclei extend up or down into other segments. This explains the apparent irregularity in the distribution and degree of paralysis in certain cases of infantile paralysis and other diseases of the anterior horns.

Similarly in a case of cutaneous anæsthesia it is important to dis-

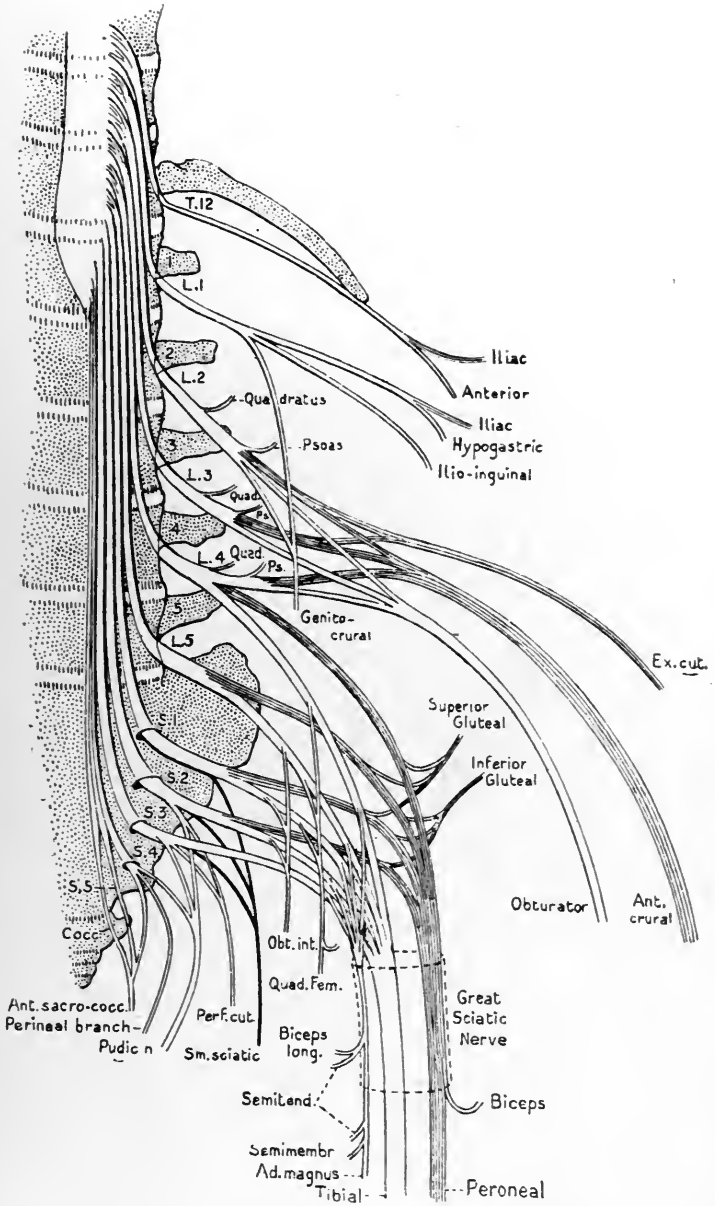

FIG. 22.—The Lumbo-sacral plexus and its branches.

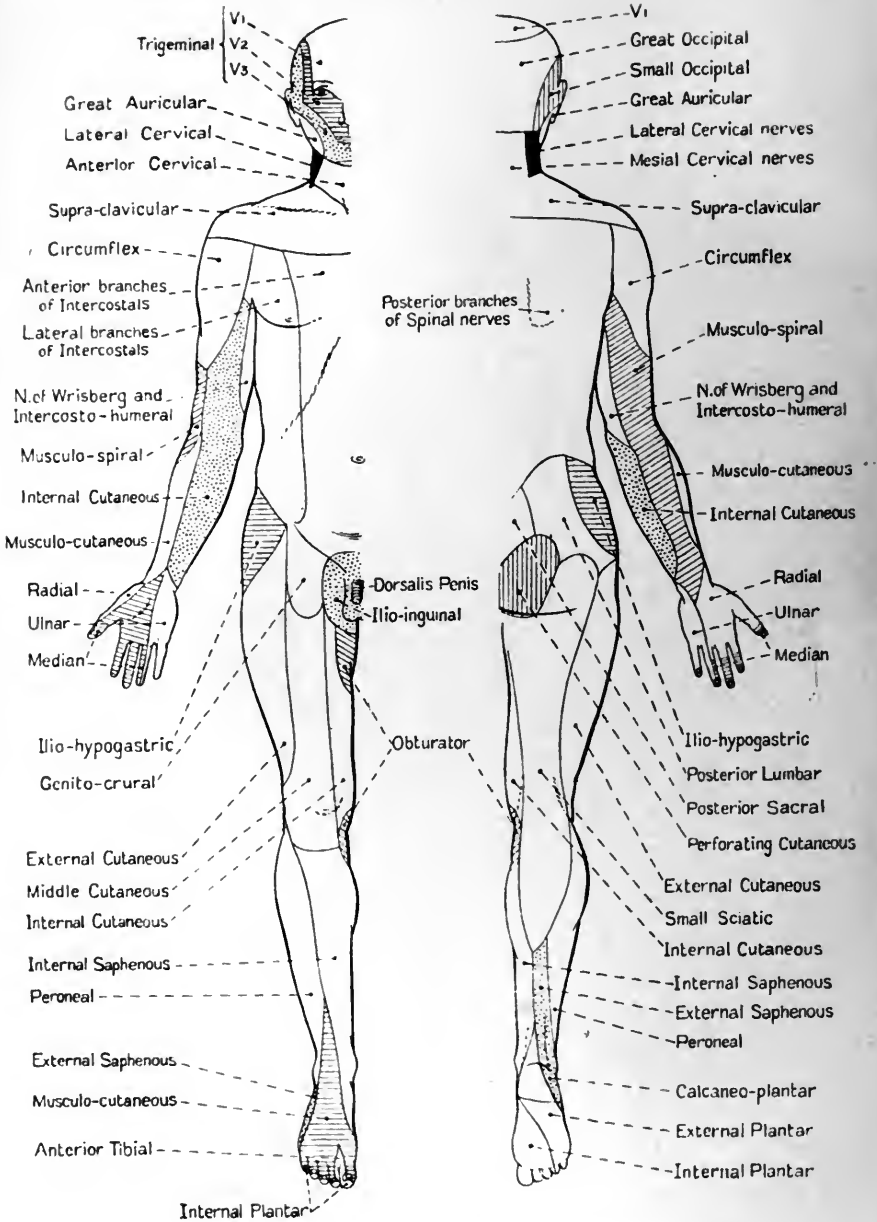

FIG. 23.—Diagram of cutaneous areas of peripheral nerves.

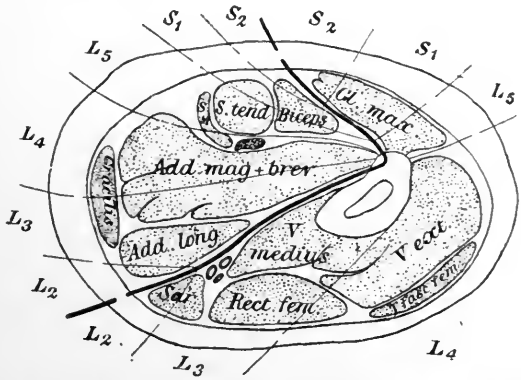

FIG. 24.—Transverse section through upper third of thigh. The thick black line indicates the boundary between the pre-axial and post-axial regions of the limb. The fine black lines mark the segmental distribution. (After Bolk.)

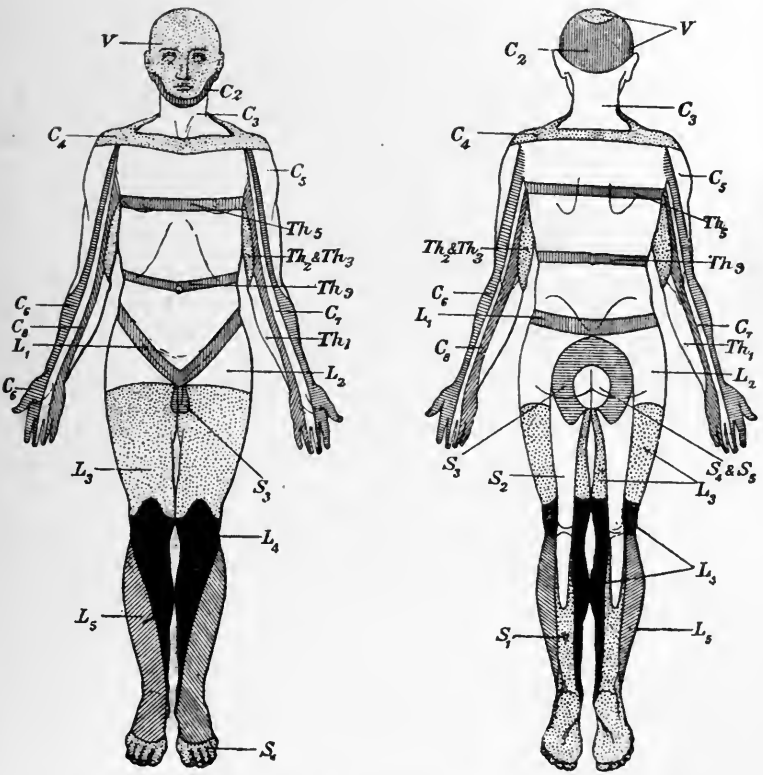

FIG. 25.—Diagram of cutaneous areas of posterior roots. (After Collier and Purves Stewart.)

tinguish between a posterior-root lesion and a lesion of a peripheral nerve-trunk such as the radial or ulnar. The distribution of the posterior nerve-roots is indicated diagrammatically in Figs. 25 and 26.

It is sometimes difficult for the student to remember the arrangement of these cutaneous root-areas. In the trunk they run mainly horizontally, whereas in the upper limbs they run longitudinally, parallel to the axis of the limb, whilst in the lower limbs, anteriorly, they run from above downwards, and posteriorly, from below upwards. Finally the genital organs, innervated by the third and fourth sacral roots, are suspended, as it were, amongst strangers, viz. in the neighbourhood of the second and third lumbar areas (see Fig. 25).

The teaching of these areas can be simplified as follows:—Let us regard the body as a long cylinder, beginning above at the head (innervated by the trigeminal nerve), and ending below at the coccyx. If this body had no limbs, everything would be easy, and we might represent the various root-areas as a series of horizontal dermatomes running

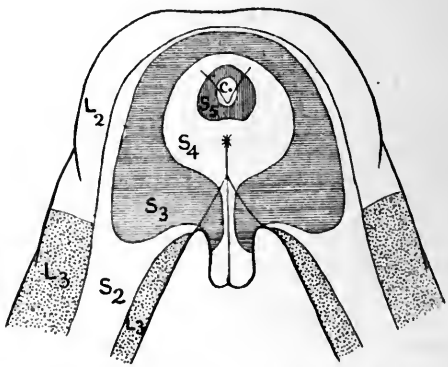

Fig. 26.—Sacro-coccygeal root-areas.

from above downwards, with the nose and mouth in the trigeminal area, the nipples at the junction of the fifth and sixth thoracic, the umbilicus at the junction of the ninth and tenth thoracic, and the anus within the fourth sacral area (Fig. 27A). The upper extremities, growing outwards horizontally from the trunk in the cervico-thoracic region, carry with them the corresponding root-areas, which run in long strips parallel to the long axis of the limbs, the thumbs being directed upwards (Fig. 27B). In the fully developed condition these areas on the trunk are reduced to a mere line, so that the fourth cervical segment comes to touch the third thoracic segment.

The lower limbs may also be represented as horizontal outgrowths in the lumbo-sacral region, being strongly rotated from within outwards, so as to place the great toes uppermost. In this position the cutaneous root-areas run from above downwards, the pre-axial roots running along the anterior aspect and the post-axial roots along the posterior aspect, always from above downwards. It is essential in this scheme to retain a small projecting tail with the lower sacro-coccygeal root-areas. In the fully developed condition this tail, of course, is embedded in the

C1	C2	C3	C4	C5	C6	C7	C8	Th1	
Ster Om Thy Gen Di	no-hyoi o-hyoi ro-hyoi lo-hyoi -gastric Tra	deus deus deus dens us peziu s Levat. An	guli Scap. aphrag ma Scale ni Rhom boidei Serratus		magnus	MUSCULAR LOCALISATION IN CERVICAL ENLARGEMENT			
				Pectoralis (cl Supra-Spinat. Infra- Subs Ter	avicular) Spinatus capularis es minor	Pectoralis (sternal) Latiss. dorsi Pector	alis minor		SHOULDER
			D eltoideu s Biceps brac hii Brachialis Ant icus Supinator lo ngus		Triceps b	rachii			ARM
					Flexors & Extensors of Wrist Pronato	rs Flexors and Extensors of Fingers			FOREARM
							Interossei & Thenar & H	Lumbricales ypothenar	HAND

Th12	L1	L2	L3	L4	L5	S1	S2	S3	S4	
Quadr	atus Lum Crema	borum ter								
		P s o a Ilia	s cus							HIP
				Tensor	fasciæ					
				Gl	uteus med	ius				
				Gl	uteus mini	mus				
				Qu	adratus fem	oris				
					Geme	lli				
					G l u t e u s	m a x i m	us			
					Ob	turator inte	rnus			
		Pectin Addu G A	eus tor longus r a c i l i dductor bre	s vis						THIGH
			Sartor	ius						
			Obturator	externus						
			Quadriceps	extensor						
			Add	uctor mag	nus					
				Se	mi-mem	b r a n o s	us			
					Se	mi-tendin	osus			
				Bic	eps femor	is				
				Tibialis A	uticus					
				Extensor pro	p. hallucis					
				Extensor l	ongus digit	orum				
					Ga	strocnemi	us			LEG
					S	o l e u	s			
					Pl	antaris				
					Po	pliteus				
					Peroneu	s lougus				
						Peron. brev.				
					Tibiali	s posticus				
					Flex. lo	ng. digitorum				
					Flex.	long. hallue.				
MUSCULAR LOCALISATION IN LUMBO-SACRAL CORD					Extens.	brev. digitor.				FOOT
					Ab	ductor hallu	ei			
						Flex. brev. hal	luc.			
						Lumbric	ales			
						Inteross	ei			
						Sphincter An	i exter.			
							Le	vator	Anl	
							Per	ineal	Muscles	

posterior wall of the anus. Finally, the genital organs, innervated by the third and fourth sacral roots, are inclined forwards.

Plate I. is from a coloured model, constructed according to the foregoing scheme, in which the various root-areas are coloured in series, according to the order of the tints in the spectrum.[1] Thus red = No. 1, orange = No. 2, yellow = No. 3, green = No. 4, blue = No. 5, indigo = No. 6, violet = No. 7, and brown = No. 8. Nos. 9 to 12 are indicated by paler shades of blue, indigo, violet, and brown respectively. Lastly, on one side of the model we have also indicated the areas of distribution of the various peripheral nerves, for purposes of comparison.

Paths of Special Senses—Olfactory Path.—The olfactory nerves, starting from a small area of nasal mucous membrane on the superior

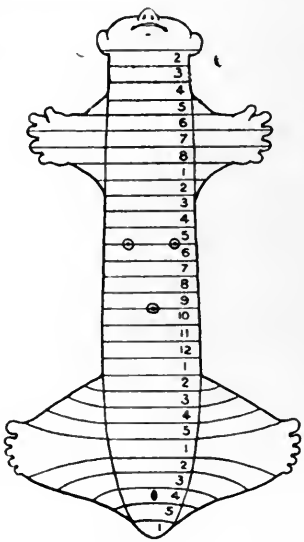

Fig. 27A.

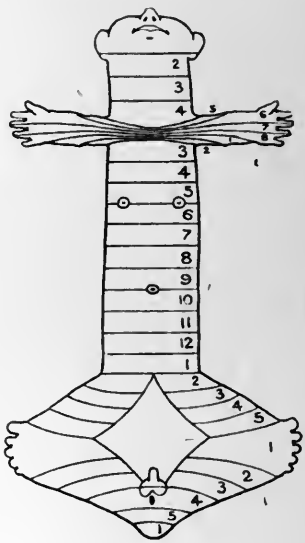

Fig. 27B.

turbinal body and the corresponding uppermost part of the nasal septum, perforate the cribriform plate of the ethmoid bone in numerous small filaments and reach the lower olfactory centre within the olfactory bulb. The central olfactory tract has various connections, not of great clinical importance, leading to the optic thalamus and to other sub-cortical ganglia. These paths connect the olfactory bulb with the cortical centre for smell, situated, as we have already seen, in the uncinate gyrus at the tip of the temporo-sphenoidal lobe (Fig. 4). The olfactory tract does not traverse the internal capsule. Each olfactory bulb is connected not only with the uncinate gyrus of the

[1] This papier-maché model is manufactured by the Tynecastle Co., 1, Berners Street, London, W. 1.

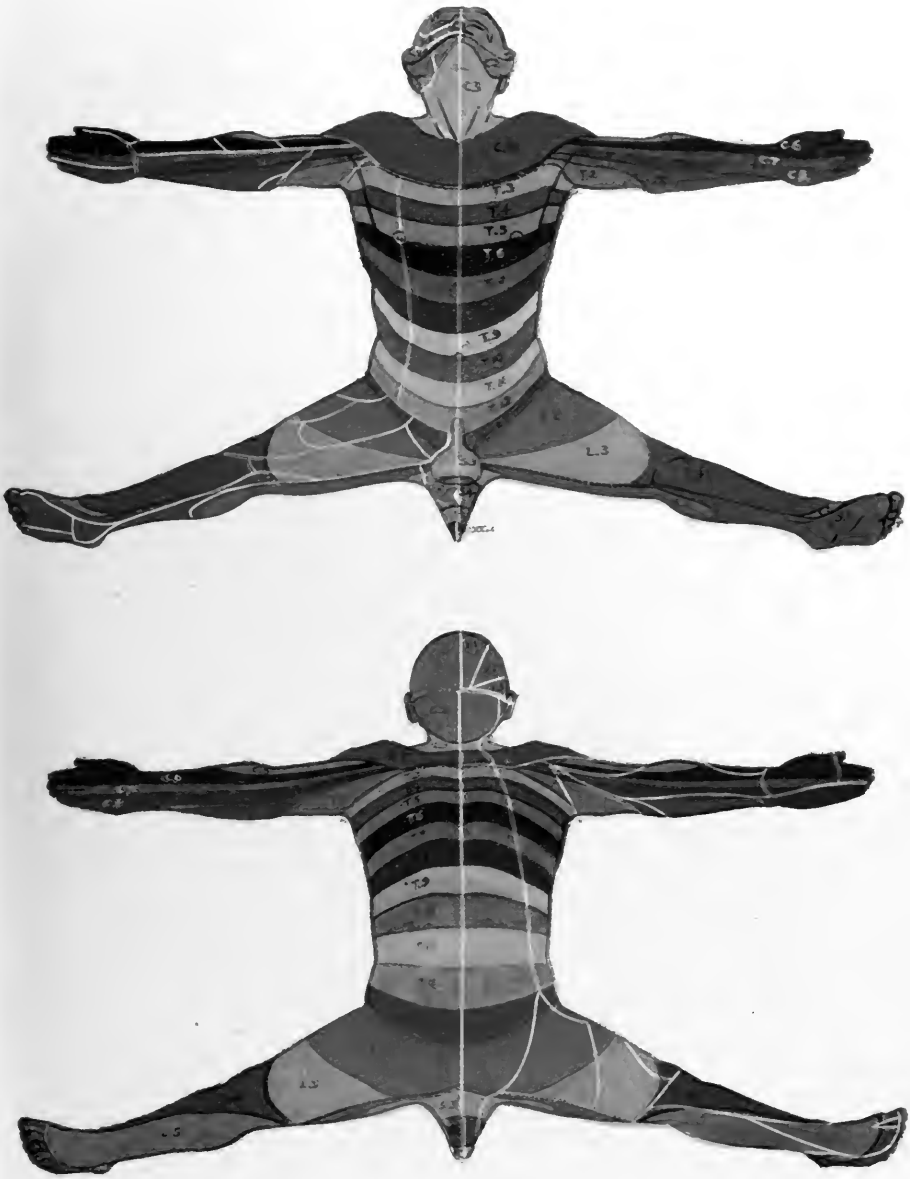

COLOURED MODEL, SHOWING CUTANEOUS ROOT-AREAS.

Peripheral-Nerve Areas are indicated, by white lines, on the right half of the model.

To face page 36.

same side, but also, through the anterior commissure, with that of the opposite side (see Fig. 28).

Visual Path.—This is of great clinical importance. Starting from the retina, the visual fibres run backwards along the optic nerve. At the optic chiasma there is a partial decussation, so that the fibres from the left halves of both retinæ (corresponding to the right halves of the visual fields) run together in the left optic tract, and *vice versâ*. The central visual impulses, from each macula lutea, do not pass into both optic tracts, as was formerly thought, but each optic tract carries fibres from the ipso-lateral half of the retina, including the corresponding half of the macula. The fibres of each optic tract run

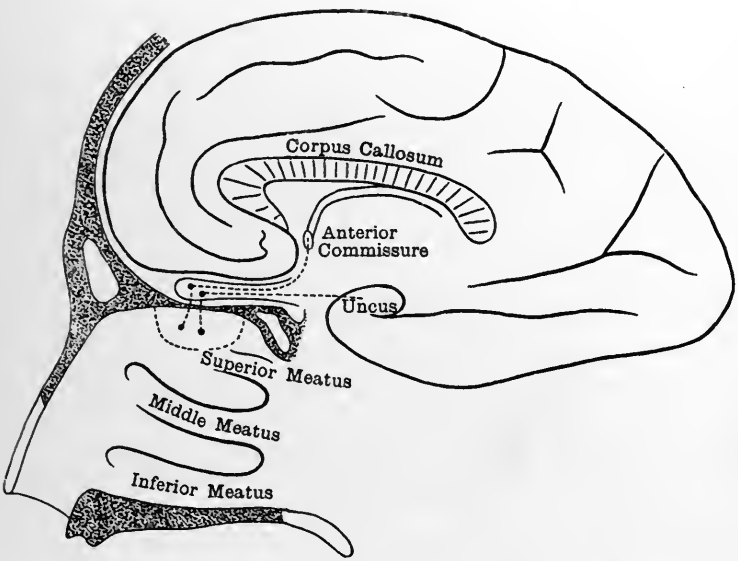

Fig. 28.—Diagram of connections of olfactory nerves.

backwards, winding around the other side of the crus cerebri, to the *primary optic centres*, viz. the postero-dorsal part of the optic thalamus (a station en route towards the cortical visual path), the external geniculate body and the anterior corpus quadrigeminum (reflex centres for ocular movements and for accommodation of the eyes, effected by connections with the ocular nuclei in the floor of the aqueduct).

From these three stations new fibres arise, forming the "*optic radiation*," passing through the internal capsule behind the fibres for common sensation (Fig. 7) and so reaching the cortical half-vision centre. This centre, mainly on the mesial aspect of the hemisphere, is divided into an upper and a lower part by the calcarine fissure (Fig. 4). Above the fissure is the cuneate lobe, below it is the lingual

gyrus. The half-vision centre also extends on to the convexity of the occipital lobe at its posterior extremity (Fig. 3). The calcarine fissure forms a boundary-line between the cortical representations of the upper and lower quadrants of the corresponding half of the visual field. Therefore a lesion of the left occipital lobe, or of the whole of the left cuneus and lingual gyrus, or of the fibres of the left optic radiation, will cause a right-sided hemianopia in both visual fields; a lesion of the the left cuneus, *i.e.* limited to the part *above* the calcarine fissure, will cause blindness of the *right lower quadrant* of both visual fields; whilst if the lesion be *below* the left calcarine fissure, in the lingual gyrus, it will produce blindness of the *right upper quadrant* of both fields. These are varieties of " quadrantic hemianopia."

The macular region of the retina is represented in the cortex at the extreme posterior pole of the occipital lobe; a superficial lesion in this region will produce a macular (or minute central) hemi-scotoma in both visual fields. If the lesion is deeper, the scotoma is somewhat larger, being both macular and para-macular.

The serial concentric zones of the retina, from macula to periphery, are represented in regular order, from behind forwards, in the calcarine cortex. Thus a lesion confined to the anterior part of the calcarine cortex will produce a peripheral scotoma, hemianopic in type, strictly symmetrical in both visual fields.

A lesion of the upper lip of both calcarine fissures produces a *horizontal hemianopia inferior*, with blindness of the lower half of both visual fields. Such a lesion is not uncommon from war-injuries. *Horizontal hemianopia superior*, on the other hand, is very rarely observed, since any traumatic lesion of the lower lip of both calcarine fissures is almost certain to damage not only the cerebellum but the straight sinus and the lateral sinuses, and is therefore almost invariably fatal.

An interesting point about horizontal hemianopia inferior is that the boundary between the upper, seeing half, and the lower, blind half, of the fields is not exactly horizontal (unlike lateral hemianopia, in which the boundary is usually accurately in the vertical meridian). This is probably due to the fact that the lesion is rarely limited exactly to the upper lip of the calcarine fissure.

Appreciation of the movement of an object is sometimes present in a blind part of the visual field when a stationary object is not recognised. In a recovering hemianopia, recovery of vision for a moving object precedes recovery of vision for a stationary object and this dissociated improvement often begins in the peripheral part of the visual field.[1]

[1] Riddoch, *Brain*, 1917, vol. xl., p. 15.

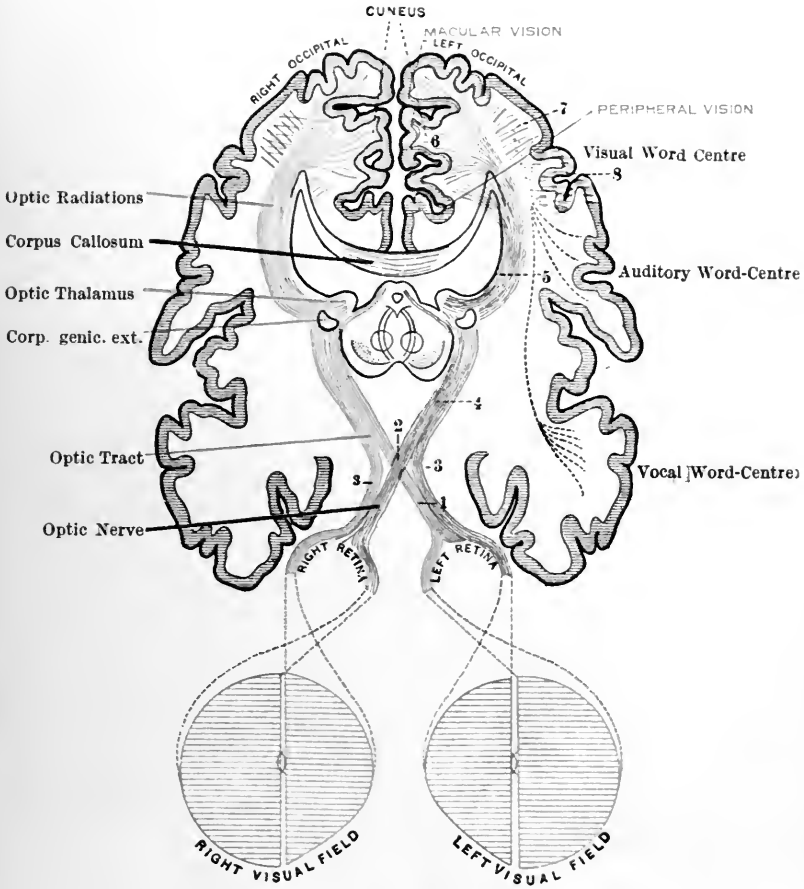

FIG. 29.—Diagram of Visual Paths (modified from Vialet).

Lesion at 1		produces	Blindness of one eye.
,,	,, 2	,,	Bi-temporal hemianopia.
,,	,, 3 and 3	,,	Bi-nasal hemianopia.
,,	,, 4	,,	R. hemianopia with hemiopic pupil reaction.
,,	,, 5	,,	,, with normal pupil reaction.
,,	,, 6	,,	,, ,, ,,
,,	,, 7	,,	Loss of visual orientation and localisation in space.
,,	,, 8	,,	Word-blindness.

To face page 38.

Lesions of the higher, psycho-visual cortex in the angular and supramarginal gyri cause a difficulty in recognising objects seen except those objects in the centre of the visual field.

In lesions of the lateral surfaces of the hemispheres, especially in the postero-parietal region, these higher psycho-visual functions may be alone affected, leaving visual sensibility intact. Such lesions produce loss of visual orientation and localisation in space, disturbance of the perception of depth and distance, loss of visual attention, and visual agnosia.[1]

There is also a hysterical phenomenon known as "crossed amblyopia." This means a concentric contraction of both visual fields, more marked in the contra-lateral eye.

Finally, in right-handed people there is in the left angular gyrus a centre for the storage of visual memories of written and printed speech. If this centre be destroyed, we have word-blindness, which may or may not be associated with right hemianopia, according as the subjacent optic radiations are affected or not. Fig. 29 indicates diagrammatically these various fibres and centres, and also shows the effects upon the visual fields of lesions in various parts of the visual path.

Gustatory Path.—The course of the taste-fibres outside the brain is somewhat complex, and we shall study it again later when we consider the cranial nerves. It is probable that some of the taste impulses, chiefly those from the front of the tongue, enter the brain through the sensory root of the fifth cranial nerve, some through the glosso-pharyngeal nerve, and some through the *nervus intermedius* or sensory root of the facial. The cortical centre for taste is in the front part of the temporal lobe, close to the olfactory centre (Fig. 4). The intra-cerebral course of the gustatory fibres is not definitely settled, but it is probable that they do not traverse the internal capsule.

Auditory Path.—This is of some practical importance (Fig. 30).

Entering the medulla in the cochlear nerve, the auditory fibres embrace the restiform body, some passing along its inner side to the ventral auditory nucleus, others passing along its outer side to the dorsal auditory nucleus. From these two nuclei new fibres pass upwards towards the cortex. A few run up uncrossed in the fillet of the same side, but most of the fibres decussate and ascend in the fillet of the opposite side. Some end in the posterior corpus quadrigeminum, others go directly to the thalamus, where they end in the corpus geniculatum mediale. Finally the bulk of them, passing through the sub-lenticular region of the internal capsule in the "auditory radiation" behind the sensory fibres, reach the cortical auditory centre in the superior temporal convolution (Fig. 3), and in the anterior transverse temporal convolution of Heschl:—Flechsig's "auditory gyrus"[2] (situated on the upper surface of the temporal lobe, at the bottom of the Sylvian fossa, immediately behind the insula), with which the superior temporal is continuous.

[1] Holmes, *Brit. Journ. of Ophthalm.*, 1918, p. 353.
[2] *Neurologisches Centralblatt*, 1908, p. 1.

We note that each cortical centre receives auditory messages from both ears, though more extensively from the ear of the opposite side, and that therefore a lesion limited to one temporal lobe will not cause deafness. In right-handed people there is a specially differentiated portion of the left auditory centre where memories of word-sounds are stored up (Fig. 3).

Vestibular Path.—This conveys impulses from the semicircular canals of the inner ear. These impulses conduct sensations of rotation

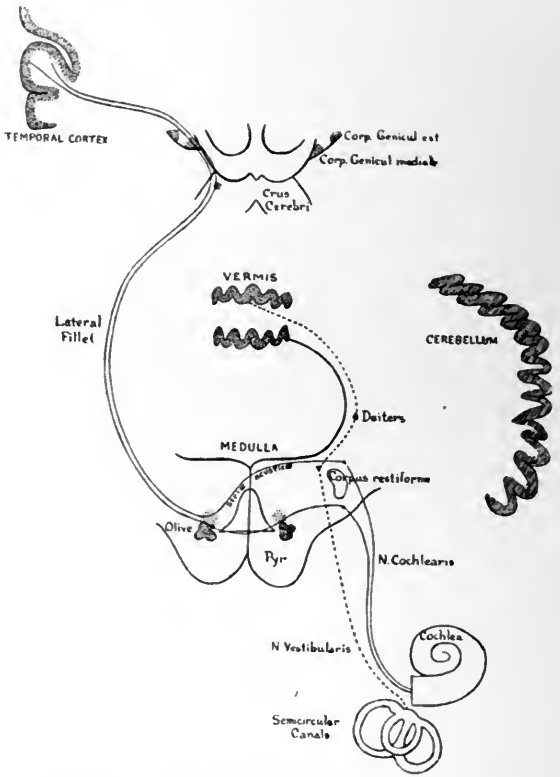

Fig. 30.—Diagram of connections of cochlear and vestibular nerves.

of the head in various planes, and are concerned chiefly with the maintenance of bodily equilibrium.

The fibres of the vestibular nerve, entering the brain-stem at the lower border of the pons, terminate in the vestibular nucleus beneath the floor of the fourth ventricle. This nucleus has several sub-divisions, of which the most important is the lateral vestibular nucleus of Deiters. Deiters' nucleus sends off various efferent tracts, including the vestibulo-spinal tract, running downwards into the spinal cord and serving to co-ordinate movements of the trunk and limbs in response to

stimulation of the semicircular canals. It also sends off another tract to the nuclei of the ocular muscles, whereby conjugate movements of the eyes are provided for, enabling one to keep the gaze fixed upon a stationary objectwhilst the head is moving.

It should be observed that there is no direct pathway leading upwards from the vestibular nucleus to the thalamus or cerebral cortex. Normally, therefore, equilibratory reactions excited from the semicircular canals are performed unconsciously.

There are, however, important afferent tracts leading from the vestibular apparatus to the cerebellum ; some from the vestibular nucleus, others directly by root-fibres of the vestibular nerve.

The cerebellum is the chief co-ordination centre for the reception of vestibular impulses. Normally none of its activities produce conscious sensation.

A certain amount of clinical evidence[1] supports the view that there is a special cortical centre associated with the sensations of **hunger** and **thirst.** It would appear to be in the temporal lobe, at or near the olfactory centre. Abscesses, injuries and tumours in this region have been associated with voracious appetite and intense thirst, persisting for weeks or months.

Arteries of the Brain.—Most cases of acute brain disease which we meet with in civil practice are the direct result of some vascular disease, *e.g.* hæmorrhage, thrombosis, or embolism. It is therefore important to understand certain facts about the cerebral circulation.

The brain is supplied by two pairs of arteries—the internal carotids and the vertebrals, as shown in Fig. 31. At the lower border of the pons, the two vertebral arteries join to form the *basilar* artery, which runs forwards in the mesial groove along the front of the pons, supplying perforating branches to the pons and arteries to the cerebellum. Between the crura cerebri the basilar divides into the two *posterior cerebral* arteries, each of which winds round the outer side of the crus supplying it as it passes, and also giving branches to the optic thalamus and the corpora quadrigemina. Finally it reaches and supplies the lower part of the temporo-occipital cortex (Figs. 32 and 33). Each posterior cerebral artery sends a posterior communicating artery forwards to join the internal carotid.

The internal carotid, close to its termination, gives off an important branch—the *anterior choroid* artery, which passes backwards to enter the descending horn of the lateral ventricle. The area supplied by the anterior choroid (see Figs. 32 and 33) includes the posterior two-thirds of the posterior limb of the internal capsule, part of the choroid plexus of the lateral ventricle, and also the uncinate gyrus of the temporal lobe.[2] Finally, the internal carotid divides into three main branches—anterior cerebral, middle cerebral, and posterior communicating. The two anterior cerebral arteries are connected by the short anterior com-

[1] Stephen Paget, *Essays for Students*, 1898.
[2] Beevor, *Brain*, 1907, p. 403.

municating artery, thus completing the "circle of Willis." The *anterior cerebral* artery passes forward, and then, curving round to the top of the corpus callosum, turns backwards, parallel with its fellow of the opposite side, between the mesial surfaces of the two hemispheres. Most of the mesial surface of the cerebral hemisphere, as far back as the parieto-occipital fissure, is supplied by the anterior cerebral artery (Figs. 32 and 33). It also sends branches over the edge of the hemisphere to its convex surface, supplying the anterior and mesial part of the frontal lobe and a small part of the parietal lobule. And at the beginning of its course, it sends a few perforating branches inwards to the caudate nucleus.

The *middle cerebral* artery, or *arteria fossæ Sylvii*, is clinically the most important of the three. Its main trunk passes upwards and

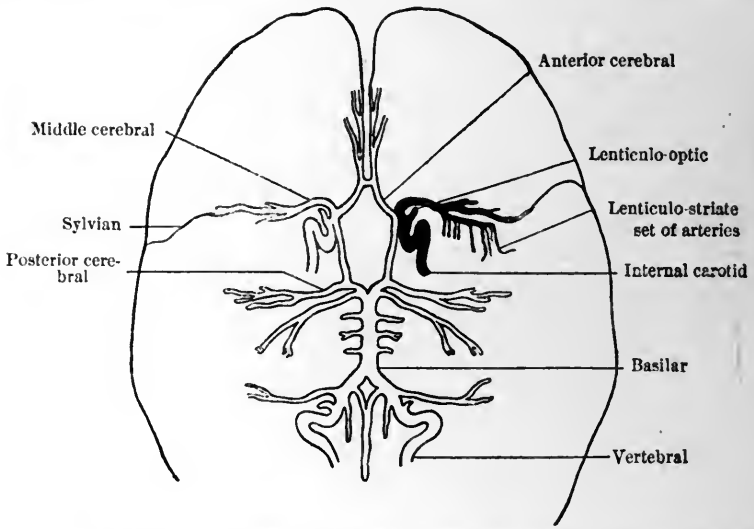

FIG. 31.—Arteries at the base of the brain. One, the lenticulo-striate, is called the artery of cerebral hæmorrhage. (After Dercum.)

outwards along the Sylvian fissure to the surface of the island of Reil, where it divides into its terminal branches. At its beginning it gives off numerous basal perforating arteries, which enter the anterior perforated space and ascend to the caudate and lenticular nucleus (which together constitute the corpus striatum), also to the optic thalamus. These branches are called lenticular, lenticulo-striate, and lenticulo-optic, according to their distribution. All these, and especially the lenticulo-striate arteries, are frequently the seats of cerebral hæmorrhage. The main trunk of the middle cerebral runs along the Sylvian fissure where it divides into four terminal branches (Figs. 32 and 33). One goes to Broca's convolution (the third inferior frontal); another to the lower two-thirds of the pre-central convolution and to the adjacent part of the second frontal convolution; another to the post-central convolution and the adjacent superior parietal convolution; and a fourth to the supra-marginal convolution, the angular convolution and the upper temporal convolutions, and so to the tip of the lobe on its mesial aspect.

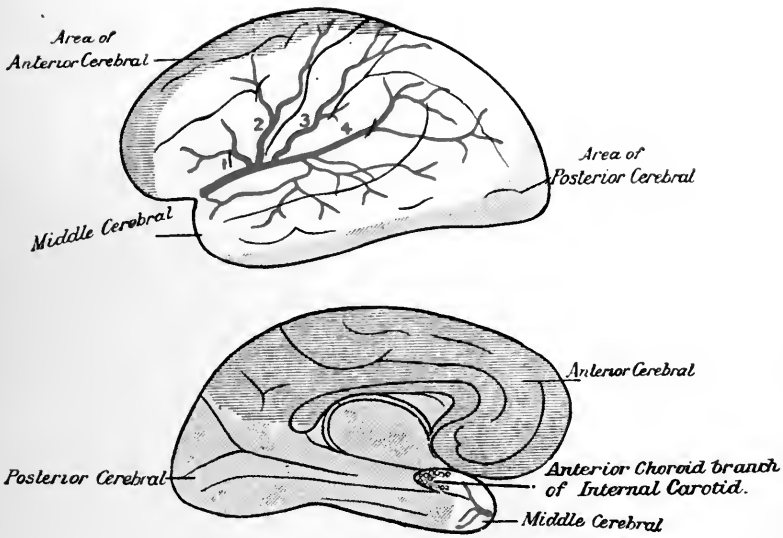

FIG. 32.—Diagram of arterial supply of cortex.

To face page 42.

The cortical arteries anastomose with one another, but not so the perforating basal vessels. They are " terminal " arteries, and do not anastomose either with each other or with the cortical vessels. Therefore if a basal artery becomes blocked by thrombosis or embolism, a permanent area of necrosis results. On the other hand, the blocking of a cortical artery admits of a more favourable prognosis, since a collateral circulation may develop and the necrotic process be arrested.

The *cerebellum* is supplied by the anterior cerebellar and superior cerebellar arteries from the basilar, and by the posterior cerebellar arteries from the vertebral. The posterior inferior cerebellar artery, which supplies the lateral aspect of the medulla, is of clinical importance inasmuch as, when it is thrombosed, the resulting area of destruction

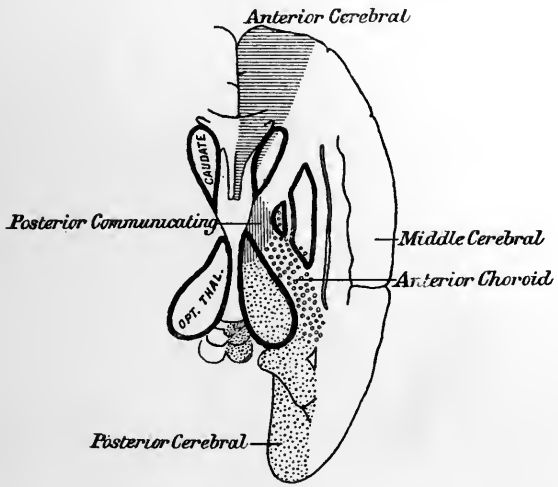

FIG. 33.—Arterial supply of basal ganglia and cortex. (After Beevor.)

(including the inferior olive, the restiform body, and the intervening nuclei of the vagus and glosso-pharyngeal) produces a characteristic unilateral bulbar syndrome (see later, p. 257).

The *spinal cord* is supplied by three main arteries, one anterior and two posterior, running on the surface along the entire extent of the cord. The anterior spinal artery arises from one or other vertebral, receiving a small communicating branch from the opposite vertebral. As it runs down the front of the cord, it is reinforced by a series of smaller vessels, derived from the intercostal and lumbar arteries, which enter here and there along the anterior roots. The anterior spinal artery sends numerous branches deeply along the pia mater lining the median fissure, dipping alternately into the right and left sides of the fissure, and supplying the grey matter of the cord.

The two posterior spinal arteries, one on each side, also arise from the vertebral arteries and run downwards on the back of the cord, close to the posterior roots, being reinforced by small branches entering here and there along the posterior roots. Fig. 34 shows diagrammatically the position of these various spinal arteries, and it should be observed that the grey matter and the white receive their blood-supply from different vessels. Moreover, like the perforating basal arteries of the brain, all the spinal arteries, once they have penetrated the cord, are terminal arteries and do not anastomose. Therefore embolism or thrombosis of a spinal artery always produces an area of necrosis.

The **Venous Circulation** in the brain is peculiar, inasmuch as the direction of the blood-stream in the cortex is the same in the arteries as in the veins, *i.e.* from before backwards. The *superior longitudinal sinus* receives not only the superior cerebral veins from the cortex, but also some veins from the scalp, and through its starting-point at the foramen cæcum it receives branches from the nasal vein, though after childhood this foramen often becomes closed. Therefore when **thrombosis of the superior longitudinal sinus** occurs in a marasmic child, we expect epistaxis, convulsions, and distension of the nasal veins, together with distension of the veins of the scalp. Posteriorly the superior longitudinal sinus ends at the torcular Herophili. This sinus runs so close to the surface that in the infant, before the anterior fontanelle becomes closed in, it is easy to use it for the purpose of intravenous injections.

The *inferior longitudinal sinus* is quite small, and, like the superior, lies between the layers of the falx cerebri, but at its lower edge. It runs backwards to the anterior edge of the tentorium, receiving branches from the mesial surface of the hemispheres, and ends in the straight sinus. The straight sinus receives some cerebellar veins and the veins of Galen from the velum interpositum and interior of the brain, and passes backwards either into the torcular Herophili or into one of the lateral sinuses. When the veins of Galen are thrombosed the cerebral ventricles become distended with fluid.

The *lateral sinuses* begin at the internal occipital protuberance and arch outwards, one on each side, to open through the jugular foramen into the internal jugular vein. The sinus passes close to the mastoid portion of the temporal bone. Here it receives the superior petrosal sinus, and also emissary veins from the scalp in the mastoid region. Just before it empties into the jugular, it receives the inferior petrosal sinus and sometimes the occipital sinus from the torcular.

Lateral sinus thrombosis is a well-known and dangerous complication of suppuration in the middle ear. It is recognised by distension of the mastoid veins, œdema of that region, and hardness and tender-

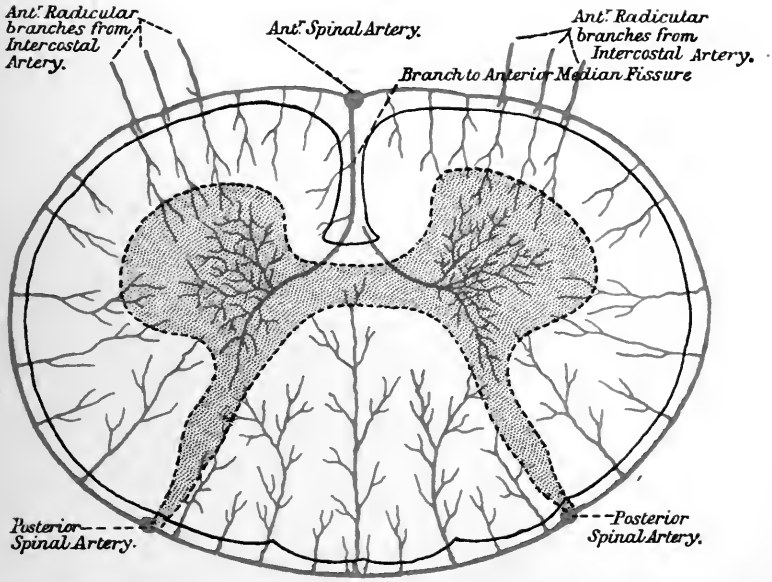
Ant.r Radicular branches from Intercostal Artery.
Ant.r Spinal Artery.
Ant.r Radicular branches from Intercostal Artery.
Branch to Anterior Median Fissure
Posterior Spinal Artery.
Posterior Spinal Artery.

FIG. 34.—Diagram of the course and distribution of the terminal arteries of the spinal cord. (After Van Gehuchten.)

To face page 44.

ness of the internal jugular vein. Together with this we may have rigidity of the neck, tinnitus, vertigo, and even signs of compression of the vagus, such as dyspnœa, dysphagia, bradycardia, and palatal paresis. It is not uncommon to find swelling and œdema of the ipsolateral optic disc. Crowe[1] has pointed out an additional physical sign, based upon the fact that in health, if one internal jugular vein be compressed in the neck, the retinal vessels show no change, but when both jugulars are digitally compressed, the retinal veins become visibly engorged. If one jugular vein (or the lateral sinus from which it arises) be already obstructed by thrombosis, pressure on the jugular vein of the sound side will produce venous engorgement of the retinal veins (visible by means of direct ophthalmoscopy) and sometimes also of the supra-orbital veins: whereas if both jugulars are patent, pressure on one jugular produces no such result.

The *cavernous sinuses* lie one on each side between the sphenoidal fissure and the apex of the temporal bone. Each sinus receives the ophthalmic veins from the orbit and communicates by means of the circular (or intercavernous) sinus with its fellow of the opposite side. The sinus ends posteriorly by opening into the two petrosal sinuses.

Fig. 35.—Thrombosis of left cavernous sinus.

Thrombosis of the cavernous sinus is generally secondary to some septic condition of the orbit, naso-pharynx, or sphenoidal sinus. It is recognised by the presence of chemosis (œdema of the conjunctiva), proptosis (bulging forwards of the eyeball), and œdema of the upper lid and root of the nose (see Fig. 35). There may be paralysis of certain of the external ocular muscles from affection of the third, fourth, or sixth nerves, which lie in the outer wall of the cavernous sinus.

Nearly all the intra-cranial venous blood leaves the skull by the internal jugular veins, so that in an infective thrombosis of any of the cerebral sinuses it may become necessary to ligature the internal jugular vein to prevent a general pyæmia.

[1] *Bulletin of Johns Hopkins Hospital*, 1912, vol. xxiii., p. 321.

CHAPTER III

METHODS OF CASE-TAKING

In no class of maladies is a thorough examination of the patient of greater importance than in cases of nervous disease. One cannot urge too strongly the value of systematic examination. It matters little what particular scheme of case-taking be adopted, so long as it is one which ensures that the investigation is complete, and that no point of importance is overlooked. Sometimes, it is true, we may make a diagnosis at a glance, as for example in paralysis agitans, or chorea. But more usually the patient presents symptoms or signs which are common to several diseases, and we have to decide from which of these diseases he is suffering. The chief causes of wrong diagnosis are insufficient examination, inaccurate observation, and, less commonly, false conclusions from correct and sufficient facts. But if we pursue a good routine method of examination, gross errors of diagnosis can generally be avoided.

Examination of a nervous case should not be confined to the nervous system alone. All the systems of the body should be investigated. An accomplished neurologist must be in the first place a sound general physician.

The value of negative as well as positive facts cannot be overestimated. The neurological student should accustom himself from the outset not only to chronicle deviations from the normal, but also, if he finds that certain other functions are normal, to record the fact and not to pass them over without reference.

As in any other case, a careful history should first be obtained. It is comparatively seldom that a patient, however willing he may be, provides us spontaneously with an accurate history of his case. We generally have to guide his tale by suitable questions, and in many cases we have to supplement the patient's account by inquiring for corroborative or correcting facts from the patient's friends.

We first inquire as to the *mode of onset* of the patient's symptoms, whether such onset was sudden or gradual, and, if gradual, the exact order in which the various symptoms appeared. In the *family history* inquiry should be made as to the occurrence of nervous or mental disease in other members of the family, also as to a family history of gout, asthma, tuberculosis, cancer, etc. In certain cases, consanguin-

ity of the parents should be inquired for. In the account of the patient's *previous health*, it is important to inquire as to syphilis, kidney disease, gout, rheumatic fever, or any previous nervous disease, and a note should be made as to the patient's occupation and habits of life, and as to his temperance in alcohol, tobacco, etc. When inquiring about venereal disease, if the patient is a man, we should put our questions straightforwardly, but in female patients considerable delicacy is necessary, and it is advisable simply to inquire for collateral symptoms, *e.g.* rashes, falling out of hair, sore throat and, especially in married women, a succession of premature or dead children. In any case we should never interrogate a male patient on the subject of venereal disease in the presence of his wife, nor *vice versâ*.

Having thus noted the chief points in the history of the case, we proceed to the examination of the patient's *present state*. The following scheme will be found useful:—

Scheme for Routine Examination of Nervous System.

Higher Cerebral and Mental Functions.

Intelligence—Attention—Memory—Emotional state—Hallucinations or delusions—Delirium—Coma—Drowsiness—Insomnia.

Fits or other Abnormal Movements.

Fits — Tremors — Fibrillary movements — Chorea — Athetosis — Ties — Myoclonus, Myotonus, etc. Description of each.

Speech and Articulation.

Aphasia—Is patient right or left handed ?

Cranial Nerves.

1. Smell—Anosmia—Parosmia.
2. Visual acuity—Fields of vision to a moving and to a stationary object: Hemianopia, etc.—Colour-blindness—Ophthalmoscopic examination—Optic discs, atrophy, neuritis—Retinal hæmorrhages, choroiditis, etc.
3. } Pupils: Size, shape, reaction to light (direct and consensual), and to accom-
4. } modation—External ocular movements—Ptosis—Movements of eyes in
6. } all directions—Convergence—Squint—Diplopia—Nystagmus.
5. Sensation—Face: Conjunctival, nasal, and buccal mucous membranes—Taste. Motor—Masseters, temporals, pterygoids, etc.
7. Sensory fibres (nervus intermedius): Cutaneous sensation in external meatus and membrana tympani. Taste in anterior two thirds of tongue (chorda tympani).
   Motor fibres: Facial muscles, upper and lower—Nerve to stapedius—Hyperacousis.
8. Hearing: Aerial and bone conduction—Examination of meatus and tympanic membrane—Tinnitus.
   Vestibular sensation: Vertigo—Thermic nystagmus—Deviation tests.
9. Taste: Posterior third of tongue—Anæsthesia of pharynx—Difficulty in swallowing. "Curtain" movement of pharyngeal wall.
10. Palate—Recurrent laryngeal branch—Laryngoscopic examination—Heart, respiration, digestion.
11. Sterno-mastoid and Trapezius.
12. Tongue (motor).

Sensory Functions.

Subjective sensations: Pain:—site, direction of radiation, character, frequency—Headache—Vertigo—Tingling—"Pins and needles"—Formication, etc.

Sensibility to touch — pain — temperature — Anæsthesia — Paræsthesia — Hyperæsthesia—Tenderness on pressure over nerve-trunks, muscles, or skin—Vibration-sense (with tuning-fork—Joint-sense—Sense of active muscular contraction with different weights—Stereognosis and recognition of passive movements (three dimensional)—Compass test (two dimensional)—Spot-finding (uni-dimensional)—Recognition of intensity (between cold and cool, between warm and hot, etc.)—Recognition of similarity and difference (appreciation of size, weight, shape, texture).

Motor Functions.

Paralysis or Paresis:—In head and neck, upper limbs, diaphragm, intercostals, spinal and abdominal muscles, lower limbs.
Monoplegia—Hemiplegia—Diplegia—Paraplegia—Hemi-paraplegia—"Crossed paralysis," etc.

Co-ordination:—Unsteadiness of upper or lower limbs on voluntary movement—Deviation tests after inducing vestibular nystagmus—Finger-nose and heel-knee tests—Gait.

Muscular Atrophy or Hypertrophy. Rigidity—Flaccidity—Hypotonia.

Reflexes.

Superficial.—Corneal, palatal, epigastric, abdominal, cremasteric, plantar (flexion or extension of hallux)—bulbo-cavernosus—anal.

Deep.—Jaw, wrist, elbow, knee, ankle-jerks. Ankle-clonus—knee-clonus, etc.

Organic.—Micturition—Retention—Retention with overflow incontinence—Intermittent incontinence—Constant paralytic dribbling—Defæcation—Control of sphincters—Priapism.

Trophic Functions.

Muscles.—Electrical reactions—Faradic—Galvanic—Condenser shocks.
Skin.—Bullæ—Herpes—Bed-sores—Perforating ulcers—Glossy skin, etc.
Joints and Bones.—Arthropathies—Spontaneous fractures—Pes cavus, etc.

Examination of Skull and Vertebral Column.

Abnormal projections or depressions—Tenderness, etc., on percussion—Radiography.

Cerebro-spinal Fluid.

Naked-eye characters of fluid—Microscopic examination—Cytology—Bacteriology—Wassermann reaction—Albumin, globulin, urea, etc.

Vegetative Nervous System.

Cervical sympathetic—Dilatation of pupil to shade and cocaine—Ciliospinal reflex — Proptosis — Exophthalmos — Enophthalmos — Retraction of upper lid—Pseudo-ptosis—Flushing or sweating of face, neck, upper extremity.

Angio-neuroses — Raynaud's disease — Erythromelalgia — Angio-neurotic œdema — Localised hyperidrosis or anidrosis — Intermittent claudication, etc

Several points should be noticed in the foregoing scheme. We begin with the higher cerebral and mental functions, for this reason, that if a patient be mentally obtuse, or worse, if he be confused or delirious, then any statement he may make is open to doubt, and for our diagnosis we must rely mainly (and in cases of coma entirely) upon physical signs and upon the history supplied by the patient's friends.

The patient's emotional state is sometimes of diagnostic significance. Not only are many hysterical patients unduly emotional, but a similar

condition is observed in certain cases of disseminated sclerosis, where there is a tendency to smile and giggle upon slight provocation, whilst, on the other hand, cases of aphasia and of advanced bulbar palsy are often lachrymose.

The statements of a patient who is addicted to habitual alcoholic intemperance, or to chronic poisoning with opium, cocaine or other drug, must also be received with philosophic doubt. There is a special variety of loss of memory, called **Korsakow's psychosis,** which occurs chiefly in chronic alcoholists. The patient is usually a woman and the subject of peripheral neuritis. This is most commonly alcoholic in origin, but is sometimes due to other toxic causes, such as arsenical poisoning, septicæmia, or other severe fever, *e.g.* malaria or enteric fever. The patient has a faulty conception of time and place and a specially deficient memory for recent events. Moreover she frequently suffers from "mythomania" and has what are euphemistically called "pseudo-memories," so that she is a reckless liar and "the truth is not in her." This is one of the toxic varieties of insanity, and is commoner in women than in men. The male alcoholist seldom shows Korsakow's psychosis, but if his alcohol be suddenly withdrawn (*e.g.* during an acute illness or following an accident), he tends to suffer from the more violent and dramatic "delirium tremens," with the tremors, acute distress, auditory hallucinations of voices talking to him, and visual hallucinations of rats, beetles, devils, etc. (zoopsia), so familiar to the lay writer. Olfactory or gustatory hallucinations are rare in alcoholists.

Passing from the patient's mental condition, we should carefully observe and describe any fits, tremors, or other spontaneous abnormal movements that may be present. Disorders of speech and articulation should next be studied, and the cranial nerves examined in due order.

It will be observed that, in our scheme of case-taking, sensory functions are investigated before motor. As a matter of experience, this order of examination is found to be of considerable practical advantage. The discovery of an area of anæsthesia often puts us rapidly on the track of a correct diagnosis and enables us to select with greater ease the salient points in the motor and other phenomena.

Certain accessory methods of examination, such as the testing of electrical reactions and lumbar puncture, are required only in special circumstances, where they may throw a flood of light on an otherwise obscure case. Inspection, palpation, and percussion of the skull are of considerable value in some cases of tumour of the brain, especially in cases of cerebellar growths. Sometimes it is advisable to have the scalp shaved, in order to detect abnormalities in the shape of the cranium.

Having collected our facts, comprising the history and the present state of the patient, we are now in a position to make our diagnosis. And in the process of diagnosis we have, first of all, to ask ourselves—Is the disease an organic one, due to a gross irritative or destructive lesion in the nervous system, for example cerebral hæmorrhage, alcoholic neuritis or tuberculous meningitis? Or is it one of the so-called "functional" diseases, that is to say, without known morbid anatomy, for example hysteria, migraine, neurasthenia?

The boundary-line between functional and organic diseases is not so definite as might at first sight be supposed. At the present day, many diseases are classified as functional, for no better reason than that in them no constant anatomical changes have yet been recognised. In such diseases as epilepsy, exophthalmic goitre, and Raynaud's disease, there can be little doubt that profound molecular changes exist—in the first instance in the central nervous system, in the two latter in the vegetative system—but these changes have not yet been identified. Other diseases again, due to poisoning by microbes or their toxins, or by other poisons, *e.g.* chorea, hydrophobia, tetanus, certain varieties of epileptiform fits, etc., are undoubtedly the result of pathological changes affecting various groups of nerve elements. And yet, because at present these changes are not visible histologically, they have been classed as "functional." Even hysteria itself, the prototype of functional disease, has some profound underlying bio-chemical change. The term "functional," then, is a confession of our etiological ignorance, and is by no means synonymous with "curable."

If the evidence points to an organic lesion, we have then to ask ourselves two further questions: (1) Where is the lesion? (2) What is its pathological nature? The answer to the first question, which constitutes the *anatomical diagnosis*, is derived mainly from a study of the distribution and grouping of the signs and symptoms. The answer to the second, constituting the *pathological diagnosis*, is attained mainly by a study of the history of the mode of onset and the rate at which the lesion develops.

In making an anatomical diagnosis we should always endeavour to think of a single lesion which will account for all the symptoms. Thus, for example, suppose a patient comes to us with hemiplegia of the left arm and leg, of the "upper motor neurone" type (see p. 28), and at the same time with a right-sided facial palsy of the "lower motor neurone" type. In such a case, instead of diagnosing two lesions, one in the right side of the brain causing left hemiplegia and another in the right facial nerve causing right facial palsy, we prefer to diagnose a single lesion in the right side of the pons, implicating simultaneously the right facial nerve and the pyramidal tract (see Fig. 6).

As an example of pathological diagnosis, suppose we have a patient with spastic paraplegia of both lower limbs and with anæsthesia up to the level of the umbilicus, the anatomical position of the lesion is

WITHDRAWN
LIBRARY
COLLEGE OF MEDICAL EVANGELISTS

comparatively easy to fix, namely in the lower thoracic region of the cord, implicating both sensory and motor tracts. If the symptoms appeared suddenly, we think of a vascular lesion such as hæmorrhage or thrombosis; if they developed within a day or two, some inflammatory condition such as myelitis is probable; whilst if they only appeared very slowly, taking many months to reach their present intensity, we have to think of a slowly progressive lesion, such as a tumour.

FIG. 36.—Paralysis of left musculo-spiral nerve, to which is superadded a hysterical monoplegia of the whole upper limb.

We must never diagnose hysteria or neurasthenia until we have excluded gross organic disease. And, finally, we should remember that the presence of certain hysterical or neurasthenic symptoms does not exclude a co-existent organic lesion, nor *vice versâ*. **Functional and organic disease may be combined** in the same patient, and this combination increases the difficulty of diagnosis. Thus, for example, a patient with hysterical paraplegia used a pair of crutches to get about; the pressure of the crutches in his axillæ subsequently produced a bilateral musculo-spiral paralysis of organic origin.

In most cases the functional element is more extensive in distribution than the underlying organic part, and, as it were, submerges it. Unless care be exercised in the examination, the organic factor may either be overlooked and the whole case wrongly regarded as functional, or, on the other hand, the organic paralysis may appear more serious than it really is. The following is another example of combined functional and organic paralysis:—

A gunner, aged twenty-seven, was hit by a shrapnel bullet at Gallipoli. The entry-wound was through the middle of the left upper arm, behind the musculo-spiral groove; the exit-wound was an inch higher up, through

the middle of the biceps. The bullet-track thus crossed the musculo-spiral nerve. The patient's upper limb at once dropped powerless to his side; he himself felt as if it had been blown off. He had no pain at the time of injury, nor afterwards.

When examined, eight days after the injury, there was complete anæsthesia of the left upper limb to all forms of cutaneous stimulation from the level of the acromion downwards (see Fig. 36). Joint-sense was absent at the fingers and wrist, normal at the elbow and shoulder. Vibration-sense was lost in the hand, forearm, and upper arm, normal at the clavicle and scapula.

The only voluntary movement that could be performed in the left upper limb was feeble flexion of the fingers. The thumb, wrist, and forearm were completely paralysed. The biceps and triceps could be felt feebly to contract, but not enough to move the elbow. He could feebly abduct and adduct the shoulder.

To faradism there was loss of reaction in the supinator longus and in the extensors of the wrist, fingers, and thumb. All the other muscles of the upper limb reacted briskly.

Fig. 36 shows the patient during an attempt to flex both elbows and to dorsiflex both wrists. On the left side he fails to do so. There is wrist drop, and the elbow is being passively flexed by the nurse. The entry-wound behind the musculo-spiral nerve is shown, also the upper limit of the cutaneous anæsthesia, up to the middle of the scapula.

CHAPTER IV

COMA

We are not infrequently called to see a patient who is found to be unconscious. In such cases it is of great importance to make a correct diagnosis as to the probable cause. There are different degrees of unconsciousness. For example, there are conditions in which the patient can be roused from his unconsciousness by shaking, shouting, or other stimuli, as in the case of ordinary sleep. When this degree of unconsciousness occurs in pathological conditions, as in a patient stupefied by various poisons (whether produced within the body or introduced from without), or from mechanical compression of the brain, for example by hæmorrhage, we call the condition **stupor.**

Cerebral Concussion, resulting from head-injury, follows immediately upon that injury, without any latent interval.[1] It is probably due to sudden hyperacute compression, or squeezing, of the whole brain, producing an instantaneous cerebral anæmia with wide-spread paralytic symptoms. This anæmia, in its most profound degree, has only a momentary duration and tends to pass off spontaneously, through reflux of blood. Complete re-establishment of the cerebral circulation takes some time, since the original anæmia of the bulbar nuclei causes a fall in blood-pressure.

The concussed patient is pale and collapsed, with a systolic blood-pressure lowered to 80 or 70 mm. of Hg or even less. He may be stuporose or even comatose. In a slight case there is merely temporary unconsciousness or giddiness, with pallor and a little mental confusion, often followed by headache. In more severe cases there is an *initial stage* of collapse with unconsciousness lasting for hours or even for days. But in most cases the patient can be roused by strong stimuli. His face is pale, his pupils dilated, his breathing is slow, shallow, and irregular; his pulse is weak and his temperature subnormal. He lies

[1] In war-time, concussion may occur from a sudden and violent variation in atmospheric pressure, resulting from the bursting of a high-explosive shell, without any direct cranial trauma. Experiments on animals* have shown that, under such conditions, minute peri-vascular hæmorrhages are produced in various situations, *e.g.* the grey matter of the cerebral cortex or of the mid-brain, the unsupported parts of the spinal nerve-roots, and the surface of the spinal cord; the alveolar capillaries of the lungs are also ruptured.

* Mairet and Durante, *Révue neurologique*, 1917, p. 421.

with flaccid limbs, like a drunken man. Trendelenburg has aptly named this condition "traumatic narcosis."

When the initial hyperacute compression passes off, it is followed by a certain amount of diffuse, reactionary swelling or œdema (such as follows a severe blow on any other organ). This œdema is associated with mild irritative phenomena, due to diffuse obstruction of the cerebral venules. This is the so-called *stage of reaction*, often ushered in by vomiting, sometimes even by an epileptiform convulsion. Consciousness begins to return; the temperature rises and may mount to 100° F. or higher; the pulse is now full and bounding, and the respirations become deeper. There is usually headache. In some cases, in which there has been considerable cerebral contusion, the reactionary œdema increases for a time until, about forty-eight hours after the accident, the classical picture of "**cerebral irritation**" is produced. Here the patient has curled up on his side, with all his limbs flexed and his head covered by the bed-clothes, making no spontaneous movements but resentful of any kind of stimulus, physical or mental. He is perfectly conscious, however, and has severe headache. The pulse is quick and the temperature raised from the subnormal concussion-level to 101° or 102° F.

A severely concussed patient generally has a "retrograde amnesia," *i.e.* he has no recollection of the incidents which occurred within the last few hours immediately prior to his accident. As a rule, although the memory of these incidents returns later, the remembrance of the accident itself is permanently lost.

Coma is that degree of unconsciousness which is so deep that we are unable, by any ordinary stimulus, to rouse the patient. A deeply comatose patient does not swallow fluids placed in his mouth, his conjunctival reflexes are absent and his pupils insensitive to light, as in deep chloroform anæsthesia.

How are we to proceed when called to see a patient whom we find comatose? Firstly, we inquire into the history, as to the patient's previous health, whether the coma was sudden or gradual in onset and whether it was preceded by other symptoms, such as convulsions or headache. We then examine the patient, feel the head for signs of injury, smell the breath, examine the pupils, noting their size, equality or inequality, and their reaction to light; we listen to the heart and note the character and frequency of the pulse and respirations. We note the radial systolic blood-pressure and measure it by means of a sphygmomanometer, if available. We observe whether the face is symmetrical or not, and whether there is conjugate deviation of the head and eyes in any direction. The optic discs in all cases should be examined. We lift the limbs in turn and let them fall, observing

whether there is any difference between the flaccidity of the two sides. We also test the knee- and ankle-jerks and examine the abdominal and plantar reflexes on both sides. Then we pass a catheter, draw off the urine, note its specific gravity and test it for albumin and for sugar. Finally we note the temperature in both axillæ, and in certain cases we perform lumbar puncture and examine the cerebro-spinal fluid. In patients from malarious districts we should also examine a blood-film for the malarial parasite.

The first question is whether the coma is due to a general toxæmia, such as poisoning by alcohol or opium, uræmia, diabetes, etc., or whether it is the result of some gross intra-cranial lesion, such as hæmorrhage, meningitis, abscess, tumour, etc.

As a general maxim we may state that, if coma be toxæmic in origin, practically all the signs and symptoms will be bilaterally symmetrical. On the contrary, most cases of gross intra-cranial disease being unilateral, or at least asymmetrical, there will therefore be a corresponding preponderance of symptoms on one side of the body, so that, in addition to coma, we have a number of unilateral signs. Let us consider these unilateral cases first.

The commonest case is that of **spontaneous cerebral hæmorrhage.** Here the onset of unconsciousness is generally sudden; the patient's face is flushed or cyanosed, his skin sweats profusely, he breathes stertorously, his blood-pressure is high, and his pulse is slow, full and bounding. All his limbs are flaccid, but on comparing the two sides, we find that the flaccidity is more absolute on the hemiplegic side. For example, the elbow of the affected side can be passively flexed to a greater degree than that of the healthy side. The arm and leg on the paralysed side also fall more "dead" than do those of the sound side when lifted up in turn and allowed to drop. The paralysed leg lies extended, whereas the healthy one tends to be semi-flexed. The head and eyes are often turned to one side, generally away from the paralysed limbs, unless the hæmorrhage be cortical or intra-ventricular, in which cases the deviation may be toward the paralysed limbs, and is associated with other irritative phenomena, *e.g.* spasticity instead of flaccidity. The face is asymmetrical, especially its lower part, the paralysed cheek flaps loosely during respiration and the mouth is distorted like a mark of exclamation laid on its side (-•), as if the patient were "puffing his pipe" at the paralysed angle of the mouth. The pupils are generally dilated and sometimes unequal, the larger pupil being on the side of the brain lesion. In pontine hæmorrhage, however, the pupils are often contracted to the size of pin-points. At the onset of an ordinary apoplexy, whilst we get little help from the deep reflexes, which may or may not be diminished or lost on the

affected side, there is, from the very outset, an extensor plantar reflex in the great toe of the hemiplegic foot, and all the other superficial reflexes on that side are diminished or absent. The skin of the abdomen can be pinched or pricked on the paralysed side without eliciting an abdominal reflex—(Rosenbach's sign). The corneal reflex is abolished on the hemiplegic side instead of on both sides as in toxic coma. The temperature on the paralysed side is usually higher than on the other, although the general temperature of the whole body falls at first. If the coma has lasted several hours, the bladder becomes distended and may develop an overflow incontinence. Afterwards, the temperature rises above normal, and in bad cases may go on to hyper-pyrexia.

Most cases of spontaneous cerebral hæmorrhage occur in patients past middle-age, in whom the arteries are no longer elastic and healthy, and there is often a history of kidney disease, with its resultant cardiac hypertrophy and high-tension pulse, conditions particularly liable to result in the bursting of a cerebral artery. The actual attack of hæmorrhage not uncommonly occurs during some slight physical exertion or mental excitement, as in public speakers (such as clergymen, politicians, orafter-dinner orators), or in old people with brittle arteries, during straining at stool. In most cases of intra-dural cerebral or spinal hæmorrhage from whatever cause, the cerebro-spinal fluid is tinged with blood in greater or smaller amount.

But, in rare cases, cerebral hæmorrhage may also occur in young people with healthy vessels, as, for example, in a child during violent convulsions or during a paroxysm of whooping-cough, when the hæmorrhage is commonly venous in origin (due to passive congestion with rupture of the cortical veins), and subdural in situation, or it may occur in any of the so-called "bleeding diseases"—purpura, hæmophilia, leukæmia, etc., especially after some trivial injury.

Cerebral hæmorrhage often occurs in cases of general paralysis of the insane, and in fact may be the first symptom calling attention to the disease. The symptoms are those already described, but there is usually a history of previous mental failure, grandiose ideas, loss of memory, attacks of emotional excitement, and slight indistinctness of articulation. In the absence of such history, we may be unable at the time to diagnose anything more than the fact of a cerebral hæmorrhage. But afterwards, when the patient recovers from his apoplexy—and the general paralytic recovers much more rapidly than the non-insane patient—we can generally recognise the characteristic evidences of the disease, both psychical and physical.

Coma may also be due to **traumatic cerebral "compression,"** where there is a hæmatoma from arterial bleeding on the surface of the brain, either intra- or extra-dural. The signs are practically the same

as in spontaneous apoplexy but the onset is different, for there is a history of a head injury. The symptoms develop gradually, especially if the hæmorrhage be extra-dural, beginning with local paralysis and perhaps localised convulsions. The paralysis gradually increases, the patient becomes drowsy, stupid, and finally comatose, the blood-pressure meanwhile rising to an excessive degree. There may be, before the onset of coma, a "*lucid interval*" of several hours or even a whole day, during which the patient, who was perhaps only stunned by the original blow, recovers consciousness and is apparently normal. A lucid interval of this duration, when followed by the above symptoms, generally indicates that the progressive hæmorrhage is extra-dural, most often the result of rupture of the middle meningeal artery or of one of its branches.

In intra-cranial hæmorrhage œdema of the retina often supervenes within a few hours.[1] The œdema is more intense in the eye on the same side as the focal compression, and this fact may be of diagnostic value in obscure cases of coma following head-injuries. This retinal œdema rapidly subsides if the intra-cranial tension be relieved by operation.

It is uncommon for symptoms of compression to come on immediately after the head injury, and when they do so, they suggest a depressed fracture pressing directly upon the brain. This can generally be detected by examination of the cranium.

Another important form of cerebral hæmorrhage which produces cerebral compression is **chronic subdural hæmorrhage** or **delayed traumatic apoplexy**, in which a collection of blood, often very large, gradually accumulates between the dura mater and the cerebral hemisphere. This blood is enclosed within a distinct membrane, derived from the coagulated blood itself. Its longest diameter, which may measure four to six inches, is usually antero-posterior, most commonly in the fronto-parietal region. The condition is sometimes bilateral. The bleeding is venous in origin, and is due to rupture of the short cerebral veins which enter the superior longitudinal sinus almost at right angles. These veins are firmly fixed at one end in the rigid dura, whilst they are attached at their cerebral end to the relatively movable brain. Chronic subdural hæmorrhage is the result of a trauma, but the injury is generally comparatively trivial, so much so, that unless inquired for, it may be entirely overlooked. A sharp blow, especially on the front or back of the head, may, without any fracture of the cranium, or even without a scalp-wound, suddenly dislocate the hemispheres and rupture the veins on one or both sides. The resulting hæmorrhage is a slow or intermittent venous oozing. After the injury

[1] Cushing, *New York Medical Journal*, January 19, 1907.

there is usually a long interval, of several days at least (much longer than in cerebral compression from arterial bleeding), before the hæmorrhage is large enough to cause symptoms of intra-cranial pressure. Then headache appears, severe and persistent, sometimes over the seat of the hæmorrhage. This headache lasts a week or two and is gradually followed by slight mental changes, such as absent-mindedness, sleepiness, forgetfulness, etc. This "prodromal period" generally lasts about six weeks. Then, rather suddenly, the symptoms become much worse and the drowsiness quickly deepens to coma. This may be ushered in by violent headache and vomiting. The coma is of a remarkable type, undergoing curious spontaneous variations, so that the patient passes from consciousness to unconsciousness and *vice versâ*. There is no other clinical condition in which this feature is so striking. The patient in the intervals appears mentally dull, but not confused. Responses to simple questions are made very slowly, but quite intelligently, so far as they go. The physical signs of focal cerebral lesion are variable, slight, and elusive. Pressure by the effused blood on the motor cortex may produce monoparesis or hemiparesis of leg and arm, the face generally being unaffected. An extensor plantar reflex and diminution or loss of the abdominal reflex are perhaps the most valuable unilateral signs. The extensor response may, however, be bilateral, even with a unilateral lesion, probably from dislocation of the opposite motor cortex against the cranium. Pressure on the mid-brain may produce ocular or pupillary changes. Optic neuritis may develop. In unilateral lesions it is usually most marked on the side of the lesion. In bilateral lesions, it tends to be most intense on the side of the greater lesion. Respiration is often peculiar—like that of a healthy person sleeping soundly—*i.e.* a little exaggerated in amplitude and with expiration slightly emphasized. This can be observed when the patient is apparently awake. The hæmorrhage is often bilateral, thereby confusing the clinical picture. Correct diagnosis is of great importance, since the condition is amenable to surgical treatment, and if the blood-cyst be evacuated and drained, complete recovery may occur. Spontaneous recovery is unlikely.

Chronic subdural hæmorrhage is probably identical with the condition known as *pachymeningitis hæmorrhagica interna*, which is associated with general paralysis, with chronic alcoholism, and with senile dementia. The condition has usually been assumed to be a spontaneous subdural venous hæmorrhage, but, as Trotter points out, alcoholic and insane patients are exactly those who are particularly exposed to the moderate kind of injury which is especially prone to produce chronic subdural hæmorrhage, and the patient is not likely to remember or make much of the accident.[1]

[1] Trotter. *Brit. Journal of Surgery*, vol. ii., 1914, p. 271.

Pontine Hæmorrhage is generally near the middle line, and therefore tends to produce bilateral symptoms. Pontine cases generally (but not always) have strongly contracted pupils owing to irritation of the third nerve nuclei. There is often hyper-pyrexia and most cases are fatal.

Thrombosis of the Cerebral Sinuses is a rarer cause of coma. Here the diagnosis rests chiefly on the history. Cases secondary to suppurative conditions of the middle ear or frontal sinuses will have a corresponding history and the other signs of intra-cranial venous obstruction. Primary thrombosis of a sinus, occurring without infection, as in marasmus, profound anæmia, etc., is excessively difficult to recognise.

Thrombosis of cerebral arteries, producing cerebral softening, often causes hemiplegia, but its onset is slower than is that of hæmorrhage; it more often comes on during ordinary sleep and is rarely associated with coma. In young patients it is generally syphilitic in origin.

In old people the commonest variety of non-fatal hemiplegia is the so-called **lacunar hemiplegia,** due to the occurrence of small lacunar foci of peri-arterial disintegration. The onset is sudden, but is rarely associated with unconsciousness. On the contrary, the old man, as it were, supervises his hemiplegic attack: he suddenly notices paresis and flaccidity of the limbs on one side, usually more marked in the leg than the arm. This hemiparesis clears up in a few hours or days without leaving behind it contracture in the paresed limbs. Such attacks tend to recur, affecting one or both sides of the brain, and often producing a curious short-stepped gait (*"marche à petits pas"*), until some day a terminal and fatal hæmorrhage occurs in and around one of the lacunæ, producing coma and the other classical signs of cerebral hæmorrhage.

Acute encephalitis, a disease of infective origin, is an occasional cause of coma, not only in children but in adults. A patient, free from the ordinary signs of cardio-vascular disease which would suggest a cerebral hæmorrhage or thrombosis, and without evidence of aural or other infection likely to induce meningitis, develops within a few days hemiplegic, aphasic, or other cortical symptoms, associated with deepening coma, sometimes preceded by headache and cerebral vomiting. The cerebro-spinal fluid in such cases, although under increased pressure, is otherwise normal, or may be more or less blood-stained from cortical thrombosis and capillary hæmorrhages supervening on the encephalitis. Some of these cases recover completely, especially after decompression by lumbar puncture; others remain permanently hemiplegic; others die within a few days from toxæmia or cortical hæmorrhage.

Amongst the other gross intra-cranial diseases producing coma, is **cerebral meningitis.** Here again our diagnosis depends on the history. Most frequently the patient is a child. Instead of a history of sudden coma or of head injury we learn that there have been, for some days, headache, vomiting, photophobia and head-retraction, and often the characteristic "hydrocephalic cry." The child gradually becomes drowsy, apathetic, and finally comatose. Rigidity of the neck muscles and head-retraction persist during the coma (Fig. 37). Kernig's sign, Bikeles's sign, and Brudzinski's "neck" and "leg" signs are often of value. *Kernig's sign* consists in a reflex contraction of the hamstring muscles and a wince of pain when an attempt is made to put the sacral nerve-roots on the stretch by flexing the hip to a right angle and at the same time extending the knee. *Bikeles's sign*[1] in the upper limb (analogous to Kernig's in the lower) consists in putting

FIG. 37.—Case of posterior basic meningitis, showing head-retraction and posture of limbs.

the roots of the brachial plexus on the stretch, by sitting the patient up, bending the elbow, pulling the arm upwards and backwards at the shoulder-joint to its maximal degree and then attempting passively to extend the elbow. In some cases of meningitis this last movement is resisted by the elbow-flexors. This sign is more constant in brachial neuritis than in meningitis. *Brudzinski's neck-sign*, which is even more frequently present than Kernig's sign, is elicited by passively flexing the head on the chest. This induces flexion of the lower limbs at the hips and knees, sometimes to a marked extent. *Brudzinski's leg-sign* is elicited by passively flexing one lower limb on the abdomen to its full extent, when the other leg is at once drawn up by the patient to a similar position. If the meningitis be chiefly on the convexity of the brain, there are commonly convulsions preceding or accompanying the coma. On the other hand, if the meningitis be mainly basal,

[1] *Neurolog. Centralbl.*, 1917, s. 407

there are cranial nerve paralyses, especially of the ocular muscles. Examination of the cerebro-spinal fluid obtained by lumbar puncture gives conclusive evidence in cases of suspected meningitis.

The diagnosis between meningitis and **cerebral abscess**, especially in cases of suppurative otitis, is sometimes difficult. Amongst the important diagnostic points the state of the pulse is of great value. In meningitis the pulse tends to be small, rapid, and irregular; in brain-abscess it is regular and full. In meningitis the temperature is usually raised: in brain-abscess it is often subnormal. Optic neuritis, if present, will indicate that the coma is not due to mere hæmorrhage, but that there is increased intra-cranial pressure, either due to meningitis, **cerebral abscess**, or possibly, if the history be a matter of weeks or months, to **intra-cranial growths**, syphilitic, tuberculous, or neoplastic.

Let us now pass to the other class of cases of coma, due not to a gross intra-cranial lesion, but to some general toxic condition of the higher cerebral centres. In this group the important point to notice is the absence of unilateral signs.

In the coma of **opium poisoning** there may be a history of laudanum swallowed or morphine injected hypodermically. An empty laudanum bottle or a hypodermic syringe may be found by the patient's side when he is discovered. If laudanum has been taken by the mouth, its odour may be detected in the breath. A chemical analysis of the stomach-contents obtained by the stomach-tube, will also help in the diagnosis. In the comatose patient we notice the excessive slowness of respiration, the slow and feeble pulse, the cold clammy skin, and, most striking of all, the pupils contracted to pin-points. These symptoms might be confused with those of pontine hæmorrhage. But there is not the pyrexia of a pontine apoplexy, and the coma of opium is not so deep as that of hæmorrhage. It used to be taught that in opium-poisoning the plantar reflexes are of the normal flexor type, but I have seen a case in which a young man, after a toxic hypodermic dose of morphine, became comatose with absent knee-jerks and ankle-jerks, and with extensor plantar responses. Fortunately, he recovered, and a few hours later the deep reflexes had reappeared and the plantar reflexes were again flexor in type.

The coma of **acute alcoholic poisoning** is not so deep as that of apoplexy, for the patient can generally be roused, temporarily at least, by energetic stimulation. The typical stertor of apoplexy is not present, the pupils are dilated and react to light, and the corneal reflexes are preserved. The temperature is subnormal, the breath and stomach-contents smell of alcohol, and if we mix a specimen of the urine with potassium-bichromate solution and then allow strong sulphuric acid to

flow to the bottom of the test-tube, a green colour appears if alcohol be present in the urine.

We must be careful, however, not to diagnose alcoholic poisoning simply because the patient's breath smells of alcohol. In the first place, a patient with cerebral hæmorrhage may have had alcohol given him, just at the onset of his symptoms. Or secondly, a patient who has been drinking alcohol may have an attack of apoplexy, or he may fall and sustain a head injury causing compression. Therefore every patient with apparent alcoholic coma should be carefully watched for about twenty-four hours, in case unilateral paralysis, an extensor plantar reflex, or inequality of the pupils should supervene.

Post-epileptic Coma may be mistaken for apoplexy, if we do not happen to know that the patient is epileptic. But generally we have the history of preceding fits, and in a chronic epileptic there may be old scars about the scalp, tongue, or face, the result of injuries during previous fits. There is no preponderance of unilateral symptoms after a general epileptic fit, nor is there inequality of the pupils. The tongue may have been bitten during the fit and may be still bleeding during the stage of coma. Within an hour or less, the epileptic recovers consciousness without paralytic sequelæ. If, however, some transient localised motor weakness follows, this points rather to a Jacksonian fit due to a focal lesion.

In the **Stokes-Adams syndrome** we have profound coma and stertorous breathing, with or without epileptiform convulsions. The condition is readily diagnosed by recognition of the extremely slow pulse-rate. Acceleration of the pulse precedes recovery from the coma.

Uræmic Coma is not uncommon, occurring as it does in patients who are the subjects of nephritis, acute or chronic. The coma is usually preceded by uræmic headaches, vomiting, and convulsions, local or general. A history of previous renal disease is here of great value, and there may be obvious signs of renal dropsy about the face and legs. Respiration is frequently of the Cheyne-Stokes type. The breath often has a urinous odour, and a catheter specimen of urine will show albumin together with various kinds of casts, and, in acute nephritis, blood. But we must not forget that a patient with chronic renal disease, a high-tension pulse and a hypertrophied heart, is a specially likely candidate for cerebral hæmorrhage. Therefore in a case of coma, mere albuminuria should not lead us to diagnose uræmic coma. We must always be on the look-out for symptoms of unilateral paralysis.

Diabetic Coma is easy to recognise, if we know that the patient has been suffering from diabetes. Even if there be no history of

diabetes, examination of the urine shows the characteristic high specific gravity, together with the presence of sugar in large amount as shown by the ordinary tests.[1] The addition of a few drops of liq. ferri perchloridi to the urine produces a deep brownish-red colour, due to diacetic acid. The "acetone" smell of the breath is unmistakable and occurs only in diabetes, in the rare condition of "delayed poisoning by anæsthetics,"[2] and in the "cyclical or periodic vomiting" with acetonuria seen in children,[3] both of which latter conditions are associated with acute fatty changes in the liver. Further, diabetic coma is not sudden in onset, but is commonly preceded by abdominal pain, air-hunger, and uncontrollable drowsiness, merging into profound coma with remarkably deep breathing. The pulse is usually small and rapid, unlike the full, slow pulse of cerebral hæmorrhage. Eyeball tension is usually lowered to a remarkable degree. Rise of temperature, which is so common in cerebral hæmorrhage, does not occur in diabetic coma.

Sunstroke sometimes causes coma. Here, of course, for diagnosis it is essential that there should be a history of exposure to a hot sun, of a previously healthy patient. Cerebral malaria must always be excluded (*vide infra*). Alcoholic patients are more liable to sunstroke than teetotallers. A patient who is comatose from sunstroke often has extraordinary hyper-pyrexia—108° F. and upwards. General convulsions may occur. The cerebro-spinal fluid in such cases often shows evidences of acute meningeal reaction, in the form of a polynuclear pleocytosis, passing on subsequently to lymphocytosis.

In patients from malarial climates we must also be prepared to meet with a comatose variety of **malignant tertian malaria**, in which the parasites produce thrombosis of the smaller cortical vessels. A malarious patient may rapidly become comatose with hyper-pyrexia, and may die within a few hours. In such cases the malarious history and the examination of the blood for the plasmodium will settle the diagnosis. It should be remembered that cerebral malaria may develop not only in tropical or sub-tropical countries, but may supervene after the patient has returned to a colder climate.

A patient dying from cancer may become comatose shortly before death—the so-called **coma carcinomatosum**, a condition similar to diabetic coma and associated with the appearance of β-oxybutyric acid and acetone in the urine.

[1] Glycosuria by itself, however, is not conclusive evidence that a case of coma is diabetic in origin, since sugar may appear temporarily in the urine as the result of a cerebral lesion (*e.g.* hæmorrhage) or after an epileptic fit. Glycosuria may also occur as a terminal phenomenon in tuberculous meningitis, generally within the last forty-eight hours before death.

[2] Guthrie, *Clinical Journal*, June 12, 1907.

[3] Langmead, *British Medical Journal*, 1905, p. 350.

We need not do more than mention the terminal coma of such diseases as acute yellow atrophy and rheumatic hyper-pyrexia, or the "coma-vigil" of typhus and of severe enteric fever.

Hysterical Trance, by a careless observer, might be mistaken for true coma. The hysterical patient, however, has neither stertor nor cyanosis, the breathing and heart's action are regular, though perhaps very faint, the pupils react to light, and the patient generally resists forcible opening of the eyes.

Thus a young man of twenty-two who had sudden attacks of apparent sleep (narcolepsy) coming on in the middle of meals or when playing cards, refused to be roused by ordinary stimuli in the form of shaking or shouting, but yielded at last to forcible digging in the ribs. He passed through a stage of "grande hystérie" before waking up, and for some time afterwards had hysterical blindness and presented other hysterical phenomena.

Cases of katatonic **stupor** or **trance** constitute a fairly common variety of war-neurosis. A young soldier, often of neuropathic diathesis, who has had some violent shock, whether physical, from the stunning effect of a shell-explosion, or mental, from the emotion produced by the horrors of the battle-field, is found to be in a condition of trance. If placed in bed he lies there, apathetic and silent, paying no attention to his surroundings. He does not ask for food, but if it is placed in his mouth, he swallows it. There is often rigidity of the proximal muscles of the limbs on passive movement. He may be completely mute or he may repeat the same word, or some unintelligible sound, over and over again, or makes spontaneous rhythmic movements of the limbs, face or trunk. If placed on his feet, he remains standing, making no effort either to walk or to get into bed again. Sometimes after a few minutes his legs give way and he collapses on the floor; but, without hurting himself. If led forward by the hand or gently pushed from behind, he walks slowly with a feeble, shuffling gait, but soon comes to a standstill. If he meets with an obstacle, *e.g.* a wall, he remains in contact with it, motionless. This condition, which closely resembles the spontaneous stupor of peace-time cases of dementia præcox, may last for a few days or for several weeks, clearing up gradually at first and later somewhat suddenly. The mutism often persists when the other phenomena have disappeared. Sometimes the power of speech is restored suddenly, perhaps after some emotional shock of an agreeable nature. In other cases the patient passes through a stage of severe stammering, lasting for many weeks.

The **hypnotic trance** may be regarded as an artificially-induced form of hysteria, the result of suggestion in a sensitive subject.

CHAPTER V

FITS AND OTHER CONVULSIVE PHENOMENA

We are often consulted about patients who are said to have "fits," but we are seldom fortunate enough to witness an attack. If we do, the diagnosis presents little difficulty. More often, in making our diagnosis as to the nature of a fit, we have to depend upon the description given by the patient's friends.

The following is a list of the chief clinical conditions in which convulsive phenomena occur:—

- CEREBRAL FITS
  - HYSTERICAL
    - Hysteria major.
    - Catalepsy.
    - Hysteria minor.
    - Post-epileptic hysterical attacks.
  - EPILEPTIFORM
    - Epilepsy major (*grand mal*).
    - Epilepsy minor (*petit mal*).
    - Post-epileptic automatism — "masked epilepsy."
    - Toxic conditions: — Asphyxia, uræmia, puerperal eclampsia, alcohol, absinthe, lead, etc.
    - General paralysis of the insane.
    - Psychasthenia ("*Affekt-epilepsie*").
    - Organic brain lesions — Jacksonian fits, etc.
    - Infantile convulsions
      - Toxic.
      - Organic.
    - Stokes-Adams disease.
- CEREBELLAR FITS.

In making inquiries about convulsive phenomena, whatever their nature, it is advisable to avoid using the word "fit," especially if we are discussing symptoms in the presence of the patient. It is better to refer simply to "attacks." Many epileptics are unaware of their own disease, and even when they know its nature, they dislike hearing about their "fits."

The first point we should try to determine is whether the attacks are hysterical or epileptiform. In reference to this the age and sex of the patient are often of importance. We do not meet with hysteria

in infants, and rarely in children below the age of puberty. Epilepsy is of equal frequency in both sexes, whereas hysteria in civilian life is twenty times commoner in females than in males. Hysterical attacks in male patients are most frequent in lads at about the age of puberty.

Scheme of Investigation in Cases of Fits

Exciting cause. Nature of warning, if any. Onset, sudden or gradual. Scream. Injuries during falling. Movements, tonic, clonic, purposive. Starting-point of movements, and exact order of spread. Biting of tongue. Micturition or defæcation. Colour of face, pale, flushed, cyanosed. Pupils. Corneal reflexes. Knee-jerks and plantar reflexes immediately after attack. Duration of attack. After-symptoms (coma, vomiting, headache, sleep, etc.).

Pursuing the foregoing scheme, we should inquire whether there was any apparent cause for the attack. Hysterical attacks generally follow some emotional disturbance. **Epilepsy** comes on without exciting cause. A warning or *aura* before an attack of epilepsy may be of the most varied character. Perhaps the commonest is the "epigastric" aura; or there may be an indescribable feeling of terror; subjective auditory or visual phenomena (visual auræ being most frequently red in colour); unilateral tingling or twitching of the face or one of the limbs; or a "dreamy" mental state (sometimes associated with subjective sensations of smell or taste); and so on, according to the particular cortical area whence the epileptic explosion happens to start. But often the epileptic has no aura; he falls suddenly as if struck down by an unseen hand. If we happen to be feeling the pulse of an epileptic at the moment of onset of a fit, it will sometimes be noticed that the heart suddenly stops for a few seconds. Such cardiac arrest, however, is not invariable. **Hysterical attacks** usually come on gradually, and are often preceded by the hysterical "globus" or ball in the throat, or by feelings of palpitation, excitement, giddiness, tingling in the feet, etc.

Sometimes at the onset of the attack the epileptic, as he falls, utters a weird epileptic cry or moan, which is not repeated. By this time he is already unconscious and does not hear his own cry. Frequently he injures himself in falling, especially by striking his head. Many chronic epileptics may be recognised by the presence of numerous scars on the scalp and face. The hysterical patient, on the contrary, seldom injures herself when falling. She comes down carefully, often on a sofa or easy-chair. She not uncommonly screams, and may continue to scream or shout throughout the attack.

The nature of the movements during the attack is of importance. In epilepsy we have the tonic stage, in which all the voluntary muscles, including those of respiration, become suddenly rigid. The patient,

therefore, falls like a log, and his lips and face become cyanosed, his pupils dilating and becoming insensitive to light. The tonic stage passes into the clonic, in which violent jerking occurs in all the voluntary muscles, at first rapid, and gradually becoming slower and of greater range. The eyes, which during the tonic stage have been drawn to one side (the side on which the tonic spasm was more intense), now show rapid clonic jerks towards that side and the mydriasis ceases. The face loses its cyanotic hue, air re-enters the lungs, and is jerked out in short puffs mixed with saliva, forming a froth which is not infrequently blood-stained, since the jerking tongue may be bitten by the clonic movements of the jaws. During this stage the patient often empties the bladder and sometimes the rectum. Within two or three minutes from their onset the movements gradually cease, and the patient remains in a state of coma, with stertorous breathing, flaccid limbs, and sometimes profuse sweating, the eyes being now turned to the side opposite to that towards which they originally deviated, and the pupils being now contracted. Then, after ten minutes or so, the coma passes off, and the patient may vomit, or may wake up, perhaps with a headache, or may pass into a sound sleep.

In a hysterical attack, on the other hand, the patient's face is natural in colour, never cyanosed, though later it may become flushed from physical exertion. The voluntary muscles are usually contracted, the fists clenched, the eyes tightly closed, and resistant to opening, but if the eyes be forcibly opened the eyeballs roll upwards. Then, after a stage of general tremor totally unlike the clonic stage of epilepsy, the patient makes violent "purposive" movements, kicking, pushing, biting, rolling about, banging her head on the floor, beating her own face, pulling her hair, etc. During this stage various grotesque postures may be assumed; of these, the most characteristic is one in which the back is arched (opisthotonos) and the patient rests on her head and heels. Or there may be curving of the trunk laterally (pleurosthotonos), or forwards (emprosthotonos), "crucifixion" attitude, etc. The patient may talk, scream, or sing during the attack, which may last for many minutes. But throughout the attack the pupils generally react to light, and the corneal reflex is usually preserved. The hysterical patient never bites her tongue, though she may bite her lips or fingers, or snap at the fingers of bystanders. She never empties the bladder or rectum during the attack, and after it is over she may or may not have any recollection of what has happened, and is sometimes in a semi-dazed condition. The hysterical patient is more likely to recover suddenly after the fit than the epileptic; also she is more likely to "feel better" after the fit than in the case of an epileptic.

The knee-jerks, during the stage of flaccid coma terminating a

severe epileptic fit, may be temporarily abolished, but soon they become exaggerated, and, for a few minutes, ankle-clonus may often be elicited, whilst the plantar reflexes may be extensor in type. In hysteria the reflexes are unaltered.

Immediately following an epileptic fit there is often a temporary lymphocytosis of the blood; a phenomenon which does not occur in hysteria nor in malingering.[1]

If we bear in mind the foregoing points, the diagnosis between a severe epileptic fit and an attack of "*grande hystérie*" is generally easy.

Catalepsy is easily recognised by the peculiar immobility of the limbs. It occurs in its most intense degree in certain cases of dementia præcox, but is also met with, less severely, in hysterical patients. The patient during the attack, though not unconscious, is unable to move a muscle, but her limbs are plastic like those of a lay figure, and if placed passively in any posture, remain there.

There are also many varieties of *minor hysterical attacks*, easy of recognition, of which the commonest consist merely in emotional outbursts of uncontrollable laughing or crying, or a feeling of a lump in the throat—"globus hystericus"—which causes the patient to swallow.

Supposing, then, that we have come to the conclusion that the patient's attacks are hysterical and not epileptiform, we should not rest content until we have settled the further point as to whether the hysterical attack was preceded by an attack of minor epilepsy or *petit mal*.

Attacks of **petit mal** are often overlooked. It is well to remember that in true epilepsy (whether major or minor) the one essential phenomenon is not convulsions but loss of consciousness. In *petit mal* it may be the only phenomenon, so transient, perhaps, that the patient does not even fall; he simply pauses for an instant during conversation, looks strange, and then goes on with what he was saying. Or he may fall down and get up again immediately, a variety of epilepsy which is often mistaken for syncope, but is distinguished by the suddenness of onset and of recovery. If we happen to observe a patient at the moment of his attack of *petit mal*, we generally notice that the pupils dilate and his face turns momentarily pale, the pallor being followed by flushing. It is immediately after such a minor attack that some patients go on to a *post-epileptic hysterical attack*, and if the initial epilepsy be not recognised, treatment will fail.

Attacks of minor epilepsy are, now and then, associated with **post-epileptic automatism,** in which the patient has an attack of *petit mal* which perhaps passes unnoticed; he then proceeds to perform some unusual or inappropriate act, of which he has no recollection after-

[1] Bossard, *Schweizer Archiv für Neurologie und Psychiatrie*, 1917. Heft. 12.

wards. The same eccentricity is repeated on each occasion. Perhaps the commonest automatic action is that of undressing; or he may proceed to empty his bladder, as in the oft-quoted instance of the judge who did so in the corner of his court of justice; or he may perform some still more complicated action.

Thus a case of mine was that of a well-known financier who had several attacks of loss of memory (amnesia). During one of these, lasting two and a half hours, he attended an important board-meeting and proposed certain resolutions to which, both before and after, he was strongly opposed. He then took a friend out to lunch and returned to his office. He finally woke up and asked his confidential clerk where he had been.

The medico-legal significance of these cases is of importance, since such a patient, in a condition of post-epileptic automatism, may commit serious and complicated crimes, of which he has afterwards no recollection. This condition is sometimes called "*masked*" or "*larval*" *epilepsy*. It is possible that attacks of automatism or psychic epilepsy may occasionally actually replace the ordinary epileptic fit without an antecedent attack of *petit mal*, may in fact be "epileptic equivalents." But the more carefully such cases are observed, the oftener is some indication found of minor epilepsy immediately before the eccentric action, in the form perhaps of initial transient pallor. This was so in the case of the financier above referred to. Other cases of amnesia accompanied by ambulatory automatism are hysterical in nature (see later, p. 386). A previous history of epilepsy, either major or minor, is of great diagnostic value.

Supposing that, having excluded hysteria, we arrive at the conclusion that a patient's fits are epileptiform, we must still remember that many other conditions besides idiopathic epilepsy can produce epileptiform fits. Sudden obstruction of the larynx, *e.g.* by a piece of meat, bolted in a hurry, becoming impacted at the top of the larynx, may cause immediate unconsciousness followed by a typical epileptiform fit and by death unless the offending foreign body be promptly extracted. Similar **asphyxial fits** sometimes occur in cases of attempted suicide by hanging, where the unconscious person is cut down in time. Fits may also be of toxic origin. Acute **alcoholic** or **absinthe poisoning** may produce coma and convulsions. The history and the smell of the breath will usually guide us in such cases. The sudden withdrawal of alcohol from a chronic drunkard is sometimes followed by an epileptiform fit. In patients suffering from the convulsions of **lead poisoning** there are usually some of the other signs of plumbism, such as the blue line in the gums, high arterial tension, weakness of the extensors of the wrist, optic neuritis, etc., whilst the cerebro-spinal fluid shows a lymphocytosis. Toxins produced within the body may also cause fits exactly

similar to epilepsy, witness the **uræmic convulsions** of Bright's disease and of puerperal eclampsia. In every case of fits appearing in a previously healthy individual, the urine should be tested and the optic discs examined. In cases of chronic renal disease, besides the cardio-vascular changes, there not uncommonly exists albuminuric retinitis, which is of great diagnostic significance. When we come to the subject of infantile convulsions we shall find that many of them are toxic in origin.

Epileptiform fits may occur during the course of **general paralysis of the insane ;** they may, in fact, be the first symptom of the disease. Epileptic fits appearing for the first time in a middle-aged patient should always suggest the possibility of paralytic dementia. In such cases we look for inequality or irregularity of the pupils, and especially for loss of the light reflex, mental changes, facial tremors, and slurring articulation, and a history of syphilis should be sought. Lumbar puncture will show lymphocytosis of the cerebro-spinal fluid, a condition which is constant in general paralysis, but does not occur in idiopathic epilepsy, except as a transient phenomenon.

Epileptiform or hystero-epileptiform fits may also occur in *psychasthenic* individuals, so-called "*Affekt-epilepsie*" of Bratz. Such patients have stigmata of psychasthenia in the form of phobias, tics, obsessions, etc. (see p. 364). Epileptiform fits in psychasthenia, unlike true epilepsy, occur only after some direct exciting cause, such as physical or mental over-exertion or excitement, and may perhaps be due to vasomotor disturbance in the brain. The attacks, as a rule, are few in number and may be limited to a single one.

Intra-cranial tumours anywhere, even deep within the substance of the brain, may cause general epileptiform fits, from **increased intra-cranial pressure.** Here we are usually guided by the cardinal signs of intra-cranial tumour—headache, vomiting, optic neuritis, etc.

All the epileptiform fits to which we have as yet alluded have a bilateral general distribution, and are not succeeded by any localised paralysis. But when fits are produced by gross focal irritation of the cortex their onset is a local one, and they are not necessarily associated with loss of consciousness. Such "**Jacksonian fits**" are usually followed by weakness of the part which is primarily convulsed. Jacksonian fits may occur as often as fifty or a hundred times a day. They usually begin with a subjective sensory aura, such as tingling, numbness or twitching, localised in some particular part, *e.g.* the thumb or big toe. Then there is tonic spasm of that part, followed by clonic jerking. This may remain confined to the muscles where it began, or it may spread to others. If it spreads, it does so by a deliberate march from one cortical centre to another (Fig. 3, p. 4). Thus a fit commencing

in the big toe will occur successively in the ankle, knee, hip, shoulder, elbow, hand, etc., and affects the face last of all. Or a fit beginning in the elbow will spread *viâ* the shoulder, hip and knee, to the toes, and simultaneously *viâ* the wrist, fingers and neck, to the face and tongue, as the ripples produced by dropping a stone into a pool spread in ever-widening circles. A patient who has Jacksonian fits may remain conscious throughout the fit and may even be able to speak, though he is usually somewhat confused and excited. But if the convulsion spreads to the opposite cortical area, thus becoming bilateral, consciousness is lost as the fit crosses over. Jacksonian fits are followed by local weakness and increased deep reflexes in the convulsed part.

FIG. 33. FIG. 38A.

Cortical gumma of the face-centre of the right cerebral cortex.

Fig. 38 shows patient during a Jacksonian fit of the left face.
Fig. 38A shows weakness of the left face on voluntary movement.

Fig. 38 shows a patient during a localised fit of the left face, due to a gumma in the cortical facial centre. Fig. 38A shows the maximum voluntary movement of his face after the attack. It will be seen that the left lower face is markedly weaker than the right.

The localised paralysis passes off in the reverse order from that in which the spasm appeared, the muscles first convulsed being the last to recover power.

Of course, cortical lesions will produce localised motor phenomena only if they affect the motor centres in the region of the precentral gyrus. A focal lesion of a sensory cortical area produces, not a motor, but a *sensory fit*. Thus a post-central cortical lesion will cause tingling in the contra-lateral side, localised to the leg, to the brachio-facial region, or to the glosso-labial region, according as the upper, middle, or lower third of the post-central gyrus is affected.

Disease of the tip of the temporal lobe (Fig. 4, p. 5) causes a sudden subjective sensation of smell or taste (often associated with a characteristic "dreamy" mental state); a lesion in the occipital cortex causes subjective visual hallucinations, such as flashes of light in the contra-lateral half of the visual fields; and so on. Moreover, after a sensory fit it is not uncommon to find temporary sensory paralysis, *e.g.* localised paræsthesia after a post-central fit, anosmia after a temporal fit, or hemianopia after an occipital fit.

A Jacksonian fit, of whatever variety, is the result of a local lesion in the neighbourhood either of the cortex or of its superjacent meninges or bones. If the lesion be in the substance of the cortex, not merely superficial to it, there is often some local paralysis even before the fit occurs.

Localised fits may be produced by any irritative cortical lesion. The commonest causes are tumours, syphilitic or otherwise, abscesses, meningitis of any variety, local hæmorrhages, depressed fractures, scars of old cranial wounds in war, and so on. Localised fits may also be produced by *sub-cortical tumours* in the pre-central region. In such cases we observe muscular paresis in the affected limb, together with recurring convulsive phenomena in the limb; but the point of onset of the successive fits is less constant than in a true cortical convulsion, and the fit begins sometimes in one, sometimes in another muscle-group of the affected limb.[1] We should also bear in mind that Jacksonian fits may occur in certain cases of general paralysis of the insane, and sometimes even in uræmia.

Infantile Convulsions are epileptiform attacks occurring in infancy. The symptoms are similar to those of true epilepsy, but less violent. When called to see a child with convulsions, we should first examine for rickets, since rickety and hereditarily neurotic children are especially prone to convulsions. We should also try to determine whether the fits are reflex, toxic, or organic in origin.

In rickety infants of neurotic inheritance *reflex convulsions* may be set up by peripheral irritation such as the cutting of a tooth, round-worms in the intestine (thread-worms do not cause convulsions), a tight prepuce, etc. Moreover, rickety children often have other evidences of spasmophilia, such as tetany, laryngismus stridulus, and the well-known inversion of the thumbs towards the palms, a phenomenon which sometimes precedes a convulsion.

Toxic conditions may produce convulsions in previously healthy children. Thus any acute fever such as pneumonia, measles, scarlet fever or influenza, may be ushered in by a convulsion instead of by a rigor as in the adult. The convulsions produced by round-worms

[1] *Cf.* van Valkenburg, *Neurologisches Centralblatt*, 1906, p. 594.

may be partly toxic in origin. Uræmic convulsions occur in children, though less often than in adults, and in cases with recurring convulsions the urine should always be examined. Asphyxial convulsions, due to deficient oxygenation of the brain, occur in dyspnœa from any cause, *e.g.* during pneumonia and diphtheria, during a paroxysm of whooping-cough, or in the cyanosis of congenital heart disease.

Intra-cranial *organic* lesions may cause infantile convulsions. Thus, for example, polio-encephalitis superior, an acute inflammatory affection of the cortex cerebri (or cerebelli), has a febrile onset with vomiting and convulsions, usually more marked on one side than on the other. Its virus is probably identical with that of acute anterior poliomyelitis. After the convulsions have passed off, the child is often left permanently hemiplegic, diplegic, or ataxic. If the cortex of the frontal region is affected, permanent mental dulness may remain. The nuclei of various motor cranial nerves may also be affected (polio-encephalitis inferior), producing squint, facial, palatal, or glossal palsy. If there is a coexistent meningeal inflammation it will be evidenced by a lymphocytosis of the cerebro-spinal fluid. It is sometimes difficult to distinguish the disease from tuberculous meningitis. In polio-encephalitis, however, the coma is usually less profound and the disease is much less fatal. Moreover, the cerebro-spinal fluid, although showing a lymphocytosis, does not contain tubercle bacilli.

Local disease or injury of the bones or membranes may produce infantile convulsions. Convulsions appearing within a few hours after birth are not infrequently the result of compression of the brain by a meningeal hæmorrhage of venous origin from laceration of cortical veins. In such cases the diagnosis may be confirmed by examining the cerebro-spinal fluid, which is blood-stained.

Meningitis, whether due to the tubercle bacillus, to syphilis, or to other organisms, may produce convulsions, not only when cortical, in which case convulsions appear early, but also in basal cases, where the fits are due to increased intra-cranial pressure.

Epileptiform fits also occur in one variety of the **Stokes-Adams syndrome.** This condition occurs after middle life, usually in male patients with degenerate arteries. It is characterised by paroxysmal attacks of abnormal slowness of the ventricular beat, the rate sinking as low as twenty per minute or even less, together with excessive pulsation in the veins at the root of the neck, much more rapid than the ventricular beats, and corresponding with the auricular contractions. Such a patient is liable to syncopal attacks, to which may be superadded epileptiform fits or attacks of coma without convulsions. Fits do not occur unless the heart-block is complete, when the ventricle

no longer responds to auricular stimulation, but assumes a new rhythm of its own. More or less slowness of pulse usually persists between the paroxysms, as a permanent phenomenon. The condition is due to disease, syphilitic or otherwise, of the auriculo-ventricular muscle-bundle,[1] which arises in the right auricle, traverses the inter-ventricular septum and is distributed to both ventricles. When this bridge is diseased, the normal stimulus from auricle to ventricle is delayed or may even be completely blocked. This is known as heart-block, in which the auricles go on contracting normally, but the ventricle only responds to every second or every third stimulus. There is thus a dissociation between auricular and ventricular rhythm.[2]

Strychnine Convulsions should never be confounded with epileptiform fits, since they begin with clonic spasms, and shortly become tonic with opisthotonos, the tonic spasms recurring again and again with increasing severity. A patient poisoned by strychnine is not unconscious. Moreover, there are periods of intermission, lasting for several minutes at a time, during which the muscles are relaxed.

The tonic spasms of **tetanus** might be mistaken for strychnine poisoning, but they have no initial clonic stage. The classic symptom of tetanus is the well-known tonic spasm of the jaw muscles, producing "lock-jaw" or *trismus*. To this are superadded paroxysms of tonic spasm in the face (*risus sardonicus*), trunk and limbs, with opisthotonos, somewhat like those of the tonic stage of strychnine poisoning. Between the tetanic paroxysms there is no complete muscular relaxation as in strychnine poisoning, but simply a remission of the degree of spasm, the jaw muscles remaining partially contracted.

A patient suffering from **rabies** (or **lyssa**), following the bite of an infected dog, exhibits great mental excitement, often amounting to acute delirious mania, with tonic spasm of the muscles of deglutition, especially on attempting to swallow liquids (hence the misnomer hydrophobia). Unswallowed saliva may ooze from the mouth. The spasm may also be induced by other stimuli such as a bright light or a loud sound. The spasm spreads to other muscles, especially those of respiration, and severe opisthotonos may supervene at the end, the patient dying within a few days either of respiratory spasm or from syncope. Hydrophobia may be simulated by hysterical patients who have been bitten by a non-rabid dog. In such cases globus hystericus and hysterical opisthotonos may both be present, but true respiratory spasm does not occur in hysterical attacks, though there may be hysterical rapidity of breathing.

During an attack of **tetany** the posture is highly characteristic.

[1] Kent, *Journal of Physiology*, 1893, vol. xiv., p. 233.
[2] Mackenzie, *Diseases of the Heart*, 1908, p. 169.

There is a paroxysmal bilateral tonic spasm, usually painful, of the hands and feet, the hand assuming a conical shape (*"main d'accoucheur"*), the fingers being extended at the inter-phalangeal joints, slightly flexed at the metacarpo-phalangeal joints and pressed together with the thumb usually tucked inside the fingers; at the same time the muscles of the thenar and hypothenar eminences are contracted, so that the hollow of the palm is deepened. In the feet, the toes are flexed towards the sole, the ankle is dorsiflexed and the foot is sometimes inverted. These postures may persist during sleep. Pres-

FIG. 39.—Tetany.

sure on the nerve-trunks of the affected limb induces a typical spasm (Trousseau's sign), and the muscles and nerves are unduly irritable both to faradism and to galvanism (Erb's sign).

Tetany is most commonly met with in rickety children (Fig. 39) with deficiency of calcium salts, in whom it is often associated with other evidences of "spasmophilia" such as laryngismus stridulus and excessive irritability on percussion of the facial nerve (Chvostek's facial phenomenon). But it occasionally occurs in adults, *e.g.* after extirpation of the thyroid gland, or rather of the parathyroids, whose internal secretion plays an important part in maintaining a sufficiency

of calcium salts in the tissues and in controlling the production of guanidin (guanidin being a constituent of the creatin of muscle, possibly derived from creatin by a process of metabolism). Tetany is, therefore, a symptom of parathyroid deficiency, whether arising from disease or from artificial removal of the glands. Tetany also occurs sometimes during pregnancy or lactation, and as a grave terminal symptom in dilatation of the stomach. This latter variety of tetany is probably toxic in origin: so also are the rare cases of tetany associated with congenital dilatation of the large intestine in children.[1] Cataract is a curiously frequent concomitant of the gastric form of tetany. An endemic form of tetany also occurs in certain Continental towns, chiefly in the winter months. It is especially common amongst shoemakers. Chronic poisoning by ergot-infected grain may produce an epidemic form of tetany. With the removal of the poison the symptoms promptly subside.

FIG. 40.—Chvostek's sign of tetany on percussion over the right facial nerve.

Cerebellar Fits.—Irritative lesions of the sub-cortical intracerebellar nuclei are occasionally associated with cerebellar fits. These are never clonic, but consist of tonic spasms, sudden in onset. In *unilateral* cerebellar disease the spasms are more marked in the ipso-lateral limbs than in those of the opposite side. The face is usually unaffected. The ipso-lateral limbs become rigidly adducted to the trunk, the contra-lateral limbs are abducted, whilst at the same time there is a screw-like rotation of the limbs, trunk and head around their own long axes, from the side of the lesion towards the healthy side,[2] and a deviation of the eyes towards the healthy side. Hughlings Jackson has described another variety of cerebellar fit occurring in cases of tumour of the *middle lobe*. Here also, as in tumours of the lateral lobe, the fits are tonic, not clonic. They consist of head-retraction with arching of the back, flexion of the elbows, supination of the hands, and rigid extension of the legs, with pointing of the toes.

But let us not forget that epileptiform fits of cerebral type may also occur in cases of cerebellar tumour, due either to the general increase of intra-cranial pressure, or to a fulminating meningitis superadded to an old tuberculous tumour.

[1] Langmead, *Lancet*, Jan. 19, 1907.
[2] Grainger Stewart and Holmes, *Brain*, 1904.

CHAPTER VI

INVOLUNTARY MOVEMENTS

Besides fits, which we have already considered, there are many other conditions in which involuntary contractions occur in the voluntary muscles. But our knowledge of the mechanism of their causation is so incomplete that it is impossible at present to classify them accurately. We must therefore content ourselves, in the meanwhile, with referring to some of their chief clinical varieties.

In studying involuntary movements occurring in striated muscles, it is important to notice whether the movement is confined to an individual muscle or part of a muscle, or whether, on the other hand, it consists in alternate contraction of muscles and of their antagonists. We should also observe whether the abnormal muscular contractions produce movements of a joint, or whether they are so localised, either to a small muscle or to part of a larger one, that we merely see or feel the muscle fibres contracting beneath the skin.

The muscular phenomenon known as **shivering** or **rigor** is sometimes physiological. For example, when a healthy person becomes chilled, as by prolonged swimming, he shivers on coming out of the water. The involuntary muscular contractions of which shivering consists are for the purpose of producing heat and thereby raising the depressed body-temperature. But often rigors are toxic in origin, as are those occurring at the onset of certain acute fevers. Thus we have rigors in pneumonia, malaria, influenza, scarlet fever, etc. And the rigor which sometimes follows catheterisation is probably also toxic in origin, since it rarely occurs except when there is a raw surface in a urinary tract which is not aseptic. In all these toxic rigors, although the shivering patient has a sensation of cold, his temperature meanwhile is rising, and it continues to rise until the rigor stops. He has the sensation of cold because by vasomotor action the blood is driven out of his skin, which is therefore cooled and is actually cold, although the temperature of the blood is raised.

Transient flickering or quivering of a muscle, a condition known as **myokymia** (or more popularly as "live flesh"), affecting a few muscle-bundles of a single muscle, without producing movement of a joint, is not uncommon in people who are anæmic, neurasthenic,

or out of health. It is specially common in the orbicularis oculi and in some of the larger muscles of the limbs, *e.g.* the deltoid and biceps in the upper limb, the glutei and quadriceps in the lower. This variety of myokymia is not associated with muscular atrophy, nor with any alteration of electrical excitability. It is unaffected by rest or by voluntary exertion, and has no serious significance.

Sometimes, however, fibrillary movement occurs in organic lesions of the lower motor neurone. Thus in the muscular atrophy of *chronic anterior poliomyelitis*, of *amyotrophic lateral sclerosis*, and of some cases of *syringomyelia*, diseases in which the cells of the anterior cornua are undergoing slow degeneration, there may be seen fibrillary or fascicular tremors in the wasting muscles. This quivering myokymia can often be elicited by gentle flicking, or by a breath of cold air blown over the skin. A precisely similar fibrillary tremor occurs in the wasting tongue of *bulbar paralysis*, when the degenerative process has involved the hypoglossal nuclei. Fibrillary tremor does not occur in the primary myopathies, whether atrophic or pseudo-hypertrophic in type. In other cases fibrillary tremor occurs in the distribution of a motor nerve which has begun to recover from previous paralysis. It is not uncommon in the face during convalescence from facial palsy, and sometimes it persists for months and years after voluntary power has returned, as in the case of a professional friend of my own who is otherwise perfectly well. More usually the myokymia passes off when motor power has been restored.

Somewhat different in appearance is the condition known as **myoclonus,** a rare disease, characterised by paroxysms of sudden shock-like contractions in various muscles, lasting for several minutes at a time, irregular in rhythm and varying in rapidity from ten to fifty per minute. In slight cases the twitches may be insufficient to produce movements in the affected parts. The muscles affected are usually those of the limbs, especially the lower limbs, often symmetrically on the two sides, but contractions may also occur in the trunk and even in the face. Sometimes the diaphragm and the larynx are affected, so that curious grunting respiratory sounds are produced. There is no muscular atrophy or alteration in electrical excitability. The spasms cease during sleep. Several varieties of myoclonus have been observed. In one—Friedreich's *paramyoclonus multiplex*, usually a disease of adult life—the myoclonus ceases on voluntary movement. Another variety is Unverricht's *family myoclonus* or *myoclonus epilepticus*, in which several members of a family are affected, all belonging to the same generation, though the disease is not handed down from parent to child. In addition to the myoclonus, these patients have epileptiform fits, and they tend ultimately to become more or

less demented. Moreover, the muscular contractions in family myoclonus are intensified by voluntary movement and by psychical excitement. Family myoclonus usually manifests itself in early life, often at or before puberty. Thus in a little boy of thirteen suffering from myoclonus affecting the muscles of the neck, shoulders, trunk, thighs and cremasters (see Fig. 41), the condition had existed since the age of four, and he had also epileptiform fits. Two elder brothers

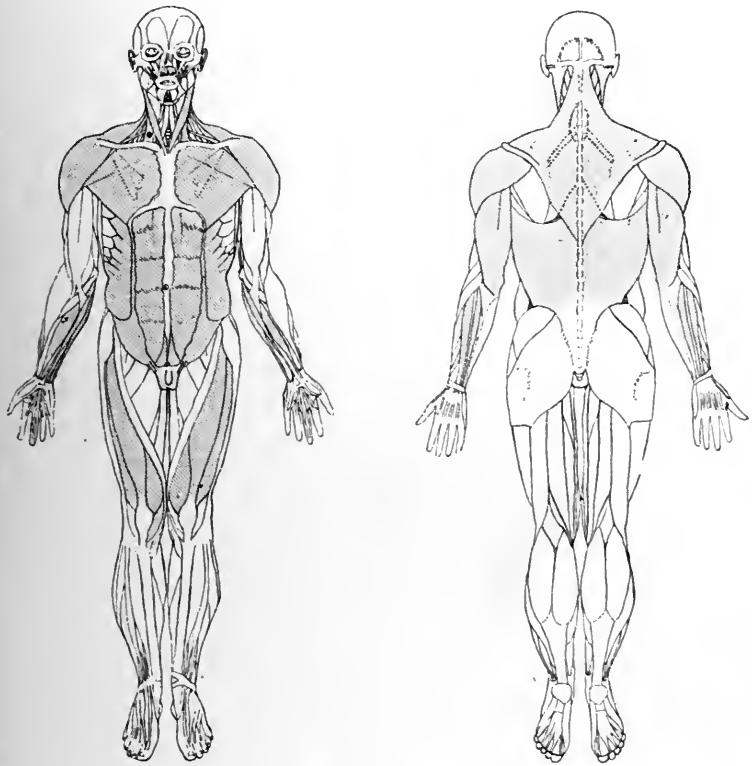

FIG. 41.—Unverricht's family myoclonus or "myoclonus epilepticus" in a boy aged 13. Besides the muscles indicated by shading in the diagram, the soft palate was also affected.

were similarly affected, both of whom, as the patient graphically put it, began to "click" at the age of seven. On the other hand, another patient suffering from Friedreich's paramyoclonus showed no symptoms of the disease till the age of forty-seven. He never had fits, and at the age of fifty, when he came under observation, he had myoclonic shocks limited to the muscles indicated in the accompanying diagram (Fig. 42). Another variety is the *nystagmus-*

myoclonus of Lenoble and Aubineau, to which we shall refer later (see p. 131).

We next pass to the consideration of **tremors.** The term "tremor" is applied to involuntary rhythmic oscillations of one or more parts of the body, resulting from the alternate contraction of muscle-groups and of their antagonists. A *simple* tremor is one which affects a single muscle-group and its antagonists, whilst in a *com-*

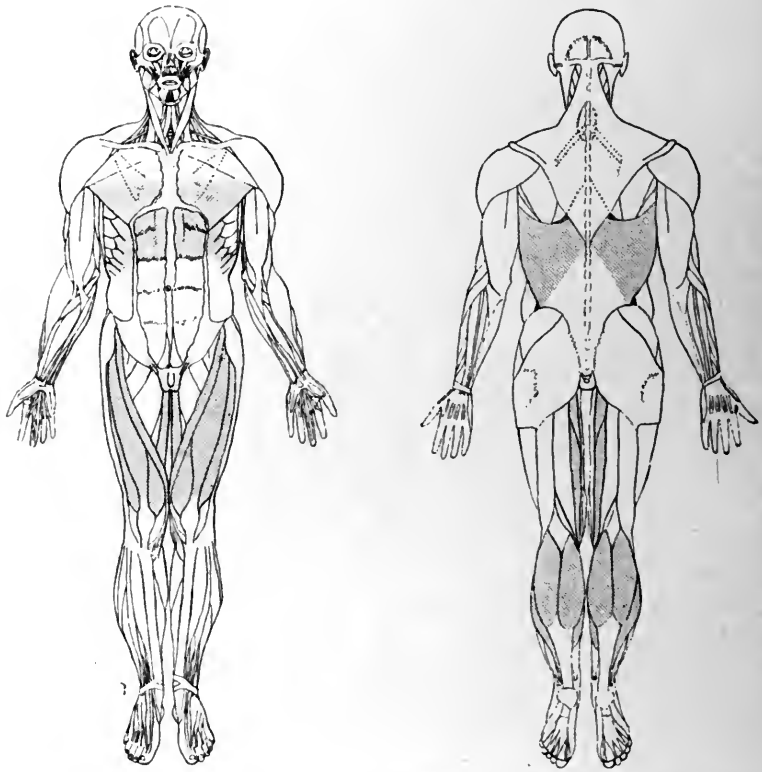

FIG. 42.—Friedreich's paramyoclonus multiplex in a man aged 50. The affected muscles are indicated by shading.

pound tremor several groups with their antagonists are in action, producing a complex movement, *e.g.* flexion and extension of the fingers combined with pronation and supination of the forearm. Tremors may be rapid or slow; they may be diminished or increased by voluntary exertion, and they generally cease during sleep.

We must not forget that an ordinary voluntary muscular movement is not the result of a continuous muscular contraction, but is constituted by the fusion of a rapid succession of short single con-

tractions, averaging from ten to twelve per second. In conditions of temporary *fatigue* or of more chronic *neurasthenia* the rate of these muscle-discharges becomes slower and less regular, so that the individual muscular contractions fuse less perfectly and the result is a very fine tremor on voluntary movement. In *emotional* excitement —more often in states of fear than from pleasurable emotion—there may be a fine rhythmic tremor of about eight or nine oscillations per second, familiar to the knees of many a public speaker. The same occurs in *exophthalmic goitre*. This tremor is made more apparent by voluntary exertion. It is best elicited by making the patient hold his hands horizontally in front of him, with the fingers widely spread. We can then feel the tremor even better than see it, by placing our own fingers lightly on the dorsum of the patient's hand. This fine tremor affects all the limbs, and in many cases can be detected by simply placing one's hand on the patient's shoulder. Tremulous respiration, in which the tremor is synchronous with that of the outstretched hands, is also one of the most constant signs of exophthalmic goitre. It is best marked during full expiration.[1]

Similar fine tremors also occur in certain **toxic** conditions. The tremor of chronic alcoholic poisoning is familiar to the lay observer, and when an alcoholic patient becomes delirious and maniacal (usually following a sudden enforced abstinence), his tremors are so evident that the condition is termed "delirium tremens." But other poisons besides alcohol produce fine tremors; for example, nicotine poisoning from excessive cigarette-smoking, also chronic poisoning by lead, mercury, chloral, cocaine, tea, coffee, tobacco, etc.

In cases of suspected alcoholism a valuable corroborative sign, known as *Quinquaud's finger-crepitation*, may often be elicited. In testing for this, we make the patient extend the fingers at the interphalangeal joints and press them at right angles to the palm of our own hand, which we hold in a vertical position. For the first two or three seconds nothing particular is noticed, but if the patient be a chronic alcoholic, we soon begin to feel a series of slight shocks, as if the phalanges of each finger were knocking, one against the other, trying to reach our palm.

The tremor of **paralysis agitans** occurs at rest and is generally rather coarse, varying in different cases from four to seven oscillations per second. It produces joint movements, *e.g.* the well-known "pill-rolling" movement of the thumb and fingers, flexion-extension movement of the wrists, pronation-supination of the forearm, flexion-extension of the ankle, etc. The coarser the movement, the slower is the rhythm. Paralysis agitans generally begins after middle life,

[1] Minor, *Zeitschrift f. d. ges. Neurologie u. Psychiatrie*, 1912, Bd. 12.

although juvenile cases are sometimes met with, in which the disease appears during adolescence. The disease is a progressive one. Its symptoms commence unilaterally, and may remain confined to one side for some time before ultimately becoming bilateral, as seen in Figs. 43 and 43A, which are taken from the same patient at an interval of three years. Usually the tremor of paralysis agitans can be temporarily controlled by voluntary exertion. But this is not always so; indeed, cases occur in which voluntary movement increases the tremor. Paralysis agitans is always accompanied by

FIG. 43.—Paralysis agitans, left-sided.

FIG. 43A.—Paralysis agitans:—the same patient as in Fig. 43, three years later.

rigidity in the affected muscles; in fact, rigidity may be well marked without tremor, in the so-called "paralysis agitans sine agitatione." An attack of ordinary hemiplegia occurring in a patient with paralysis agitans arrests the tremor in the hemiplegic limbs, but if the hemiplegia clears up, the tremor may subsequently reappear.

Senile tremor is not unlike the tremor of paralysis agitans, but its onset occurs much later in life. Moreover, it begins bilaterally, especially in the head, jaw, and lips, and is unaccompanied by the characteristic rigidity of Parkinson's disease. Thus in a famous old admiral it began at the age of eighty-four as a gentle antero-posterior

tremor of the tongue, with a synchronous movement of the orbicularis oris. Both his hands had tremor and an interosseal attitude like that of paralysis agitans, but without rigidity.

In rickety children living in badly-lit rooms, especially during the second six months after birth, we sometimes observe a peculiar involuntary rotatory or nodding tremor of the head which usually comes on quite suddenly in winter-time and is known as **spasmus nutans.** It is generally accompanied by fine, rapid nystagmus, either horizontal, vertical or rotatory, which may be more marked in one eye than the other. If we fix the child's head, the nystagmus increases. The head movement is more often a lateral rotation than an antero-posterior nodding. It stops when the child's eyes are closed, either voluntarily or artificially. The symptom persists for six or eight weeks or longer, and then passes off, perhaps to return again in the following winter. It is not associated with any mental defect.

Head-rolling is another variety of involuntary rhythmic movement met with in children, chiefly below the age of two years. Many of the patients are rickety and a large proportion have otitis media, latent or evident.[1] The movement is more vigorous than that of spasmus nutans, it is unassociated with nystagmus, and it ceases when the child sits up, only occurring when he lies down.

Rhythmic tremor sometimes occurs in gross brain disease. Thus, for example, in cases of **lesions in the tegmental region** of the pons or crus cerebri,[2] affecting the *rubro-spinal tract* (which descends from the red nucleus into the lateral column of the opposite side), or in lesions of the *lenticular nucleus*, we occasionally observe a slow rhythmic tremor of the limbs of the opposite side, chiefly in the hand and foot. This tremor is increased by excitement or voluntary movement, but ceases during sleep. In the diagnosis of such cases we have, besides the tremor, the other localising signs of a gross destructive lesion. Thus if the ocular nuclei (which lie dorsal to the red nucleus) be affected, there is ocular palsy of the nuclear type; if the pyramidal tract be affected there is spastic hemiplegia; and if the sensory tract, traversing the internal capsule and optic thalamus, be implicated, we have hemianæsthesia. When a unilateral lesion of one crus cerebri produces oculomotor paralysis of one side with tremor of the opposite arm and leg, this is known as *Benedikt's syndrome.* Moreover, certain lesions of the optic thalamus cause loss of emotional mobility in the opposite side of the face in laughing or crying, with little or no weakness on voluntary movement.

[1] Still, *Clinical Journal*, Nov. 28, 1906.
[2] Holmes, *Brain*, 1904, vol. xxvii., p. 327.

Progressive lenticular degeneration, associated with cirrhosis of the liver, is a rare family disease which occurs in young people,[1] affecting the extra-pyramidal motor path (including both the large-celled pallidal system, derived from the lenticular nucleus, and the small-celled neo-striate system of the caudate nucleus and putamen). The disease is invariably progressive and fatal, usually within two to seven years. It is recognised by the presence of bilateral rhythmic tremors of the limbs, of paralysis agitans type, but increased on voluntary movement, together with marked hyper-tonicity of the limbs and face, the face being "set" in a spastic smile. Nevertheless, inasmuch as the disease leaves the pyramidal paths unaffected, there is no true motor paralysis, although voluntary movements are interfered with by the muscular rigidity. Sometimes spontaneous athetoid or choreiform movements are observed, differing in this respect from paralysis agitans. There is also dysphagia and dysarthria, and a degree of emotionalism, the spastic smile tending, on slight provocation, to become a spasmodic laugh. The optic discs, pupils, and cranial nerves are normal. There is no nystagmus. There are no sensory abnormalities. The deep reflexes are normal. The plantar reflexes are flexor in type and the abdominal reflexes are preserved. Post-mortem the lenticular nuclei on both sides are found to be degenerated, chiefly in the putamen and to a less degree in the globus pallidus, and in advanced cases there may be a cavity in each corpus striatum. The brain and spinal cord are otherwise normal. The liver shows intense multilobular "hob-nail" cirrhosis. **Pseudo-sclerosis** (see p. 261) closely resembles progressive lenticular degeneration in many of its clinical features, but has no family tendency, and runs a much slower course.

In some cases of tumour of the frontal lobe, there is a fine tremor in the upper limb when it is held horizontally forwards. The tremor in such cases affects the ipso-lateral limb; thus in a right-sided frontal tumour we may find tremor in the right hand.

Let us now pass to the irregular, non-rhythmic, spontaneous movements. Of these, ordinary "rheumatic" **chorea** furnishes one of the most striking examples. All are familiar with the irregular, jerking, wriggling, grimacing movements of a choreic child. They may affect the face, soft palate, tongue, trunk, limbs, and even the muscles of respiration. The movements of the limbs are often more marked on one side than on the other, and may be confined to one side—so-called hemi-chorea. Choreic movements occur spontaneously but are increased by emotion or by voluntary movements. They cease during sleep. The muscles of choreic limbs have a diminished

[1] Wilson, *Brain*, 1911, p. 295.

tonus (hypotonia). A good method of eliciting choreic movements in a slight case of the disease, is to make the child hold both hands above the head, when after a few seconds slight involuntary movements appear in the fingers of one or both sides.

Huntington's chorea is a hereditary variety of chorea with progressive dementia, which comes on after middle life and becomes steadily worse. It is associated with degenerative changes in the corpus striatum (especially in the small-celled neo-striatum system) and in the cerebral cortex of the frontal region.

Hyoscine chorea, whose symptoms are similar to those of ordinary chorea, occurs during acute intoxication with hyoscine, and is sometimes, but not invariably, associated with mild delusions.

The movements of **athetosis** or "mobile spasm" are different, occurring as they do most commonly in the spastic limbs of old-standing hemiplegics (chiefly after infantile hemiplegia). Athetosis never occurs in a limb which is completely paralysed, but only when some degree of voluntary power survives. It is probably due to over-action of the sub-cortical centres in the corpus striatum, which have been released from cortical control. The movements are usually confined to the upper limb, and consist of very slow, irregular, twisting movements, most marked in the fingers and wrist, but in severe cases affecting the forearm, elbow, shoulder, and even the lower limb, where the most common involuntary movement is a hyper-extension of the great toe. Only in bilateral athetosis (generally though not always, following diplegia) do the movements affect the face, causing hideous grimacing (see Fig. 54, p. 112). In a typical case the hand movements consist of slow flexion, then hyper-extension and spreading out of the fingers, irregularly, one after another. Combined with this, there is alternate abduction and opposition of the thumb, with flexion or extension of the wrist, and pronation or supination of the forearm. Fig. 44 is taken from a well-marked case of athetosis in which the movements affected all the joints of the upper limb. Athetosis is intensified by voluntary movement, whether of the paralysed limb, or of the opposite unaffected hand. It cannot be controlled by voluntary effort, and sometimes persists even during sleep.

Spontaneous **"associated movements"** occur involuntarily in many cases of hemiplegia. Thus the patient, when attempting to draw up the hemiplegic leg, involuntarily dorsiflexes the ankle and hyper-extends the hallux, or when flexing the fingers, he involuntarily dorsiflexes the wrist, and so on (see later, pp. 87 and 208)

In certain cases of hemiplegia and diplegia, involuntary movements of the limbs, especially of the upper limbs, can be produced

by changing the posture of the head, whether actively or passively.[1] These **conjugate automatic movements** are analogous to those observed experimentally in decerebrate animals.[2] In such animals the uncontrolled centres for reflex tonus in the pons, mid-brain, and medulla induce a heightened tonus in the extensor muscles of the limbs, constituting the so-called "decerebrate rigidity." Under these conditions, if the decerebrate animal's head be passively turned to one side or to the other, there occurs an exaggeration of the extension of the

FIG. 44.—Athetosis in a woman aged 29, the subject of right-sided hemiplegia of nineteen years' duration. There was severe paralysis of the right upper limb from the shoulder downwards. The figures show athetosis of fingers, wrist, and elbow.

limb towards which the animal's face is turned (facial limb) together with a diminution of the extension of the limb towards which the occiput is turned (occipital limb). Similarly, in certain cases of cortical diplegia, in which the strio-spinal centres are released from control, if the patient's head be turned to the right, we observe that the left upper limb slowly becomes tonically flexed, whilst the right becomes extended (see Fig. 140, p. 276). The phenomenon takes about a minute to reach its maximum. If we now turn the head

[1] Marie and Foix, *Revue neurologique*, 1914, p. 120.
[2] Magnus, *Münch. med. Wochenschrift*, 1912, No. 13.

to the opposite side, the attitude of the upper limbs becomes reversed. Similar phenomena are sometimes seen in hemiplegia, being limited, of course, to the hemiplegic limbs. Thus we may observe flexion of the hemiplegic upper limb when the face is turned away from the hemiplegic side, and extension of the hemiplegic limb when the face is turned towards the hemiplegic side.

Many healthy people make automatic extension movements of the upper limbs during the act of yawning. By the ancients these were termed **pandiculation.** Such movements are often well seen in the paralysed limbs in a case of severe hemiplegia when the patient yawns or is tickled, and the patient may harbour vain hopes of a return of motor power by observing extension movements of his paralysed fingers or elevation of the paralysed arm. Unfortunately these movements are not a hopeful sign in hemiplegia; on the contrary, they are due to uncontrolled activity of the strio-spinal system, and the more severe the lesion of the pyramidal tract, the more marked is the pandiculation. It does not occur in limbs which are the subjects of athetosis or other involuntary movements.

It is not uncommon, in cases of chronic organic hemiplegia, to observe involuntary **synkinetic movements** of the opposite non-paralysed limb during powerful voluntary efforts to move the paralysed limb. Still more frequently the converse condition is observed, in which a synkinetic movement of the paralysed limb occurs when the opposite non-paralysed limb is powerfully innervated. Thus when a hemiplegic patient executes any powerful movement of the non-paralysed limb against resistance, *e.g.* clenching the fist, extending the elbow, etc., the muscles of the hemiplegic limb may undergo involuntary contraction. The resulting movement exaggerates the pre-existing posture of contracture, *i.e.* the ordinary synkinetic movement is a flexion of the upper limb and generally an extension of the lower limb. In exceptional cases the lower limb becomes flexed. In every case, however, the attitude assumed by the limb is always the same for that particular patient. Synkinesiæ are much more easily elicited in contractured than in flaccid limbs.

A rarer type of synkinesia is *imitative synkinesia*, in which voluntary movements of one side of the body tend to be reproduced symmetrically on the hemiplegic side. This is best detected by making the patient alternately pronate and supinate the healthy limb and observing whether this gesture is reproduced by the hemiplegic limb.[1]

A degree of bimanual synkinesia may be physiological, especially in children, so that movements tend to be carried out bilaterally. Occasionally this condition persists into adult life. It may run in

[1] Marie et Foix, *Revue Neurologique*, Jan., 1916, p. 1.

families, when it is usually to be regarded as a stigma of a neuropathic inheritance.

Spontaneous movements also occur in cases of advanced **Friedreich's ataxia,** being most marked in the head, neck, and face. They commonly consist in irregular nodding movements of the head or grimacing, which has been called "nystagmus of the face." But in Friedreich's ataxia the most outstanding feature is inco-ordination of voluntary movements. The absence of the knee-jerks, the deformity of the feet, the scoliosis, etc., will all point to a correct diagnosis.

Fig. 45.—Tabetic pseudo-athetosis on closing the eyes.

Spontaneous movements, **pseudo-athetosis,** also occur in certain cases of **tabes** in which there is severe impairment of joint-sense and ataxia, with deficient muscular tonus. The movements are chiefly seen in the fingers and wrists, and can best be demonstrated by making the patient close his eyes and hold his hands steadily in the air with the fingers extended. In a few seconds we observe slow irregular flexion or extension movements of the fingers, which gradually assume curiously distorted attitudes, of which the patient is totally unaware. (See Fig. 45, also Fig. 170, p. 305, where similar movements have occurred in the lower limbs.)

Again, in **general paralysis of the insane,** spontaneous tremors of an irregular type are frequently observed, even when the patient is at rest. They occur chiefly in the face, especially if the patient be emotionally excited or just about to speak. Waves of fibrillary tremor appear, rippling along the muscles of the lips, tongue, and face. Irregular tremors of an intentional type are also frequently present, especially in the upper limbs. Their rhythm varies from 5 to 9 per second. They can often be demonstrated by asking the patient to write. Here we have other physical signs to guide us, *e.g.* the slurring articulation, the irregular or unequal pupils, frequently of Argyll-Robertson type, exaggeration or loss of the knee-jerks, the condition of the cerebro-spinal fluid, and the characteristic mental symptoms.

There is another great group of involuntary movements, which includes the habit spasms, the tics, and the reflex spasms. A proper classification of these is well nigh impossible, since the different varieties merge into each other. All are most common in people of "nervous" constitution, all are increased by emotion, and they cease during sleep. Slight degrees of **habit-spasm** may occur without any other sign of functional disease. Public speakers, such as clergymen, barristers, actors, and even medical lecturers, occasionally have little unconscious "tricks" of movement. A distinguished university professor has frequent clonic jerks of the frontales muscles, which suddenly elevate his eyebrows; a popular comedian makes rapid blinking movements of both eyes (blepharospasm) when he advances towards the foot-lights; a young lady has clonic spasms of both platysmata when her neck is exposed in evening dress at dinner parties, and so on. Such minor degrees of habit-spasm are usually bilateral and occur without any local exciting cause.

More severe varieties of habit-spasm are included under the term **"Tic."** A tic is of cortical, not reflex origin, and consists in the frequent explosive repetition of the same motor act—generally a violent, irregular one, such as rapid shaking or tossing of the head, grimacing, wriggling of the shoulder, etc. It passes off as suddenly as it comes on. Moreover, it does not interfere with voluntary movements. For example, however violent a tic of the right shoulder or arm may be, the patient's handwriting shows no abnormality. As Patrick[1] has put it, when the impulse to tic can no longer be controlled, the patient takes pen from paper, executes his tic and then resumes writing. At first sight, tic might be confounded with chorea. But chorea does not repeat the same movement regularly again and again. Patients who have severe tic usually show signs of mental degeneracy. This does not mean that they are necessarily deficient in intelligence. On the contrary, they are often "superior degenerates," bright and lively, but mentally immature, capricious, emotional, psychasthenic, and frequently the subjects of obsessions and various forms of "phobia." The greater the psychical abnormality, the more inveterate is the tic. "Tiqueurs" often have other evidences of the psychasthenic constitution, such as explosive articulation, "word-swallowing," sudden stoppage of speech, disordered respiration, echolalia (impulsive repetition of a particular word or phrase, or coprolalia (repetition of a blasphemous or obscene word).

Spasmodic torticollis is one of the commonest and most severe varieties of tic. Though the result of the movement is to jerk the head to one side, commonly to the left (see Fig. 46), the spasm is

[1] *Journal of American Med. Assoc.*, Feb. 21, 1905.

really a bilateral affair, since muscles on both sides of the neck, protagonists and antagonists, are employed to produce the movement. It is sometimes combined with a backward jerk, a so-called retrocollic spasm. The movement may be tonic, clonic, or a combination of the two—tonico-clonic. The patient can often curb the movement by means of some antagonistic measure of his own invention, *e.g.* by light pressure on the chin with his finger. Severe torticollis usually begins after middle life. At first occurring in paroxysms, it ultimately becomes continuous during waking hours, and the affected muscles become hypertrophied from over-use.

FIG. 46.—Spasmodic torticollis, with secondary hypertrophy of right sterno-mastoid.

Besides idiopathic spasmodic torticollis, which comes on apparently spontaneously, certain cases have a definite exciting cause and should be classed, not with the tics, but with the reflex spasms which we shall consider presently. Thus, for example, we may have *neuralgic torticollis*,[1] in which an occipital neuralgia or a painful tooth is followed by spasmodic torticollis, usually tonic in form. When the neuralgia passes off, the muscular spasm ceases also. Again, we may have *labyrinthine torticollis*,[2] due to chronic irritation of one of the semicircular canals. In such cases the torticollic spasm has the object of mitigating vertigo, which would occur if the head were not kept leaning over to the opposite side. A torticollis thus initiated may become inveterate, but some cases are cured by the administration of quinine. A small proportion of cases are examples of *professional torticollis*, occurring only at the moment of performing a special act, especially in cobblers and tailors, who have to turn the head and eyes to follow the needle. Such cases are more properly to be classed with the occupation-neuroses (see p. 249). Spasmus nutans, head-rolling, and other rhythmic movements (see p. 83), must not be confounded with true torticollis, in which the spasms are either tonic or irregularly clonic.

There is another group of movements which, originally excited by some peripheral irritation, are classed as **reflex spasms.** A spasm, unlike a tic, begins locally, perhaps in a single muscle, and spreads

[1] Cruchet, *Traité des Torticolis Spasmodiques*, Paris, 1907.
[2] Curschmann, *Deutsche Zeitschrift für Nervenheilkunde*, 1907, p. 305.

to adjacent muscles. When the exciting stimulus is unilateral, the reflex spasm is usually unilateral also, but not invariably so, for bilateral reflex spasms also occur, as in tonic and clonic contraction of the orbiculares oculorum (blepharospasm), the result of corneal or conjunctival inflammation, or as in the case where a vaginal caruncle or anal fissure produces vaginismus with bilateral adductor spasm. Of the unilateral reflex spasms one of the most striking is the intense facial spasm which occurs in severe cases of trigeminal neuralgia or **tic douloureux,** which is not a true tic but a reflex spasm. In this disease the patient has paroxysms of agonising pain in one or more divisions of the trigeminal nerve. During a paroxysm, the face on the side of the pain is thrown into strong tonic contraction, the eye is closed, the mouth is drawn up on the affected side, and the patient often presses his hand desperately over the site of pain. Only when the acute stage of the paroxysm passes off do the facial muscles relax.

FIG. 47.—Left-sided facial hemi-spasm.

Less severe paroxysmal **facial hemi-spasm,** either tonic or clonic, usually commencing with waves of flickering fibrillary movement, especially in the orbicularis oculi, closely resembling the movements produced by faradic stimulation and implicating some or all of the facial muscles, may arise from other reflex causes, generally in the territory of the fifth nerve, such as a decayed tooth, a non-erupted wisdom-tooth, a nasal polypus, etc. Facial hemi-spasm, unlike tic douloureux, is painless. Occasionally it occurs primarily, without apparent cause, as in the patient shown in Fig. 47. It also occurs, less frequently, in lesions of the facial nerve itself, as, for example, when tumours (especially of the cerebello-pontine angle) or abscesses compress the nerve. Sometimes it follows an attack of ordinary facial palsy; less commonly it may precede its onset. Therefore in every case of facial hemi-spasm we should search for local lesions in the territory not only of the trigeminal but also of the facial nerve.

Sometimes a reflex spasm may persist as a habit-spasm, long after the original exciting cause has passed away. Such cases can usually be diagnosed by their history. For example, a lad lost his left arm by avulsion in a machinery accident. The stump was amputated at the shoulder-joint, but clonic spasms appeared in the trapezius and scapular muscles, and these persisted even after all the posterior nerve-roots in that region were divided by operation. Cases of "shivering stump" after amputation in war-time are often due to irritation at the cut ends of the nerves. Others may be examples of local tetanus (see later, p. 509).

FIG. 48.—Right-sided blepharospasm.

Certain well-marked types of blepharospasm sometimes follow shell-explosions in war. In one variety the retinæ, owing to the intense flash of the bursting shell, are over-stimulated and become hyperæsthetic. The patient endeavours to protect them from light by a vigorous blepharospasm, which may be bilateral, or, more commonly, unilateral. In other cases, again, particles of dust are driven into the conjunctivæ by a missile landing close in front, and here also a reflex blepharospasm results, as in the patient shown in Fig. 48. This lad was struck by a fragment of bomb in the right frontal region, producing only a superficial abrasion. His right eye, however, was blind for five days, and subsequently remained closed for over a month by spasm of the orbicularis, the right eyebrow standing at a lower level than the left. On forcibly opening the lids, there was acute photophobia, accompanied by spasmodic contraction of the orbicularis. The pupil was slightly larger than on the left side, but reacted normally to light, whilst the external ocular movements were normal.

In any variety of blepharospasm, if we forcibly open the lids, the vision is usually found to be little affected, but photophobia is generally intense. The blepharospasm may persist for periods varying from a few hours to several months.

Fig. 49 shows a case of reflex ulnar spasm in a blacksmith who sustained a severe jar of the left elbow when holding an iron bar which was being hammered by a fellow-workman. The muscles of the left hand at once became weak. Five months later, tonic spasm gradually set in, limited to the intrinsic muscles of the hand supplied by the ulnar nerve. From contraction of the interossei the fingers were tightly adducted, whilst the hypothenar muscles produced opposition of the little finger. When examined a year after the accident, this tonic spasm still persisted, and there was blunting of sensation to cotton-wool and pin-pricks in the ulnar territory of the hand, with loss of vibration-sense in the two ulnar fingers. Prolonged massage and electrical treatment to the limb having failed to produce improvement, the ulnar nerve at the elbow was injected with normal

Fig. 49.—Reflex ulnar spasm.

saline solution containing a little cocaine. The spasm was promptly relieved, and a week later no sensory or motor abnormality could be detected (see "Reflex Paralysis," p. 239).

But other cases occur, even of unilateral spasm, without any reflex exciting cause or the history of one, and they are difficult to classify.

Thus a lady whose menopause occurred at the age of forty-five, at the same time also lost most of her property through the failure of a bank. She gradually developed clonic spasm of the left facial muscles. At first, this consisted merely in a slight flickering of the lower lid for a second or two, every few days, but the condition gradually increased in severity until when she came under observation thirteen years later, the spasms affected all the facial muscles on one side, beginning as a flickering movement, and then becoming tonic and lasting from twenty to thirty seconds at a time, the eye being closed, the eyebrow elevated, the angle of the mouth drawn outwards, and the platysma thrown into strong contraction. In the intervals between attacks the face was symmetrical. Under treatment by bromides and galvanism this patient rapidly became better.

Hysterical Tremors following Shell-Explosions.—Some of these tremors occur in patients who have had cerebral concussions; others in soldiers who have had the emotional shock of an artillery bombardment

without any physical concussion or other injury. Generalised tremor in a few instances begins when the patient is actually at his post in the trenches: this is really an emotional reaction. Much more frequently it develops when he is admitted to hospital, especially if he is in the same ward with other cases of war-neuroses. This hysterical tremor may affect arms and legs, sometimes the head also; and is of a coarser, violent type, aggravated by emotion, by voluntary movement and by loud noises. In other cases the tremor is limited to a single limb or part of a limb. Isolation, combined with curative suggestions and with repeated passive movements of the affected limb until the muscles have become relaxed, benefits these cases, and their prospects of ultimate recovery are good.

Finally, there are numberless varieties of **hysterical spasms** apart from the hysterical "fits," which have already been discussed. We can only refer to some of the commoner types. Thus *saltatory spasm* consists of a series of jumping or skipping movements, which occur whenever the patient assumes the erect posture. A similar spasm, less severe in degree, may produce paroxysms of trembling in the legs, as in a hysterical girl of nineteen with many other manifestations of hysteria, in whom the spasms ceased at once when she lay down. All sorts of movements, however, may occur in hysteria, simulating almost any kind of tremor. For instance, a hysterical woman of twenty-one had constant movements of the face, left arm, and both legs, resembling those of athetosis, but very much faster. In her case typical hysterical contractures and segmental anæsthesia of the hysterical type, together with the normal state of the reflexes, aided in the diagnosis of hysteria, which disease will be further considered in a subsequent chapter.

CHAPTER VII

APHASIA

We exchange ideas with our fellow-men chiefly by means of speech. To speak is not merely to utter words. Speech is a psychical process consisting in the construction of propositions. Speech possesses an arbitrary code of signals, vocal or written. These signals are perceived by our auditory or visual centres. Every country has its own particular code or language, which is learned by each of its inhabitants. Gestures and mimic movements, as a means of communication, although international, have a very limited field of usefulness as compared with speech or propositionising. Two individuals, each ignorant of the other's language, can certainly communicate with each other after a fashion by means of gestures alone, yet they cannot express many ideas in this way, but only simple primitive emotions, such as pleasure, anger, surprise, and so on, or pantomimic imitations of certain acts.

There are three chief classes of cases in which the functions of articulate speech may be lost. Firstly, there are conditions in which the patient's higher intellectual functions are in abeyance, either congenitally as in idiots, or from disease as in acquired dementia, coma, stupor, or in certain cases of hysteria. Such patients are speechless, but they are not aphasics. Secondly, there are the cases where the higher intellectual centres are capable of function, but the cortical speech-centres which control the motor acts of speaking and writing, or the sensory processes of recognising spoken or written words, are diseased, and yet the patient has not necessarily any paralysis of the peripheral organs of speech, nor is he necessarily deaf or blind. To this group the term "aphasia" is applied. Lastly, there are the cases where, with intact intellectual functions and normal cortical speech-centres, there are defects in the peripheral organs of articulation, so that the patient is unable to articulate distinctly—for example, cases of cleft palate, post-diphtheritic palsy of the palate, facial or hypoglossal paralysis, bulbar paralysis, and so on. These are affections, not of speech proper, but of articulation.

Aphasia may be defined as impairment or loss of speech due to the loss of memory for those signs, vocal or written, by means of

which we exchange ideas with our fellow-men. An aphasic, unless his higher intellectual centres are impaired, usually preserves his powers of gesture and of pantomime. Aphasia is due to disease, organic or functional, of certain well-defined special centres in or near the cortex of the brain. These cortical centres exist on both sides of the brain, but ordinarily in right-handed people the speech-centres on the left side of the brain are predominant.

Let us consider the speech-centres somewhat more in detail. For the interchange of ideas two distinct processes are required—one sensory, the other motor. The sensory process includes the hearing and understanding of spoken words, and also the seeing and understanding of written or printed letters. The memories of words

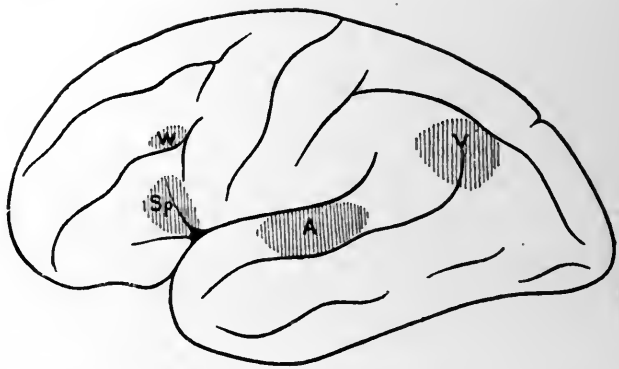

FIG. 50.—Diagram of left cerebral hemisphere, showing approximate positions of the centres concerned in speech.

A. Auditory word-centre. } Sensory.
V. Visual word-centre. }
Sp. Vocal word-centre. } Motor.
W. Motor centre for writing. }

heard and seen are stored up in specialised parts of the auditory and visual centres, named respectively the auditory word-centre and the visual word-centre (Fig. 50). The auditory word-centre is at the upper or Sylvian surface of the temporal lobe (anterior transverse gyrus of Heschl, Flechsig's "auditory gyrus") and in the adjacent posterior end of the first temporal convolution. The visual word-centre (in individuals who have learned to read) is in the angular gyrus. Either centre may be diseased; so that we have two varieties of sensory aphasia, or aphasia of comprehension, viz.—**auditory aphasia** and **visual aphasia.** Then there is in speech the motor element, consisting of the motor act of expressing ourselves in words, either vocally or by means of writing. The memories of these motor acts of vocal speech are usually supposed to be stored up at the posterior end of the inferior frontal (Broca's) convolution, and in the adjacent part

of the pre-central convolution and of the insula. If this centre be destroyed, **motor aphasia** (aphasia of expression) or **aphemia** results, the patient being unable to utter words of which his motor memories have been destroyed.

Marie, however, has recorded cases of destruction of Broca's convolution without any speech defect, and denies that it has any special importance in the mechanism of speech. He considers that cases of so-called motor aphasia are really examples of ordinary sensory aphasia combined with articulative difficulty (anarthria or dysarthria) due to a lesion of the lenticular nucleus and its surrounding white matter; and maintains that isolated lesions of Broca's convolution are accidental and of minor significance.

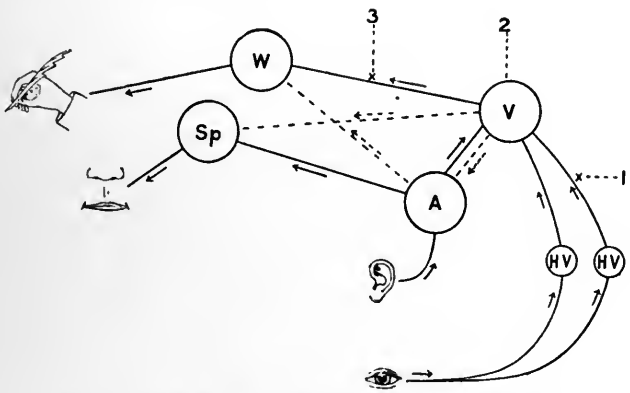

FIG. 51.—Diagram of speech-centres (after Bramwell).
A. Auditory word-centre. V. Visual word-centre.
Sp. Motor vocal word-centre. W. Motor centre for writing.
HV. Half-vision centre.
The interrupted lines indicate possible but less habitual routes for transmission of impulses.

Earlier writers used also to describe a separate centre for writing (independent of the vocal word-centre), a lesion of which would produce loss of the faculty of writing—**motor agraphia.** But no case has been verified pathologically in which a focal lesion has produced pure agraphia without affection of vocal speech, so that the writing-centre, although it may be represented diagrammatically in a theoretical scheme of cortical speech-centres, is probably merely a part of the ordinary psycho-motor centre for the upper extremity.

Fig. 51 is a scheme of the connection of the various centres concerned in speech. Let us first notice that the motor vocal word-centre is subservient to the auditory word-centre, and that the writing-centre is similarly subservient to the visual word-centre. A child first learns to speak by hearing spoken words and then imitating them. Therefore speech is at first entirely auditory in origin. Later, in learning to read, the meaning of each word is learned by associating

the letters seen with words heard spoken, so that the auditory word-centre acts as the instructor of the visual word-centre.

In most people, during the process of silent thought, words are revived primarily in the auditory word-centre, and there is usually a simultaneous revival of the same words in the visual word-centre. But in other people the revival in the visual word-centre comes to be of greater importance. Accordingly we may classify people into "auditives" and "visuals" according to their mode of revival of words in thought. Most of us are "auditives." Simultaneous revival of word-images in several speech-centres makes our comprehension of the idea more perfect. Thus a difficult concept is better understood if we read it aloud, because this involves the activity of the visual, auditory and vocal word-centres.

Aphasia commonly results from organic disease of one or more of the cortical speech-centres, or of the sub-cortical fibres connecting them. The most frequent organic causes are embolism, hæmorrhage, or thrombosis, cerebral abscesses and cerebral tumours. In war-time traumatic lesions of the speech-centres are common. The differential diagnosis between these various conditions depends largely on the history; embolism producing the symptoms suddenly, hæmorrhage taking several minutes, thrombosis taking perhaps hours, abscesses being more gradual in onset and tumours still more so. But we also meet with cases of temporary or functional aphasia, sometimes from mere debility or exhaustion, sometimes from localised vascular spasm, sometimes following a "congestive attack" in general paralysis or an epileptic fit, or accompanying a paroxysm of migraine, or an attack of uræmia.

In investigating a case of aphasia we should first note whether the patient has other signs of gross cerebral lesion, such as hemianopia, or hemiplegia, and should inquire whether he is naturally right- or left-handed. Most children are taught to write with the right hand, whether they are right-handed or not, and therefore in determining this point we inquire with which hand a man draws a cork, throws a stone, etc.; or if a woman, with which hand she combs her hair or threads a needle; or, in either sex, which hand is used in cutting bread.

The following series of inquiries (based on Beevor's scheme) should then be made. The capital letters in parenthesis indicate the parts of the brain involved in each case.

1. Can the patient spontaneously utter intelligible words? **(Sp.)** Note the extent of his vocabulary. Can he pronounce all words or only a few? Get the patient to talk spontaneously, and observe whether he talks fluently or misplaces words or syllables, whether

he talks in disjointed phrases ("telegraphic" type of speech), or whether he talks unintelligible jargon.

2. Can he understand words which he hears? (**A.**) Ask him to touch his nose, ear, eye, chin, etc., in turn, thus testing his interpretation of nouns. Then ask him to smile, whistle, shut his eyes, etc., thus testing his comprehension of verbs. Sometimes we find that the patient executes the first command correctly, but continues to repeat the same act in response to different commands. A patient can sometimes sing the words and air of a song, when he is unable to repeat the words in a speaking voice.

3. Can he understand written questions or commands which he sees? (**V.**) Write down and show him simple sentences, such as "How old are you?" "Put out your tongue." "Give me your left hand."

4. Can he write spontaneously? (**W.**) If his right hand is paralysed, let him try with the left. Observe whether he writes intelligibly, whether he misplaces words or syllables, or whether he scribbles meaningless signs.

5. Can he copy from printed to written letters? (**V→W.**) Print some word such as "Hospital" or "Monday," and get him to copy this.

6. Can he write to dictation words which he hears? (**A→V→W.**)

7. Can he pick out objects of which he hears the name? (**A→V.**) Place in front of him a heap of objects, such as a key, a shilling, a match, a pencil, and ask him to pick out each in turn.

8. Can he repeat words heard? (**A→Sp.**) Try him first with simple words and phrases, *e.g.* "cat," "dog," "nurse," "good-morning," etc.

9. Can he name objects seen, and can he read aloud from words shown to him? (**V→A→Sp.**) Point to different objects (*e.g.* pencil, cigar, watch) and ask him what they are.

10. Does he understand gestures and pantomimic movements? Without speaking to him, get him to imitate you when touching the nose, spreading out the fingers, protruding the tongue, etc.

Auditory Aphasia, or **Word-Deafness.**—The patient in this case is not deaf, but simply word-deaf. He hears ordinary sounds and noises, but spoken words are not understood; they sound to him like an unknown tongue. The character of the symptoms varies according as the lesion of the temporal lobe is sub-cortical or cortical in position.

(*a*) **Sub-cortical,** or **Pure Auditory Aphasia.**—This is extremely rare (Marie, in fact, denies its existence). Here the lesion simply blocks

the way-in for spoken words. The patient therefore has word-deafness, *i.e.* he is unable to understand what is said to him; he is also unable to repeat spoken words or to write from dictation. But the auditory word-centre being still intact, he possesses all his memories of auditory speech, and therefore spontaneous speech is perfect. Moreover, the visual word-centre being in normal working order, he is still able to read, and, as a matter of fact, reading is his only means of receiving messages from other people. A deep-seated lesion of the temporal lobe may interrupt the optic radiations. The patient then has a superadded hemianopia, but without hemianæsthesia or hemiplegia.

(*b*) **Cortical Word-Deafness.**—This is much commoner than the other variety. Here the lesion involves the cortical centre itself, and the auditory memories of spoken words are obliterated. And therefore, in addition to the previous defects of word-deafness with inability to repeat spoken words or to write from dictation, there are other symptoms due to the fact that the motor speech-centre is no longer controlled by the auditory word-centre. Internal speech and thought are impaired, and so the patient makes mistakes whether in speaking spontaneously or in reading aloud. He also makes mistakes in writing, especially in spelling. He talks fluently enough, it is true, but he tends to mix up his words or syllables, and in a severe case may jabber unintelligible jargon. Word-deafness renders the patient unaware of his own errors. This, as we shall see, is in marked contrast with motor aphasia, where the patient recognises his own mistakes as soon as he has uttered them. If the lesion of the auditory word-centre be incomplete, or in cases which are in process of recovery, the word-deafness and resulting errors of speech are also partial. These latter may, in a slight case, be confined to inability to name objects, *i.e.* nouns, the patient being still able to express abstract ideas. Thus a partially word-deaf patient, who is unable to name a knife shown him, may say, "It is for cutting." Or again, partial word-deafness may produce simply confusion of words; the patient may say one word when he means another (*paraphasia*). It rarely happens that word-deafness remains permanent and complete; the auditory word-centre in the opposite hemisphere generally compensates, to some extent, as time goes on.

The aphasic patient usually shows evidences of intellectual deficiency. His power of attention is diminished; his memory is impaired, and he is unduly emotional and irritable. The extent of mental disturbance in word-deafness varies according to whether the patient be a strong "auditive" or a strong "visual." In the latter case the mental impairment is much less than in the former, and the disturbances of motor speech are but slight.

COLLEGE OF MEDICAL EVANGELISTS

The auditory and visual word-centres are fairly close together, and more than this, they are supplied by the same branch of the middle cerebral artery (see Fig. 32, p. 42); so that it is not uncommon for a single arterial lesion, *e.g.* a thrombosis, to affect both centres together and to produce a combination of word-deafness and word-blindness.

Visual Aphasia, or **Word-Blindness (Alexia).**—In word-blindness the patient can see, but cannot understand, printed or written characters. They appear to him like strange hieroglyphics. He sees the shape of the letters, but they convey no meaning to his mind.

Here, as in word-deafness, the symptoms vary in degree. The patient may be unable to recognise a single letter (letter-blindness), or he may be able to spell out the letters singly but unable to read syllables or words. Often a patient who is unable to read any other word, can recognise his own name. Frequently he retains the power of recognising numbers and of doing addition, subtraction, and multiplication sums. We have to recognise two varieties of word-blindness, according as the lesion is cortical or sub-cortical in position.

(*a*) **Sub-cortical,** or **Pure Word-Blindness.**—Here the way-in for visual word-impressions is destroyed, the visual word-centre remaining intact. The patient cannot understand written or printed words, nor can he read aloud, but he still retains the power of writing spontaneously and from dictation; and therefore he can express his thoughts perfectly in writing, but is unable to read what he has himself written. Inasmuch as a sub-cortical lesion, in order to produce word-blindness, must be beneath the angular gyrus and in such a position as to cut off the afferent visual impulses from both half-vision centres to the visual word-centre in the angular gyrus, it will necessarily implicate the optic radiation to some extent. And therefore a pure or sub-cortical word-blindness, is always associated with (right-sided) hemianopia or, when partial, with (right-sided) hemi-achromatopsia (Fig. 52).

(*b*) **Cortical Word-Blindness.**—In this variety, in addition to the symptoms just described, there is loss of the memories of written or printed words, and therefore, inasmuch as the visual word-centre, which controls the writing-centre, is destroyed, the patient has **agraphia** of sensory origin. He is unable to write spontaneously, to copy from printed into written characters, or to write from dictation. If the lesion of the visual word-centre be partial the alexia and agraphia are also incomplete, and mistakes in writing may amount simply to the writing of wrong words, syllables or letters—so-called "*paragraphia.*"

These points are illustrated by Bramwell's well-known diagram

(Fig. 51), in which a lesion at the position marked 1, destroying fibres passing from one half-vision centre to the visual speech-centre, would not produce word-blindness. A lesion at 1, destroying fibres passing from both half-vision centres to the visual speech-centre, would produce word-blindness but not agraphia, since the visual speech-centre is unaffected and is able to influence the motor writing-centre. A lesion at 2, destroying the visual speech-centre, would produce word-blindness and agraphia. A lesion at 3 would produce agraphia (unless the motor writing-centre could be brought into action in some roundabout way), but not word-blindness, the visual speech-centre being intact.

Motor Aphasia.—In this variety the patient has lost the power of expressing himself by spoken words. He can neither speak spontaneously nor can he read aloud. And yet (unless the motor speech-centres on both sides of the brain are destroyed) he is not absolutely dumb. As Hughlings Jackson puts it, the patient is speechless, but as a rule not wordless. He can usually utter intelligently a few words of "propositional" value, such as "yes" and "no" (by means of the speech-centre on the uninjured side ?). In addition he may have other words or phrases, mostly interjections of merely emotional significance, such as "yes," "no," "oh my !" "damn !" "by Jove !" —so-called "recurrent utterances"—which he utters automatically when excited, or when making an effort to speak. A patient who recovers soon from his aphasia loses his recurrent utterance, and "becomes able not to utter it," *i.e.* the higher centres regain control and prevent the over-action of lower centres.

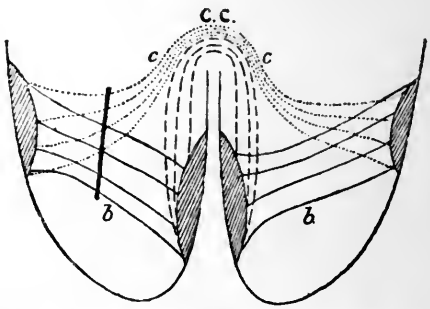

FIG. 52.—Diagram representing a lesion (indicated by thick black line) which produces pure word-blindness (Bastian).

C. C. Posterior extremity of corpus callosum.
c. c. Commissural fibres connecting the two visual word-centres.
b, b. Fibres connecting each half-vision centre with the visual word-centre of the same side.

Sometimes a patient who cannot speak in the ordinary way may be able to sing the music, and even the words, of a song. This is

probably accomplished by means of a motor singing-centre, situated on the right side of the brain, at the posterior end of the second frontal gyrus.[1] Lesions of this singing-centre may cause loss of the power of singing, or whistling, melodies, without any ordinary aphasia.

A patient who has motor aphasia, unlike a word-deaf person, is conscious of his own errors.

(*a*) **Sub-cortical, or Pure Motor Aphasia.**—Here the patient, though intelligent and able to understand spoken and written language (by means of his uninjured auditory and visual word-centres), cannot utter spoken language, whether spontaneously by reading aloud or by repeating what he hears. This is because the way-out for spoken speech is blocked. But his mental speech-processes are unimpaired, and if the outgoing fibres from the writing-centre are unimpaired, he is able to express himself in writing, as in the biblical case of Zacharias, the father of John the Baptist (St. Luke, i. 62, 63), and in many cases the patient can indicate by signs how many syllables or letters are in the word which he desires to speak but cannot utter. This variety of aphasia sometimes occurs in hysteria. The hysterical aphasic cannot utter any sound whatever, whether articulate or not. Recovery from hysterical aphasia, under the influence of strong suggestion, may occur suddenly and sometimes completely. Zacharias was probably a hysterical aphasic.[2]

(*b*) **Cortical Motor Aphasia.**—This type, in which the lesion is supposed to be limited to the cortical motor speech-centre in the inferior frontal gyrus and adjacent grey matter of the insula and pre-central gyrus, is less securely established than the other varieties. (Marie denies its existence altogether.) The patient in this variety has not only all the defects of a sub-cortical case, which we have just considered, but, in addition, his mental processes of internal thought are impaired, since the co-ordination of memories of words spoken and written by himself is impaired. He has therefore difficulty in understanding complicated sentences, whether spoken or written. Together with difficulty in vocal speech there is often (though not always) associated a similar difficulty in writing—*agraphia*—proportional to the defect of speech.

Pure isolated agraphia, without any other symptom, does not occur, and as we have seen, the commonest variety of agraphia is that due to cortical word-blindness. The study of agraphia due to sensory aphasia is easier than that associated with motor aphasia

[1] Mann., *Monatschrift für Psychiatrie*, 1898, Bd. iv.; K. Mendel, *Neurologisches Centralblatt*, 1916, p. 354.

[2] "And his mouth was opened immediately, and his tongue loosed, and he spake, and praised God."

because in sensory aphasia there is no necessary motor paralysis of the right arm or hand, whereas sometimes in motor aphasia the hemiplegic patient has to make his attempts at writing with the left hand.

Such are the chief types of aphasia. Clinically, however, it is commoner to meet, not with pure auditory, visual, or motor aphasia, due to a small focal lesion, but with combinations of these, or with total aphasia, the result of a larger destructive lesion implicating several or all of the speech-centres. Such severe aphasias, of course, produce a more profound degree of mental deficiency, and inasmuch as the same artery, the middle cerebral, supplies not only the speech-centres, but also the other cortical motor areas and the corpus striatum (see Figs. 32 and 33), total aphasia is usually combined with severe right hemiplegia.

Hysterical aphasia is usually accompanied by other manifestations of hysteria, and especially by hysterical hemiplegia. It is paradoxical and polymorphic, and usually differs from organic aphasia in some curious fashion, according to the caprice of the patient. Thus, for example, a patient with hysterical aphasia may also have peculiar tricks of intonation or of accent.

Marie,[1] whilst admitting the existence of visual, auditory and motor aphasia as clinical syndromes, denies the existence of diagrammatic visual, auditory and motor speech-centres, and attributes all aphasic phenomena to intellectual deficiency from disintegration of some part of Wernicke's zone (which consists of the gyri surrounding the extremities of the Sylvian and the parallel fissure), which zone he regards as an intellectual area. According to Marie the essential fact of aphasia, of whatever variety, is insufficient comprehension of speech. He adduces evidence to show that Broca's convolution plays no special part in the function of speech except in so far as it contains certain motor centres for the face, tongue and larynx. In fact he discards a special vocal-word centre just as others discard a motor centre for writing. The syndrome of motor aphasia is explained by him as due to intellectual deficiency *plus* articulative anarthria, this latter being due to a lesion of the lenticular zone (comprising the lenticular nucleus and its surrounding white matter). In other words, he regards motor aphasia simply as a sensory aphasia *minus* the power of speech. The intellectual processes of speech in right-handed patients are localised in the left hemisphere, whereas anarthria may be produced by a lesion of either lenticular zone.

But though seductive in their simplicity, there are certain obstacles to accepting Marie's views in their entirety. Even supposing that the only real varieties of aphasia are sensory, and admitting that some defect of intelligence is present in every case, it seems none the less probable that visual and auditory speech-centres do exist, and that lesions of these centres, rather than mere intellectual deficiency, are the cause of the well-defined clinical types of sensory aphasia. As Dejerine has urged, we may have advanced dementia from undoubted cortical disease, as in general paralysis,

[1] *Semaine Médicale*, 1906, Nos. 21, 42, and 48.

without any aphasia whatever, sensory or motor. It therefore seems probable that the diminution of intelligence which is seen in aphasic patients is due to interference with cortical sensorial processes, producing disruption of the cerebral mechanism of speech, rather than that the aphasic phenomena should be regarded as secondary to intellectual defect.

With regard to Marie's conception of motor aphasia as a mere combination of intellectual deficiency with anarthria, it may also be objected that this theory fails to account for the presence of well-articulated "recurrent utterances" such as are present in most patients with complete motor aphasia. If anarthria alone were the cause of the speech-loss, it ought to render the articulation of all words difficult. Moreover, the cortical vocal-word-centre is not limited to Broca's convolution, but probably extends into the insula and to the neighbouring part of the pre-central gyrus. So that there is no insuperable difficulty in the existence of a lesion limited to Broca's convolution unaccompanied by aphasia.

Apraxia is the inability to execute certain familiar purposive movements with the limbs, when there is neither motor paralysis, sensory disturbance, nor ataxia of the limb, nor any intellectual impairment. It is tested by handing the patient objects—such as scissors, key, comb, drinking-glass, button-hook, a pack of cards, a box of matches, etc.—and observing whether he knows how to use them. Apraxia of the muscles of the limbs is analogous to motor aphasia of the speech-muscles. Certain functions, comparable to the functions of speech, have their cortical centres situated in the first and second frontal gyri of the left hemisphere, these centres being connected with the corresponding centres in the right hemisphere by means of the anterior fibres of the corpus callosum.

Apraxia may be either sensory or motor in type. Thus if an apraxic patient be handed a tooth-brush or a key, and asked "How do you use this?" he may put it in his mouth and try to smoke it like a cigar. Such apraxia is *sensory* in origin, due to failure of recognition (agnosia). On the other hand, suppose he recognises it as a tooth-brush or a key and that he may even name it and tell what it is for, but when asked to use it he fumbles aimlessly with it, his apraxia is *motor* in type. To take another example, motor apraxia of the tongue is often seen in a hemiplegic patient who fails to protrude his tongue when told to do so, but can still lick his lips unconsciously. Sometimes the apraxic patient cannot perform a given series of purposive movements unless he has the sensory stimulus of the object in his hand, with which the movements are associated. For example, an apraxic cornet-player could not purse up his lips to blow the instrument unless he had the actual mouthpiece at his lips. Agraphia, which we have already described, is to be regarded as a variety of apraxia, and may be either of sensory or of motor origin.

Over 95 per cent. of people are right-handed. In them the left cerebral hemisphere is the dominant one and, besides controlling the

limbs of the right side of the body, it exercises a potent influence upon the right cerebral hemisphere by means of the commissural fibres of the corpus callosum. Thus many movements of the left limbs are initiated by the left hemisphere, so that a left-sided cortical or sub-cortical lesion, if implicating the corpus callosum, may produce not only right-sided hemiplegia or monoplegia, but also apraxia of the non-paralysed left hand. Such apraxia of the ipso-lateral hand is evidence of a lesion of the fibres of the corpus callosum. Apraxia is associated with lesions of the left hemisphere much oftener than with right-sided lesions.

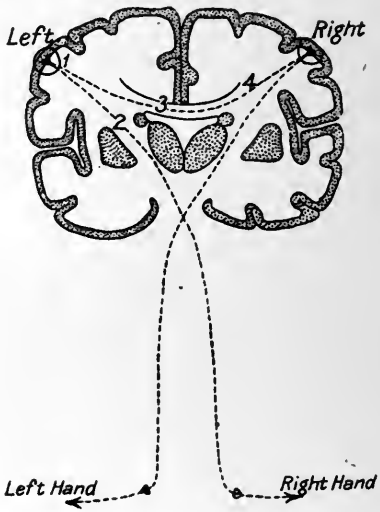

FIG. 53.—Diagram illustrating relation of corpus callosum to apraxia.

Fig. 53 is a diagrammatic representation of the above-mentioned points, which shows that:—

1. A left-sided cerebral lesion at or close beneath the arm-centre produces right monoplegia or hemiplegia, whilst the left arm becomes apraxic.
2. A lesion of the left internal capsule, where the commissural fibres are uninjured, causes right-sided hemiplegia, without apraxia.
3. A lesion of the corpus callosum (or of the left centrum ovale implicating callosal fibres) will cause left-sided apraxia (from loss of the guidance of the left arm-centre over the right), without hemiplegia on either side.
4. A lesion of the right frontal lobe may interrupt the callosal fibres passing from the left to the right arm-centre without injuring the pyramidal fibres from the right centre to the left hand. In such a case we have a left-sided apraxia from a right-sided lesion.

CHAPTER VIII

DISORDERS OF ARTICULATION

It is necessary to distinguish clearly between speech and articulation. Speech is a cortical function, articulation is mainly bulbar.

Disordered articulation, or **dysarthria,** signifies difficulty in performing the co-ordinated muscular movements necessary for the production of the consonants and vowels which go to form syllables and words.

In simple dysarthria there is no affection of the cortical centres or paths which are concerned in the processes of speech proper. A patient, for example, who has advanced bulbar palsy, even when he is unable to articulate a single word, is not, strictly speaking, speechless. He is inarticulate, which is quite a different thing. His mental speech-processes remain normal, he can still express himself fluently in written speech, and he is able to understand everything he hears or sees.

The peripheral mechanism of vocal speech is partly musical (or voiced), consisting in vibration of the approximated vocal cords. It is also partly consonantal (or voiceless), consisting in the co-ordinated action of numerous muscles of the lips, tongue, palate, and pharynx. The term "articulation" is specially applied to the mechanism of consonantal pronunciation.

To test a patient's power of articulation, we listen to his ordinary conversation, or we ask him to read aloud a passage from a book or newspaper, and notice how he pronounces his words. Then, if he shows any abnormality in connection with particular consonants, we ask him to repeat "catch" words, chosen so as to present special difficulties, *e.g.* "British constitution," "biblical criticism," "West Register Street," "hippopotamus," "Burgess's fish-sauce shop." With a French patient useful catch-phrases are "école polytechnique," "chasseur, sachez chasser!" "chirurgien du trente-troisième d'artillerie."

Difficulties of articulation are the result of defects, consisting either in paralysis or inco-ordination, of certain groups of muscles in the lips, tongue, palate, pharynx, or larynx. The underlying defect may either be in the bulbo-muscular neurones (comprising the

pontine and medullary nuclei, the peripheral motor nerves and the muscles), or it may be due to supra-nuclear affections in the cortico-bulbar neurones, at some point between the higher speech-centres and the bulbar nuclei. Or it may be due to ataxia of the organs of speeh.

Infra-nuclear and Nuclear Affections of Articulation.—Articulation may be impaired as a result of paralysis of any of the motor nerves or nuclei supplying the articulative muscles.

Unilateral hypoglossal paralysis (as in the case of a business man shown in Fig. 84, in whom this nerve was divided by a stab in the neck dealt by a discharged employé) produces motor paralysis followed by atrophy of the corresponding half of the tongue. The paralysed half-tongue feels to the patient as if he had a foreign body in his mouth. This makes his articulation clumsy, lisping and indistinct, especially in the case of linguo-dental (S, Z, Th) and of anterior linguo-palatal consonants (T, D, L, R). But after a few days the patient becomes accustomed to the feeling of his palsied half-tongue, and his articulative difficulty to a large extent disappears.

Facial palsy, from its affection of the lips, renders labials (P, B) and labio-dentals (F, V) indistinct, especially so when the palsy is bilateral.

Bilateral paralysis of the palate, *e.g.* post-diphtheritic paralysis, and syphilitic perforation of the palate, produce the same articulative difficulty as in congenital cleft palate, inasmuch as the nasal cavity cannot be shut off from the mouth. As a result the voice is nasal, and certain consonants are altered (B becomes M, D becomes N, K becomes Ng, and so on), so that articulation as a whole is indistinct. This indistinctness of articulation is increased when the patient stoops forwards: it diminishes or even disappears on lying with the head thrown backwards, since in the latter position the paralysed soft palate tends to fall back by its own weight and shuts off the naso-pharynx.[1]

Total paralysis of the palate is also associated with difficulty in deglutition, especially with liquids, which during the act of swallowing regurgitate into the naso-pharynx and escape through the anterior nares.

Unilateral paralysis of the recurrent laryngeal nerve, if complete, renders the voice hoarse, by paralysing one vocal cord, and so interfering with the phonation of vowels, but not with the articulation of consonants. If the vagus root be affected at its point of exit from the medulla, the soft palate is often paralysed on the same side (see later, Cranial Nerves). But unilateral palatal palsy, unlike bilateral, does not affect the articulation of consonants.

[1] Schlesinger, *Neurologisches Centralblatt*, 1906, p. 50.

Articulation may also become indistinct from disease of the bulbar nuclei—so-called glosso-labio-laryngeal paralysis, or **bulbar palsy.** In this disease there is a diffuse, progressive weakness of the muscles of articulation, with atrophy and fibrillary tremors of the muscle-fibres, especially those of the tongue and lips. Articulation becomes more and more indistinct, saliva dribbles from the patient's trembling lips, and in advanced cases there is interference with swallowing and coughing. If, as is often the case, bulbar palsy is an upward extension of an amyotrophic lateral sclerosis, there may be a concomitant muscular atrophy and fibrillary tremor in the muscles of the upper limbs, especially in the intrinsic hand muscles. Owing to affection of the pyramidal tracts, there is also exaggeration of the deep reflexes and general spasticity, especially of the lower limbs.

There is a form of *myopathy*—the *facio-scapulo-humeral type* of Landouzy and Dejerine, in which the facial muscles are atrophied. This affection is a bilateral one and the patient's lower lip protrudes in a characteristic fashion which has been termed the "tapir" type of lip. He has also a peculiar "transverse" smile. In severe cases of this disease the articulation of labial consonants becomes impaired just as it does in double facial palsy.

Myasthenia gravis, when it affects the bulbar muscles, reproduces all the features of bulbar palsy, with this difference, that the paralysis varies in its degree from time to time, becoming accentuated by fatigue. After a period of rest a patient thus affected may resume with normal articulation, but, if he continues to speak, his muscles gradually become exhausted, and his articulation becomes more and more indistinct. Not only the lips and tongue, but the ocular muscles, the muscles of mastication and various muscles of the trunk and limbs, show evidence of temporary paralysis or fatigue, and ultimately the patient succumbs to fatigue of his respiratory muscles.

Articulative Ataxia.—There are some diseases in which articulation becomes indistinct, not from paralysis of the muscles but from ataxia.

In recent and *acute cerebellar lesions, e.g.* from encephalitis or from bullet-wounds of the cerebellum, articulation becomes slow, laboured, and monotonous, with a curious jerky irregularity. Phonation, as a rule, is even more affected than articulation, and the voice is curiously explosive. Cerebellar dysarthria is mainly due to asynergia of the laryngeal and articulatory muscles. If the patient survives his lesion, this dysarthria tends gradually to subside.

The articulation in some cases of *disseminated sclerosis* assumes a peculiar so-called "staccato" character, probably due to cerebellar disease. In this variety the words are enunciated in a curious,

jerky, mincing manner, very difficult to describe, but easy to recognise, once it has been heard. This is sometimes called the "scanning" speech, from its fancied resemblance to the scansion of Latin or Greek verse.

In *Friedreich's ataxia* the articulation becomes slow, thick, and clumsy, and the patient talks as if he had a foreign body in his mouth, so that his speech has been aptly termed the "hot-potato" speech. The pitch of the voice in this disease may vary from word to word, and in advanced cases a certain degree of mental feebleness is often superadded.

In laryngeal *tabes*, in which the larynx is affected by ataxy, the voice is tremulous, and when a tabetic patient has ataxia of the tongue his articulation becomes laboured. This lingual trouble in tabes is often associated with a peculiar constant rolling movement of the tongue on the floor of the mouth, even when the patient is not speaking. The patient often has an annoying subjective sensation in his tongue, as if it were covered with blotting-paper, which he tries to get rid of by the restless rolling of his tongue.

Supra-nuclear, or **Cortico-bulbar Affections of Articulation.**—Articulation may be affected where the upper or cortico-nuclear neurones are involved. The slurring articulation of many cases of acute *alcoholic intoxication* is familiar to lay observers, being especially marked in the pronunciation of labial and of anterior linguo-dental consonants. In rare instances alcoholic dysarthria persists for days after the alcoholic celebration. Tollmer and other French authorities ascribe this circumstance to cerebellar intoxication. Many alcoholic patients realise their own articulative difficulty, and in endeavouring to compensate for it, they utter certain words with a deliberation and undue emphasis that betrays them.

Very similar to the alcoholic articulation is that of *general paralysis of the insane*. But the typical general paralytic shows also a characteristic fibrillary tremor of all the muscles around the lips and nose.

Both in acute alcoholism and in general paralysis there is often a tendency to choose an occasional wrong word, or to misplace syllables. Such defects are not bulbar but cortical in origin. In the later stages of general paralysis, articulation may be totally unintelligible, reduced to a mere mumble.

After an attack of right-sided hemiplegia, the patient is often aphasic. But even in a left-sided hemiplegia where no true aphasia exists, it is not uncommon to find a temporary change in the articulation, which loses its crispness, and becomes somewhat laboured and indistinct. This dysarthria usually passes off after a few days,

but sometimes persists permanently, in varying degree, especially if the lesion involves the lenticular nucleus. A lesion of the left lenticular produces greater dysarthria than one of the right nucleus.[1] The dysarthria of lenticular disease is due mainly to spasticity of the muscles of articulation.[2]

In cases in which a patient has a bilateral hemiplegia we often meet with **"pseudo-bulbar" paralysis.** The most common history is that there have been one or more hemiplegic attacks, all confined to the same side, but at last the patient has an attack on the opposite side. This now produces, in addition to the classic signs of a double hemiplegia, pseudo-bulbar paralysis, with thick, indistinct articulation, closely resembling that of true bulbar palsy and with the same dribbling of saliva, difficulty in swallowing, coughing, etc., but without atrophy or fibrillary tremors of the affected muscles. The pseudo-bulbar patient is emotionally irritable; he laughs, or more often cries, on slight provocation, and, unlike the subject of true bulbar paralysis, he is generally somewhat deficient mentally. There is usually a history of successive (more rarely of simultaneous) attacks of hemiplegia on opposite sides of the body.

Bilateral athetosis is a disease which is usually congenital, although the symptoms do not necessarily appear at birth, but may begin in childhood or even in adolescent life. The disease gradually increases in severity. It is characterised by wild wriggling and twisting movements of all the limbs, chiefly on attempted voluntary movements (but sometimes spontaneously, when no effort is being made), and by grimacing of the face, together with spastic rigidity of the affected muscles (see Figs. 54 and 55). There is generally a certain degree of mental deficiency. In this malady there is a congenital atrophy, so-called "état marbré," of the corpus striatum, with diminution or total loss of its normal ganglion-cells which are replaced by a fine network of nerve-fibres. The disease is probably due to degeneration of the extra-pyramidal, neo-striate system of cells, situated in the caudate nucleus and putamen[3] (see p. 10). The pyramidal tracts are unaffected, and the plantar reflexes are usually of the normal flexor type. In this disease articulation is often affected. The grimaces of the face and of the tongue muscles interfere considerably with articulation. Moreover, irregular spasmodic contractions of the diaphragm and other respiratory muscles give the voice a curiously jerky or groaning character, due to sudden interruptions of breathing.

In *paralysis agitans*, as the disease advances, the patient's voice

[1] Mingazzini, *Sulla sintomatologia delle lesione del nucleo lenticolare*, 1902.
[2] Wilson, "Progressive Lenticular Degeneration," *Brain*, 1912.
[3] Cecile Vogt, *Neurologisches Centralblatt*, 1911, p. 397.

becomes thin, feeble and reduced almost to a monotone, whilst his articulation, like his gait, acquires a "festinant" character. When speaking, he begins slowly, but towards the ends of sentences or long words he tends to hurry, so that the final syllables are pronounced hastily. Together with this we have the characteristic rigid, "starched," expressionless face, the Parkinsonian mask, commencing unilaterally and ultimately becoming bilateral.

In severe cases of *chorea* the articulation may be interfered with, owing to sudden violent movements of the face, tongue, and respiratory

Fig. 54.

Fig. 55.

Figs. 54 and 55.—Bilateral athetosis in a girl of 17. The patient was a 7½ months child. She had also signs of stenosis of the pulmonary artery.

muscles. Speech becomes hesitating and jerky, and in very bad cases the voice may be reduced to a whisper.

There are also affections of articulation due to functional cortical disturbances. Of these the most familiar is **stammering.** This is commonest in individuals, usually above the average intelligence, who have a congenital psychasthenic tendency. Other cases of stammering are hysterical in origin, sometimes due to imitation of other stammerers, sometimes arising by auto-suggestion.

Stammering consists in a want of co-ordination between the vocal (laryngeal) and consonantal (oral) mechanisms of speech, so that, in the common type, the patient sticks at an initial consonant or an initial syllable, which he often continues to repeat, over and over again, before he finally succeeds in enunciating the rest of the word, *e.g.* "p-p-p-p-p-perfectly cha-cha-cha-cha-charming." He misdirects

his energy on the consonants, instead of touching them lightly and passing on to the vowel sounds. The severity of a stammer is generally increased by emotional excitement. Most stammerers lose their stammer when they sing, their attention being then directed to the vocal part of speech. The vast majority of stammerers are males.

A rarer variety of stammering is that in which the patient sticks at initial vowels. This is due to temporary spasm of the false vocal cords, and the patient remains with his mouth wide open until the spasm relaxes, when his words suddenly rush forth in a hurried stream until he has no breath left. He then takes another breath and the precipitate rush again occurs.[1]

Many stammerers acquire various tricks, chiefly through their efforts to overcome the stammer. Thus extra noises may be thrown in, *e.g.* sudden inspiratory grunting or whooping noises, or the patient may make grimaces or curious contortions of his limbs.

This leads us to recall the various *articulation tics* or habit-spasms which are met with in psychasthenic patients, either in conjunction with stammering or independently of it. These may be of the most varied character. The patient's speech may be interrupted by weird pharyngeal barking or grunting noises. Or the articulation may be monosyllabic, a whole breath being taken for each syllable. Or, again, it may be jumbled up in the most extraordinary ways, though the "tiqueur" usually interpolates, now and then, a clearly articulated sentence or phrase amongst other unintelligible ones. Hysterical aphonia is fairly common, and can usually be recognised by the history, together with the characteristic laryngeal appearances. We also meet with cases of hysterical mutism, in which the patient does not utter even a whispered word. Nevertheless he has an abundant stock of pantomimic gestures and can also express his ideas fluently by writing.

Deaf-mutes are the patients who are popularly known as "deaf and dumb." A normal child learns to speak by imitating words which he hears. If a child be congenitally deaf, he does not learn to speak, but remains deaf and dumb. Moreover, if he is born with normal hearing, but subsequently becomes deaf, *e.g.* from middle-ear disease or from meningitis, before the age of about six years, he usually loses his power of speech. Such deaf-mutes can generally be taught to speak again by the oral or "lip-reading" method, where

[1] Cathcart has pointed out that this variety of stammering is described in Shakespeare's *As You Like It* (Act iii., Scene 2) as follows:—

"I would thou couldst stammer, that thou mightst pour this concealed man out of thy mouth, as wine comes out of a narrow-necked bottle, either too much at once, or none at all. I prithee, take the cork out of thy mouth that I may drink thy tidings."

the child imitates the movements of his teacher's muscles of articulation and also learns to phonate, though usually with a harsh, discordant voice. But even deaf-mutes who have never been taught to speak usually make noises of some sort or other, often pharyngeal snorts and grunts, or spluttering labial noises, and less frequently laryngeal sounds. They do this especially when excited. This was the case with a deaf-mute who used to make weird snorting noises when playing football. These doubtless helped to smite terror into the hearts of the opposite side. The congenital deaf-mute is usually brighter and more clever than the deaf-mute whose deafness was acquired. Deaf-mutes generally have a wonderful command of gestures and signs.

Deaf-mutism constitutes a common variety of war-neurosis after shell-explosions. The soldier is flung to the ground, or perhaps even partially buried, by a bursting shell, and may be rendered unconscious, although this latter is not essential. He immediately finds himself mute or deaf-mute. A considerable proportion of such patients can be rapidly cured by suggestion, sometimes aided by the administration of a general anæsthetic.

The dumbness which is present in profound degrees of idiocy is not an articulative difficulty, but a true speech affection due to maldevelopment of the cortical speech-centres. An imbecile child is speechless because he has no ideas to express; in this respect he differs from the deaf-mute, who is often bright and intelligent.

Certain varieties of deficient articulation are met with in children or in adults who are mentally more or less childish. The condition known as **lalling** consists in a want of precision in the pronunciation of certain consonants. Thus a patient may substitute the uvular R for the ordinary linguo-palatal R, or he may substitute V or Th or W for R, so that "broken reed" becomes "bwoken weed." Or, again, the patient may substitute Th for S and is then said to *lisp*. These last two varieties are sometimes voluntarily assumed, as a fashionable affectation, by young men not overburdened with brain power. More serious varieties of lalling are where the letter L is replaced by some other consonant, so that "elephant" may be pronounced as "edephant," "esephant," "enephant," "erephant," etc. Still worse is it when the patient has difficulty with K or G, their places being taken by T and D respectively.

As a general rule, it may be stated that lalling on a single consonant does not necessarily indicate defective intellect, whereas lalling on many consonants, if the patient has passed the age of childhood, should arouse the suspicion of mental deficiency, although lalling is a normal stage in the process of learning to speak.

Finally, there is the condition known as **idioglossia,** in which from difficulty in pronouncing his consonants a child retains the correct vowels but substitutes other consonants and seems to speak a new language of his own. The child is usually mentally bright and understands all that is said to him. He talks volubly but unintelligibly. As a rule he completely outgrows the weakness in course of time.

CHAPTER IX

CRANIAL NERVES

THE recognition of cranial nerve palsies is, diagnostically, of the utmost importance, nor is it a matter of such difficulty as is commonly imagined.

First, or Olfactory Nerves.—

From a small area of mucous membrane, in the upper part of the nasal cavity, there arise the unmyelinated olfactory fibres. These pierce the cribriform plate of the ethmoid bone in about twenty small bundles and terminate in the superjacent olfactory bulb. Intermingled with these fibres are the fibres of the *nervus terminalis* whose function is unknown and the fibres of which leave the olfactory fibres above the olfactory bulb.

To test the sense of smell, we direct the patient to close his eyes. We then hold aromatic substances, such as oil of cloves, peppermint, turpentine, or asafœtida, in front of each nostril in turn, closing the other nostril with the finger. Ammonia or acetic acid must not be used to test the sense of smell, since these stimulate the fifth nerve (common sensation), and may produce a pungent sensation in the nose, even when the sense of smell is lost.

Anosmia, or loss of the sense of smell, is sometimes of diagnostic value. It may occur, for example, in congenital absence of the olfactory nerves, in lesions of the olfactory bulb or olfactory tract, in some frontal tumours, in tabetic atrophy of the olfactory nerves, and in injuries of the anterior fossa of the skull. It also often occurs unilaterally in hysterical hemiplegia and is then associated with diminution of the other special senses on the hemiplegic side. But the value of anosmia as a symptom is lessened by the fact that numerous local obstructive conditions in the nose, *e.g.* nasal polypi or even a simple cold in the head, also produce loss of smell, so-called respiratory anosmia.

Parosmia, or perverted sense of smell, is always cortical in origin. Various subjective *hallucinations of smell* occur not only in mental disease but also in gross lesions of the uncinate gyrus, which is the cortical olfactory centre. But here again local nasal conditions may also cause olfactory sensations, *e.g.* the unpleasant odour perceived by a patient suffering from empyema of the antrum of Highmore from which horribly offensive pus is escaping into the nose. On the

other hand, in ozæna from chronic atrophic rhinitis the offensive smell is not perceived by the patient, although painfully evident to his neighbours.

Paroxysmal parosmia, preceded by a disagreeable sensation of irritation at the root of the nose, and sometimes followed by violent sneezing and sudden secretion of nasal mucus, may occur as a *nasal crisis* in tabes.[1]

Second, or **Optic Nerve.**—Strictly speaking, this is not a true peripheral nerve. Its essential, receptive part, the retina, both developmentally and structurally, is a part of the brain, and the so-called optic nerve is a true cerebral tract.

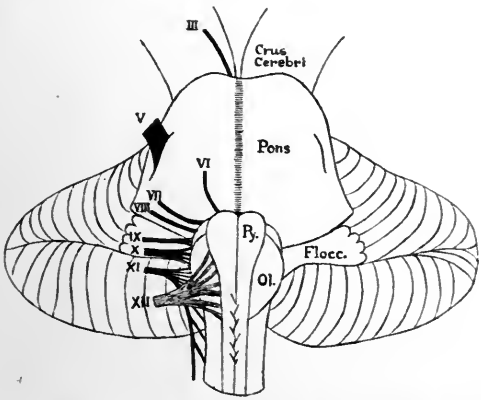

Fig. 56.—Diagram of pons and medulla, showing cranial nerves.

The optic nerve contains not only visual fibres, but also the afferent fibres for the pupillary reflex.

We have already referred to the course of the visual path from retina to cortex (Fig. 29, p. 38). In testing vision we should determine *visual acuity* by means of test types at a fixed distance, such as six metres. Using Snellen's types, of which the largest should be readable at sixty metres, and the smallest at six metres, we direct the patient to read the letters from above downwards. If his vision is normal he will be able to read the smallest type at six metres. His visual acuity is then represented as $V=\frac{6}{6}$. But if he can only read down as far as the type which ought to be visible at thirty metres, then $V=\frac{6}{30}$. Each eye should be tested separately, the test types being well illuminated and the patient standing with his back to the light. When the visual acuity is much impaired, the patient may not see even the largest type, but can only count fingers at a

[1] Klippel and Lhermitte, *Semaine Médicale*, Feb. 17, 1909.

short distance, or perhaps can only tell light from darkness. Temporary diminution of visual acuity may occur in myasthenia gravis.[1]

Hemeralopia, or day-blindness, is a condition in which the power of vision is bad during the day or in a bright light, whilst the patient sees better in a dim light. The phenomenon is not uncommon in tobacco amblyopia, where there is usually present a central scotoma for green and red. The hemeralopia is probably due to the fact that a bright light rapidly fatigues the retina and also, by producing pupillary contraction, causes the peripheral part of the retina to be less in use than the central, whereas in a dim light the pupil dilates and the unaffected peripheral portion of the retina comes into play.

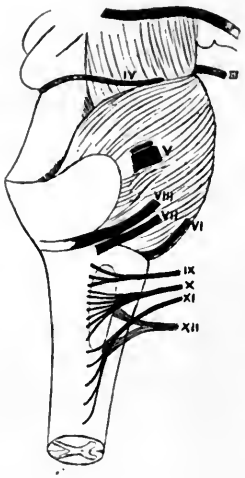

Fig. 57.—Lateral view of brain-stem with cranial nerves.

A patient with **nyctalopia,** or night-blindness, becomes almost blind at dusk or in a dim light. This occurs in association with various conditions, of which the most interesting is congenital *retinitis pigmentosa*, a disease easily recognised on ophthalmoscopic examination. It is sometimes met with in patients who are exhausted by insufficient food, insomnia, and prolonged over-exertion, *e.g.* amongst soldiers in the field, in whom the condition is probably of cortical origin. Night-blindness also occurs to a lesser degree in certain cases of "cortical" cataract, when the lenticular opacity acts as a permanent diaphragm. Night-blindness can also be simulated.

Colour vision is most conveniently tested by means of Holmgren's wools. These are thrown on a table well lit by daylight, and the patient is given one particular test-skein of wool which is kept separate from the heap, and told, not to name the colour, but to match it, selecting from the heap of coloured skeins all those which are like the test-skein, whether lighter or darker in shade. The patient is given a pale green test-skein. If his colour vision is normal, he will pick out all the pale greens correctly, but if he is red-green colour-blind he will select a grey or straw-coloured skein. Congenital red-green colour-blindness is the commonest variety. Yellow-blue colour-blindness is less common. If a patient be totally colour-blind he will confuse with the test-skein all those of similar brightness, no matter what their colour may be.

The size of the **field of vision** in each eye is of great importance,

[1] Tilney and Mitchell Smith, *Neurographs*, 1911, vol. i., p. 178.

and for its accurate measurement a perimeter is required. This, however, is a large and expensive piece of apparatus. For clinical purposes the following method is sufficient, presuming that the physician's own visual fields are normal. The physician sits exactly opposite the patient, about a yard away from him. Each eye is tested separately. To test the patient's *right* eye, direct him to cover up his left and to gaze steadily at the physician's left eye. Meanwhile the physician closes his own right eye and looks steadily at the patient's pupil, watching that the patient's eye does not wander from the fixation point. Then, holding his own left hand in a plane midway between himself and the patient, and beginning almost at arm's-length, he brings his hand inwards from the patient's ear towards the middle line, meanwhile moving his own fingers. If the patient's visual field is normal, he will catch sight of the moving fingers at the same time that the physician does so. If he does not, that visual field is contracted and the physician then brings his moving fingers inwards until the patient does catch sight of them. In this way we test both the upper and lower quadrants of the field on the temporal and nasal sides, in turn. If we find the visual field diminished in one or other eye, it is well to take a careful perimetric chart.

In a patient with a right-sided hemianopia, if we draw a horizontal line on a piece of paper and then ask the patient to mark with a pencil the mid-point of this line, he will constantly make the mistake of indicating a point distinctly to the right of the mid-point. The probable explanation of this *bisection test* is that, owing to the greater effort required by the ocular muscles to turn the eye towards the blind half of the visual field, the extent of the "blind" part of the ocular movement is over-estimated by the patient.[1]

We may find a *central scotoma* or blind patch in one or both visual fields. This is detected by attaching a small white object to the end of a thin rod and holding it in the centre of the visual field, midway between one's own and the patient's eye. In this situation it is not seen by the patient. We gradually move the white object radially outwards in various directions until the patient catches sight of it. Central scotoma may occur in various organic diseases of the optic nerve or retina, such as early optic atrophy, central retinal hæmorrhage, etc., or it may result, in a minor degree, from obstruction to central vision, *e.g.* by central opacities in the lens or cornea. It may also occur, as a temporary phenomenon, in some cases of migraine. Such conditions are easy of recognition. Central colour scotoma to red and green (detected in a similar fashion with coloured objects) together with deficient visual acuity, is highly suggestive of *tobacco*

[1] Axenfeld, *Neurolog. Centralblatt*, 1894, s. 437.

amblyopia. In such cases, besides a history of chronic excess in tobacco, we look for corroborative signs such as fine tremor of the hands, cardiac irregularity with extra-systoles, cardiac pain, etc. An almost identical amblyopia may also occur from chronic *alcoholism*.

Quinine blindness, occurring after toxic doses of quinine, is accompanied by intense spasm of the retinal arteries which, seen with the ophthalmoscope, are contracted to fine scarlet threads. Vision may be completely lost, with loss of the light reflex, or it may be reduced to a para-central patch of vision. The condition may last hours, or days, or may even be permanent, progressing to optic atrophy.

The visual field may be *concentrically contracted*. This condition is sometimes due to optic atrophy, the field being reduced to a small area surrounding the fixation-point, so that the patient looks at the outer world as though through a narrow tube. Contraction of the field also occurs in glaucoma, in which condition we find the associated phenomena of increased tension of the globe, failure of visual acuity, and cupping of the optic disc. In most cases of glaucoma the pupil is dilated and sluggish, or even immobile. Concentric contraction of the field of vision for blue, sometimes actually amounting to blue-blindness, may occur in cases of increased intra-cranial pressure, especially from cerebral tumours.[1] More commonly concentric contraction of the visual field occurs in hysteria, the field on the hemiplegic side of the body being more contracted than that on the other side (Fig. 58). Temporary contraction of the visual field may occur in myasthenia gravis.

A cortical lesion of the psycho-visual cortex of the angular and supra-marginal gyri, besides producing disorders of visual localisation in space (p. 39), also causes difficulty in the recognition of objects seen, unless they are in the centre of the visual field. Objects in the peripheral parts of the visual field, although seen, are not recognised. This gives a false appearance of contraction of both visual fields, which has been somewhat clumsily named *crossed amblyopia*. But crossed amblyopia is much commoner in hysteria, in which it is frequently associated with diminution or loss of other special senses on the side of the more contracted field whose colour sense is frequently lost (achromatopsia). Hysterical amblyopia is unknown to the patient, and is only discovered on examination by the physician in a patient who is specially vulnerable to suggestion.

Hemianopia (Fig. 59) means blindness of half the visual field, right or left as the case may be, from causes other than retinal disease. It usually affects the visual field of both eyes, and is due to a lesion of the visual fibres at or behind the *optic chiasma*. Such chiasmatic

[1] Cushing, *Johns Hopkins Hosp. Bull.*, 1909, xx., p. 95.

lesions may result from pressure by tumours, syphilitic or inflammatory affections of the basi-sphenoid, from tumours of the brain or of its membranes, and especially from pituitary tumours, as in acromegaly. We have already considered the signs of lesions of the optic radiations and tracts, and it is convenient here to recall the effects of **lesions of the optic chiasma.**

(A) If the lesion be in the central part of the chiasma, interrupting the decussating optic fibres (belonging to the nasal halves of both

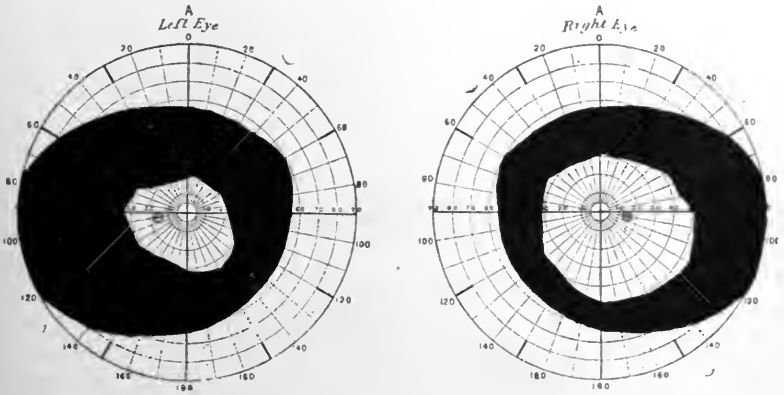

FIG. 58.—Crossed amblyopia, in a case of hysteria.

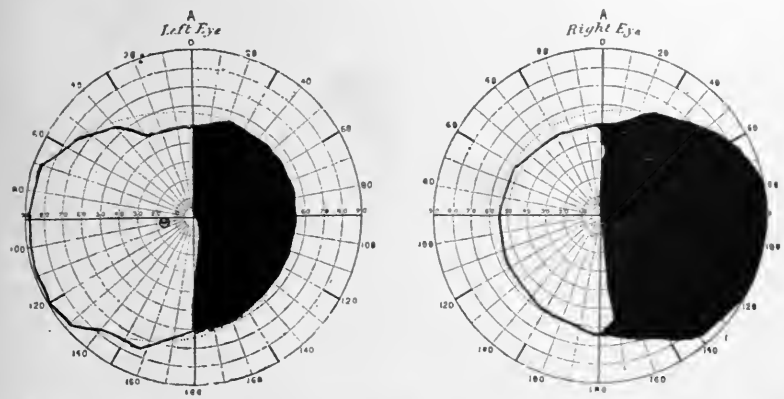

FIG. 59.—Right homonymous hemianopia, in a case of softening of the left occipital lobe.

retinæ), there is blindness in the outer half of each visual field:—*bi-temporal hemianopia* (Fig. 60). This sometimes occurs in pituitary tumours.

(B) If the lesion be situated at one or other lateral extremity of the chiasma, it will interrupt merely the non-decussating fibres of the optic nerve and optic tract on that side, causing *unilateral nasal*

hemianopia in the corresponding eye. To produce bilateral nasal hemianopia there must be two separate lesions, one at each end of the chiasma, a condition which very seldom occurs. A lesion involving the central part of the chiasma and extending to one or other side (Fig. 60, A *plus* B) will produce the sum of these two, namely, bi-temporal hemianopia *plus* unilateral nasal hemianopia, *i.e.* total blindness of one eye with temporal hemianopia of the other.

(C) A lesion of the left optic tract behind the chiasma produces, as already seen, hemianopia in the right halves of both fields of vision.

(D) A lesion of one optic nerve simply causes blindness in the corresponding eye.

In rare cases we may have a *quadrantic hemianopia* in which only one quadrant (instead of one-half) of both visual fields is blind. This

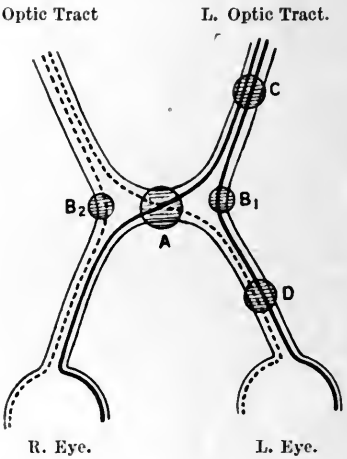

FIG. 60.—Diagram of course of visual fibres in optic chiasma. (Hamilton.)

is generally due to a lesion limited to part of the cortical half-vision centre in the cuneate lobule and lingual gyrus. The calcarine fissure divides the half-vision centre into an upper and a lower part. A lesion above the calcarine fissure, *i.e.* in the cuneate lobule, causes blindness of the lower quadrant, whilst a lesion below the calcarine fissure, *i.e.* in the lingual gyrus, causes blindness of the upper quadrant of the corresponding half-fields.[1]

The optic discs and retinæ should be examined with the ophthalmoscope in every case of nervous disease. Every neurologist must be able to use the ophthalmoscope. The most important conditions to look for are optic neuritis and optic atrophy. **Optic neuritis** occurs in numerous pathological conditions within the skull, especially in

[1] Henschen, *Le Centre cortical de la Vision.* Internat. Med. Congress, Paris, 1900.

intra-cranial tumours and in tuberculous meningitis. But it also occurs in nephritis, in lead poisoning, in diabetes, and in severe anæmia; and these four common conditions must always be excluded before we diagnose gross intra-cranial disease. We may also meet with optic neuritis in certain cases of cervical myelitis. **Optic atrophy** may occur primarily, as in tabes and disseminated sclerosis, or it may be a secondary post-neuritic process. Sometimes it follows a *retro-bulbar neuritis*, which is due most frequently to the toxin of disseminated sclerosis, less commonly to chronic alcohol or tobacco poisoning. Pallor of the temporal halves of the optic discs is often an early sign of disseminated sclerosis. The combination of blindness from optic atrophy with mental deficiency from arrested cerebral development occurs in the *amaurotic family idiocy* of Tay and Sachs, an affection of certain Jewish children, coming on in infancy. In these cases, on ophthalmoscopic examination there is a characteristic cherry-red spot seen at the macula lutea, due to local œdema and atrophy of the retina, whereby the vascular choroid shines through.

Apart from optic neuritis and optic atrophy, we must be on the look-out for other pathological conditions of the fundus, such as choroiditis, albuminuric retinitis, tubercle of the choroid, occlusion of the central retinal artery, retinal hæmorrhages, etc.

It must be remembered that a patient may have severe optic neuritis without any impairment of vision. Optic atrophy, on the other hand, causes the visual field to contract concentrically to a greater or less extent, whilst the visual acuity diminishes and ultimately the eye becomes blind. The atrophy of retro-bulbar neuritis often produces central scotoma from affection of the papillo-macular bundle of optic nerve fibres. Scotoma is often the first sign of retrobulbar neuritis, long before atrophy is visible by the ophthalmoscope.

Third, Fourth, and **Sixth Nerves.**—It is convenient to study together these three nerves which, between them, innervate all the voluntary muscles of the eye. The distribution of each is as follows:—The *third* nerve (oculo-motorius) supplies all the external ocular muscles except two:—the superior oblique supplied by the fourth nerve, and the external rectus supplied by the sixth. It also supplies the voluntary part of the levator palpebræ superioris (the involuntary part being supplied by the cervical sympathetic), and it contains fibres which indirectly, through the ciliary ganglion and short ciliary nerves, supply the non-striated sphincter pupillæ and ciliary muscle. The *fourth* nerve (patheticus) supplies the superior oblique alone, the *sixth* nerve (abducens) the external rectus alone.

The third, fourth, and sixth nerves are often regarded as purely

motor nerves, but Sherrington[1] has shown that a considerable proportion of their nerve-fibres are afferent, conveying impulses of kinæsthetic sense from the extrinsic ocular muscles, and maintaining ocular posture during waking hours in the delicate adjustment and maintenance of the gaze. The common occurrence of squint in tabes (analogous to the hypotonia of tabetic limbs) is probably due to loss of the normal reflex tonus of the ocular muscles.

The third nerve also contains efferent autonomic fibres for the ciliary ganglion, from which are innervated the ciliary muscle and the sphincter of the iris within the eyeball, *i.e.* the muscles of accommodation.

Experimental and clinical evidence (Piltz,[2] Bach[3]) has shown that the *ciliary ganglion* of the cranial autonomic system is the peripheral motor nucleus controlling the sphincter pupillæ. Marina,[4] in a series of twenty-eight cases of tabes and general paralysis exhibiting the Argyll-Robertson pupil, found this ganglion invariably degenerated. In one of them where the Argyll-Robertson phenomenon was confined to one eye, the ciliary ganglion was degenerated on that side alone, the ganglion of the other side being normal. It is therefore probable that degeneration renders the ciliary ganglion inexcitable to the stimulus of light, whereas it can still respond to the stronger stimulus of voluntary impulses transmitted along the third nerve. The connection between the anterior corpus quadrigeminum and the third nerves is *viâ* the fasciculus sublongitudinalis.[5]

The Pupil.—We note the size of the pupil, both in a bright and in a dim light. Firstly, we observe whether the pupils are equal in diameter. Slight inequality (*anisocoria*) of the pupils is not uncommon in individuals who are otherwise healthy, and if the pupils react to light and to convergence, such trivial inequality, by itself, has no special significance. In a normal individual, if the eyes be turned to the right and kept there for several seconds, the right or abducted pupil becomes slightly larger than the left or adducted one, and conversely on looking to the other side.[6] Marked inequality, however, should always make us suspicious of organic mischief. Abnormal dilatation of the pupils (*mydriasis*) is often present in anæmia and neurasthenia, but it may occur, on one or both sides, in organic nervous disease. Mydriasis may be either paralytic, from paralysis of the sphincter pupillæ, as in disease of the third nerve or ciliary ganglion, or it may be irritative, as when due to stimulation of the dilator pupillæ. It also occurs when optic atrophy has caused blindness, and is then due to the absence of visual impressions. *Myosis* or abnormal contraction of the pupils occurs in pontine hæmorrhage,

[1] *Brain*, 1915, vol. xxxviii., p. 209.
[2] *Neurologisches Centralblatt*, 1903.
[3] *Zeitsch. für Augenheilkunde*, 1904.
[4] *Annali di Nevrologia*, 1901.
[5] Majano, *Monatschrift für Psychiatrie und Neurologie*, 1903, Bd. xiii., Heft 1.
[6] Tournay, *Bulletin de l'Académie de Médecine*, 10 Mars, 1917.

probably from irritation of inhibitory fibres leading from the brain to the ciliary ganglia.[1] It is also present in many cases of tabes, as well as in certain cases of disease of the cervical region of the cord (notably in syringomyelia) from interruption of the pupil-dilating fibres.[2] Myosis is also caused by iritis, and by the irritation of foreign bodies in the cornea, and a transient myosis occurs for a day or so after excision of the Gasserian ganglion [3] (see Fig. 61).

Variations in the size of the pupil may also be the result of mydriatic (pupil-dilating) drugs, either locally instilled (atropine, homatropine, cocaine) or taken internally (belladonna), whilst other drugs are myotics (pupil-contractors), either local (eserine, pilocarpine) or internal (opium, jaborandi).

The outline of the pupil should be carefully examined. Sometimes, instead of being circular, it is oval or irregularly polygonal. Such variations have an important diagnostic value. For if we exclude congenital malformation such as coloboma, operative procedures such as iridectomy, and disease such as iritis causing synechiæ, then it may be taken as a general rule that irregularity of the pupils signifies either tabes, general paralysis, or other form of syphilis, the lesion being either in the short ciliary nerves or in the ciliary ganglion itself. *Ectopia pupillæ* is a condition in which the pupil is not in the centre of the iris. Sometimes it occurs in lesions of the mid-brain;[4] in other cases, however, it appears to have no pathological significance. Irregularity of the pupil can be produced experimentally by stimulation or division of the short ciliary nerves.

The **pupillary reflex to light** should always be observed. For this purpose it is convenient to have the patient sitting near a window in such a position that one side of his face is illuminated. He is then made to gaze at the ceiling whilst the physician, with the palms of the hands, shades and uncovers one or both eyes. Each eye must be observed separately, noting the effect on the pupil of shading and uncovering, first the same eye and then the opposite eye. Normally the iris contracts when light falls on the retina whether of the same eye (direct reflex) or of the opposite eye (consensual reflex).

The light-reflex depends upon the integrity of a reflex arc, whose afferent limb is the peri-macular fibres of the retina and optic nerve, whose intermediate station is in the mid-brain, and whose efferent limb passes through the third nerve and ciliary ganglion to the pupillary sphincter (Fig. 61).

If the healthy pupil be strongly illuminated and examined with a magnifying lens (say × 10), we observe that it is not stationary but in a continuous state of fine irregular movement, slight alternate

[1] Bach, *Zeitschrift für Augenheilkunde*, 1904, s. 105.
[2] See later, *Cervical Sympathetic*, p. 341. [3] H. M. Davies, *Brain*, 1907, p. 265.
[4] S. A. K. Wilson, *Brain*, 1906, p. 524.

narrowing and widening, varying both in rhythm and amplitude. This normal *pupillary unrest*[1] must not be confounded with *hippus*, which is a pathological condition consisting in rhythmic clonic contractions of the iris, regular in their periodicity, much coarser in range, and visible to the naked eye. Loss of the normal pupillary unrest is always pathological, and may be one of the earliest signs of organic affection of the reflex visual path, *e.g.* in tabes or general paralysis.

Loss of reaction to light occurs in optic atrophy, in paralysis of the third nerve, and in degeneration of the ciliary ganglion.

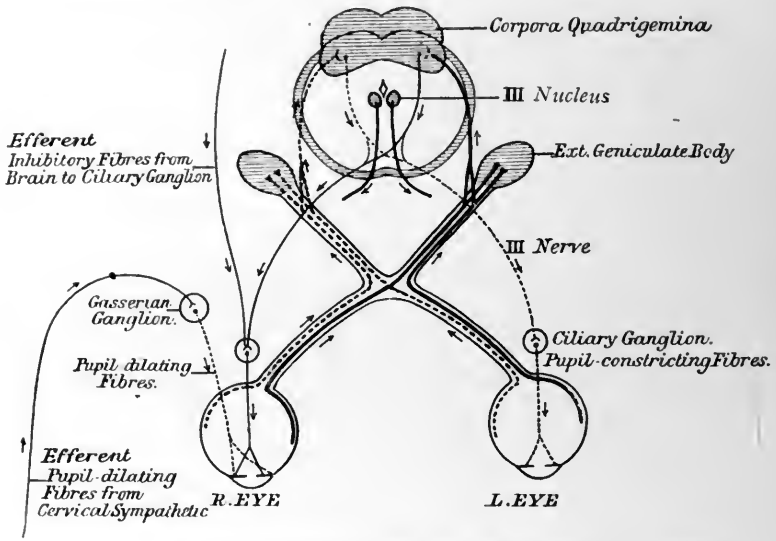

FIG. 61.—Diagram of the path of the pupil-reflex (modified from Bach).

Loss of the light-reflex together with preservation of contraction during accommodation for near objects—the classic *Argyll-Robertson phenomenon*—occurs typically in tabes and in general paralysis of the insane. It also occurs sometimes in other varieties of cerebro-spinal syphilis, and its presence has been demonstrated in a few rare cases without syphilitic infection, *e.g.* in chronic alcoholism[2] and even in syringomyelia.[3] Marina has shown it to be associated with degeneration of the ciliary ganglion. It also occurs in blindness from optic atrophy.

In the early stages of optic atrophy the pupil of the affected eye may contract sluggishly to light, compared with the normal eye; or

[1] Hübner, *Archiv für Psychiatrie*, 1906, Band 41, s. 1016.
[2] Nonne, *Neurologisches Centralblatt*, 1912, p. 5.
[3] Sicard and Galezowski, *Revue neurologique*, 1914, p. 300.

it may contract fairly well for a moment, but under continued exposure it dilates again, unlike a healthy pupil.[1] If this phenomenon be associated with diminution of visual acuity or with failure to distinguish between red and green in the centre of the visual field, we should be suspicious of early optic atrophy (even though the optic disc be normal in appearance), which in many cases is due to commencing disseminated sclerosis. *Wernicke's hemiopic pupillary reaction*, in certain cases of hemianopia, is absence of pupillary contraction when a ray of light is thrown on the blind side of the retina. It signifies a lesion of the visual path behind the chiasma, and below or at the corpora quadrigemina. In retro-quadrigeminal hemianopia, where the lesion is anywhere between the corpora quadrigemina and the visual cortex, the pupillary reaction is normal (Fig. 29, p. 38).

The **reaction of the pupil to accommodation** is the contraction of the pupil which occurs when the patient converges the eyes to look at a near object. We test this by holding a finger close to the patient's face, first telling him to look at some distant object, and then suddenly to look at the finger. If he is blind, he can nevertheless converge by attempting to look at his own finger. In paralysis of the third nerve there is total immobility of the corresponding pupil, both to light and on convergence. Loss of the contraction on accommodation with preservation of the light-reflex—a condition the converse of the Argyll-Robertson phenomenon—is not uncommon after diphtheria, and is often accompanied by other evidences of post-diphtheritic neuritis, such as paralysis of external ocular muscles or of the palate, loss of knee-jerks, etc. *Paradoxical pupillary reaction* is when the pupil dilates instead of contracting on exposure to light. This phenomenon, which is not uncommon in tabes (occurring, according to Pilcz, in 40 per cent. of cases), can be demonstrated as follows:—Sitting facing the light, with his head inclined backwards, so as to face the ceiling, the patient screws up the eyes forcibly, and on opening them, he again gazes up at the ceiling. When the eyes are thus re-exposed to light the pupils dilate (instead of contracting as in health) owing to the fact that as the voluntary contraction of the sphincter passes off, there is no counteracting contraction to light.

The *reaction of the pupil to painful stimulation* of the skin of the neck, causing the pupil to dilate, is important with regard to the cervical sympathetic. It is often absent in the early stages of tabes. A *psychical dilatation* of the pupil also occurs, temporarily, under the influence of lively emotion, such as fear, intense interest, sexual orgasm, etc. The pupils may even dilate when the individual thinks of a dark object or contract at the idea of a luminous one.

[1] Gunn, *Brit. Med. Journal*, 1907, p. 353.

Let us now consider **paralysis of external ocular muscles.**

To detect paralysis of the ocular muscles, having first examined the pupils, noting their size and any irregularity of outline, and having tested their reaction to light and on accommodation, we then ask the patient to follow our finger with his eye, making him look alternately up, down, to the right and left, and finally making him converge. Meanwhile we observe whether there be any squint, deficient movement in any direction, diplopia, or nystagmus.

If an individual muscle be paralysed, there is diplopia, squint, and deficiency of movement of the affected eye towards the direction of traction of the affected muscle. Fig. 62 is Bishop Harman's diagram

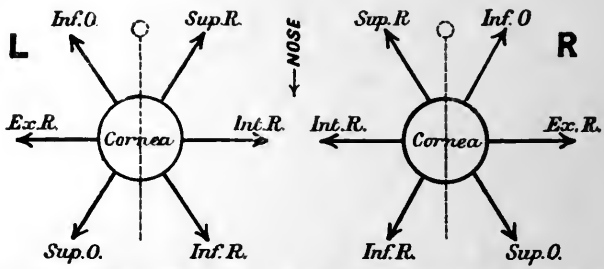

FIG. 62.—N. Bishop Harman's chart to show (1) *Movements of ocular muscles,* and (2) *Position of false image* in paralysis.

1. (*a*) Rectangular movements. The arrows point to the direction in which the eye is turned by each muscle.
   (*b*) Rotation. Put a match, head upwards, on each of the dotted lines indicating the vertical meridans. Muscles that rotate eye inwards turn the match-head towards nose (Sup. Rectus and Sup. Oblique); those that rotate it outwards turn match in the opposite direction (Inf. Oblique and Inf. Rectus).
2. Put matches on diagram again. The match will represent the true image. The four rays marked Sup. R., Inf. R., Sup. O., and Inf. O. will represent the relative position (in vertical and lateral displacement and tilting) of the false image produced in paralysis of each of these muscles. In paralysis of Int. or Ext. Rectus the false image will run vertically through the corresponding arrow-head.

indicating the action of the individual muscles. A simple rule, worth remembering in all cases of ocular paralysis, is that the affected eye is displaced (by the unopposed antagonists) in a direction opposite to the direction of traction of the paralysed muscle, whilst the false image, seen by the affected eye, is displaced in the direction of traction of the paralysed muscle.

Figs. 63 and 64 are Werner's well-known " memoria technica," showing the position of the false image in the various ocular paralyses. Fig. 63 shows the position of the false image in paralysis of any of the recti; Fig. 64 in paralysis of the oblique muscles. For example, Fig. 63 shows that in diplopia from paralysis of the left inferior rectus, (1) the false image is on the right of the true (*i.e.*, it is crossed); (2) the false image has its upper end inclined towards the true; (3) the false image is lower than the true; and (4) the diplopia occurs on downward movement of the eyes.

To test diplopia we use a long, lighted candle, at a distance of about three yards from the patient, holding it, first, exactly opposite

the patient and moving it gradually from side to side and then from above downwards. One of the patient's eyes is covered with a red and the other with a green glass, to differentiate the two images, and the patient has to tell us the relative position of the red and of the green candle. It is necessary to ensure that the patient keeps his head fixed during the process of testing. The false image is that seen by the paralysed eye, the true image by the sound one.

Diplopia is a more delicate test than paralytic squint, for where there is slight paresis of an ocular muscle there may be no noticeable squint, and yet the diplopia may be quite appreciable to the patient. To detect a paralytic squint we direct the patient to follow our finger,

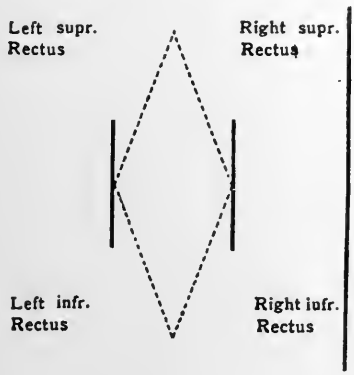

FIG. 63.

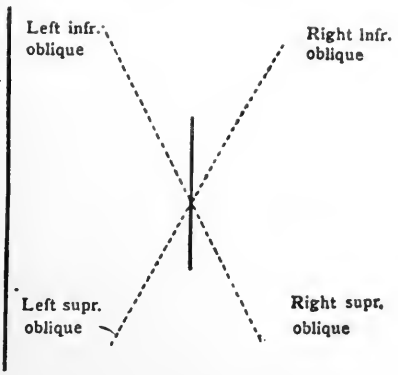

FIG. 64.

FIGS. 63 AND 64.—Werner's "artificial memory" for the double images in ocular paralyses (*Ophthalmic Review*, 1886). Fig. 63 shows the position of the images in paralysis of the recti muscles. Fig. 64 in paralysis of the oblique muscles. The dotted lines indicate "false" images, the thick black lines "true" images.

moving it laterally from side to side, and then vertically up and down, and observe whether there is deficiency of movement of one or both eyes in any particular direction or directions.

Nystagmus is an involuntary rhythmic tremor of the eyeballs, generally bilateral and symmetrical. The movement consists of an oscillation, usually horizontal, from side to side, but sometimes vertical or even rotatory, or it may be circumductory—a combination of rotation with vertical and horizontal movements. Nystagmus may be either **pendular** (where the movements to both sides are equal in range and of equal speed), or **rhythmic,** the commoner type, where both movements are equal in range but the one is a fast jerk and the other a slow one. In most cases nystagmus is a fixation-nystagmus, *i.e.* it occurs when the patient fixes an object at a distance from the "rest point" of his eyes. It is usually best marked when the eyes are voluntarily moved to an extreme degree either laterally or, less

commonly, vertically. In rhythmic horizontal nystagmus the rapid jerk is to the side towards which the eyes are directed, and the slow phase is a deviation back towards the rest-point. But sometimes, especially in the rotatory variety, nystagmus occurs when the eyes are directed straight forward. In cases in which an ocular muscle has been paralysed but is in process of recovery, if we make the patient look steadily in a direction which necessitates the active movement of the paresed muscle, slight rhythmic nystagmus may develop, analogous to tremulousness of the hand after carrying a heavy weight.

Another variety is **labyrinthine** or **vestibular nystagmus**. This, together with violent vertigo, may be produced experimentally in healthy subjects by syringing the drum of the ear with water, either distinctly above or distinctly below the temperature of the body. Bárány[1] regards this nystagmus as a result of convection currents in the endolymph produced by warming or cooling of the labyrinth. The presence of such **thermic nystagmus** can be used as a test of the integrity of the vestibular nerve. The objective phenomena vary according to the position of the patient's head.

Thus, for example, if the patient be standing up, with the head turned face downwards, and if the left ear be irrigated with cold water, the nystagmus which is produced is horizontal in type with the quick jerk to the left and most marked when the patient looks towards the left side. Meanwhile the head and eyes, and also the trunk, tend to rotate strongly, around the long axis of the body, towards the right side. If the patient's head be erect when his left ear is syringed with cold water, the nystagmus is rotatory in type and to the right, and the forced movement of the head and trunk is a lateral bending towards the left side. If the patient lies on his back, when the left ear is irrigated with cold water, he will tend to roll towards the ipso-lateral side and horizontal rhythmic nystagmus will be noticed towards the contra-lateral side. If hot water be used instead of cold, the direction of nystagmus and of forced movement of the head, eyes, and trunk is in each case reversed.[2]

In some cases of otitis media, in which a fistulous communication exists between the middle ear and the internal ear, sudden raising of the pressure of the middle ear, *e.g.* by compressing the external auditory meatus with the finger, or by inflation of the ear through the external meatus, stimulates the external semicircular canal through the fistulous opening and produces sudden labyrinthine nystagmus and vertigo, in which the nystagmus is horizontal in type, the head and eyes being deviated towards the contra-lateral side. If the labyrinth be already destroyed, this fistular test is negative.

In cases of labyrinthitis, *e.g.* by inward spread from an otitis

[1] *Centralblatt für Augenheilkunde*, August, 1905.
[2] Scott, *Lancet*, June 11, 1910.

media, there is total deafness of the affected side, together with complete loss of thermic and of fistular nystagmus. The inflamed labyrinth produces spontaneous vertigo with nausea, vomiting, and with a spontaneous rotatory nystagmus towards the sound side, if the head be in the erect posture.

Nystagmus occurs in various central organic diseases, not of the cerebral hemispheres, but of the mid-brain, pons, and cerebellum. It is specially characteristic of disseminated sclerosis, Friedreich's ataxia, syringomyelia, and cerebellar disease. In unilateral cerebellar disease it occurs on fixing the eyes on an object towards the ipso-lateral boundary of the visual field. Nystagmus may also occur in alcoholic peripheral neuritis. It is present also in certain patients who have become more or less blind (though in complete blindness the movement is more often a slow, aimless rolling of the eyes), also in albinism (where the vision is congenitally impaired. Another well-recognised form is **miner's nystagmus,** due to persistent ocular strain in a dim light. Miner's nystagmus is pendular but very fine and rapid, generally vertical, worse on looking upwards, and accompanied by spasm of the levator palpebræ. It is often associated with vertigo.

Labyrinthine nystagmus can also be produced in a normal person by placing him on a rotating stool with the head erect and spinning him rapidly around the long axis of his own body. In such a case, if the stool be suddenly stopped, the endolymph keeps on moving for a time and a temporary after-nystagmus appears, horizontal and rhythmic, the rapid phase of the nystagmus being in the opposite direction from the previous rotation. If a patient who already has a horizontal nystagmus be similarly revolved around his own long axis, on suddenly stopping the rotation we find that the original nystagmus towards the direction of rotation has temporarily ceased whilst that in the opposite direction is exaggerated.[1] In such a case, the experimental after-nystagmus has for the time over-compensated the pre-existing nystagmus.

There is also a rare congenital affection known as *nystagmus-myoclonus*, in which, together with nystagmus, commonly of the lateral pendular variety, there are involuntary jerking movements of the limbs or trunk. These movements are aggravated by cold or by tapping the muscles, but can be controlled by an effort of will. The deep reflexes are often exaggerated, and it is not unusual to have other coexisting deformities, such as hypospadias, flat-foot, facial asymmetry, persistent branchial cleft, etc.[2]

We are now in a position to recognise the signs of paralysis of any of the ocular nerves. In a case of complete **third nerve paralysis** (Figs. 65 and 65A) there is ptosis or drooping of the upper lid, from

[1] Cassirer and Loeser, *Neurologisches Centralblatt*, 1908, s. 252.
[2] Lenoble and Aubineau, *Revue de Médicine*, July 16, 1906.

paralysis of the levator palpebræ, with over-action of the frontalis on that side, so that the eyebrow stands higher than normal.

In hysterical ptosis (Fig. 66), on the other hand, there is usually no over-action of the frontalis; nor is there in the ptosis of myasthenia gravis, since the frontalis is usually partially paralysed as well.

In third nerve paralysis there is also external strabismus from unopposed action of the external rectus, and there is inability to move the eye upwards, directly downwards, or directly inwards, although a slight downward and inward movement can be executed by the superior oblique. The pupil is dilated owing to paralysis of the

FIG. 65. FIG. 65A.

FIG. 65.—Total paralysis of right third nerve from syphilitic disease.
FIG. 65A.—The same patient, the right eyelid being passively lifted to show the external strabismus and dilatation of pupil on the paralysed side.

sphincter iridis, and does not contract either to light or on attempted accommodation.

Complete paralysis of the third nerve is less common than is a partial paralysis affecting one or more muscles.

In some cases of partial third nerve paralysis in which there exists a unilateral ptosis with complete inability to raise the lid voluntarily, we observe that an involuntary elevation of the paralysed lid occurs if the healthy eye be passively closed with the finger. When the opposite eye is again opened, the paralysed lid drops at once, with a see-saw movement (*ptosi a bilancia*). The explanation of this curious phenomenon, which only occurs in a certain proportion of cases, is that the motor fibres to the levator palpebræ are derived from the nuclei of both third nerves, and if the crossed fibres of origin happen to escape, the see-saw phenomenon can be demonstrated.[1]

[1] Paccetti, *Policlinico*, 1896, sez. med. fasc. 3.

Weakness of the internal recti sometimes occurs in exophthalmic goitre (constituting *Moebius's sign*). We make the patient look upwards to the ceiling and then ask him to look at the tip of his own nose, when we observe that only one eye converges, the other eye becoming divergent.

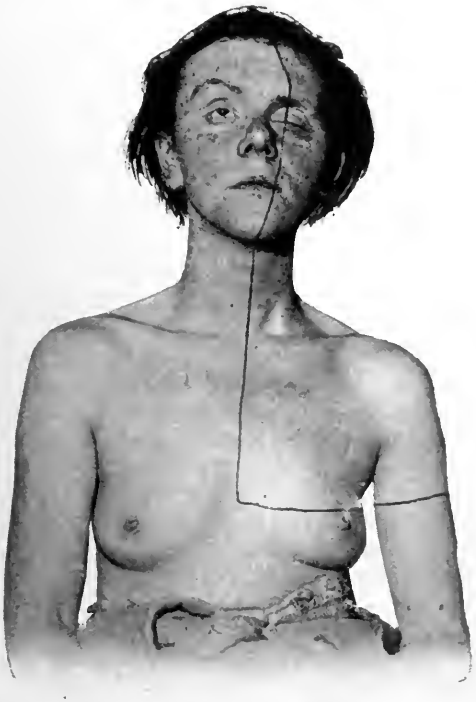

Fig. 66.—Case of left-sided *hysterical ptosis* in a woman of 25, showing absence of frontalis over-action on paralysed side. The area on the left side of the head, neck, trunk and shoulder, within the black line, was totally anæsthetic to all forms of stimuli. There was loss of smell and taste on the left side: contraction of the left visual field and diminution of hearing in the left ear. The figure also shows the presence of "dermographism." The patient's name having been traced on the chest with the head of a pin, a hard, cord-like pattern was produced, capable of being photographed.

Paralysis of the Fourth Nerve produces paralysis of the superior oblique muscle of the corresponding eye. This muscle has a threefold action; it turns the anterior pole of the eye downwards and outwards and at the same time rotates its vertical meridian slightly inwards at its lower end (see Fig. 62). The deficiency of movement is difficult to see, and the paralysis is recognised mainly by the characteristic diplopia which occurs when the patient gazes in the direction in which the superior oblique ought to come into action, *i.e.* downwards

and outwards. When the patient looks horizontally forwards or upwards there is no diplopia. But when he looks downwards and outwards, diplopia appears, the false image standing lower than the true, and having its upper end tilted towards the other (Fig. 64). The false image also appears to the patient nearer to him than the true, the reason for which is obscure. Moreover the patient feels giddy, especially when he looks downwards, as in walking downstairs, and he habitually inclines his head forward and towards the sound side.

Paralysis of the Sixth Nerve is particularly easy to recognise. There is merely paralysis of the external rectus, with inability to turn the eye outwards beyond the mid-point, all other movements being normal (Figs. 67 and 67A), and there is diplopia on looking

FIG. 67.

FIG. 67A.

Case of paralysis of the left sixth nerve.

FIG. 67 shows the normal movement of both eyes on looking to the right.
FIG. 67A shows attempted movement of eyes to the left. The left eye sticks at the mid-position.

outwards. In old cases in which contraction of the non-paralysed internal rectus has supervened, an internal strabismus results.

Sometimes an external ocular muscle is attacked by rheumatic myositis, which causes an ocular palsy of benign form. The muscle most frequently thus affected is the external rectus.

Ocular paralyses differ in type according as they are due to a supra-nuclear lesion (between the second frontal gyrus and the ocular nuclei), a nuclear lesion in the mid-brain, or an infra-nuclear lesion of the individual nerves such as we have just described.

Ocular paralysis from a **supra-nuclear lesion** never attacks a single ocular muscle or even a single eye. On the contrary, associated muscles of both eyes are affected. The common type of paralysis from a destructive lesion at or above the internal capsule is one in which the patient loses the power of turning both eyes towards the

contra-lateral side. Therefore the unopposed antagonists draw both eyes over towards the side of the lesion; this is called *conjugate deviation*. In certain cases of conjugate deviation, although the patient can no longer turn his eyes voluntarily to one side, say the right, he can do so reflexly by fixing some object directly in front with his eyes, this object being then moved towards the right or the patient's head being passively rotated to the left.[1] Curiously enough, conjugate deviation upwards or downwards does not occur from a paralytic lesion of the internal capsule, unless a bilateral lesion be present.

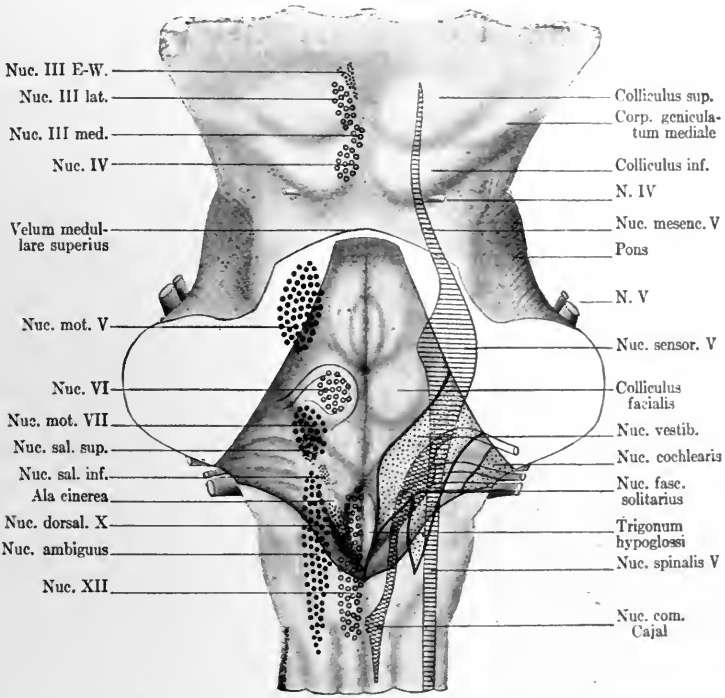

FIG. 68.—Dorsal view of mid-brain and medulla, with positions of various cranial nerve nuclei.

In supra-nuclear lesions *reflex nystagmus* is still preserved. Bárány[2] has shown that reflex nystagmus can be produced in normal individuals in two ways. Firstly, there is *optic nystagmus*, produced by making the patient watch a rapidly-moving landscape when looking out of the window of a railway carriage, or by making him watch a series of vertical bars on a horizontally revolving cylinder. Secondly, there is *vestibular nystagmus*, produced either by rapid rotation of the

[1] Bielschowsky, *Münchener medizinische Wochenschrift*, 1903, s. 1666.
[2] Bárány, *ibid.*, 1907, s. 1072.

individual on a revolving chair (rotation to the right producing horizontal nystagmus to the left and *vice versâ*), or by syringing the ear with cold water, stimulation of the right ear producing nystagmus, partly horizontal but mainly rotatory, to the left and *vice versâ* (see above, p. 130). If the vestibular nerve be diseased, reflex vestibular nystagmus is abolished.

Skew deviation of the eyes occurs in certain acute lesions of the lateral lobe of the cerebellum or of its middle peduncle. Thus in a woman with a fatal hæmorrhage in the right half of the cerebellum and pons, the right eye was directed downwards and inwards, and the left eye upwards and outwards.

A nuclear lesion of the third, fourth, or sixth nuclei in the floor of the Sylvian aqueduct may be partial or complete, and the type of ocular palsy which results is called **nuclear ophthalmoplegia.** In some cases the fibres for the ciliary ganglia, or the ganglia themselves, or short ciliary nerves to the internal ocular muscles (iris and ciliary muscle) are alone affected, and not the external muscles of the globe. The result is **ophthalmoplegia interna,** in which the pupils are dilated and immobile both to light and on convergence. This condition may be unilateral or bilateral, according as the ciliary ganglia or short ciliary nerves are affected on one or both sides. It often occurs as a transient result of post-diphtheritic neuritis. **Ophthalmoplegia externa** is a nuclear disease of the Sylvian aqueduct affecting numerous external ocular muscles, generally of both eyes and often symmetrically. A fairly common type is where the power of upward rotation of the eyes is lost, lateral movements being still possible. Ophthalmoplegia externa usually occurs alone, less commonly it is associated with the internal variety. When both varieties are combined we have **total ophthalmoplegia,** in which the eyes are fixed and motionless, the pupils being immobile, both varieties of reflex nystagmus (optic and vestibular) being lost, and the patient can look in any particular direction only by facing his head that way *en bloc.*

Chronic nuclear ophthalmoplegia, of slow onset and progressive course, is sometimes due to the toxins of syphilis or of disseminated sclerosis.

Acute nuclear ophthalmoplegia, of rapid onset, sometimes follows acute fevers, *e.g.* enteric fever, dysentery, or influenza. It also occurs as part of a primary disease, known as **encephalitis lethargica.** Like acute poliomyelitis (see p. 218), which in some respects it resembles clinically, although its rate of onset is slower, as a rule, it may occur in epidemic form. The toxin of encephalitis lethargica has a selective action upon the oculo-motor nuclei in the floor of the aqueduct, and may also extend bilaterally down to other motor nuclei, such as those

of the facial nerves, and even to the motor nuclei of the palate, larynx and tongue. After an incubation period of a few days, nuclear ophthalmoplegia rapidly develops, both external and internal, together with moderate pyrexia and profound lethargy, so that the patient is drowsy and stuporose; he also has severe and widespread muscular asthenia. Nevertheless, inasmuch as the long sensory and motor tracts in the brain-stem are unaffected, there are no sensory phenomena, nor is there any paralysis of the limbs, whose reflexes remain unaffected. Retention of urine, however, is a common symptom. In a few cases, where the virus exercises a selective action on the pallidal system of the corpus striatum, the clinical picture, developing within a few days, is that of acute paralysis agitans, with its characteristic facies, posture, rigidity, and tremors. The cerebro-spinal fluid is usually normal; sometimes it contains a few extra lymphocytes. The duration of the stupor may vary from a few days in some cases to several weeks in others.

An interesting sub-variety of acute nuclear ophthalmoplegia, known as **botulism**, is due to poisoning by meat, cheese, or fish, infected with an anaerobic organism, the *Bacillus botulinus* (botulus = a sausage), the toxins of which have a selective action upon the cranial nerve nuclei. The symptoms resemble those of encephalitis lethargica, but in addition there is sometimes a toxic erythematous rash, and the salivary secretion is diminished, so that the mouth becomes abnormally dry.

The prognosis of acute toxic ophthalmoplegia, whether of the epidemic lethargic type or of the less common botulism, is grave, but not necessarily hopeless. Even in severe cases, the disease may run an afebrile course, and recovery, complete or partial, may occur after several weeks, if the nerve-cells have escaped disintegration. In fatal cases, death occurs from respiratory failure.

Nuclear ophthalmoplegia, especially external ophthalmoplegia, may be associated with motor paralysis of the limbs if the lesion extends ventrally and implicates one or other pyramidal tract; or it may be associated with involuntary tremors if the lesion affects the red nucleus or rubro-spinal tract (Fig. 20, p. 20).

Sometimes it is possible to differentiate between a nuclear and an infra-nuclear ocular lesion. In the case of *paralysis of the sixth nucleus* in the pons, there is not merely weakness of the external rectus of the same side, as in paralysis of the sixth nerve trunk, but in addition the internal rectus of the opposite eye is paralysed, so that conjugate movement of both eyes towards the affected side is impaired. The weakness of the contra-lateral internal rectus is only in connection with its associated movement with the external rectus of the ipso-lateral eye. This is proved by the fact that, in paralysis

limited to the sixth nucleus, both internal recti can still act normally during convergence. Again, since the facial motor root loops round the sixth nucleus within the pons, a lesion of the sixth nucleus is not infrequently accompanied by facial paralysis on the same side. The sixth nucleus is essentially an oculogyre centre, turning both eyes to the corresponding side, and therefore controlling not only the external rectus of the ipso-lateral side, but also the internal rectus of the contra-lateral side.

With regard to the diagnosis between nuclear and infra-nuclear paralysis of the third nerve; if in a doubtful case the orbicularis oculi is found to be affected together with the external ocular muscles, then the lesion is in the region of the nucleus, since the orbicularis is innervated by a group of cells which are in anatomical proximity to the oculomotor nucleus (but which really belong to the facial).

Mendel's theory[1] assumed that these cells belonged to the oculomotor nucleus and reached the orbicularis through the facial, but Bishop Harman[2] has shown that all the facial muscles, from orbicularis oculi downwards, are innervated from the group of cells comprising the facial nucleus, the upper end of this group extending as high as the oculomotor and the lower end reaching to the level of the hypoglossal.

Sometimes transient ocular palsy affects the third nerve in whole or in part, recurring in the same eye without apparent cause at intervals of weeks or months, and clearing up completely between the attacks. This condition, known as *migraine ophthalmoplégique*, is generally associated with headache, most intense in the eye and forehead of the affected side, and with vomiting. Its pathology is obscure; probably some cases are due to an inflammatory affection of the meninges at the point where the third nerve pierces them to enter the sphenoidal fissure. This is all the more probable inasmuch as the first division of the fifth nerve, which traverses the sphenoidal fissure, is often simultaneously affected, with the result that there is blunting of sensation in its area of distribution.

Now and then we meet with **congenital ptosis**, in which there is paralysis of the superior rectus and levator palpebræ superioris of one eye. In some of these cases, although the patient cannot raise his upper lid voluntarily, yet, curiously enough, the lid is jerked up when certain jaw movements are made, particularly when the patient throws into action the external pterygoid muscle of the same side, in depressing the lower jaw towards the opposite side.

This so-called "**jaw-winking**" movement has been suggested by Harman to be the survival of a movement in fishes whereby, when the mouth is opened for breathing or eating, the gill swings open.

[1] *International Med. Congress, Washington*, 1887, vol. v., p. 311.
[2] *Transactions of Ophthalmological Society*, 1903, p. 356.

In man the pterygoid and orbicularis oculi muscles are homologous with the deep and superficial muscles of the branchial arch of the fish's spiracle, and when the one is contracted the other tends to relax and "the weak levator, taking advantage of the quiescence of its too powerful opponent, lifts the eyelid."

Jaw-winking movements generally disappear before adult life.

The Fifth or Trigeminal Nerve has an extensive distribution, of which the main points are as follows:—

The nerve consists of two distinct parts, sensory and motor. The sensory root, the one on which is a large flattened ganglion—the Gasserian ganglion—divides below the ganglion into three divisions, of which the first two are entirely sensory. The motor root courses beneath the Gasserian ganglion, and then joins the third division, which thus becomes a mixed nerve.

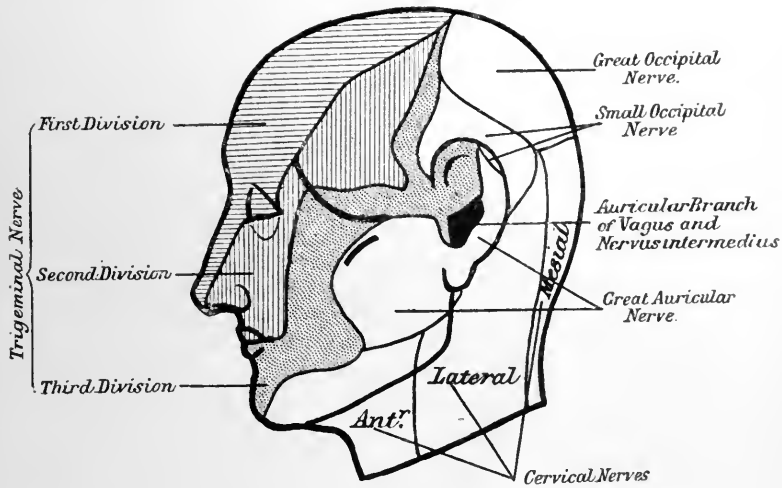

Fig. 69.—Cutaneous supply of head (modified from Frohse).

The *first or ophthalmic division* passes through the sphenoidal fissure into the orbit and supplies the eyeball and lachrymal gland, the conjunctiva (except that of the lower lid), the skin of the forehead and scalp up to the vertex (Fig. 69), the mesial part of the skin of the nose, and the mucous membrane of the upper part of the nasal cavity. It also contains efferent pupil-dilating fibres derived from the cervical sympathetic, joining it at the Gasserian ganglion, and going to the iris (Fig. 61).

The *second or superior maxillary division* passes through the foramen rotundum across the spheno-maxillary fossa to the infra-orbital canal. In the spheno-maxillary fossa it is connected with Meckel's ganglion, which gives off amongst other branches the Vidian nerve. This latter runs backwards to join the facial nerve, the posterior end of the Vidian being named the great superficial petrosal (Fig. 70). The superior maxillary division supplies the skin of the upper lip, the side of the nose and the adjacent part of the cheek, the lower eyelid and part of the temple. It

also supplies the conjunctiva of the lower lid, the upper teeth, the mucous membrane of the upper lip, the upper part of the cheek, upper jaw, hard palate, uvula, tonsil, naso-pharynx, middle ear and lower part of nasal cavity. It also contains some taste fibres to which we shall refer presently.

The *third or inferior maxillary division* is a mixed nerve. It emerges through the foramen ovale. The motor fibres supply the masseter, temporal, and both pterygoid muscles, also the tensor palati, tensor tympani, mylohyoid and anterior belly of the digastric. The sensory fibres supply the skin of the posterior part of the temple and adjacent part of the pinna, the anterior and upper wall of the external auditory meatus, as far as and including the anterior part of the drum, part of the cheek, the lower lip and chin, also the lower teeth and gums, the tongue (as far back as the circumvallate papillæ), floor of mouth, inner surface of cheek, and salivary glands.

The **Course of the Taste Fibres** is a complicated one and still much disputed[1] (Fig. 70). Those for the anterior two-thirds of the tongue are contained in the lingual nerve—a branch of the third division. But they do not run straight up from the lingual into the fifth nerve. They leave the lingual, course along the chorda tympani, and reach the facial within the Fallopian aqueduct. They run in the facial as far as the geniculate ganglion, where some may pass off along the great superficial petrosal to Meckel's ganglion, ultimately rejoining the fifth nerve through its second division. Most of the taste fibres leave the geniculate ganglion to enter the nervus intermedius, passing thence to the glosso-pharyngeal nucleus.

The taste fibres for the posterior third of the tongue and the palate which are supplied by the glosso-pharyngeal nerve, probably enter the brain through the glosso-pharyngeal. They do not join the fifth nerve, since division of the fifth nerve by the operation of removal of the Gasserian ganglion causes impairment of taste only in the anterior two-thirds of the tongue, and not constantly in that. Taste is not abolished in fifth nerve palsy, as was formerly thought, for in several cases of excision of the Gasserian ganglion I have found that the patient, though unable to feel the contact of food or other objects on the affected side, still retained acute sense of taste at the back of the tongue.

To examine the sense of taste we direct the patient to protrude the tongue, and we rub on it various substances such as sugar, salt, quinine, and citric acid, preferably in white powders, which the patient cannot distinguish at sight one from the other. The patient must keep his tongue protruded throughout each test, and as soon as he feels a taste he should make a sign and also determine in his mind what the taste is, before taking the tongue in. It is convenient to have a card with the following words printed on it:—"sweet," "sour," "bitter," "salt," "coppery." The patient can then point with his finger to indicate which taste he perceives. If he be allowed to pull the tongue in while waiting for the sensation to arrive, fallacies may occur owing to movements of the tongue, and the flow of saliva carrying the substance to other parts. To map out exactly an area

[1] Cushing, *Johns Hopkins Hospital Bulletin*, 1903. Nos 144-145. Davies, *Brain*, 1907, p. 219.

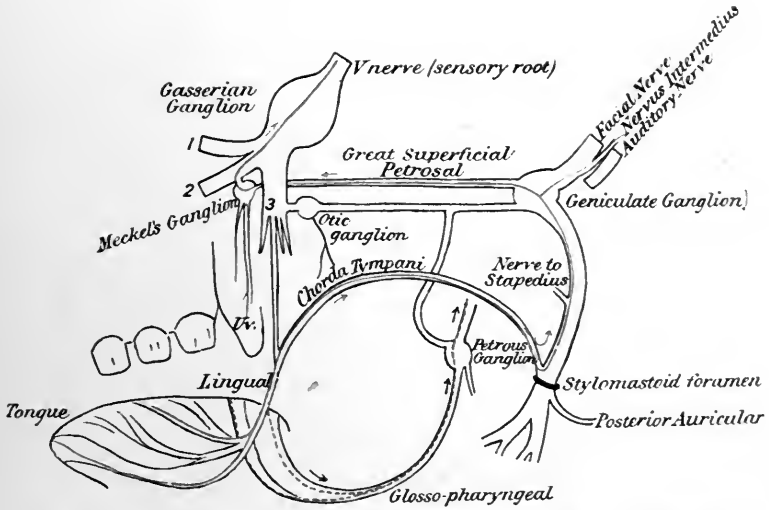

FIG. 70.—Diagram of trigeminal, facial, and glosso-pharyngeal nerves, showing course of taste fibres.

To face page 140.

of loss of taste (*ageusia*) the most accurate method is to use a weak galvanic current with a wire electrode, which produces a coppery or metallic taste.

When the fifth nerve is totally paralysed there is anæsthesia of the corresponding half of the face and scalp, not extending as far as the angle of the jaw, this part being supplied by the cervical plexus (Fig. 69). The cornea and conjunctiva on the affected side are anæsthetic, and also the mucous membrane of the corresponding side of the nose, mouth, part of the soft palate and tongue, as far back as the circumvallate papillæ which, with the area behind, are innervated by the glosso-pharyngeal. This defect extends exactly to the middle line, and therefore the patient when drinking feels as if the cup were broken. Food tends to collect within the anæsthetic cheek, the buccinator muscle being anæsthetic, though its motor power is unaffected. Taste is impaired in the anterior two-thirds of the tongue, but does not remain totally lost. The trigeminal nerve has also sensory fibres for the facial muscles. Hence there is a degree of awkwardness and apparent weakness of the face—a pseudo-facial palsy, due to loss of the sense of active muscular contraction. All the muscles supplied by the motor root undergo atrophic paralysis and develop the electrical reactions of degeneration. There is hollowing of the temporal fossa above the zygoma, and wasting of the masseter below it, so that the zygoma becomes abnormally prominent. When the patient clenches his teeth, neither the temporal nor the masseter can be felt to harden as on the normal side, and when he depresses his chin the mandible is pushed over towards the paralysed side (Fig. 71). This is owing to paralysis of the external pterygoid, which fails to draw the condyle forwards on the affected side. The deflected mandible carries with it the tongue, but there is no real deviation of the tongue, when measured from the middle line of the lower incisors. Paralysis of the mylohyoid is sometimes evidenced by a relative flaccidity upon upward pressure on the floor of the mouth on the affected side. It is stated that paralysis of the tensor tympani causes a difficulty in hearing notes of low pitch, but this is not easy to determine. Secretion of tears on the paralysed side is diminished, as is also the secretion of nasal mucus and of saliva. Consequently these mucous membranes become abnormally dry, and may show secondary trophic changes. Thus stimulation of the nasal mucous membrane by snuff no longer causes sneezing. Smell at first is unimpaired, but later, from dryness and secondary trophic changes in the Schneiderian membrane, there may be anosmia in the affected nostril. The corneal and lachrymal reflexes are lost, also the palatal reflex. The tongue on the paralysed side becomes excessively

furred, probably because on the anæsthetic side there is deficient friction by food. The teeth on the paralysed side are anæsthetic and tend to drop out; this has been ascribed to a trophic change, but more probably it is mainly traumatic, the patient biting clumsily with his anæsthetic teeth. It used to be stated that neuro-paralytic keratitis occurred in total trigeminal palsy, owing to trophic changes. But this is not invariably so; when it does occur, it appears to be due to the presence of a special bacillus[1] in the anæsthetic eye, where, moreover, there is a deficiency of lachrymal secretion. Further, if the anæsthetic lids be kept closed by a suture, keratitis does not occur, even though the special bacillus be present.

Fig. 71.—Paralysis of *Left third* and of *Right fifth* nerve. The patient is looking upwards and opening the jaw. Showing dilatation of pupil on left side with deficient upward movement of left eye. Also showing the deviation of the lower jaw towards the right side. The black line indicates area of anæsthesia on the right side of the face.

There is another disease which occurs in the territory of the fifth nerve, viz. **progressive facial hemiatrophy.** This disease, which commences in early life—usually before puberty, and more often in females than in males—shows itself first in the skin of the face, either near the orbit or over the upper or lower jaw, gradually spreading over the whole face on one side. The skin becomes thinned from atrophy of its papillary layer, the subcutaneous fat disappears, and thus the affected side of the face becomes wrinkled and furrowed, in marked contrast with the healthy side. Later the subjacent muscles, cartilages, and bones become atrophic, but without motor paralysis or reaction of degeneration. The corresponding side of the tongue (Figs. 72A and 166A), and occasionally that of the soft palate, also become wasted. But the hemiatrophied tongue, when protruded, comes out straight, unlike that of a patient with atrophy from hypoglossal palsy (Fig. 84, p. 164). The hair on the affected side of the face may fall out or become white, and the sebaceous glands may atrophy. The scalp is rarely affected. There is no anæsthesia.

[1] Davies and Hall, *British Medical Journal*, 1908, p. 72.

The area of this disease corresponds accurately with that of the distribution of the fifth nerve, and in certain cases pathological changes have been found either in the nerve itself or, more constantly, in its nucleus of origin. Thus Mendel found signs of neuritis in the nerve, together with changes in the spinal root of the fifth within the medulla. More

FIG. 72. FIG. 72A.

From a case of left-sided facial hemiatrophy. Showing atrophy of corresponding half of tongue.

recently Loebl and Wiesel[1] found an interstitial neuritis of the Gasserian ganglion and of the parts distal to it. Removal of the Gasserian ganglion does not produce hemiatrophy.

Facial hemiatrophy may also be a symptom of syringobulbia, in which case we have the characteristic "dissociated" anæsthesia and other phenomena (see p. 198).

[1] *Deutsche Zeitschrift für Nervenheilkunde*, 1904, Bd. 27, s. 355.

CHAPTER X

CRANIAL NERVES (*continued*)

Of all the peripheral nerves in the body, cranial or spinal, the **Seventh** or **Facial nerve** is by far the most frequently paralysed, hence the importance of knowing its anatomical course and distribution. Like the trigeminal, it is a mixed nerve, possessing a motor root—the facial nerve proper, and a sensory root—the nervus intermedius of Wrisberg. These two roots meet at the geniculate ganglion.

Let us first consider the **motor root.** Arising from a nucleus situated mainly in the lower part of the pons, but some of whose cells (namely, those for the orbicularis oculi) extend as high as the nucleus of the third nerve, and others (namely, those for the orbicularis oris) are as low as the hypoglossal nucleus, the motor root of the facial pursues a tortuous course. Firstly, within the substance of the pons it forms a loop which hooks round the nucleus of the sixth nerve. Then, leaving the ventral surface of the brain-stem, it enters the internal auditory meatus, and passes along a winding bony canal in the temporal bone—the aqueduct of Fallopius. In the upper part of this canal it traverses a swelling, the *geniculate ganglion*, which is joined by the sensory root or portio intermedia of Wrisberg, also by the great superficial petrosal nerve from Meckel's ganglion, and by the small superficial petrosal from the otic ganglion (see Fig. 70). The otic ganglion is constituted by nerve-cells similar to those of the sympathetic ganglia; the geniculate ganglion is similar in structure to a posterior root-ganglion and is sensory in function. Inflammation of this ganglion is accompanied by herpes of the external auditory canal and adjacent part of the auricle, exactly analogous to herpes zoster[1] (see Fig. 69, p. 139). Within the aqueduct the facial gives off a branch to the stapedius, and, lower down, the chorda tympani leaves it to join the lingual nerve. It then emerges from the skull through the stylo-mastoid foramen, giving off a posterior auricular branch to the muscles of the pinna and to the occipital belly of the occipito-frontalis. The main trunk then divides into its terminal branches, supplying all the muscles of the face (except the levator palpebræ superioris) from the frontalis above to the platysma below. It also supplies the stylohyoid and posterior belly of the digastric.

The facial nerve also contains efferent "autonomic" secretory fibres, whilst the taste-fibres of the chorda tympani accompany the motor portion of the nerve in part of its course. Thus lesions at different levels can be distinguished one from the other.

1. If the facial nerve is affected *after its exit from the stylo-mastoid*

[1] J. Ramsay Hunt, *Journal of Nervous and Mental Diseases*, 1907, p. 73.

foramen, *e.g.* by cold, or by injuries or tumours in that region, the result (**Bell's Paralysis**) is complete palsy of that side of the face, which is therefore asymmetrical at rest, and the asymmetry is exaggerated on voluntary movement. The patient has neither emotional nor voluntary movement of the affected side (Figs. 73 and 73A).

The furrows of the forehead are wiped out, and the patient cannot wrinkle the brow nor frown on that side. The eye is more widely open on the affected side and cannot be shut. The tears run down the cheek instead of into the lachrymal duct, and may produce ex-

FIG. 73. FIG. 73A.

Case of left-sided facial palsy. Fig. 73 at rest. Fig. 73A on attempt to close eyes and retract angles of month.

coriation of the skin or eczema. When the patient tries to shut the eye he merely rolls the eyeball upwards and outwards, or upwards and inwards, sometimes with a zig-zag movement, until the cornea passes under cover of the upper lid. An additional sign, the "levator" sign, pointed out by Dutemps and Cestan,[1] is as follows:—When the patient looks down and then attempts to shut both eyes slowly, the upper lid on the paralysed side is seen to move up a little (see Figs. 74 and 74A), owing to contraction of the levator palpebræ, which normally acts synergically with the orbicularis but is now no longer antagonised by it. Another sign is Negro's[2] hyper-kinetic sign of the eyeball and upper lid. When the patient looks upwards to the full extent the two eyeballs become asymmetrically placed. On the paralysed

[1] *Journal de Neurologie*, 1904, p. 48.
[2] de Castro, *Revue neurologique*, 193, No. 3, p. 149.

side the globe deviates outwards and then comes to rest at a higher level than on the normal side, probably owing to over-innervation of the superior rectus muscle.

The inability to close the eye allows the entrance of foreign bodies, and consequently conduces to conjunctivitis. The corneal reflex is abolished, and the regular involuntary blinking of health no longer occurs on the paralysed side. The eye brims over with tears, so that vision on the affected side is rendered less acute. Curiously enough, though the eye cannot be shut during waking hours, during sleep it often closes almost completely, probably from relaxation of the levator palpebræ.



FIG. 74. FIG. 74A.

FIG. 74.—Case of right-sided facial palsy: patient looking downwards at observer's finger.
FIG. 74A.—The patient closes both eyes: observe the elevation of the right upper lid.

The tip of the nose is drawn somewhat towards the sound side, the naso-labial fold on the affected side is flattened out, the ala nasi sinks in and shows no active movement, voluntary or respiratory, though it may flap passively during forcible nasal breathing. The mouth is drawn towards the sound side, but on the affected side its angle droops and saliva dribbles from it. When the patient smiles or shows the upper teeth, the healthy side moves alone; he cannot whistle, and the articulation of labial consonants is impaired. During mastication food accumulates between the teeth and the paralysed cheek. The patient often bites his cheek or lower lip, and during forcible blowing expiration the paralysed cheek flaps loosely. Voluntary movement of the integument by the platysma, as in forcible depression of the chin against resistance, is abolished on the affected

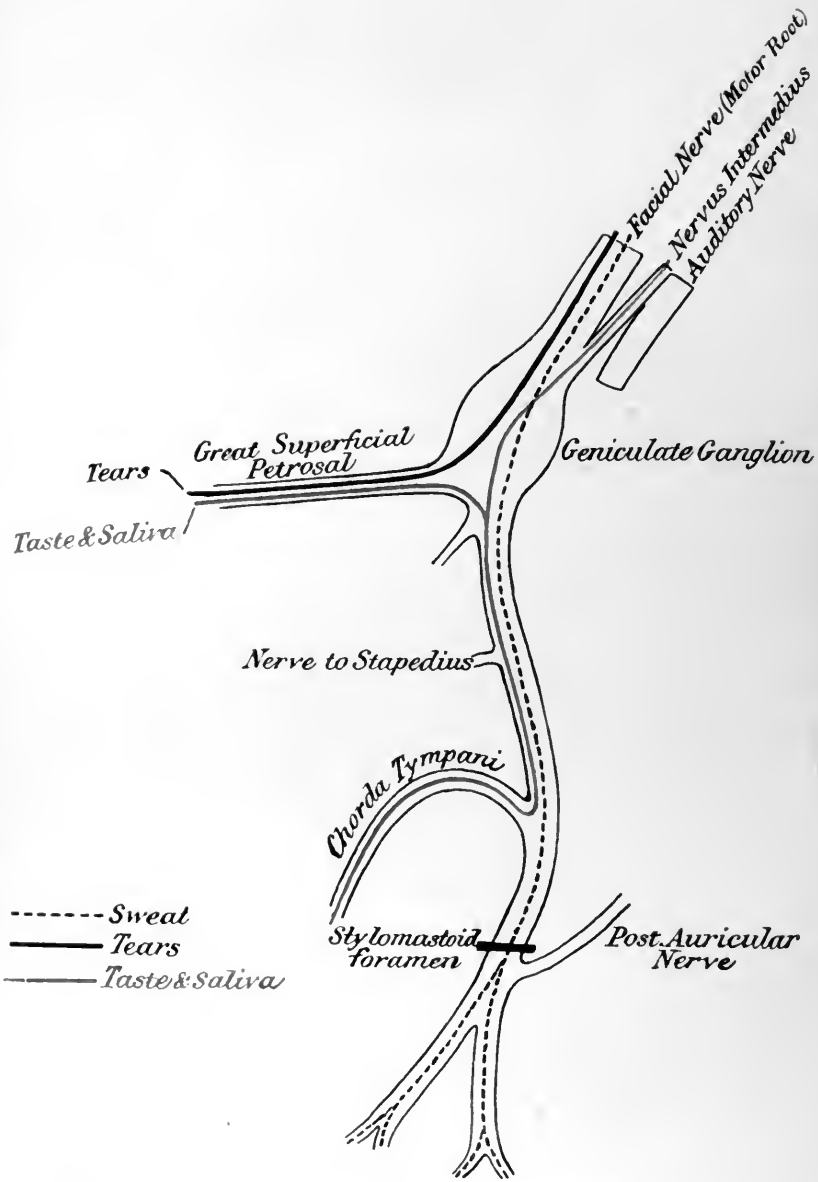

FIG. 75.—Diagram of facial nerve, showing course of secretory and of taste-fibres.

To face page 147.

side. In those patients who were previously able to move the ear voluntarily, that power is also lost. All the paralysed muscles gradually develop the electrical reactions of degeneration. The affected side of the face generally sweats less than the healthy side.

2. If the lesion be *within the Fallopian aqueduct* below the geniculate ganglion, it produces all the above symptoms, and, in addition, from implication of the chorda tympani, there is loss of taste (and sometimes slightly of common sensation) in the anterior two-thirds of the tongue on the affected side, and also occasionally abnormal subjective sensations of taste, and sometimes diminution or excess of submaxillary and sublingual saliva. The deficiency of taste and of saliva may cause this part of the tongue to be abnormally furred up to the middle line. If there be paralysis of the nerve to the stapedius, there is *hyperacousis* or painful sensitiveness to loud sounds[1] (presuming that the auditory apparatus is not affected), and the patient can no longer produce the subjective noise in the ear, which we normally hear on attempting very forcibly to innervate the facial muscles, especially the orbicularis palpebrarum.

3. If the motor root of the nerve be affected *between its emergence from the pons and the geniculate ganglion*, it produces the same symptoms as in Bell's paralysis, but without affection of taste in the front of the tongue. And since disease in this region almost invariably implicates the auditory nerve, there is usually deafness also. If the auditory nerve chances to escape, hyperacousis will occur from stapedius paralysis. Many cases have deficiency of tears on the affected side. Most cases of basal intra-cranial disease present general symptoms also, such as headache, giddiness and vomiting.

4. If the lesion of the motor root be *within the substance of the pons*, facial palsy results as in Bell's paralysis, but taste and hearing are unaffected. There is, however, usually an accompanying paralysis of the sixth nerve or its nucleus, since the facial motor root hooks round the sixth nucleus within the pons.

Paralysis of the soft palate used to be included in the symptoms of a lesion of the facial nerve at or above the geniculate ganglion. But the weight of evidence goes to prove that the facial has no share in the innervation of the palate. Chvostek,[2] in 1883, published a case of sarcoma of the facial nerve in which paralysis of the palate had been observed, but that was before the days of the Marchi method, and it is impossible to be sure that the lower roots of the vagus were undegenerated. In his case there was also a cancer in the tongue.

[1] Moos (*Zeitschrift für Ohrenheilkunde*, vol. viii., p. 221) records a case in which the hyperacousis was specially for low-pitched notes.

[2] *Wiener medizinische Presse*, 1883, s. 34.

Slight cases of facial palsy, whether due to cold, middle-ear affection, compression, or other causes, may recover completely in one or two weeks. More severe cases last from two to eight months before recovery begins. Or the palsy may remain permanent. In severe cases, in which improvement does not begin for three months or more, a spastic or contractured condition usually comes on as voluntary power reappears. The mouth becomes drawn back again towards the paralysed side, the palpebral fissure, instead of being wider, is narrower than on the healthy side, and the naso-labial and other furrows not

FIG. 76. FIG. 76A.

Case of left-sided facial palsy with contracture. Fig. 76 shows position at rest. Fig. 76A shows maximum voluntary movement.

only reappear, but become exaggerated. The result is that, at rest, the healthy side may seem the weaker of the two, though when voluntary movement takes place it is easy to see which is the affected side (see Figs. 76 and 76A). Together with this contracture there is always in the spastic muscles a tendency to associated movements. Thus, on screwing up the eye on the affected side, the angle of the mouth becomes drawn outwards; or again, on showing the upper teeth, the eye becomes closed. Sudden flickers of involuntary fibrillary tremors may sometimes be seen on the affected side. The spastic facial muscles can also be made to contract reflexly by tapping lightly over the point of emergence of the most accessible branch of the fifth, viz. the supraorbital nerve.[1]

[1] Mondino, *Rivista di patologia nervosa e mentale*, 1907, p. 49.

Secondary contracture occurs only in cases of incomplete recovery. During the stage of total paralysis, when no impulses are reaching them, the muscles are quite flaccid. The development of contracture indicates that nerve and muscular regeneration are imperfect. It may be that whilst highly-specialised pyramidal impulses fail to reach the affected muscles, the more primitive extra-pyramidal impulses (subservient by less highly differentiated nerve-fibres and muscle-fibres) are the only ones which have reappeared, producing hyper-tonicity and associated movements.

FIG. 77. FIG. 77A.

FIG. 77.—Bilateral facial palsy, alcoholic in origin, associated with peripheral neuritis of upper and lower limbs.

FIG. 77A.—Maximum voluntary movement of face, on attempting to close the eyes and to retract angles of mouth.

Bilateral facial palsy is rare. It may be due either to intra- or extra-cranial causes, the commonest intra-cranial cause being gummatous basal meningitis. Of the extra-cranial causes, the most important are double otitis media, cold, and post-diphtheritic paralysis. Alcoholic paralysis rarely attacks the facial nerve, but when it does, the affection is bilateral, as in the case of the man shown in Figs. 77 and 77A, who also had typical alcoholic neuritis of the limbs.

In bilateral facial palsy there is no asymmetry of the face, but it hangs like a fixed expressionless mask, incapable of evincing the slightest emotion.

Bilateral facial weakness also occurs in the "facio-scapulo-humeral" type of myopathy, to which we shall refer in a later chapter.

Nervus Intermedius of Wrisberg, or Sensory Root of the Facial.—Between the facial motor root and the auditory nerve at the floor of the cranial cavity, and entering the internal auditory meatus along with them, there is a slender fasciculus, known as the *portio intermedia*.

The fibres of this nerve are remarkably small in calibre. Their trophic centre is in the cells of the geniculate ganglion. Centrally the fibres run into the medulla, alongside the fibres of the auditory nerve, to join a nucleus closely connected with that of the glosso-pharyngeal. Peripherally from the geniculate ganglion fibres run along the great and small superficial petrosal nerves; others along the trunk of the facial, in the chorda tympani.

The cutaneous area of the geniculate ganglion, according to Ramsay Hunt's observations,[1] includes the tympanic membrane, the external auditory meatus and adjacent skin of tragus, anti-tragus, concha, and part of the lobule. The geniculate ganglion also receives sensory fibres from the inner ear and from the middle ear with its prolongations (Eustachian tube and mastoid cells).

The nervus intermedius conveys taste impulses from the anterior two-thirds of the tongue upwards to the brain, by way of the glosso-pharyngeal nucleus (Fig. 75, p. 147). It also contains autonomic efferent secretory fibres which join the submaxillary ganglion and innervate the sublingual and submaxillary salivary glands.

Inflammation of the geniculate ganglion, analogous to inflammation of the posterior root-ganglion in herpes zoster, as Hunt has pointed out, produces characteristic symptoms. These consist in deep-seated pain in the ear and mastoid region, with herpes of the auricle and external auditory canal. If the inflammation be intense enough to implicate the motor fibres of the facial there is facial palsy also, with loss of taste in the chorda tympani distribution. If the auditory nerve be implicated there is vertigo, tinnitus, deafness and even nausea and vomiting.[2]

The **Eighth** or **Auditory Nerve** comprises two entirely dissimilar sets of fibres (see Fig. 30, p. 40). Firstly, there are **cochlear fibres** from the auditory labyrinth, subserving the function of hearing. Secondly, there are **vestibular fibres** from the semicircular canals or static labyrinth; these fibres constitute the most important nerve of equilibration, informing us of variations in the position of our head in space, but without producing conscious sensations. The central connections of the cochlear and vestibular nerves are also fundamentally different (see p. 40). Affections of the cochlear fibres produce auditory phenomena, while disease of the vestibular fibres causes one form of vertigo, though vertigo and other auditory symptoms often result not only from disease of the labyrinth or vestibular fibres, but from affections of the middle or even of the outer ear.

[1] *Brain*, 1915, vol. xxxviii., p. 418.
[2] See a case by Arthur Cheatle, *Trans. Otological Soc.*, vol. ii., p. 6.

The chief symptoms referable to the auditory nerve are deafness, tinnitus and vertigo.

In a patient who is apparently deaf we should always, before proceeding to test the hearing, examine the external auditory meatus, to make sure that it is not blocked, *e.g.* by wax. We then test *aerial conduction* by the ticking of a watch, the patient's eyes being shut and one ear closed while the other is being tested. Holding the watch at some distance from the ear, we slowly bring it nearer until the patient can just detect the tick. The distance at which this is heard should be expressed as a fraction, the denominator of which is the distance at which a normal ear hears the watch. If there is **deafness,** we have to determine whether this is due to middle-ear disease or to affection of the labyrinth or auditory nerve. The *tuning-fork tests* help us here. First, we try the "lateralising test" (Weber's). Normally a vibrating tuning-fork, preferably C^1 (=256 vibrations per second), placed on the vertex or centre of the forehead, is heard equally in both ears, and if one ear be temporarily closed by the finger, the note is heard louder on that side. Next, we compare the relative bone and air conduction (Rinne's test). The tuning-fork is pressed firmly on the mastoid process. We then wait till it is no longer heard through the bone, and find normally that it is still audible when held close to the external meatus.

If the middle ear be diseased, or if the outer ear be blocked up, there is loss of aerial conduction, but bone-conduction is still preserved. The tuning-fork on the vertex is then heard louder on the affected side ("positive-Weber,") and Rinne's test is negative, *i.e.* the tuning-fork is no longer heard aerially after fading away on bone-conduction. But if the deafness be due to affection of the internal ear or of the auditory nerve—so-called "nerve-deafness," a tuning-fork on the vertex is not heard on the affected side ("negative-Weber"), whilst as a rule there is "positive-Rinne," though not always. In deafness from chronic middle-ear catarrh, the hearing is generally better in the midst of a noise (*e.g.* in an omnibus or railway carriage), than in a quiet place:—so-called *paracousis Willisii*,[1] whereas in nerve-deafness the reverse is the case. Additional localising evidence may also be obtained from the other concomitant symptoms. Thus gross disease of the auditory nerve within the skull, *e.g.* in a case of lateral extra-cerebellar tumour, is often accompanied by facial paralysis, though this conjunction is of value only when middle-ear

[1] Paracousis, according to some observers, is associated with abnormally low labyrinthine pressure, and the temporary improvement of hearing in such patients during a noisy journey, in a railway carriage or motor car, is due to a reflex contraction of the stapedius muscle pushing inwards the foot of the stapes and raising, for the time being, the pressure of the endolymph (see A. Cheatle, *Trans. Otol. Soc.*, 1900, vol. i., p. 52; also C. Heath).

disease can be excluded. On the other hand, disease of the labyrinth is often associated with tinnitus or vertigo, and labyrinthine deafness is specially characterised by loss of perception for high-pitched tones, as tested by Galton's whistle. Disease of the auditory nuclei within the pons may be associated with weakness of the motor facial nerve of the same side and paralysis of the opposite arm and leg.

Hysterical Deafness.—This is specially common as a war-neurosis. After a shell-explosion, especially one in which the soldier has been buried for a time, the patient sometimes has a condition of temporary paralysis of all his special senses, so that he is, for the time, blind and deaf (and often mute as well). This condition generally passes off in a few hours. But sometimes recovery is incomplete, and one of the special senses (most frequently that of hearing) remains *hors de combat*, even without any organic lesion of the auditory apparatus. The condition may last for weeks, or even months, but ultimately clears up.

In cases of deafness with the foregoing kind of history, we have, first of all, by careful examination, to exclude coarse organic lesions of the middle or inner ear, *e.g.* rupture of the tympanic membrane, fracture of the petrous bone traversing the labyrinth, or hæmorrhage within the labyrinth. The patient's general aspect often gives us a clue, although we must not forget that a hysterical subject may have an organic lesion also. Hysterical deafness is generally bilateral and, at first, absolute, whereas deafness from a permanent organic lesion is generally asymmetrical and incomplete. The most difficult cases are those in which the diagnosis lies between hysterical deafness and an organic labyrinthine lesion with true nerve-deafness. Occasionally a sudden and unexpected loud noise (*e.g.* that of a bicycle-horn a few feet away) produces a slight reflex contraction of the orbicularis oculorum in a patient with hysterical deafness, whereas in organic deafness this cochleo-orbicular reflex is absent. Finally, the thermic vestibular tests (p. 130) are often of special value. In organic lesions of the labyrinth we can no longer elicit vertigo or nystagmus by this means, whereas in hysterical deafness these reactions are normal, or even exaggerated in intensity.

Tinnitus, or ringing in the ears, is a subjective symptom. It signifies irritation of some part of the auditory apparatus. The term does not include elaborate auditory hallucinations of cortical origin, such as distinct melodies or voices uttering intelligible words. The nature of the sound in tinnitus varies in different cases; for example it may be buzzing, hissing or whistling. Broadly speaking, we recognise two main kinds of tinnitus—the pulsating and the continuous. *Pulsating* sounds, synchronous with the pulse, occur in a few intracranial aneurisms (sometimes audible by the physician on auscultation

of the skull), but are also not infrequent in simple neurasthenia in the "silent watches of the night," and in temporary Eustachian obstruction, as in some cases of coryza. Curious "clicking" sounds in the ear may result from clonic spasm of the tensor tympani muscle. *Continuous* sounds may be of high or low pitch. We should always observe whether they are increased or diminished by the recumbent posture. Low-pitched continuous tinnitus may be the result of venous hyperæmia, in which case it is aggravated by recumbency, or of simple anæmia, which is relieved by lying down. Nitrite of amyl aggravates tinnitus when due to hyperæmia and relieves it when due to anæmia. High-pitched continuous tinnitus is generally due to labyrinthine stimulation, either from outer or middle-ear affection (perhaps merely wax or water in the external meatus, an obstructed Eustachian tube, or an indrawn tympanic membrane), or from actual labyrinthine disease. It is also caused by certain drugs, notably by quinine and salicylates. Such drugs induce deafness as well as tinnitus, and the tinnitus may persist for weeks after the deafness has cleared up. Pulsating tinnitus due to arterial congestion can often be arrested temporarily by compression of the vertebral artery supplying the labyrinth, or of the carotid supplying the external or middle ear.[1]

Vertigo, or giddiness, is the peculiar, disagreeable sensation which results if our sense of secure equilibration is disturbed. The process of equilibration is a muscular act, in which all the muscles in question are innervated, of course, by the cerebral cortex, this latter being again largely influenced by the cerebellum.

The cerebellum is a co-ordinating centre for equilibration. It receives afferent impulses from various sources, of which the semicircular canals of the inner ear are by far the most important, the others coming from the skin of those parts on which the body happens to be resting, from the muscles and joints concerned in maintaining our balance, and from the muscles of the head and eyes concerned in looking towards surrounding objects. Each half of the cerebellum exercises a co-ordinating influence, through the corresponding superior cerebellar peduncle, upon the contra-lateral cerebral cortex, and thus upon the muscles of the ipso-lateral limbs.

Giddiness is often accompanied by a feeling of movement either in the patient himself (subjective vertigo) or in external objects (objective vertigo). Severe giddiness usually produces the motor phenomenon of reeling or staggering.

Vertigo may result from affection either of the higher cerebral centres or of the co-ordinating cerebellar centres, or from affection of any of the afferent paths to which we have already referred. Severe

[1] Dundas Grant, *Brit. Med. Journal*, Dec. 24, 1887.

vertigo is often accompanied by nausea and vomiting, as in sea-sickness.

Vertigo may occur in healthy people. Thus, for example, a galvanic current of 10 to 15 milliamperes passed transversely through the head produces a variety of giddiness probably due to labyrinthine stimulation. In this **galvanic vertigo** the patient tends to walk or fall towards the side of the positive pole, and his head and eyes are also rotated in that direction, accompanied by a rotatory nystagmus, until the moment of stopping the current, when he tends to fall towards the side of the negative pole.

Rapid rotation of the body round its own axis, as in waltzing, or rapid changes in our position in space, as in swinging, produce giddiness which is probably due to variations in the pressure of the endolymph within the semicircular canals.

Some people feel giddy when stepping unexpectedly from a firm surface on to a piece of boggy turf, or, as in a famous Edinburgh street, on to a piece of indiarubber pavement, this variety of vertigo being due to deficient sense of resistance conveyed from the skin of the soles and from the muscles and joints of the lower limbs.

The giddiness produced by standing near the edge of a cliff or of a high tower is most probably due to loss of muscular impressions from the ocular muscles. Ordinarily we have surrounding objects at or above our own level with which to compare our position in space, and if such objects are absent, vertigo may result.

Vertigo is also associated with various pathological conditions. Among the intra-cranial causes we may mention blows on the head (this variety is often relieved by repeated small doses, about $\frac{1}{100}$ grain, of perchloride of mercury),[1] and sudden *cerebral anæmia* or *hyperæmia*. A distinguished member of the medical profession who was the subject of aortic regurgitation used to have attacks of intense vertigo if he took a saline aperient. Probably in his case the withdrawal of a considerable amount of fluid from the circulation rendered the brain anæmic—hence the vertigo. It was always relieved by the recumbent posture, while cardiac tonics and the avoidance of hydragogue cathartics prevented its recurrence. Vertigo from cerebral hyperæmia is very common in women about the menopause, also in the arterio-sclerosis of chronic renal disease. In the latter class, relief is often obtained by the administration of iodides. It is still more marked in many cases of cerebral hæmorrhage or thrombosis, of which it may be a premonitory signal. Giddiness in old people with atheromatous arteries, if it be associated with headache, and especially if there be no sign of labyrinthine disease, should always be regarded seriously.

[1] Dundas Grant, *Clinical Journal*, Oct. 9, 1907.

Intra-cranial tumours may cause giddiness by raising the general pressure within the skull, and cerebellar tumours are especially associated with vertigo, even apart from increased intra-cranial pressure. *Intra-cerebellar tumours* of the lateral lobe produce a vertigo in which the subjective sense of rotation of the body is in the same direction as that of the apparent movement of surrounding objects, *i.e.* away from the side of the lesion. In *extra-cerebellar tumours*, while external objects appear to move away from the side of the lesion, the sense of subjective rotation is reversed, *i.e.* towards the side of the lesion.

A characteristic form of vertigo has also been described by Bruns,[1] and confirmed by various other observers.[2] It is produced by the presence of a *cysticercus in the fourth ventricle*. Sometimes the worm is anchored to the ependyma, sometimes it is swimming free. The patient, who otherwise shows no sign of intra-cranial organic disease, has paroxysms of violent vertigo, chiefly on sudden movement of the head, either active or passive, causing a temporary shifting of the position of the worm. He also has attacks of occipito-frontal headache with vomiting; his gait is tottering and unsteady, and glycosuria is not uncommonly present. The cerebro-spinal fluid may show eosinophilia, a sign which is practically pathognomonic, and there is usually also an increase of eosinophiles in the circulating blood. There may be intervals during which he is apparently well, and the case may be mistaken for hysteria. Death usually occurs suddenly from respiratory paralysis.

Vertigo is associated with certain degenerative diseases, notably with disseminated sclerosis. Vertigo is frequently the "aura" of an epileptic fit, or may accompany the headache of an attack of migraine. A hereditary family form of giddiness has also been described.

Toxic vertigo from alcohol or tobacco is a familiar type, and to the toxic class we may also refer cases produced by gastric disorder, by constipation, and by some cases of intestinal parasites, though in the last instance a reflex element may also be present. Giddiness is often present in neurasthenic and hysterical patients, in whom it may be elicited by the slightest exciting cause, for example by rectal examination.

Ocular vertigo occurs in cases of paralysis of any of the external ocular muscles, and is associated with diplopia. The visual field being erroneously projected, the patient judges wrongly as to the relation of his body to what he sees. "Objects appear to be in certain positions where the patient's feet, as a matter of fact, fail to find them" (Hughlings-Jackson). The giddiness in such cases is not due directly to

[1] *Centralblatt für Neurologie*, 1902, s. 565.
[2] Osterwald, *Neurologisches Centralblatt*, 1906, s. 265.

the diplopia, for it persists when the sound eye is covered. This condition can be imitated in health by closing one eye and displacing the other eye inwards by pressure with the finger, when if the individual tries to walk along a straight line his gait becomes very unsteady.

But in the majority of cases vertigo is associated with some disorder of the ear. It may result from wax, or foreign bodies in the meatus, or it may supervene during ear-syringing, especially if there be a perforation of the drum. The pathological cause may also lie in the middle ear, as in otitis media or obstruction of the Eustachian tube, or the condition may result merely from sneezing or blowing the nose, also from spasm of the tensor tympani muscle.

Lastly, there is what is known as **Ménière's disease** or **labyrinthine vertigo.** This has three main classes of symptoms: firstly, giddiness and reeling, due to affection of the semicircular canals; secondly, deafness and tinnitus, due to affection of the auditory fibres; and thirdly, associated bulbar phenomena, such as nausea and vomiting, cardiac failure, cold clammy sweat, etc., due to affection of adjacent medullary centres.

The vertigo of Ménière's disease is paroxysmal, and comes on with such suddenness that the patient may fall to the ground as if struck down by an unseen hand. In other cases he reels, but has time to clutch at some neighbouring object to prevent himself from falling. The giddiness lasts sometimes for hours; slighter attacks may pass off in a few minutes. It is increased by movement, and the slightest attempt to raise the head may induce vomiting. The direction in which the patient falls is usually forwards or towards one side, and commonly away from the side of the affected ear. Not infrequently nystagmoid jerks of the eyes occur during the attack, and double vision has also been observed. The vertigo is frequently accompanied or followed by headache, nausea and vomiting, lasting sometimes for hours. Together with these there are characteristic auditory phenomena, generally a sudden loud noise, usually unilateral. There is also deafness, more or less complete, on the same side as the tinnitus, with diminution or loss of bone-conduction. A certain degree of deafness and tinnitus remains between the attacks, but is rarely absolute.

Such symptoms, occurring with apoplectiform suddenness, constitute the typical picture of Ménière's disease. But frequently the paroxysms are much slighter, and unassociated with nausea or vomiting, so that the patient may simply have sudden transient giddiness. But the attacks tend to recur; rarely does a patient escape with a single attack. The intervals between them vary; they may gradually decrease in frequency, or may progressively increase until after suc-

cessive attacks the deafness becomes absolute. The vertigo then usually ceases.

Labyrinthine vertigo is distinguished from epileptic vertigo by the coexistence of vertigo with tinnitus and deafness. Loss of consciousness, which is the rule in epilepsy, is rare in labyrinthine vertigo. From cerebral hæmorrhage or thrombosis it is distinguished by the presence of auditory phenomena, and by the absence of signs of a focal brain lesion.

The pathology of Ménière's syndrome is obscure. Ménière himself described a hæmorrhagic effusion in the inner ear. But as Arthur Cheatle[1] has luminously suggested, the phenomena are in many respects closely analogous to those of glaucoma, and may possibly be due to a sudden rise of tension in the endolymph or perilymph, whether produced by hæmorrhage or other causes in the labyrinth or by sclerosis of the middle ear, whereby the *fenestra ovalis* and *fenestra rotunda* become fixed, thereby depriving the inner ear of safety-valves which normally permit of compensation for sudden changes in labyrinthine pressure. Labyrinthine vertigo often yields to bromides or to small doses (½ to 1 grain) of quinine.

A focal **lesion of Deiters' nucleus** produces sudden vertigo and reeling, together with nausea, acute distress, transient tinnitus or deafness, nystagmus, and sometimes pain in the distribution of the trigeminal nerve. All these phenomena are easily explicable when we remember the connection of Deiters' nucleus with the cerebellum and with the oculomotor nerves (see p. 40), and its close proximity to the sensory nucleus of the trigeminal.

No case of isolated palsy of the **Ninth** or **Glosso-pharyngeal Nerve** has yet been observed in man, so that its exact functions are not completely determined. Our chief information is derived from a study of lesions of the foramen lacerum posticum, in which the glosso-pharyngeal nerve is damaged in conjunction with the vagus and accessorius.

We know that it supplies taste-fibres to the posterior third of the tongue and to the soft palate. It probably also supplies the taste buds which exist on the epiglottis and on the arytenoid cartilage. The glosso-pharyngeal is also a nerve of common sensation for the back of the tongue, part of the soft palate and upper part of the pharynx. Its motor fibres supply the superior and middle constrictors of the pharynx, together with the stylo-pharyngeus. The superior constrictor is supplied through the pharyngeal plexus (constituted by pharyngeal branches from the glosso-pharyngeal, the vagus, and the cervical sympathetic). The glosso-pharyngeal nerve also sends efferent secretory fibres to the parotid gland.

[1] *Archives of Otology*, vol. xxvi., 1897, p. 185.

Paralysis of the nerve causes anæsthesia of the back of the tongue and pharynx, difficulty in swallowing and deficient taste in the posterior third of the tongue. In man, unilateral paralysis of the superior constrictor is visible as a "curtain movement" of the pharyngeal wall towards the non-paralysed side, at the commencement of the act of deglutition. There is also difficulty of swallowing solid foods, owing to inability to grasp the bolus properly by means of the pharyngeal constrictors. In animals when this nerve has been divided experimentally, the pharynx and œsophagus remain tonically contracted, owing to paralysis of the "autonomic" inhibitory fibres contained in the glosso-pharyngeal.

The **Tenth Nerve, Vagus,** or **Pneumogastric Nerve,** according to modern nomenclature, is held to include, not only the vagus itself as

FIG. 78.—Paralysis of the right side of the palate. The patient is saying "Ah," and the palate is pulled up towards the left side. The arrow points to the centre of the uvula.

formerly recognised, but also those roots which used to be called the "bulbar part of the spinal accessory." Nowadays the term "spinal accessory" is limited to the spinal part of the accessorius which arises from an entirely separate nucleus, whereas the old "bulbar part" is derived from, and belongs to, a continuation of the vagus nucleus (nucleus ambiguus) in the medulla.

The vagus has a most extensive distribution. It contains both cerebro-spinal and autonomic fibres and supplies the pharynx, larynx, œsophagus, heart, lungs, stomach, and partly even the intestines and spleen. By its auricular branch it also supplies part of the skin of the outer ear. Of its pulmonary autonomic fibres some are motor for the bronchial muscles; others are sensory for the respiratory passages. The vagus is both motor and sensory for the œsophagus and larynx, sensory for the stomach, and partly motor for the stomach and intestines.

Its lowest roots of origin are those which are of the greatest diagnostic importance, for they contain motor fibres for the levator palati and the larynx, together with autonomic efferent inhibitory fibres for the heart. With the exception of the crico-thyroid muscle, which is innervated by the superior laryngeal branch, all the laryngeal muscles are supplied through the inferior or recurrent laryngeal nerve.

The symptoms of vagus paralysis vary according to the site of the lesion. Intra-cranial lesions may affect all its roots of origin, or may attack the upper or the lower roots alone. In the latter case there is often a concomitant affection of the adjacent hypoglossal nerve.

If the whole of one vagus trunk be affected, there is unilateral paralysis of the palate and larynx (*Avellis's syndrome*), together with anæsthesia of the larynx on the affected side. The only way to recognise a unilateral paralysis of the palate is to watch the movement of its

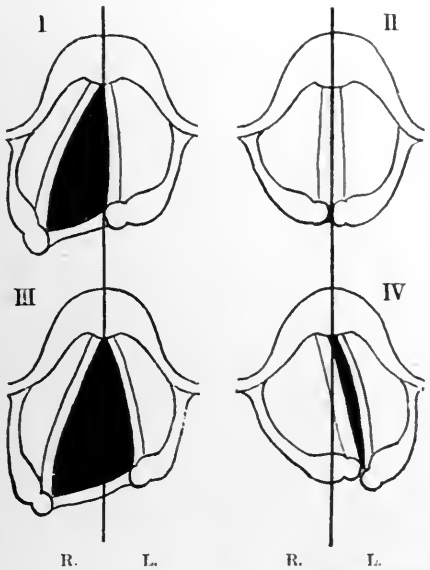

Fig. 79.—Organic laryngeal paralyses (Barwell).

I. Left abductor paralysis, during inspiration.
II. Left abductor paralysis, during phonation.
III. Left recurrent laryngeal paralysis, during inspiration.
IV. Left recurrent laryngeal paralysis, during phonation.

median raphé when the patient utters a long "Ah." Normally the raphé rises straight up. But if one side of the palate be paralysed the healthy side alone pulls upwards and the raphé deviates to the sound side, forming a characteristic dimple (Fig. 78).

If both vagi be paralysed, there is tachycardia and irregularity of the heart, from paralysis of the cardio-inhibitory fibres. There are also slowness and irregularity of respiration. These do not occur in unilateral vagus palsy. Gastric symptoms have also been observed even in unilateral cases, such as gastric dilatation, vomiting, gastric pain, and loss of the sensations of hunger and thirst.

Of all these symptoms, the most constant and easiest to recognise are the affection of the soft palate and the laryngeal palsy.

Paralysis of the **recurrent laryngeal nerve** may occur alone. The commonest cause is aortic aneurism, which frequently compresses the nerve on the left side. Mediastinal growths may also compress it. Or its paralysis may even be the result of mitral stenosis, when the left auricle becomes dilated and thus compresses the nerve directly against the pulmonary artery, or the auricle may force the left bronchus upwards and compress the nerve against the aortic arch.[1]

In *recurrent laryngeal paralysis* the vocal cord on the affected side is immobile, fixed in the cadaveric position, *i.e.* midway between

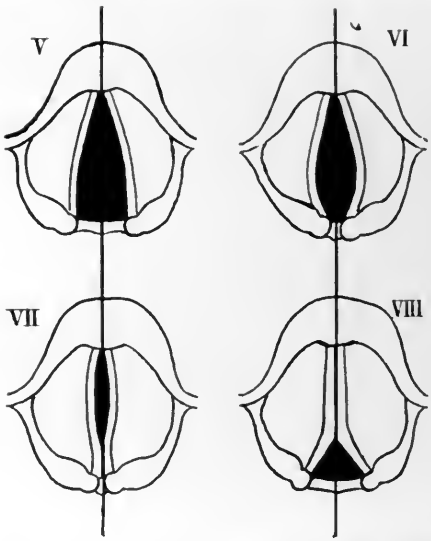

FIG. 80.—Functional laryngeal paralyses (Barwell).

V. Adductor paresis—all the adductors affected—phonation.
VI. Adductor paresis—arytenoideus unaffected—phonation.
VII. Paralysis of the thyro-arytenoidei—phonation.
VIII. Paralysis of the arytenoideus—phonation.

abduction and adduction, and the voice is generally hoarse though not absent, since during phonation the healthy cord can cross the middle line to meet the paralysed one. If *both recurrent laryngeals* be paralysed, both vocal cords are motionless and in the cadaveric position, and phonation is impossible, since the cords cannot be brought together. There is no stridor except on deep inspiration.

It is here convenient to recall some of the chief diagnostic features of **laryngeal palsies** (Figs. 79 and 80). Abductor palsy, unilateral or bilateral, is always organic, and is often the earliest sign of a commencing recurrent laryngeal nerve affection. In *unilateral abductor palsy* the voice is unaffected, but on laryngoscopic examination the paralysed cord is seen to be immobile during inspiration, not moving

[1] Frischauer, *Wiener Klin. Wochenschrift*, Dec. 28, 1905.

outwards like its healthy fellow. On phonation the cords meet normally. In *bilateral abductor palsy* the voice is also unaffected, since both cords come together on phonation. And since they no longer move outwards during inspiration, but on the contrary are sucked together, inspiration is laboured and stridulous, and the patient is in danger, since the slightest swelling of the cords may completely block the glottis. *Paralysis of the internal thyro-arytenoid muscle*, which occurs in some cases of early bulbar paralysis, is characterised by an oval instead of a linear appearance of the glottis on attempted

FIG. 81. FIG. 81A.

Paralysis of right spinal accessory nerve.

Fig. 81 shows the downward and outward displacement of the right scapula. Observe alteration in the lateral outlines of the neck. On the paralysed side the outline is formed by the levator anguli scapulæ; on the normal side by the trapezius.
Fig. 81A shows the patient attempting to depress the head against resistance. Observe the absence of the right sterno-mastoid, the right omo-hyoid being now subcutaneous.

phonation, owing to loss of the support of these muscles. The voice is therefore hoarse, but abduction and adduction are otherwise unaffected. *Adductor paralysis* is always bilateral and generally hysterical. It is common in hysterical aphonia. The patient loses his voice, often suddenly, and talks in a whisper. There is no stridor, and on inspiration the cords move normally outwards. But on attempted phonation they do not reach the middle line. The condition often disappears suddenly under treatment by suggestion, combined with laryngoscopy, or with the application of strong faradic shocks to the larynx.

The **Eleventh or Spinal Accessory Nerve** is distributed to the sterno-mastoid and to part of the trapezius. It is exclusively a motor nerve.

When it is paralysed, we have paralysis and atrophy of the sterno-mastoid, which no longer stands out on rotation of the head to the opposite shoulder, nor on depressing the head against resistance (Figs. 81 and 81A). The sterno-mastoid receives a small part of its innervation from the second cervical nerve, and sometimes a number of its muscle-fibres survive even after the spinal accessory is divided. The paralysis of the trapezius varies in degree according to the extent to which the muscle is supplied by the spinal accessory and by the cervical plexus respectively. Ordinarily the uppermost fibres of the trapezius are innervated by the spinal accessory, whilst the middle

FIG. 82.—Paralysis of right spinal accessory nerve, showing downward and outward displacement of scapula. Owing to absence of the trapezius, the rhomboid muscles on the right side have become subcutaneous.

fibres of the muscle are supplied by the third and fourth cervical nerve and the lowest fibres of all by the spinal accessory. When the trapezius is paralysed, the outline of the neck is altered, owing to the levator anguli scapulæ having become subcutaneous, and there is a characteristic deformity of the angle of the shoulder resulting from the displacement of the scapula (Fig. 82). The scapula on the paralysed side is displaced downwards and outwards, and rotated outwards, so that its inner border, instead of being parallel with the spine, is inclined from below upwards and outwards. When the patient braces his shoulders back, the scapula is imperfectly approximated to the middle line, and the rhomboids on the paralysed side become visible subcutaneously (Figs. 83 and 83A).

The *supra-trapezial plexus* (from the third and fourth cervical nerves) is sometimes affected alone, independently of any lesion of the spinal

accessory. The symptoms, as regards deformity (see Fig. 281, p. 518), are similar to those of trapezius palsy from a spinal accessory lesion as above described, with this difference, that the uppermost fibres of the muscle survive, and that there is often a patch of cutaneous anæsthesia in the outer scapular region.

The Twelfth or **Hypoglossal Nerve** is also entirely motor in function.

Immediately after its exit from the skull it receives amongst other connections a small communicating branch from the cervical sympathetic. The hypoglossal supplies all the intrinsic muscles of the corresponding half

FIG. 83. FIG. 83A.

Paralysis of right spinal accessory nerve.

Fig. 83.—Showing position at rest.
Fig. 83A.—Showing position on adduction of scapulæ.

of the tongue. Outside the skull it is joined by branches from the first and second cervical nerves, and from these two latter nerves the depressors of the hyoid bone are supplied, through the *descendens hypoglossi*.

The symptoms of hypoglossal paralysis are very characteristic (Figs. 84, 85, and 285). The corresponding half of the tongue becomes atrophied and wrinkled. When the tongue is protruded the healthy side causes the tip to be pushed round to the paralysed side in a sickle-shaped curve. If the nerve is divided suddenly, by accident or operation, the patient feels for a few days as if the paralysed half of the tongue were a foreign body, interfering with articulation and mastication. But this sensation soon passes off as the patient becomes accustomed to his hypoglossal palsy.

If the lesion of the hypoglossal be extra-cranial, after it has received the small communicating branch from the cervical sympathetic, we may sometimes observe vaso-motor changes in the atrophied side of the tongue. In two of my cases in which the twelfth was divided intentionally for the treatment of facial palsy by means of facio-hypoglossal anastomosis, the tongue became pale on the paralysed side. From unilateral paralysis of the hyoid depressors, the larynx may be pulled over towards the sound side during swallowing.

FIG. 84.—Paralysis of right hypoglossal nerve from a stab-wound below the jaw, showing atrophy of corresponding half of tongue and marked deviation to the right when protruded.

The **hypoglossal nucleus** within the medulla, as we have already mentioned, is closely connected with the lowest cells of the facial nucleus, viz. those which supply the orbicularis oris. Hence in lesions in the neighbourhood of the hypoglossal nucleus, the muscles of the lips are paralysed together with those of the tongue. This weakness of lips and tongue in nuclear lesions is generally bilateral, owing to the close proximity of the hypoglossal nuclei to the middle line.

Intra-cranial lesions of the hypoglossal nerve, *e.g.* from a patch of syphilitic meningitis, very frequently involve other cranial nerves in the neighbourhood.

One of the commonest **multiple palsies** is that which produces *Hughlings-Jackson's syndrome*, viz. hemiatrophy of the tongue, paralysis of the trapezius and sterno-mastoid, and paralysis of the vocal cord and soft palate, all on the same side (Fig. 85). This is the result of a lesion implicating the hypoglossal, the accessorius, and the lowest roots of the vagus.

Another variety of multiple palsies in this region is produced by a *lesion* (*e.g.* from a bullet or shell wound) *of the foramen lacerum posticum*, causing combined paralysis of the vagus, accessorius, and

FIG. 85.—Paralysis of spinal accessory and hypoglossal on right side. (Hughlings-Jackson's syndrome). Showing downward and outward displacement of right shoulder, also atrophy of right half of tongue with deviation to the right on protrusion.

glosso-pharyngeal, all of which traverse this foramen. Such a patient will show unilateral paralysis of the palate and larynx (vagus), paralysis of the sternomastoid and trapezius (accessorius) and deficient sensation of the pharynx and back of the tongue with difficulty of swallowing (glosso-pharyngeal), all on the same side.

If the lesion extends from the foramen lacerum backwards into the anterior condyloid foramen, hypoglossal paralysis is superadded, with resulting hemi-atrophy of the tongue.

A still more extensive unilateral extra-cranial lesion, deep in this same region, may implicate not only the four lowest cranial nerves, but also the cervical sympathetic trunk, producing pupillary and other changes (see p. 340).

CHAPTER XI

PAIN AND OTHER ABNORMAL SUBJECTIVE SENSATIONS

WHAT we call **pain** comprises two entirely different affairs.

Firstly, pain is sometimes a specific sensation, conducted from definite end-organs along special paths, in the peripheral nerves, posterior-roots, and brain-stem, to the thalamus and thence to the cerebral cortex. Here it is critically discriminated, and the painful spot is duly identified and localised.

Secondly, pain may be a feeling of intense unpleasantness, or disagreeableness, associated with affective and emotional reactions. This is not a true localisable sensation, but a diffuse, unlocalised experience. This second type can be induced not only by stimulation of special pain-nerves, but also by stimulation of other nerves, whether of special sensibility (*e.g.* an intense light or a piercing sound) or of nerves which normally give rise to no conscious sensation whatever (*e.g.* in visceral disorders). These unlocalised feelings are located, not in the cerebral cortex, but in the thalamus.

Mental distress, a purely cortical function, may secondarily influence the lower, thalamic, centres for pain and for emotional reflexes, thereby producing motor and secretory reactions (crying, sobbing, lacrymation, etc.), and sometimes also influences the activity of many of the vegetative functions.

Pleasure, on the other hand, is not a specific sensation, but a general unlocalised feeling-tone. It is usually associated with the performance, within physiological limits, of the normal activities of the body. Sometimes, however, pleasure seems to be a temporary "swing of the pendulum" after the relief of a pre-existing pain or discomfort. Thus, for example, the pleasurable sensation which follows the emptying of a full bladder is probably due to the relief of previous discomfort owing to tension of the bladder-wall; when this tension is relaxed and free discharge occurs, the feeling-tone changes to one of distinct pleasure. A pessimistic German philosopher, Schopenhauer, held that no such thing exists as pleasure, but only a temporary relief from pain. This, however, is untrue, for there are numerous varieties of pleasure which are unassociated with any antecedent disagreeable sensation. The normal activities of the body are not performed haphazard, but are directed towards the

accomplishment of definite ends. When these ends are attained, we experience a feeling-tone of pleasure (*joie de vivre*). And it is not only the mere activity that is pleasurable, but still more the feeling of accomplishment, or, in the case of delayed reactions, the hope of accomplishment—the pleasurable anticipation.

Stimulation of the surface of the brain gives rise to no pain, but the meninges are exquisitely sensitive, the cerebral membranes being innervated by the trigeminal nerve. Intra-cranial diseases, therefore, probably cause pain chiefly through the intermediation of the sensitive meninges. It is possible, however, that the pain in some cases of syringomyelia may not be of meningeal origin, but due to actual distension of the syringomyelic cavity by the fluid within, though against this view is the fact that pain is a late phenomenon in this disease.

Spontaneous sensations of discomfort vary in degree and in kind. Milder varieties, not amounting to actual pain, are classed as **dysæsthesiæ.** They include such symptoms as spontaneous tingling, "pins and needles," dulness, itching, flushing, etc., whilst among the more severe varieties of actual pain are the intense and agonising pains of tic douloureux, angina pectoris, renal or biliary colic, or the lightning-pains of tabes.

In the diagnosis of the cause of any particular dysæsthesia or pain, there is one invariable rule which we should always follow, namely to make a careful local examination of that part of the body to which the abnormal sensation is referred. Only in this way can we escape gross errors, such for example as that of mistaking the pain of herpes zoster for that of pleurisy. In every local pain we should first search for a local cause, whether in the skin, muscles, bones, joints, glands, or other subjacent structures. Pain due to local disease is usually more or less continuous and accompanied by objective phenomena such as redness of the skin, swelling or tenderness of the diseased tissues, rigidity of joints, and so on. The painful cramps of tetanus, rabies, and strychnia poisoning are easily recognised and need not be further described.

Some pains are generalised all over the body, for example, the pains of acute illness such as influenza, smallpox, and other fevers of rapid onset. In such cases the elevation of temperature, the presence, perhaps, of a rash, and usually the occurrence of other similar cases in epidemic form, all help us in the diagnosis.

Intractable paroxysmal pains of hemiplegic distribution, in the face, trunk and limbs, so-called *hemiplegia dolorosa*, are highly suggestive of a lesion localised in the **optic thalamus.**[1] In such thalamic

[1] Dejerine and Roussy, *Revue neurologique*, 1906, No. 12.

lesions there is also hemi-anæsthesia of the affected limbs and face, hemi-hyperæsthesia to temperature and pin-pricks, together with spontaneous choreiform or athetoid movements, probably from affection of the thalamo-striate fibres which connect the thalamus with the neo-striate system. There is also hemiataxy on voluntary movement. These cases of hemiplegia dolorosa must be carefully distinguished from the joint-pains which are not uncommon in ordinary chronic hemiplegia, which are due to secondary arthritic changes and are usually alleviated by massage, hydrotherapeutics and anti-rheumatic remedies.

Most cases of pain or discomfort, however, are localised to some more definite area, and therefore for diagnostic purposes the most convenient plan of studying pains and other subjective sensations is by considering the different parts of the body in turn.

Headache.—Cephalalgia.—A diagnosis of "headache" alone is never sufficient. Headache is not a disease, but merely a symptom.

When a patient complains of headache, local causes should first of all be excluded. Amongst the commonest *local extra-cranial* causes we should bear in mind rheumatic myositis of the occipito-frontalis muscle, with its characteristic tenderness on brushing the hair, with aggravation of pain on movement of the scalp and with scattered areas of nodular induration in the muscle-fibres recognisable on careful palpation and exquisitely tender on light pressure. Deep pressure, on the other hand, often relieves the pain. Meanwhile we usually find a considerable degree of rigidity in the muscles of the neck. This headache is often relieved promptly by hot applications and by massage. Erysipelas is accompanied by local redness, heat and œdema, and by fever. Periostitis of the pericranium causes tenderness on pressure and is often syphilitic in origin, in which case the pain is commonly worse at nights.

Headaches from local causes in the *cranial bones* are most commonly due to inflammation of the mucous membrane lining the various air-cells, *e.g.* the mastoid, frontal, or ethmoidal cells, or even to an ordinary coryza. Here the previous history of the case, together with the local examination, will serve to indicate the cause. Less frequently caries of the bones or local exostoses may be present. Carious teeth often cause headache, referred especially to the temporal region.

Acute pain in the forehead and eyeball occurs during an attack of *congestive glaucoma*. There is usually an early stage of the disease, during which the patient complains of transient attacks of mistiness of vision, lasting a few hours at a time (due to stretching and œdema of the cornea). During these attacks the pupil of the affected eye is

dilated, and the whole eye is congested. Later, the pain becomes more intense, visual acuity rapidly diminishes, and the visual field becomes contracted; whilst the pupil is dilated, often oval (with its long axis vertical), and the cornea becomes steamy and insensitive. The anterior chamber becomes shallow, with a discoloured iris and a peculiar greenish tinge of the lens (*γλαυκός* = sea-green). Meanwhile, the eyeball is very tender, and feels intensely hard on palpation.

Gross intra-cranial disease may produce intense headache, either from local affection of the meninges as in the various forms of meningitis (syphilitic, tuberculous, or pyogenic), or from general increase of intra-cranial pressure, as in diffuse meningitis, intra-cranial abscess, gumma, or tumours. Headaches of intra-cranial origin are nearly always paroxysmal, or if there be a continuous pain, it has paroxysmal exacerbations. These headaches are often associated with the other classic signs of increased intra-cranial pressure, especially with nausea, vomiting, and optic neuritis. In every case of obscure headache we should make a careful ophthalmoscopic examination. The position of the headache does not necessarily correspond with that of the tumour. Tumours of the posterior fossa produce the most severe headache.

Then there are the headaches which result from abnormalities of the intra-cranial circulation, especially from arterial hyperæmia, as in renal disease or in suppressed menstruation or temporarily from drugs such as nitrite of amyl, erythrol tetranitrate, or alcohol. Hyperæmia produces a throbbing pain, sometimes associated with giddiness, tinnitus, affection of vision, and a tendency to attacks of epistaxis. The venous hyperæmia of severe cardiac disease or of emphysema may also produce headache, which is aggravated by coughing. The headache of anæmia is probably mainly toxic in origin, rather than due to actual deficiency in the supply of blood to the head.

Certain cases of hemiplegia are preceded, for days or even weeks, by headache. This is sometimes present in *cerebral thrombosis* (*encephalomalacia*), where a premonitory headache is of considerable diagnostic value. Still more frequently the onset of a *cerebral hæmorrhage* is accompanied by headache. Therefore if an elderly man complains of headaches and bleeding from the nose, we should be cautious in checking epistaxis which may act as a safety-valve, and may save him from an attack of cerebral hæmorrhage. Cerebral embolism is not usually associated with headache.

There is another group of headaches which are produced by peripheral irritation in various parts of the body. Thus, for example, visceral irritation may cause headache, often accompanied by areas of superficial tenderness, as in ovarian or uterine diseases, or in the

headaches from which so many women suffer at the menstrual periods, and frequently also throughout the menopause. Head has pointed out that the different viscera have special areas of superficial tenderness, temporal, vertical, or occipital. In some people the swallowing of an ice causes sudden frontal headache, when the ice reaches the œsophagus or stomach. This is a typical "reflex" gastric headache. Every autumn we come across cases of "gun headache" amongst sportsmen, not simply the result of the auditory stimulus of the noise of the gun, but due partly to the shock of repeated recoils of the weapon, and partly to the toxic fumes of cartridges containing nitroglycerine. Orbital headaches are fairly frequent, sometimes the result of disease such as glaucoma or iritis, but much more commonly arising from errors of refraction, especially hypermetropia and astigmatism. Even apart from this, headache may result from prolonged eye-strain, *e.g.* after sight-seeing in picture-galleries, being commoner in people who have some error of refraction.

A large group of headaches are *toxic* in origin, the toxins altering the intra-cranial circulation, usually in the direction of raising the blood-pressure. The onset of certain infective fevers is associated with headache, for example in smallpox and influenza (commonly associated with pain in the back), in enteric fever (associated with dyspeptic symptoms), in scarlatina, pneumonia, etc. In such cases the temperature, the characteristic rash, and the other signs and symptoms will guide us. Poisoning by toxic substances is also the main cause of the headache of dyspepsia, whether it be the well-known "*Katzenjammer*"—the bursting morning-headache and nausea following a joyous alcoholic evening (this headache, by the way, can often be relieved by a 20-grain dose of calcium lactate), or the headache of chronic dyspepsia especially when associated with a constipated intestine. Headache also results from poisoning with carbonic oxide, carbonic acid and other atmospheric sewage in ill-ventilated rooms or at crowded meetings. Other poisons, again, are autogenetic in origin, as are the headaches of gout, uræmia, and diabetes. The typical renal headache is occipital in situation, although it may also occur in the frontal or temporal regions.

Sunstroke causes acute diffuse headache. Severe cases are often accompanied by other symptoms such as delirium, hyperpyrexia and coma, together with pleocytosis of the cerebro-spinal fluid. Neurasthenia and exhaustion, whether from overwork, from excessive study or from other excesses, are often associated with headache, frontal, occipital, or circular, feeling like a tight elastic band (*douleur en casque*). The post-epileptic headache following a fit is sometimes severe and may be associated with vomiting.

Bilateral headaches are most commonly toxic. The headache of dyspepsia is usually referred to the frontal region, that of constipation to the occiput, whilst vertical headaches are most commonly due to anæmia or to debility.

Some cases of concussion of the brain are followed by obstinate headaches, recurring for many months, *e.g.* in soldiers who have been blown up by shell-fire. Some of these cases are associated with œdema of the cerebral meninges, demonstrable afterwards by a decompressive operation; such cases are often relieved by simple lumbar puncture. Others again are toxic in origin, a smaller amount of toxin being efficient in producing headache after concussion than in the case of a healthy individual, whilst in other instances the headaches occur on slight mental exertion, especially where the patient has been allowed to return to work prematurely. Hence the importance of complete physical and mental rest after a severe head injury, even in the absence of signs of an organic lesion. Other cases of persistent headaches following head injury are hysterical in nature, due to the perpetuation of a transient pain by the patient's auto-suggestion.

Most of the headaches to which we have referred are bilateral or mesial in situation. Let us now consider a different group—the unilateral or circumscribed pains.

Sometimes these are due to local disease of the scalp, pericranium or skull, in which case local examination will generally reveal the cause. Or they may result from intra-cranial disease, for example, meningitis, abscess, gumma or tumour. If the underlying disease be near the surface of the skull, the site of the pain sometimes corresponds with that of the disease. But this is by no means always the case. I remember a striking case of right-sided cerebellar tumour in which the pain was confined to the left supraorbital region. The growth was diagnosed and successfully removed.

Some headaches are associated with great pallor of the face—apparently due to vasomotor spasm of the cerebral vessels, often relieved by inhalation of amyl nitrite. Others are associated with arterial hyperæmia, throbbing arteries, and a flushed face. These are sometimes promptly relieved by compression of the carotid artery on the corresponding side. Such angio-neurotic headaches are rarely bilateral.

A very acute circumscribed variety of headache is known as the *clavus hystericus*, an agonising pain usually referred to the vertex, as if a nail were pressing into the brain. It occurs in certain cases of hystero-neurasthenia. It is unassociated with any other evidences of intra-cranial disease, and its very intensity leads us to a suspicion of its true nature.

The pain of sick-headache, or **migraine** (hemicrania), with its paroxysmal attacks recurring at intervals of days or weeks, the patient during the intervals being free from headache, is usually easy of recognition. The duration of each paroxysm varies from a few hours to one or two days. Most cases begin in the morning and last till the same evening. Migraine is a family disease. It generally appears in childhood and recurs throughout the strenuous period of life, tending to disappear in old age. The pain of migraine is often alleviated by pressure on the common carotid artery of the corresponding side, but reappears when the pressure is removed. It is not uncommon to have unilateral vasomotor changes during the attack. Thus the face and ear may be flushed on the affected side. The pupils may also become temporarily unequal, although this is by no means constant. Migrainous headache generally culminates in vomiting, and is sometimes preceded by a visual aura, lasting twenty or thirty minutes, consisting of a scintillating scotoma in which there is a blind area in one half of the visual field (usually, but not always, on the side opposite to that of the unilateral headache). The blind area is bounded at its periphery by a luminous zigzag coloured spectrum. This scotoma not infrequently develops into a temporary total hemianopia. The headache of migraine is generally unilateral, and is referred to the front part of the head on the side contra-lateral to that of the visual phenomena. Thus if the visual sensations are in the left side of the visual fields, the headache is generally right-sided, and *vice versâ*.

Less commonly a migrainous attack may be preceded by a non-visual aura of some sort, *e.g.* by a subjective sensation of tingling in one hand spreading slowly up the arm to the face and tongue, and followed by headache on the opposite side of the head. If the tingling be right-sided there may be slight transitory aphasia. This variety of migraine is distinguished from a minor epileptiform attack by the greater intensity and unilateral limitation of the migrainous headache, by the slow, deliberate march of the migrainous aura, lasting perhaps for many minutes, by the absence of unconsciousness, by the absence of clonic movements, and by the fact that the premonitory tingling of migraine may spread bilaterally to the tongue and lips, whereas in an epileptiform attack, if the aura spreads to the tongue or face, it remains unilateral.[1] Migraine and epilepsy may alternate in the same patient.

Migraine ophthalmoplégique is an entirely different affair, in which, in addition to hemicranial pain, there is transient paralysis of the third nerve on the same side as the headache, with ptosis, external strabismus, mydriasis, etc. (see p. 132).

[1] Gowers, *British Medical Journal*, Dec. 3, 1906.

We now pass to pains in the region of the trigeminal nerve. Of these, **tic douloureux** is the most agonising pain from which a patient can suffer. The pain is not continuous, but paroxysmal. It rarely attacks all three divisions of the nerve, but is usually confined to one division (especially the supraorbital), or it may attack two adjacent divisions. The disease is hardly ever bilateral except in cases of diabetes. The patient has paroxysms of intolerable agonising pain in the area of the affected division, lasting usually only a few seconds. During the attack the face is often thrown into strong involuntary tonic spasm on the affected side, there is excessive lacrymation, and sometimes secretion of nasal mucus and saliva, all on the affected side. If the attack lasts for half a minute or longer, it will be found that it is not really a continuous pain, but a series of short sharp stabs of pain, interrupted by brief intervals. Not only do paroxysms occur spontaneously, but the slightest stimuli often suffice to induce an attack, and therefore the patient avoids chewing food on the affected side. I have known cases in which it was impossible for the patient to wash his face for weeks at a time lest an attack should be thereby precipitated. Stimulation of certain localised spots on the face or tongue—so-called "trigger-areas," no matter how slightly, causes an immediate explosion of pain in the affected division of the nerve. Such trigger-areas are most commonly found on the upper lip, at its junction with the ala nasi, or on the lower lip, near its vermilion border at the outer angle of the mouth or elsewhere. Inveterate trigeminal neuralgia sometimes drives the patient to suicide.

Apart from these, there are numerous varieties of more localised paroxysmal neuralgic pains referred to individual branches of the trigeminal nerve, and associated with "tender points of Valleix" over their foramina of exit. In such local neuralgias, and in tic douloureux itself, we should always search carefully for some local exciting cause in the mouth, nose, ear, or eye. A carious or inflamed tooth may cause neuralgia in the whole of the corresponding division of the fifth nerve, and the dental surgeon by extracting it will relieve the condition. But we must beware of extracting sound teeth simply because the patient refers neuralgic pain to them. Sometimes an abnormally-placed tooth, though healthy in itself, may cause neuralgia. Thus a lady of fifty-eight had had a constant burning-pain along the right side of her tongue for eight years, together with a feeling of numbness in the area of the second division of the fifth nerve. This had been vainly treated by numerous drugs, whilst all the time the real exciting cause lay in an imperfectly-erupted lower wisdom-tooth on the corresponding side, the date of the pain coinciding with the first appearance of the tooth. Disease of the antrum or other accessory

air-sinus, nasal polypi, and other local lesions may all cause localised neuralgias. If, in addition, the patient be anæmic or gouty, the tendency to neuralgia is increased. But anæmia or gout alone will not cause a local neuralgia. Some local determining cause must also be present, though it is sometimes difficult to discover. The combination of unilateral pain in the region of the third division of the trigeminal with obstructive deafness of the Eustachian tube type, and impaired movement of the soft palate on the same side, is generally due to a new growth in the lateral wall of the naso-pharynx.[1] Syphilitic basal meningitis or gumma, implicating the fifth nerve in the floor of the skull, may cause trigeminal neuralgia. The patients usually show other evidences of intra-cranial disease, and we should look for signs of involvement of the sensory or motor root (see p. 141). If such lesions last any considerable time, they tend to produce some anæsthesia of the affected nerve-area. Localised anæsthesia suggests an organic neuritis rather than a mere neuralgia.

Let us now consider the various pains which may be met with in the **trunk.** Firstly, there are the various root-pains, due to irritation of the corresponding posterior root or roots in the affected area. Sometimes such *radiculitis* is due to disease of the spinal meninges (syphilis, tubercle, or tumour), to osteo-arthritis, caries or tumours of the spinal column, or to intra-thoracic aneurisms and new growths. A characteristic feature about radicular pains is that they are aggravated by coughing or sneezing. Sometimes, even in normal individuals, tingling root-pains may occur on severe coughing, radiating along the lower roots of the brachial plexus. In addition, in radiculitis we often have sensations of tingling, congestion, coldness or heat, accurately localised to root-areas. Acro-paræsthesiæ of this sort are always suggestive. Bone pains in the spine are associated with local tenderness and rigidity. If we see a patient supporting his head with both hands owing to pain in the neck, this is almost pathognomonic of disease of the cervical vertebræ. Root-pain commencing unilaterally and later becoming bilateral is practically pathognomonic of a tumour of the spinal meninges. These pains, when due to organic lesions of the roots, are not infrequently associated with a degree of hyperæsthesia or anæsthesia of the painful area—*anæsthesia dolorosa.* If the spinal cord be compressed or infiltrated by the same lesion as that which implicates the posterior roots, we have signs of sensory or motor paralysis of the parts below the lesion, with the usual changes in the reflexes, etc. The *girdle-pains of tabes* are due to affection of the corresponding posterior roots. Tabetic girdle-pains vary in degree from the sensation of a narrow constricting cord to one of a broad

[1] Trotter, *Brit. Med. Journal,* Oct. 28, 1911.

cuirass enveloping a large part of the trunk. Such a cuirass often feels incomplete either in front or behind (Fig. 90, p. 199). Root-pains may also occur in some cases of disseminated sclerosis (*sclerosis multiplex dolorosa*), and unless this fact be borne in mind a false diagnosis of spinal tumour may be made.[1] Another root-pain is that associated with herpes zoster, which is a disease of the posterior root-ganglion. *Herpetic pain* is practically always unilateral, and may either precede or succeed the eruption of the herpetic vesicles. It may last for months after the vesicles have disappeared. The pain of herpes is often so sharp that it may be mistaken for that of pleurisy, from which it may be distinguished by auscultation. Herpes zoster is often accompanied by a lymphocytosis of the cerebro-spinal fluid. The infective organism which produces herpes is apparently identical, in many cases, with that of varicella,[2] for a chicken-pox epidemic may take its starting-point from a case of herpes zoster.

Pleurodynia is a pain in one or more intercostal spaces, due to a "rheumatic" myalgia of some of the intercostal muscles. It somewhat resembles the pain of pleurisy, but is easily distinguished by the normal temperature and by the absence of friction-sounds on auscultation. There is also a very common trunk-pain which we meet with in people who are neurasthenic or debilitated. It is a deep boring pain, usually below the inferior angle of one or other scapula. It is more diffuse and less superficial than the pain of herpes, and it has none of the physical signs of pleurisy or pleurodynia. The pain of traumatic neurasthenia, especially after a railway or other accident ("railway spine"), may simulate that of organic spinal lesions, especially when a hysterical paraplegia coexists. But the diagnosis can usually be made by noting the excessive hyperæsthesia of the spine, the absence of signs of organic disease, and the presence of various hysterical phenomena (see later, p. 373). Mammary neuralgia or mastodynia also occurs in hystero-neurasthenic patients, and must be distinguished from disease of the gland by means of physical examination.

We have also to bear in mind the various *reflected pains* which may occur in visceral diseases in which the pain is referred, not to the diseased organ itself, but to a cutaneous area innervated by the posterior root through which the afferent visceral nerves reach the brain-stem (see Fig. 191, p. 335.) Thus, for example, in pericarditis there may be precordial or epigastric pain. Physical examination will clear up the diagnosis in cases of aneurism and of mediastinal growths.

[1] Frankl-Hochwart, *Neurologisches Centralblatt*, 1906, s. 973.
[2] Bokay, *Wiener klin. Wochensch.*, Sept. 30, 1909. R. C. Low, *Brit. Med. Journal*, Jan. 25, 1919.

Phrenic neuralgia is of considerable clinical interest. It should be borne in mind that the phrenic is a mixed nerve, supplying not only diaphragmatic motor fibres, but also sensory fibres to the diaphragm, to the extra-pleural and extra-peritoneal connective tissues, and to the supra-renal body of the corresponding side. In addition, the right phrenic supplies the liver and its sub-peritoneal covering, also the inferior vena cava and the right auricle. The phrenic nerve has various connections with spinal and splanchnic nerves, notably with the inter-vertebral ganglia of the lower cervical posterior roots[1] (from the third to the sixth cervical). Thus in certain diseases such as diaphragmatic pleurisy, gall-stones,[2] hepatic abscess, supra-renal tumours,[3] etc., we may have reflected pain in the region of the corresponding shoulder, often accompanied by cutaneous hyperæsthesia.

One of the most severe of all trunk pains is the well-known *angina pectoris*. This is a paroxysmal suffocative pain, or feeling of intolerable oppression in the region of the heart, often radiating down one or both arms, but especially down the left arm. Together with this, there is a sensation of impending death. It is commonest in male patients at or after middle life, and is usually, though not invariably, associated with evidence of vascular degeneration. It has to be distinguished from toxic or neuralgic angina, so-called "pseudo-angina," a similar but much less serious affection, met with most commonly in young girls, in women who have been lactating too long, or in patients before middle life who smoke tobacco or drink tea to excess.

Irritation of the sensory nerves at the gastric end of the œsophagus, by abnormal acids or other irritants in the stomach, producing spasm of its muscular wall, may cause burning pain, usually referred to the seventh left chondro-sternal junction, and sometimes also to the left interscapular region. Such pains are associated with other dyspeptic symptoms to which we need not here refer further. As regards the situation of reflected pains in diseases of various parts of the gastro-intestinal tract, it is useful to bear in mind Mackenzie's rule,[4] that pain due to affections of the digestive tract is referred across the middle line of the abdomen, in regularly descending areas as we pass from the stomach towards the large intestine. Thus the epigastrium is the region for gastric pains (disease at the cardiac end causing pain higher up than pyloric affections), the umbilical area is the region for pains of the small intestine, the hypogastric area the site of pains due to the large intestine. A striking experimental corroboration of this can be obtained at any time by taking a sharp

[1] Kidd, *Rev. of Neurol. and Psych.*, 1911, p. 587.
[2] Mackenzie, *Brain*, 1893, p. 339; also *Symptoms and their Interpretation*, 1909, p. 45.
[3] Mayo Robson, *Brit. Med. Journal*, 1899, vol. ii., p. 1180.
[4] *Brain*, 1901, vol. xxv., p. 373.

purgative drug. When the familiar colicky pains appear, they are felt first in the region of the umbilicus, but soon they descend lower and lower, and when they arrive close above the pubes, the call for evacuation of the bowel becomes "urgent and imperative."

Tactile sensibility is absent from the mucous membrane of the entire alimentary canal, from œsophagus to rectum. Sensations of fulness, arising from transient distension of different parts of the alimentary canal, are due to stretching of its muscular coat, and these are to be regarded as varieties of muscle-sense. Pain in any part of the gastro-intestinal tube is due to muscular tension or spasm. The same is true of the ureters, bladder, and uterus.

To discuss fully the various causes of acute abdominal pain would require many chapters of description. We have to bear in mind not only diseases of the gastro-intestinal tract, in the form of catarrh, ulcer, muscular spasm, etc., but also perforations of various hollow viscera, the stomach, gall-bladder, intestines (including the vermiform appendix), rupture of a pyo-salpinx or of a tubal pregnancy, biliary or renal colic, acute pancreatitis, torsion of an ovarian pedicle, etc. In every instance not only should we carefully examine the whole abdomen, but we should, if necessary, examine the pelvis, *per rectum* or *per vaginam*, and also investigate the urine and dejecta.

Apart from acute renal colic, a floating kidney is a fairly common cause of diffuse abdominal pain, especially in poorly-nourished women with lax abdominal walls. Here again local examination of the abdomen will reveal the cause.

Before leaving the subject of abdominal pains, we must not fail to recall the familiar *crises* of tabes dorsalis:—gastric crises associated with pain and vomiting, intestinal crises associated with colic and diarrhœa, diaphragmatic crises with hiccough, bladder crises, and so on. All these may closely simulate the pain of acute abdominal disease. But the history of the case, together with an investigation of the pupils, knee- and ankle-jerks, and the other phenomena of tabes, will usually save us from error.

Lumbago, or pain in the lumbar muscles, a variety of myalgia, is usually easily recognised. The pain is intensified by active muscular contraction and also by passive stretching, induced, for instance, by the stooping posture. It is also associated with tenderness on pressure. Lumbo-abdominal neuralgia, on the other hand, is a diffuse and more superficial pain, not confined to the lumbar region, but spreading forwards to the front of the abdomen, and sometimes to the groin, genitals or gluteal region. It is paroxysmal, and during the paroxysm there may be cramp-like spasms of the abdominal muscles or of the cremaster. It is associated with the "tender points"

of a true neuralgia, these being situated over the vertebral spines, the iliac crests, the linea alba, inguinal canal, scrotum or labium. Sacral pain is often due to uterine disease, as in the familiar uterine dysmenorrhœa or the well-known pains of labour.

Coccygodynia, or neuralgic pain in the region of the coccyx, is commoner in female patients than in males. The pain is rarely continuous. More usually it is induced by sitting or walking, or by the contraction of any of the muscles attached to the coccyx, *e.g.* during defæcation. It is often associated with local tenderness, especially on rectal examination. The pain is located not only in the coccyx, but also in the soft parts just distal to the tip of the bone. Its usual cause is a dislocation or fracture-dislocation of the coccyx, either from a fall or kick upon the coccyx, or as a result of an internal trauma, especially prolonged labour. It may also occur as a symptom of tabes dorsalis, and is not uncommon in hysteria, particularly in traumatic hysteria.

Pains in the Limbs.—*Brachial neuralgia*, generally a unilateral affection, is referred, as a rule, to the whole area of distribution of the plexus, namely to the lower part of the neck, the shoulder and the whole upper limb, being most intense in the proximal part of the limb. It is rare to meet with neuralgia confined to an individual nerve-area, such as that of the median or ulnar, except in cases of local injury or disease of the nerve-trunks. The pain of brachial neuralgia is aggravated by movement of the limb, which feels heavy and numb, though there is no paralysis. The "tender points" are over the nerve-trunks, such as the musculo-spiral, circumflex, median or ulnar nerves.

If anæsthesia or trophic changes be superadded, we probably have to do with structural changes in the nerve-trunk, that is, with a brachial neuritis, not a mere neuralgia. In every case of brachial neuralgia we must carefully examine the nerve-trunks in their entire course to exclude the possibility of organic lesions compressing or infiltrating the nerves. In addition to pain, brachial neuritis often produces weakness and atrophy of the corresponding muscles, and impairment or perversion of cutaneous sensation. Bikeles's sign, by passive stretching of the roots, is often positive. It is elicited by first flexing the elbow, then raising the arm upwards and backwards at the shoulder-joint to its full extent, and finally attempting to extend the elbow.

Analogous to brachial neuralgia and neuritis in the upper limb, we have in the lower limb **sciatica,** a term which includes *sciatic neuralgia*, *sciatic neuritis*, and *hysterical pseudo-sciatica*. In every case of so-called sciatica we have to decide which of these three is present.

Many cases of *sciatic neuralgia* occur independently of any affection

of the sciatic nerve, *e.g.* in vertebral disease, tuberculous or arthritic, in affections of the sacro-iliac joint or of the hip-joint, in diseases of the femur (tumours, osteomyelitis, etc.), in intermittent arterial claudication, etc. In true sciatic neuralgia there is usually a dull, aching pain, more or less constant, in the back of the thigh, with occasional paroxysms of darting or boring pain, generally from above downwards, along the course of the sciatic nerve. Any movement of the limb whereby the nerve is made tense, or any local pressure as from sitting on a hard chair, brings on a paroxysm. Therefore the patient habitually keeps the hip and knee slightly flexed on the affected side, so as to relax the nerve. This is exemplified in Neri's sign, which is elicited by making the patient stand erect with both heels on the ground, then asking him to bend the trunk forward and pick up some object at his feet. The knee on the affected side at once becomes flexed. It is not uncommon to find a slight scoliosis in the lumbar region, the concavity being towards the sound side. The gluteal fold, a deep crease in the skin and subcutaneous tissues, becomes diminished or lost on the affected side,[1] and Rose's "gluteal sign"[2] can be demonstrated by percussion of the gluteus maximus at its points of attachment to the side of the sacrum: instead of contraction of the whole muscle, we get an exaggerated fascicular contraction of its fibres, visible subcutaneously. The "tender points" are at the fifth lumbar spine (especially on lateral pressure from the affected towards the healthy side)[3], over the posterior iliac spine, the sciatic notch, the popliteal space, the peroneal nerve below the head of the fibula, and behind the malleoli. Some cases of sciatica are associated with marked tenderness on deep pressure through the abdominal wall towards the vertebral column at a level one finger's-breadth below the umbilicus and two fingers'-breadth laterally from that point, on the side of the sciatic pain; pressure on the corresponding spot on the healthy side being painless.[4] Passive stretching of the nerve-trunk increases the pain, *e.g.* by flexion of the hip with the knee extended (Lasègue's sign). Blunting of sensation in the peroneal or posterior tibial area is uncommon, and indicates a *sciatic neuritis or perineuritis*, as also do any alterations in the electrical reactions of the muscles, or any considerable degree of muscular atrophy. Muscular atrophy is to be looked for in the calf muscles and, still earlier, in the extensor brevis digitorum. Muscular hypotonia may be present even without muscular wasting. The diminution of consistency is best felt in the calf muscles. It can also be recognised by inspection if the

[1] Carlill, *Lancet*, Aug. 19, 1916.
[2] Rose, *Presse médicale*, 4 Juin, 1917.
[3] Raimist, *Neurolog. Centralbl.*, 1909, p. 1087.
[4] Gara, *Deutsche med. Wochenschrift*, 1911, No. 16.

patient be made to kneel on a chair; the foot on the sound side is slightly extended owing to the tonicity of the gastrocnemius, whereas on the affected side it falls into a position at right angles with the leg:—the T-square sign.[1]

In sciatic neuritis the temperature of the leg is generally lower than on the healthy side, especially when felt on the outer surface in its lower half. The ankle-jerks should always be tested on both sides. In sciatic neuritis the jerk may be diminished or lost, whereas in neuralgia it remains normal. In both affections we may observe exaggeration of the cremasteric reflex on the affected side.

The reflex of the tensor fasciæ femoris (p. 315), which in neuritis of the sciatic trunk is unaffected, is usually lost when the neuritis implicates the lumbo-sacral roots from which the sciatica arises.[2] Moreover, in lumbo-sacral radiculitis (*radicular sciatica*), whilst ordinary stretching of the nerve-trunk, by Lasègue's method, is painless, inward rotation of the flexed hip often causes acute pain. We also have the characteristic aggravation of radicular pain by coughing or sneezing.

Hysterical pseudo-sciatica often follows some slight trauma in the region of the lower limb. The patient complains of pain, and he limps. Pain, being a subjective phenomenon, is difficult to verify. In hysterical cases its situation may sometimes be in the region of the sciatic nerve-trunk: more often it is referred to some paradoxical region, *e.g.* the groin, the knee, or the lumbar region. Patches of cutaneous anæsthesia are commoner than in organic sciatic neuritis, and tend to have a hysterical type of distribution. The patient's limp is usually more dramatic than in organic sciatic neuritis, and the painful limb tends to be rigidly contractured. The patient resists all attempts at passive movement, not only those which tend to stretch the nerve-trunk, but also those which relax it. Moreover, passive manipulations produce psychical phenomena in the form of irregular breathing, emotional weeping, etc. In old-standing cases there may be a slight degree of muscular wasting, from disuse. The ankle-jerk, however, is unaffected.

Varicose (or *phlebogenic*) *sciatica*[3] is a variety of sciatic neuralgia in which the small veins within the sciatic trunk have become dilated and varicose. Women are more often affected than men. The patient has inveterate pains in the sciatic region, beginning peripherally in the foot and spreading upwards to the calf, etc. The sciatic pain is induced by slow walking or by standing about, whereas brisk walking, or more violent exertion, *e.g.* hill-climbing, cycling, etc., relieves the pain. The pain also disappears on lying down. If the patient be examined

[1] Barré, *Presse médicale*, 1919, pp. 57-60.
[2] Bonola, *Revue neurologique*, Sept., 1912, p. 324.
[3] Edinger, *Berlin. klin. Wochensch.*, 1914, No. 11.

in the recumbent posture, no abnormality may be detected, but if he is examined standing up, we sometimes observe at the site of maximum pain, *e.g.* in the popliteal space or below the head of the fibula, a slight puffiness or swelling. Occasionally there is also well-marked varicosity in the larger subcutaneous veins. It is important to recognise this variety of sciatica, since ordinary drug and counter-irritants fail to alleviate it—whereas gentle elastic pressure often relieves it at once.

Meralgia paræsthetica is a variety of neuralgia occurring in the area of distribution of the lateral cutaneous nerve of the thigh. It consists in paræsthesia or actual pain in the outer aspect of one thigh. The pain is often induced by standing or walking, possibly owing to stretching of the fascia lata. In some cases it results from the pressure on the nerve by a badly-fitting corset. It is sometimes associated with flat-foot on the same side. Here, as in brachial or sciatic pain, the presence of an area of impaired sensation would indicate a neuritis rather than a neuralgia.

In rarer cases we may find neuralgia in the area of the anterior crural or of the obturator nerve, and this may be symptomatic of an intra-pelvic tumour, or of an obturator hernia.

The pains of brachial or sciatic neuralgia and neuritis, and of meralgia paræsthetica, are unilateral. Let us now consider the bilateral pains which may be met with in the limbs.

Bilateral pains should always suggest to our minds either a toxic cause attacking the peripheral nervous structures of both limbs, or some central disease of the spinal meninges affecting the posterior roots bilaterally, or again some angio-neurotic condition such as Raynaud's disease, erythromelalgia, or intermittent arterial claudication.

Pains in the muscles or joints are a common symptom in people who work under compressed air, as in divers or workers in deeply sunk caissons, whether under ground or under water. The symptoms of **caisson disease,** or "decompression paraplegia," are most likely to occur when the worker ascends too abruptly to the ordinary atmosphere. All such workers ought to pass through a "decompression-chamber," where the atmospheric pressure is gradually reduced to normal. If this be not done, bubbles of nitrogen are set free in the blood and may either form emboli in the arterioles of the central nervous system with consequent small foci of necrosis, or the nitrogen may effervesce or explode out of the capillaries into the nervous tissues, especially into the substance of the spinal cord. Capillary hæmorrhages may also occur. Clinically in such cases not only have we severe pains in the limbs, but also aural symptoms due

to labyrinthine affection:—deafness, giddiness and tinnitus, sometimes even actual rupture of the tympanic membrane. There may also be anæsthesia and paraplegia of spinal type, and such paralysis may be permanent. Slighter cases clear up quickly, if the air-extravasation has been merely from the capillaries without air-embolism of the arterioles.

The *lightning pains* of tabes may be unilateral or bilateral. They are commoner in the legs than in the arms, since tabes is a disease which generally begins in the posterior root-fibres of the lumbo-sacral region. These pains are variously described by the patient as stabbing, burning, tearing, or bursting, and are commonly associated with local hyperæsthesia of the skin. They are frequently mistaken for rheumatic pains, and all the more so inasmuch as they often coincide with changes in the weather.

Tight "tourniquet" pains around the lower limbs, in broad zones rather than narrow, are sometimes an early and persistent symptom in disease of the lumbo-sacral region of the cord. They are due to irritation of the posterior roots, and may also occur in tabes. Root-pains also occur, though less commonly, in certain cases of multiple sclerosis.

The *root-pains* of tumour or inflammation of the spinal meninges, or of spinal caries or tumour, are more or less constant, with paroxysmal exacerbations. Inflammatory affections of the meninges are usually bilateral from the outset, with corresponding bilateral pains. But in cases of meningeal tumour the pains are generally unilateral at first, and become bilateral as the disease spreads to the opposite side. The level of the pains in meningeal disease varies with the level of the affected posterior roots. Thus in cervical meningitis, tumour or caries, there is pain in the neck, spreading down one or both arms along the corresponding root-areas; in thoracic cases the pain is around the trunk, and in lumbar or sacral cases it is in various parts of the lower limbs. The recto-perineal pain of certain cauda equina lesions is peculiar in that it occurs in the sitting posture only, and disappears when the patient lies down or stands up, so as to relax the adherent sacral roots. Meningeal pain is often associated with local hyperæsthesia corresponding to the uppermost roots affected, and with tonic spasms of the muscles at that level. If the meningeal lesion affects the cord within, whether by compression or by infiltration, there will be in addition to root-pains the other signs of organic cord disease—so-called *paraplegia dolorosa*, with its superadded anæsthesia, motor weakness and alterations of reflexes below the level of the lesion. Inflammatory, tuberculous and syphilitic affections of the spinal meninges are always associated with cellular changes in the cerebro-spinal fluid.

Affections of the peripheral nerves may also produce pain. Thus in peripheral neuritis there is not only pain, with hyperæsthesia of the skin of the feet and hands, but there is intense muscular tenderness on pressure, together with a degree of tactile anæsthesia, and in severe cases muscular paralysis and muscular atrophy, accompanied by the reactions of degeneration.

Pains localised in single nerve-areas should always lead us to examine the nerve-trunk in its entire extent. *Tubercula dolorosa* are multiple growths (usually neuro-fibromata) in the connective tissue of the nerve-trunks, many of them forming little subcutaneous nodules easily palpable and exquisitely tender, others less accessible in the deeper nerve-trunks, causing referred pains in the particular nerve areas. If these growths not merely irritate but interrupt the nerve-fibres within the nerve-trunks, there may, in rare cases, be areas of anæsthesia. Clinically we seldom find motor paralysis from such growths except as a result of pressure on the spinal cord or base of the brain by a neuroma on one of the spinal or cranial nerve-roots.

Causalgia (*καυσός* = heat), better named **Thermalgia,**[1] is a variety of neuralgia in which the pain is accompanied by an intense subjective burning feeling. It is commonly associated with vaso-dilatation, redness, and sweating of the affected area of skin, chiefly of the palm or sole. Thermalgia is generally traumatic in origin, from injury to the nerve or, less commonly, to the main artery of the affected limb. In nerve injuries it is usually a sign of incomplete division of the nerve-trunk, together with excessive formation of fibrous tissue within and around the nerve. It occurs more often in median than in ulnar lesions, and rarely after injuries of the musculo-spiral nerve.[2] In the lower limb it affects the internal popliteal nerve much more often than the peroneal.

Thermalgia in peripheral nerve-lesions is associated with the signs of incomplete paralysis, sensory or motor, according to the particular nerve-strands damaged. In rare cases it occurs independently of any paralysis, *e.g.* thermalgia of the fingers after an injury in the neighbourhood of the brachial artery.

There is usually an interval, perhaps of several weeks, after the original injury, before the thermalgia sets in. Then, concurrently with the formation of scar-tissue, pain appears in the palm (or sole) and gradually increases in severity. The pain is often paroxysmal, and the patient plunges his hand, or foot, into cold water, or swathes the part in cool moist dressings, to assuage his suffering. Sometimes he holds the affected limb in an elevated posture, to diminish its

[1] Stopford, *Lancet*, Aug. 11, 1917, p. 195.
[2] An example of thermalgia after musculo-spiral injury, however, is given on p. 515.

blood-supply. The pain is aggravated by warmth or by a dependent posture of the limb.

To explain the foregoing phenomena, various hypotheses have been suggested. The most probable explanation is that the phenomena are due to a reflex vaso-dilatation; the scar-tissue in and around the nerve constantly irritates the sympathetic centre in the corresponding segment of the spinal cord. Another theory ascribes the phenomena to irritation of the peri-arterial sympathetic plexus of the main artery. Thus in a case of bullet-wound of the axilla followed by obstinate thermalgia of the hand and forearm, removal of the sheath of the brachial artery and of the surrounding scar-tissue promptly relieved both the pain and the cyanosis.

It is a curious fact that thermalgia should be specially frequent after injuries of the median and sciatic nerves, both of which have a special artery supplying the nerve-trunk. These two nerves also differ from the other nerves of the limbs in containing proportionally a larger number of vasomotor fibres for the supply of the superficial palmar and plantar arches and digital vessels.

Thermalgia of the face is occasionally met with after injuries of the eyeball in which a stump of the globe still remains in the orbit.[1] (After complete enucleation it is uncommon, provided the enucleation is done as a primary operation. Subsequent removal of the eye-stump does not relieve the pain.) The symptoms do not appear until several months after the original injury. The patient then begins to have paroxysms of intense burning pain in the face on the affected side, radiating to the vertex, together with flushing of the whole face and sometimes sweating. These phenomena, in all probability, are due to reflex irritation of the cervical sympathetic, from cicatrisation in the region of the ciliary ganglion.

In certain cases of thermalgia we may find not merely local hyperæsthesia of the skin at the site of the pain, but even stimulation of the skin at any other part of the body, *e.g.* the opposite limb, may induce intense pain, referred to the original thermalgic area. This variety of thermalgia has been called **synæsthesalgia.**[2] The synæsthesalgic pain is not elicited by mere contact or pressure on some particular spot, but if we displace the point of contact, *e.g.* by gentle friction or tickling, intolerable pain at once appears in the thermalgic area, often accompanied by intense emotional reaction, and even by flushing and sweating of the face or limb on the side of the thermalgia. Moistening of the object which is touched, or wetting of the skin before being touched, diminishes the tendency to induce synæsthesalgia.

[1] Monbrun and Athanassio-Benisty, *Révue neurologique*, Juin, 1916, p. 906.
[2] Souques, *Société de Neurologie*, 6 Mai, 1915.

It is convenient here to refer to *erythromelalgia*, characterised by cyanosis and pain in one or both feet in the dependent posture, relieved by elevating the limb; to *Raynaud's disease*, which may be associated not only with local pallor, cyanosis or gangrene, but also with subjective sensations of tingling or pain; and to *intermittent arterial claudication*, in which the patient after a few steps becomes unable to walk farther, owing to intolerable pain in the muscles of the leg. To these conditions we shall return later, when studying the nervous affections of the vascular system.

Paroxysmal spontaneous pain in the periphery of a limb, ascending towards the trunk, sometimes occurs as a variety of sensory fit in gross disease of the cortical sensory areas in the contra-lateral post-central gyrus. Thus in one case of my own, in which there was a focal lesion of the left post-central gyrus, the earliest symptom was paroxysmal pain in the right fingers and hand.[1]

Finally, we should refer to the group of pains met with in hysteria and neurasthenia. These are more often areas of hyperæsthesia than of spontaneous pain. They are specially common in the neighbourhood of joints, whose slightest movement causes intense pain. In other cases the muscles are apparently hypersensitive, so that any attempt at movement of the limb, active or passive, causes an illusion of pain—so-called *akinesia algera*, of psychical origin. But the history of the case, in which there has often been a preceding local injury, the absence of signs of structural disease, local or central, and the presence of other hysterical or neurasthenic phenomena, will aid us in our diagnosis. It may be necessary to give a general anæsthetic in order to eliminate gross local organic disease.

[1] *Review of Neurol. and Psychiatry*, 1908, p. 379.

CHAPTER XII

ABNORMALITIES OF SENSATION: HYPERÆSTHESIA, PARÆSTHESIA, ANÆSTHESIA

We have already considered the anatomical course of the chief sensory paths from the periphery to the perceiving centres in the brain (Chapter I.). Let us now proceed to consider the methods of clinical investigation of the various forms of sensation.

All parts of the surface of the body are not equally sensitive. Thus the tip of the tongue, the lips, the finger-tips, in the order mentioned, are most sensitive to surface impression, whilst other parts, such as the dorsal aspect of the trunk, the upper arm, and the calf of the leg, are least sensitive. These differences depend on various factors, such as thickness of epithelium, relative abundance of sensory end-organs, etc., into which we need not enter more minutely here.

All sorts of ingenious apparatus have been devised for the accurate measurement of minute differences in sensibility to touch, pressure, pain, temperature, and so on. But for clinical purposes we should avoid complicated apparatus, and content ourselves with the simplest possible methods which, whilst accurate enough for practical purposes, do not impose too great a strain on the patient's attention nor demand too high a degree of intelligence on his part.

The most important varieties of sensory stimuli which we employ in testing a patient's sensory functions are light touches, pin-pricks, cold and hot objects, all of which refer to *cutaneous sensations*. We have also to consider other sensations from deeper structures, such as *joint-sensation* (or sense of position on passive movement), *active muscle-sensation* (kinæsthetic sense, or sense of active muscular contraction), and, lastly, the *vibration sensation* produced when a sounding tuning-fork is placed over the subcutaneous surface of a bone or upon a finger-nail. There are other varieties of sensory stimuli, such as electro-cutaneous sensibility (which is generally, but not always, parallel in intensity with the pain-sense), and there is the sensation of pressure and appreciation of differences of pressure, etc. But these, though physiologically interesting, are of minor clinical value.

There is perhaps no better criterion of neurological dexterity than the accuracy with which an observer can map out areas of diminution

or loss of sensation on the one hand, or of perverted or exalted sensation on the other. Both experience and patience are required, in order to obtain trustworthy results.

Inasmuch as we are largely dependent on the intelligence and good-will of our patient for accurate answers, we must try, as far as possible, to eliminate all distracting outside factors. Therefore when we are testing sensation we direct the patient to close his eyes, or, better still, cover them by a bandage, so that his attention may not be diverted by watching what is being done. We must also be careful not to weary a patient by too prolonged examination, lest as he gets tired or impatient his answers become inaccurate. The simpler our methods of examination, the better are our results likely to be. We have also to contend with wide variations in the intelligence of different patients, in their education, and in their attentiveness; this latter may be modified by pain, by anxiety, or by psychical deficiencies. Sometimes we have to deal with deliberate attempts on the part of the patient to mislead us. Fortunately, patients who simulate disease generally make blunders so gross as to prevent an erroneous diagnosis on the part of a careful observer.

Clinical Investigation of Sensation.—At the start, the patient's eyes should be closed, or bandaged, or some object should be interposed between his eyes and that part of the body which is being tested. The physician must be careful to avoid suggesting the presence of sensory changes to the patient under examination. The patient should not be asked whether he feels a particular stimulus distinctly, or less distinctly. He should simply be touched or pricked at some spot and told to "point to that spot" at once with his finger. In this way we avoid suggesting the presence of anæsthesia to a hysterical patient. We then proceed to test the various *cutaneous sensations*—touch, pain and temperature, separately and in turn.

Touch is tested by means of some soft light object, such as a tuft of cotton-wool, a feather, or by gentle pulling or stroking of the hairs. Loss of sensation in the hairs is called "tricho-anæsthesia." The compass test of epicritic sensibility is carried out by placing the points of a pair of blunt compasses on the skin and observing at what degree of separation the patient can recognise two points instead of one. **Pressure** is tested by means of a pencil or other blunt object; if such pressure be steadily increased a "deep" sensation of pain is ultimately produced. **Cutaneous pain** is tested by pricking, or better by scratching, with a sharp needle; **itching** by rubbing in the hairs of *mucuna pruriens*; **cold** by blowing on the skin, or by a cold object such as a metal spoon or a test-tube containing ice-cold water; **heat** by breathing on the skin or by a warm object such as a test-tube containing hot water, or

a metal spoon which has just been removed from a jug of hot water at about 50° C. Higher temperatures produce sensations of pain rather than of heat alone.

Each variety of sensation should be examined separately, before passing on to the next kind of stimulus, and the results should be recorded on an outline-chart of the body. In mapping out areas of abnormal sensation, it is useful to have a skin-pencil with which to mark the patient's skin, before copying the result on our chart.

An important practical point in mapping out areas of anæsthesia is to begin within the anæsthetic area, and to work towards the normal skin, not in the reverse direction. It is easier for a patient to recognise the moment when he first feels a sensation than for him to observe when he first loses it. On the other hand, in mapping out areas of hyperæsthesia or of paræsthesia, we should work from normal skin towards the hyperæsthetic area, asking the patient to call out as soon as his sensation changes.

In setting about the examination of the sensory functions, we usually begin with that of touch. The patient's eyes being closed, we lightly touch successive spots on his face, trunk and limbs, sometimes on one side, sometimes on the other, meanwhile asking him to point quickly to the spot with his finger. We next proceed to do the same with light needle-scratches, then with cold and with warm objects. If the patient has an area of diminished or altered sensibility, we generally discover it by this method. When we find an area of abnormality, we proceed to map it out carefully, making separate observations for touch, pain, and temperature, and noting whether the areas coincide or overlap.

Besides noting whether a patient feels a stimulus, for instance a tactile one, we should also notice whether he localises it accurately. This is accomplished by asking him to place his finger on the spot where he was touched, for instance, the dorsum of the hand. A normal individual can do this accurately to within a fraction of an inch. But in certain varieties of anæsthesia, especially in cortical lesions, the patient, whilst able to tell that he has been touched, makes an error of several inches in localisation. This is called "atopognosis." Sometimes the patient, when touched on one side of the body, feels the sensation at the corresponding spot on the opposite side. This is termed "allocheiria," and occurs in certain cases of hysteria.

When testing pain, we sometimes find that although the patient correctly perceives and localises the stimulus, there is an abnormally long interval of time, perhaps amounting to several seconds, between the stimulus and the patient's perception of pain. This is called "delayed sensation," and is met with chiefly in cases of tabes.

The path for **itching sensation** appears to run along with the pain-fibres. Thus in organic lesions producing analgesia (*e.g.* syringomyelia, etc.) the normal sensation of itching produced by the application of *mucuna pruriens* to the skin is lost in the analgesic area.[1] In areas of hypalgesia pin-pricks may cause itching instead of pain, whilst *mucuna pruriens* induces a subnormal degree of itching.

When charting areas of very slight cutaneous anæsthesia, it is often difficult, despite the utmost care as regards our stimuli, to obtain an exact outline of the area of altered sensibility. Changes in the quality of sensations may exist which are undetectable even by cotton-wool touches. Nevertheless the patient, if he tests his own skin, may be conscious of an abnormality too delicate to be discovered by another person on objective examination. But if we have a specially intelligent patient and get him to explore his anæsthetic area by stroking with his own finger, indicating where he perceives a line of transition between normal and abnormal, it is often possible for him, by such "auto-exploration," to map out his area of altered sensibility with great accuracy.[2]

If a fold of skin be lifted up between the finger and thumb and pulled in various directions, upwards, downwards, or sideways, a normal person can always recognise the direction in which his skin is being displaced.[3] Sometimes, however, in early tabes the direction of traction of the skin and subcutaneous tissue is lost over a wide area, and this phenomenon may be present long before any cutaneous tactile anæsthesia or analgesia can be made out.

So much for cutaneous and subcutaneous sensations. But there are other forms of sensation which are of clinical importance. The **proprio-ceptive sense-organs**, deeply embedded in the skeletal muscles, tendons and joints, serve to report the exact state of contraction of the muscle, tension of the tendon and posture of the joint, thereby regulating and co-ordinating muscular activity. This group of sensations comprises joint sense, kinæsthetic sense, and tendon sensibility.

Joint sense is tested by moving a joint passively into various positions backwards and forwards, then holding it fixed in a certain position, such as that of semi-flexion, and asking the patient to imitate exactly that position with the limb of the opposite side. During this test the muscles of the joint under examination must be fully relaxed, for it not infrequently happens that when a patient is in doubt as to the position of his joint, he begins to make slight voluntary movements of the joint before answering. These must not be permitted, since he thereby gains information as to the position of the

[1] Thole, *Neurologisches Centralblatt*, 1912, s. 610.
[2] Trotter and Davies, *Rev. of Neurol. and Psych.*, 1907, p. 761.
[3] Bäyer, *Münch. med. Wochensch.*, May, 1914, p. 1105.

limb, not from his joint sense, but through an entirely different sense, viz. the kinæsthetic sense or sense of active muscular contraction.

To test this *kinæsthetic sense*, we notice whether the patient, when raising his limbs, can detect differences in the weights of objects of similar size, for example a shilling and a sovereign, either placed in his hand, or hung in a sling over his hand or foot. For this purpose we sometimes employ a series of leather or wooden balls of equal size, loaded with different weights. Normally, according to Weber's law, a healthy individual should detect an increase of one-third in the weights of two successive objects. Tabes is the disease in which this sense of active muscular contraction is most markedly diminished, and in which the joint sense is notably impaired also. The loss of these two senses is probably the main factor in the production of tabetic ataxy. Loss of kinæsthetic sense is also present in many cases of "cortical" anæsthesia.

We purposely avoid using the term "muscular sense," for several reasons. Firstly, it is ambiguous, since it has been used to include two entirely different senses:—joint sense and kinæsthetic sense. Moreover, it might also be confounded with a third sense, the *sensibility of muscles and tendons to deep pressure* with the fingers. Normally such pressure, if moderate in degree, is painless; but in certain diseases, as in peripheral neuritis, in the various forms of myositis, and in the abdominal muscles superficial to an area of peritonitis or in the segmental area corresponding to an inflamed internal organ, the muscles become exquisitely tender to the lightest pressure. On the other hand, it is common to find in tabes that severe compression of the muscles and tendons, for example of the leg muscles, and especially of the tendo Achillis, is painless (Abadie's sign). This muscle and tendon analgesia is often present in early stages of the disease.

It is sometimes of value to observe the patient's power of recognising, without seeing them, the forms of solid objects placed in his hand—so-called *stereognostic perception*. Normally a patient should be able to recognise familiar objects such as a key, a coin, or a chain. Stereognosis can also be tested in the foot by pressing certain objects (*e.g.* a chain, sponge, brush, or the observer's finger) against the plantar surface of the toes. In some cases the patient, though able to feel the presence of the object, cannot describe its form and qualities without seeing it. Such "astereognosis" is due to impairment of sensation, whether from peripheral disease, from thalamic lesions, or from disease in the cortical centres.

Lastly, there is the *vibration sense* (pallæsthesia, or "osseous sense") described originally by Egger. This is tested by means of a low-pitched tuning-fork, which is set into vibration and placed upon

the subcutaneous surface of a bone. In normal individuals a characteristic vibratile thrill is felt. But in certain diseases involving the posterior roots or posterior columns, such as tabes, or in transverse lesions of the spinal cord, the vibration sense may be lost in the bones corresponding to the affected roots (Fig. 86). Loss of this sense may be the earliest form of anæsthesia in root-lesions as in tabes, where it sometimes precedes cutaneous anæsthesia. In Brown-Séquard paralysis vibration sense is lost on the same side as the muscular paralysis[1] (see Figs. 11 and 14). But the vibration sense is not an exclusive property of bones, though bones are most strikingly sensitive; it can be perceived in other tissues, notably in the nails, which are closely connected with the periosteum, and even in the connective-tissues, although in them less intensely.

FIG. 86.—Tabes with loss of vibration-sense in bones of lower limbs, pelvis, lumbar, and lower dorsal vertebræ. The bones with loss of vibration-sense are shaded black.

Excessive sensitiveness to normal stimuli is termed **hyperæsthesia**. Such hyperæsthesia is usually accompanied by a degree of discomfort or even pain, even though a stimulus be used which is ordinarily painless. The term **paræsthesia**, or perversion of sensation, signifies that an ordinary stimulus evokes an unusual sensation, as for example a feeling of tingling when the skin is touched, or a feeling of acute pain when moderate cold is applied. Under the head of paræsthesiæ we may also include such phenomena as multiple sensations (polyæsthesia), allocheiria, etc.

Strictly speaking, diminution of sensation should be designated *hypo-æsthesia*, and the term anæsthesia should be reserved for total loss of sensation. It is usual, however, to speak of "slight," "moderate," and "total" anæsthesia. When only one form of cutaneous anæsthesia is referred to, we sometimes find it convenient to talk of *tactile anæsthesia*, of *analgesia* or loss of pain sense, and of *thermo-anæsthesia* or loss of temperature sense. We speak of *dissociated anæsthesia* when some forms of sensation, such as tactile sense, are normal, whilst in the same area others, such as pain and temperature sense, are lost. This occurs especially in syringomyelia and in the Brown-Séquard syndrome.

We speak of *hemi-anæsthesia* where one-half of the body, right or left, is affected, and of *para-anæsthesia* where both legs or both arms are affected owing to a lesion of the spinal cord or to a symmetrical affection of the posterior roots. We also speak of radial, ulnar,

[1] *Vide* Bing, *Neurolog. Centralblatt*, 1910, p. 173.

peroneal anæsthesia, etc., where the sensory loss corresponds to the distribution of a single peripheral nerve.

Hyperæsthesia.—Universal hyperæsthesia is rare. It is chiefly met with in hysteria, but also occurs in other affections, as in strychnia poisoning, where the slightest touch may suffice to evoke a violent spasm. Hemi-hyperæsthesia is chiefly found in neurasthenic and hysterical patients, and may be associated with other hysterical phenomena. Thus I remember the case of a soldier with traumatic hysteria who had hemi-hyperæsthesia, accompanied by abnormal widening of the visual field and by increased acuity of smell, taste, and hearing, all on the hyperæsthetic side of the body.

In the thalamic syndrome, hemi-hyperæsthesia (or excessive reaction) to temperature and pain, sometimes coexists with hemi-anæsthesia (or loss of sensation) to tactile stimuli and with impairment of joint sense, loss of osseous sense and astereognosis in the affected limbs. In some thalamic cases the pleasurable sensation produced by a warm hand applied to the skin of the affected side is associated with a marked accentuation of pleasure; and even emotional conditions of pleasure or the reverse (*e.g.* those produced by music) may be accompanied by specially intense response in the abnormal half of the body.[1] This thalamic overaction is due, not to irritation of the thalamus, but to its release from normal cortical control.

Hyperæsthesia in more or less symmetrical root-areas of the trunk or limbs, due to irritation of the posterior roots, is not uncommon in diseases causing pressure on the spinal cord or its meninges, as in caries or tumours of the spine. Here the hyperæsthesia corresponds to the area supplied by the uppermost root involved, and is usually associated with anæsthesia and motor weakness in the parts below.

Odd irregular areas of hyperæsthesia, which do not correspond either to root-areas or to the distribution of peripheral nerves, are amongst the commonest phenomena of hysteria. Tender areas are particularly common over hysterical joints and over certain vertebral spines in hysteria, and we frequently notice that the lightest touches cause severe pain, whereas, when the patient's attention is diverted, deep pressure on the same spot may be painless. Pressure on such tender spots may sometimes excite a hysterical attack—"hysterogenic" areas—and in other cases may restrain or stop an attack—"hysterofrenic" areas. To this subject we shall return when discussing the diagnosis of hysteria.

Next in frequency after hysterical hyperæsthesia are areas of cutaneous hyperæsthesia in tabes. Tactile hyperæsthesia is specially common in cases with gastric or other visceral crises, in the root-areas

[1] Head and Holmes, *Brain*, 1911, pp. 134–135.

corresponding to the viscus affected. It is also common in the areas where lightning-pains are felt, and like these pains it may be one of the earliest evidences of the disease. Thus a patient with incipient tabes, for years before he reached the stage of ataxia, was so hyperæsthetic around the trunk that it was agony for him to pull his shirt on, or to sponge his body when bathing. Tabetic hyperæsthesia may occur not only on the trunk, but also on the limbs, and even on the face. Hyperæsthesia is specially frequent round the orbits in cases of tabetic ocular palsies.

Hyperæsthesia in the areas of peripheral nerves occurs in the true neuralgias, as in trigeminal neuralgia, where the neuralgic area is often exquisitely tender, especially over the foramina of exit of the various branches. The patient may be unable to wash his face for weeks at a time, because the lightest touches induce a paroxysm of neuralgia. Localised hyperæsthesia sometimes precedes the eruption of herpes zoster, and may persist for weeks or months after the eruption has passed away. Lastly, we may mention the hyperæsthesia of the hands and feet in multiple neuritis, in which condition there is often present a degree of anæsthesia also. The coexistence of hyperalgesia to light pressure with anæsthesia to light touches is very characteristic of alcoholic neuritis.

Paræsthesia, or perverted sensation, has much the same diagnostic significance as hyperæsthesia. It may also be mentioned that when a peripheral cutaneous nerve is in process of recovery after an injury, the skin often passes through a stage of paræsthesia before normal sensation is restored.

Anæsthesia.—Universal anæsthesia of the skin and accessible mucous membranes to all forms of stimuli is exceedingly rare, occurring only in hysteria. Fig. 87 shows such a case in a girl, in whom it was possible to push pins through the skin on both sides of the body without causing pain.

Hemi-anæsthesia always indicates a central affection. In every case of hemi-anæsthesia we must determine whether the disease is functional or organic, and if organic, at what level in the sensory tract the lesion is situated, whether in the cortex, internal capsule, optic thalamus, or lower down.

Hysterical hemi-anæsthesia is the result of suggestion, whether by the patient or by the medical observer. It varies in degree from total anæsthesia down to the slightest degree of blunting of sensation, only discoverable on comparison of the two sides. Not uncommonly it tends towards the "segmental" type, and it is frequently accompanied by other hysterical phenomena, especially by blunting of the special senses on the hemi-anæsthetic side, concentric contraction

of the visual field, and by other features which we shall study later. Hysterical anæsthesia produces no inconvenience or loss of function, so that a hysterical patient with anæsthesia, say, of one upper limb, is able with eyes closed to execute fine movements for which accurate cutaneous sensation is indispensable, *e.g.* picking up a pin, buttoning or unbuttoning a garment, etc.

FIG. 87.—Universal anæsthesia in a hysterical patient. Sterilised safety-pins have been pushed through the skin on both sides without producing bleeding. Hysterical contracture of the left hand is also present.

We should remember that hysteria sometimes coexists with organic disease, thereby complicating the diagnosis.

Organic hemi-anæsthesia may also vary in its degree, from slight to severe anæsthesia; but it is never absolute in degree as in some cases of hysteria. It is generally more marked on the limbs than on the trunk or face, and more intense at the periphery of a limb than at its

proximal end. It is never marked off by a sharp line running across the limb, as is the "segmental" anæsthesia of hysteria, but fades gradually in intensity as we pass from the hand to the shoulder. A degree of atopognosis is always present in organic hemi-anæsthesia. The special senses are unaffected (their paths probably do not traverse the internal capsule), with one exception, namely that of vision, in cases in which the lesion implicates the optic radiations. But here again we get a homonymous hemianopia, unlike the hysterical contraction of the visual field to which we shall refer later.

If we find that a hemi-anæsthesia is organic in origin, we have then to determine whether the lesion is cortical in situation or whether it is lower:—in the thalamo-cortical path, in the optic thalamus itself, or below it. In **cortical hemi-anæsthesia** the other signs of cortical disease will aid the diagnosis. Thus in a mixed motor and sensory syndrome the presence of monoplegia rather than hemiplegia, or the occurrence of Jacksonian fits, will point to a cortical localisation, remembering that the cortical sensory areas are widely distributed over the parietal cortex, some of them intermixed with the corresponding motor centres in the pre-central gyrus.

According to Head, the most *anterior* part of the sensory cortex has to do with the recognition of *spatial* impressions, whether these be one-dimensional (spot-finding or topognosis), two-dimensional (compass-test), or three-dimensional (passive movements). The *lower* and posterior zone of the parietal region is associated with the recognition of *intensity* of sensations—"more-or-less-ness," *e.g.* the distinction between a warm object and a warmer one. The post-central gyrus is specially concerned with the recognition of *identity and difference*, as regards the size, shape and form of objects brought into contact with the body. The cortical centres are not concerned with the crude appreciation of touch, pain, heat, and cold.

Cortical anæsthesia is specially associated with untrustworthiness of response to the same tactile stimulus owing to failure of attention and to erroneous judgments, and with abnormally early fatigue, so that responses to touches on the affected hand rapidly tend to disappear. The most frequent sensory defects produced by a cortical lesion are loss of joint sense, inability to recognise differences in the weights of objects, and inability to recognise the posture of the affected limb in space when the eyes are closed.[1] Cortical anæsthesia is less profound than thalamic, and is most distinct at the periphery of the affected limb. Indeed, in cortical anæsthesia it is usual for the trunk to be little or not at all affected.

Thalamic hemi-anæsthesia, generally the result of a lesion in the

[1] Head and Holmes, *Brain*, 1911, vol. xxxiv.

postero-external part of the optic thalamus, is never monoplegic in type, but always affects the entire half of the body, including the trunk. Hemi-anæsthesia to cotton-wool touches from a thalamic lesion is often associated, as we have seen, with paroxysmal pains of intolerable severity in the affected limbs and side of the face, and with excessive sensibility to pain and temperature on the anæsthetic side, so that when a pin-point, or a hot or cold object, is dragged lightly across the trunk from the normal to the anæsthetic side, it causes excessive discomfort as soon as it crosses the middle line.

The thalamic syndrome also includes hemi-ataxy of the limbs and spontaneous choreiform or athetoid movements. The deep reflexes are unaffected, and the plantar reflex remains of the normal flexor type, since the pyramidal motor path is intact. The patient often gives a history of transient motor hemiplegia at the onset, but this motor weakness rapidly disappears and is succeeded by paroxysmal pains in the hemi-anæsthetic limbs and face.

The intensity of thalamo-cortical and of thalamic anæsthesia is deeper than in cortical cases, but not so markedly intensified at the periphery of the limbs. It is associated with hemianopia if the lesion extend backwards, or with motor hemiplegia, most marked in the leg (but not a monoplegia), if the lesion extend forwards into the pyramidal motor path.

We may also have **sub-thalamic hemi-anæsthesia** from organic lesions of the sensory path below the level of the optic thalamus; in fact, at any level in the fillet above the sensory decussation in the medulla. Such lesions are no longer associated with hyperæsthesia to painful stimuli, and can often be correctly localised by the co-existence of other signs. Thus a unilateral lesion in the *dorsal aspect of the pons*, implicating the trigeminal nerve or nucleus, together with the remainder of the sensory fibres belonging to the other side of the body, will cause a *crossed hemi-anæsthesia*, *i.e.* anæsthesia of the face on the side of the lesion, and of the arm, trunk, and leg on the opposite side (Fig. 13, p. 15). A lesion of the sensory path in the medulla below the level of the trigeminal nerve must be more widespread laterally to produce a complete hemi-anæsthesia, since the path for temperature and pain is here at some distance from the tactile path (Fig. 12, p. 15).

Anæsthesia also occurs in certain **lesions of the spinal cord.** We should note, however, that there are many cord diseases in which anæsthesia is absent, such as progressive muscular atrophy, amyotrophic lateral sclerosis and acute anterior poliomyelitis. Disseminated sclerosis also is a disease in which sensory changes are frequently absent. But if the spinal cord be destroyed or divided at a certain transverse level, whether by trauma or by disease such as acute

softening, whereby sensory as well as motor paths are interrupted, all the sensory impressions ascending in the posterior and lateral columns (Figs. 9 and 11, pp. 9 and 14) will be lost below the level of the lesion. We then have a *para-anæsthesia*, the upper limit of which corresponds with that of the highest sensory root affected. The anæsthesia of a total transverse lesion implicates all forms of sensation, both superficial and deep. And since in many of these cases there are irritative or inflammatory processes affecting the roots immediately above the area of destruction, it not unfrequently happens that there is a narrow zone of paræsthesia or of hyperæsthesia immediately above the anæsthetic area.

In cases in which the cord is gradually compressed by progressive disease in the meninges or vertebræ, there is usually a progressive paraplegia with the usual alteration of reflexes. Here anæsthesia appears late in the disease, being preceded by spontaneous subjective sensations or *dysæsthesiæ*, after which hyperæsthesia appears, and last of all anæsthesia. Moreover, in compression-paraplegia the lower sacral root-areas are usually less deeply anæsthetic than the areas above.

When a cord lesion is incomplete in its transverse extent, certain forms of sensation may escape. Thus unilateral lesions of the cord produce **Brown-Séquard paralysis.** Most commonly this is the result of a stab or bullet-wound, but it may also be caused by softenings or growths. Or a lesion which was originally more extensive, *e.g.* a hæmorrhage, may clear up so as to become a unilateral one. In the typical Brown-Séquard syndrome, as will be seen from Figs. 11 and 14, there are on the side of the lesion the well-known motor and vaso-motor paralyses, together with loss of sensation in the joints and muscles and loss of vibration sense, whilst on the opposite side there are thermo-anæsthesia, analgesia and some tactile anæsthesia. In thermo-anæsthesia from cord lesions, the areas of anæsthesia to cold and to heat are sometimes co-extensive. But this is not always so; sensibility to heat may be abolished without loss of sensibility to cold, or *vice versâ*, or the areas of loss to heat and to cold may differ widely in extent. If the lesion be above the lumbar enlargement, as is generally the case, the motor paralysis is of the upper neurone type, with spasticity, increased deep reflexes and an extensor type of plantar reflex. If, as sometimes happens in stab-wounds, the lesion destroys the most lateral region of the cord, but does not quite reach the middle line, thereby sparing the postero-internal column, the deep structures on the side of the lesion preserve their sensibility. In any case, on the side of the lesion, a narrow zone of anæsthesia exists, corresponding to the posterior root-fibres cut across at the level of the

lesion. And in cases with an abrupt onset there is, above the anæsthesia, a zone of hyperæsthesia from irritative root-changes.

Dissociated anæsthesia, often without motor paralysis, is characteristic of disease in the region of the posterior cornua of the cord or in the substantia gelatinosa of the medulla, as in *syringomyelia* and *syringobulbia*, in which analgesia and thermo-anæsthesia occur, together with loss of vibration sense, corresponding to the area of spinal cord affected, on one or both sides, whereas tactile sensation remains unimpaired (see Fig. 88). The area of dissociated anæsthesia in syringomyelia does not, as a rule, include the parts below the level of the diseased posterior horn. Only in exceptional and advanced cases and where the lateral columns have become implicated, including the long crossed fibres of the spino-thalamic tract, does the thermo-anæsthesia affect the lower limb or limbs. The syringomyelic patient often burns his fingers accidentally without pain, and he may develop painless whitlows in his analgesic fingers—so-called *Morvan's disease.* He may also have spontaneous disintegrations in joints, with fractures and osteophytic or destructive changes in the articular ends of the bones. In most cases of syringomyelia there also is some atrophy of the anterior cornua; therefore we should be on the look-out for a coexisting muscular atrophy of spinal type, involving especially the small muscles of the hands. If the pyramidal tracts become involved in syringomyelia, a spastic paraplegia is superadded, and sooner or later a degree of scoliosis or even kypho-scoliosis develops (Fig. 89).

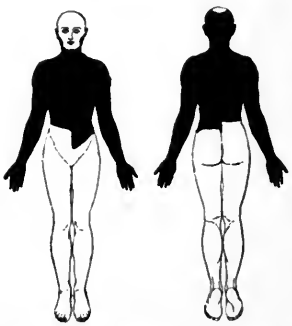

Fig. 88. — Bilateral syringomyelia, indicating area of thermo-anæsthesia and analgesia in the patient shown in Fig. 89.

But unilateral cord lesions and syringomyelia are not the only diseases which produce dissociated anæsthesia. A small lesion such as an area of softening or of new growth, in the *ponto-cerebellar angle* of the pons, at the level of the auditory nerve, will cause deafness of the same side with analgesia and thermo-anæsthesia of the opposite side, tactile sensation being unaffected. If the cerebellar peduncle be involved, there will be cerebellar phenomena also, such as we have already studied.

Tabetic anæsthesia is the commonest of all organic anæsthesiæ. In this disease the sensory loss tends to follow fairly closely the distribution of the posterior roots affected by the tabetic process. Thus it is commoner in the lower limbs than in the upper. Joint sense and vibration sense usually become impaired earlier than cutaneous sensa-

tions, whilst analgesia precedes tactile anæsthesia. In the upper limbs the fingers on the ulnar side of the hand are usually affected earlier than the other digits, and there is often a strip of analgesia

FIG. 89.—Syringomyelia with arthropathy of right shoulder-joint and scoliosis.

running longitudinally along the inner side of the whole upper limb, corresponding to the eighth cervical and first thoracic roots (Fig. 90). In many tabetics the ulnar nerve behind the elbow loses its normal

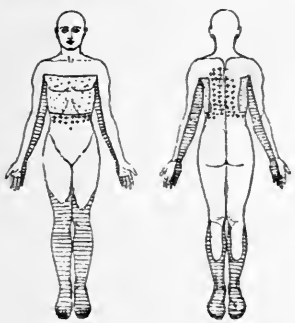

FIG. 90.—Early tabes, showing "cuirass" of subjective girdle-feeling (dotted area) with zone of cutaneous hyperæsthesia (crosses) below the cuirass, passing up between its limits posteriorly. Analgesic areas (horizontal shading) in upper limbs (C_8 and Th_1 roots) and in lower limbs (L_4, L_5, and S_1 roots).

sensitiveness on pressure—Biernacki's sign. And on the trunk it is common to find a broad zone of analgesia, and sometimes of tactile anæsthesia as well, the upper border of which is at the level of the second ribs in front. This zone is often incomplete laterally or

posteriorly, just as the subjective "cuirass" sensation may be. Analgesia of the glans penis is another early sign of tabes, also loss of the normal tenderness of the testicle on pressure. Acute inflammatory affections of the viscera, which in an ordinary individual are highly painful, may in certain tabetic patients run their course painlessly and even without rigidity of the superjacent muscles. Thus a tabetic patient may have acute pleurisy without pain; or an acute appendicitis or a gastric ulcer may progress painlessly to perforation and to diffuse, fatal peritonitis. These facts are probably to be explained by the presence of tabetic degeneration in the grey, afferent, rami communicantes leading from the sympathetic to the posterior root ganglia. Tendinous analgesia, on pinching the tendo Achillis (*Abadie's*

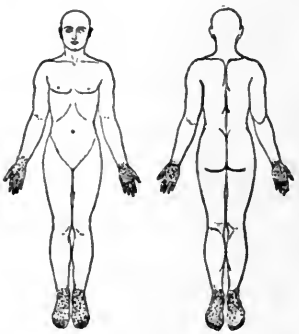

FIG. 91.—From a case of multiple neuritis, showing "glove" and "sock" areas of anæsthesia.

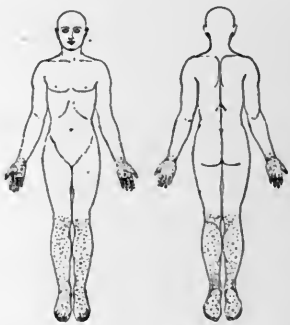

FIG. 91A.—From another case of peripheral neuritis, showing "glove" and "stocking" areas of cutaneous paræsthesia.

sign), is also present in the majority of tabetic patients. But tabetic anæsthesia is not always sharply limited to root-areas, and we should seek for confirmatory evidence of the disease in the pupils, deep reflexes, cerebro-spinal fluid, etc.

Anæsthesia in **peripheral nerve palsies** of sensory or mixed nerve-trunks is of course confined to the distribution of the affected nerve or nerves. If a pure cutaneous nerve be completely paralysed we have loss of cutaneous sensations, both "epicritic" and "protopathic," whilst the deep sensibility in muscles, tendons and bones is still preserved (see p. 12). The area of cotton-wool anæsthesia in a complete peripheral nerve lesion is always more extensive than the area of analgesia to pin-pricks. But as we ascend the nerve-trunk in a proximal direction, the two areas become more nearly co-terminous, until in a **posterior root-lesion** the area of loss to pin-pricks actually exceeds that of anæsthesia to cotton-wool touches. As Head has put it, the nearer the lesion lies to the central nervous system, the more extensive and

LIBRARY
COLLEGE OF MEDICAL EVANGELISTS

definite is the loss to pin-pricks; the nearer to the periphery, the greater is the loss to cutaneous touches with cotton-wool stimuli.

In cases of incomplete severance of a peripheral nerve the area of pin-prick analgesia is sometimes more extensive than that of cotton-wool loss. And if a nerve be partly cut across and at the same time partly compressed (*e.g.* by scar-tissue or callus), the cutaneous area corresponding to the cut part will show cotton-wool loss to be greater than pin-prick analgesia, whereas in the area corresponding to the compressed part, pin-prick loss will be greater than cotton-wool loss.[1]

If a **mixed nerve-trunk** be paralysed, muscular paralysis with atrophy is added to anæsthesia, not only of cutaneous, but also of deep sensibility in the corresponding bones, joints and tendons, and the diagnosis, as a rule, presents no difficulties. It must be borne in mind that as a mixed nerve recovers from its paralysis, sensation usually returns before motor power, and protopathic sensations recover before epicritic.

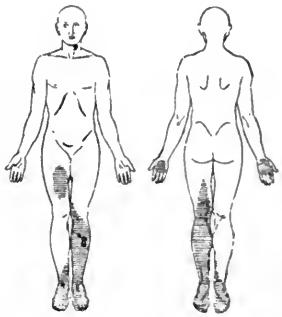

Fig. 92.—Anæsthesia in leprous neuritis.

The anæsthesia following an attack of *herpes zoster* sometimes lasts for a considerable time after the eruption has disappeared.

In the anæsthesia of *multiple neuritis*, whether resulting from alcohol, diphtheria, diabetes, septic poisoning, or other causes, the disease is generally bilateral and symmetrical, affecting hands or feet or both. Subjective tingling sensations usually precede the anæsthesia, which is of the "glove" and "sock" variety, not marked off sharply as in the "segmental" anæsthesia of hysteria, but shading off gradually at the upper margin (see Figs. 91 and 91A). Most cases have also some superadded motor weakness in the form of drop-foot and drop-wrist.

The anæsthesia of *leprous neuritis* is often curiously patchy and asymmetrical (see Fig. 92). It is associated with palpable thickening of the nerve-trunks and often with trophic changes in the skin, etc. (see later, p. 293).

Lead paralysis differs from ordinary peripheral neuritis in being entirely a motor palsy, free from sensory changes, and whilst affecting the muscles innervated by the musculo-spiral nerve, it usually leaves the supinator longus unimpaired. Moreover, the extensor communis is less severely paralysed than the extensor indicis and extensor minimi digiti.

[1] Core, *Lancet*, 1916, p. 716; Stopford, *ibid.*, 1916, p. 718.

CHAPTER XIII

ORGANIC MOTOR PARALYSIS OF UPPER NEURONE TYPE

In the investigation of the various motor palsies, apart from those affecting the cranial nerves which we have already studied, we should proceed in a definite order.

We commence by inspection of the palsied limb or limbs, noting the posture of the limb, the presence or absence of local muscular atrophy or hypertrophy, the existence of wounds, swellings, or other deformities. We then proceed to palpation of the bones and joints, following their outlines and testing their range of passive movement, so as to discover whether the deficiency of active movement may not be due to mechanical causes, such as fractures, dislocations, ankyloses, adhesions or inflammations of bones or joints, and so on.

Thus in the case of a semi-comatose lady, whom I saw within a few hours after a carriage accident, there was apparent inability to move the left arm or leg. This might have suggested a lesion of the right cerebrum producing hemiplegia, but a preliminary investigation of the bones showed that the left femur and left clavicle were broken. It was therefore unnecessary to diagnose an intra-cranial lesion of the pyramidal tract, especially as the plantar reflexes were normal on both sides. The result proved the correctness of this view.

We should also observe whether the muscles of the affected part are rigid, stiff and spastic, or whether they are loose, relaxed and flaccid.

Lastly, we proceed to investigate the patient's powers of voluntary movement of the affected limb. In doing this, it is not enough to tell the patient in general terms to " move the arm," and so on. We should test each joint and each movement separately, fixing the proximal part of the limb and instructing the patient to perform various movements:—flexion, extension, rotation inwards and outwards, etc., separately and distinctly. Thus, for example, when we direct a patient to pronate his forearm, we must fix the humerus and see that he does not abduct the shoulder to make up for deficiency in pronation. To determine whether a particular muscle is taking part in a movement or not sometimes requires very close observation, not only by inspection, but by palpation of the muscle or of its tendon. But, as Beevor has remarked,[1] the physician " must avoid the error of

[1] *Croonian Lectures*, 1904, p. 4.

assuming that the tightening of a tendon from the stretching of a passive muscle is evidence of contraction of the muscle."

Suppose that a particular movement of a limb is deficient, we estimate the deficiency in different ways, according to its degree. If the weakness is slight, we detect it by interposing some resistance, so as to load the muscles. This is accomplished either by means of weights, or, in the case of the hand, by making the patient squeeze our hand or compress an oval spring-dynamometer, or, in the case of the leg, by holding the limb down and making him elevate it against resistance.

If the weakness is more marked, it can be detected without loading the muscles. The weight of the distal part of the limb may in itself be too much for the muscles to lift, as, for example, in cases of drop-wrist and drop-foot, due to weakness of the extensors of the wrist and dorsiflexors of the foot. But even in these a minimal degree of voluntary contraction may perhaps still be present, and can still be detected by placing the limb passively in such a posture that its own weight is no longer a factor, *e.g.* by testing the extensors of the wrist with the forearm midway between pronation and supination, or testing the movements of the elbow by passively abducting the upper arm and getting the patient to flex and extend his elbow in a horizontal plane. Or we may even observe the limb when it is supported on all sides by water, as in a warm bath. In this way we may detect minimal movements. And in such cases we watch carefully, not only for movement of the joint, but for contraction of the tendons of the muscles concerned. These latter may sometimes be felt to contract, when they are too feeble to overcome the inertia of the joint.

By inspection and palpation we also note whether in the affected limb the muscles are normal in volume and firmness, whether some are enlarged and stronger than usual—*hypertrophy*—or whether some are diminished in size—*atrophy*, so that there is flattening, or even hollowing, in place of the normal muscular contour. In some cases an apparent increase in volume is accompanied by weakness of the enlarged muscles—so-called *pseudo-hypertrophy*.

If a muscle be atrophied, its electrical reactions, both to faradic shocks and to the continuous galvanic current, should be investigated. The reactions may be normal, or they may be merely quantitatively diminished. Or they may be qualitatively altered, as in the "reactions of degeneration" (see later, p. 410). Or they may be "mixed," when some fibres of the muscle are normal, whilst others intermingled with them are degenerated.

Reaction of a muscle to direct percussion is sometimes of value. This phenomenon consists in a contraction of the whole bundle of

muscle-fibres in their entire length. Response to direct mechanical excitation often persists when the deep reflexes are lost; thus, for example, when the knee-jerk is absent in tabes or peripheral neuritis, the quadriceps still responds to direct tapping. In most cases of lower motor neurone lesion this *mechanical irritability of the muscle-fibres* is increased, but the contraction is more flickering than in a healthy muscle. In muscular dystrophy the mechanical irritability is lost in the affected muscles.

In certain patients, especially on percussing the pectorals or other flat muscles of the chest, we may observe a wave of contraction dashing outwards suddenly in both directions from the point of percussion along the course of the muscular fibres, and immediately followed by a temporary small muscular swelling at the point of percussion, probably due to contraction of the undifferentiated sarcoplasm. This phenomenon is called **myoidema ;** it is common in pulmonary tuberculosis, but occurs also in many other wasting conditions not associated with muscular paralysis, and need not detain us further.

The term *paralysis*, when applied to voluntary muscles, signifies loss of the power of voluntary contraction, due to interruption, functional or organic, in any part of the motor path, from the cerebral cortex down to and including the muscle-fibre. This latter part of the definition is necessary so as to exclude such cases as ankylosed joints, in which movement is impossible from mechanical reasons without true paralysis. Strictly speaking, paralysis is total loss of voluntary motor power, lesser degrees of impairment being called **paresis.** But we often employ the term paralysis to include partial as well as complete loss of power.

The distribution of motor weakness differs according to the site of the lesion of the motor path. Thus in a unilateral brain lesion there is usually paralysis of one side of the body, including the face, trunk and limbs. This is termed *hemiplegia.* A bilateral cerebral lesion produces *diplegia* or *double hemiplegia*, the limbs on both sides of the body being affected. Paralysis of a single limb resulting from a cerebral lesion is termed cerebral *monoplegia.* Spinal or peripheral monoplegia is less common.

Paralysis of the limbs resulting from a lesion of the spinal cord is most commonly bilateral—*paraplegia*—and usually affects the legs alone; but if the lesion be in the cervical region, it affects both arms and legs. It must be distinguished from a cerebral diplegia, in which the face is sometimes also affected. In rare cases both arms may be paralysed from a spinal lesion, with little or no affection of the legs; this is *brachial paraplegia.* A unilateral spinal lesion may also cause a monoplegia, but this is uncommon. The term *crossed* or *alternate*

hemiplegia means that as a result of a single lesion there is paralysis of some parts on the right side and of others on the left. For example, a lesion in the right side of the pons at the level of the facial nerve will cause paralysis of the right side of the face and of the left arm and leg. There are, of course, other varieties of crossed paralysis.

When paralysis is due to a lesion of a peripheral nerve, it may either be asymmetrical, when the motor weakness is limited to one or more nerve-trunks, as in most traumatic nerve-palsies, or more commonly bilateral and symmetrical, as in the various forms of toxic neuritis, affecting either the upper or lower or all four limbs.

If paralysis be due to primary affection of the muscles themselves, as in the myopathies, its distribution is usually bilateral, and it affects all four limbs and sometimes even the face.

We must remember that it is not uncommon to meet with multiple lesions in a single case; yet, in diagnosis, it should always be our endeavour to try to account for all the symptoms by a single lesion.

Suppose, then, that a patient is suffering from motor paralysis (mechanical impediments having been excluded), the first question is—Is the paralysis *functional or organic?* If it is organic, we proceed to the further questions—*Where* is the lesion situated? (anatomical diagnosis), and *what* is its nature? (pathological diagnosis).

Is the Paralysis Functional or Organic?—Sometimes the distinction between functional and organic motor paralysis is easy; at other times it is a matter of considerable difficulty. Thus cases of early disseminated sclerosis are particularly liable to be mistaken for hysteria. Moreover, it is possible to have a combination of functional and organic disease in the same patient.

More detailed consideration of the diagnostic features of hysteria will be postponed till a later chapter (see p. 366), and we shall only here refer to some of the main features which enable us to decide that a case is organic rather than functional. Firstly, the history of the case often guides us; for instance, functional paralysis frequently follows an emotional shock or a prolonged mental strain, whereas traumatism, as in railway accidents, is equally liable to cause functional or organic disease.

There are two classes of signs and symptoms which point to functional rather than to organic disease—firstly, the absence of characteristic signs of organic disease, and secondly, the presence of certain phenomena peculiar to functional disease. Muscular atrophy, while much less frequent in functional than in organic palsies, is not pathognomonic of organic disease. Thus Fig. 216 (p. 387) shows a case of hysterical monoplegia with extensive muscular atrophy,

a rare combination. But the electrical reactions of degeneration are never obtained in functional paralysis. Their presence signifies undoubted organic disease somewhere in the spino-muscular neurone. Paralysis of a single muscle is pathognomonic of organic disease; it never occurs in functional paralysis, which affects whole muscle-groups or, to speak more accurately, whole movements. To sum up, then, the diagnosis between functional and organic paralysis is easy if the organic palsy is of the lower motor neurone type. It is chiefly when the organic lesion is in the upper or cortico-spinal neurone that difficulty is liable to occur, *i.e.* in cases in which there is little or no muscular atrophy, and where the electrical reactions are normal. In such cases the presence or absence of other hysterical phenomena is of great value.

A valuable sign of organic as contrasted with hysterical hemiplegia is Babinski's *combined flexion of the hip and trunk*, a phenomenon almost invariably present in organic cases. To elicit this the patient lies flat on his back on a smooth hard surface, such as a table or the floor, with his arms crossed in front of his chest and the legs not allowed to touch each other. We then ask him to sit up without using his arms (see Fig. 93). As he does so, the organically paralysed lower limb becomes flexed at the hip and the heel is raised from the surface. The toes of the hemiplegic foot becomes spread out in fan-like fashion. Meanwhile the shoulder on the healthy side is carried forwards, as if to counterpoise the contra-lateral lower limb. In hysterical hemiplegia this sign is absent, and the hysterically paralysed limb remains unraised. Another useful test to distinguish between organic and functional paralysis is the *phenomenon of Grasset and Gaussel*,[1] which is also confined to organic cases. This consists in inability on the part of the organically hemiplegic patient to raise *both* lower limbs simultaneously from the surface when lying down as before, although he is still able to lift either lower limb separately. The reason for this peculiarity is that in organic hemiplegia the patient, when he tries to lift both lower limbs at once, is unable to fix the pelvis. In testing for this sign, we must be careful to see that the two legs do not touch each other, since the patient often tends involuntarily to help up the paralysed limb by means of the sound one. Of course, the sign is only present in cases of incomplete hemiplegia. Another way of showing the same phenomenon is to direct the patient to raise the lower limb of the paralysed side and hold it in the air. If we now grasp the sound leg and raise it up, the other limb at once falls down again, because the pelvis cannot be steadied by the muscles on the paralysed side. On the other hand, if the patient first raises the sound leg and we then passively lift the

[1] *Revue neurologique*, 1905, p. 881.

paralysed one, the sound limb still remains in the air, the pelvis remaining fixed by the non-paralysed muscles of the healthy side. In hysteria there is no such difference between the separate and the simultaneous raising of the legs.

In some cases of spastic paraplegia the rigidity of the lower limbs is of diagnostic value. Thus when we passively lift one lower limb off the bed and find that the other lower limb is thereby lifted up as well, we may be practically certain that the rigidity and paralysis are organic and not functional.

A careful study of the reflexes is also of the utmost importance. The presence of an extensor plantar reflex in a patient beyond the age of infancy is pathognomonic of organic disease (see later, p. 316). The deep reflexes, although they may be exaggerated both in functional

FIG. 93.—Case of left hemiplegia, showing phenomenon of *combined flexion of hip and trunk* on attempting to sit up without using arms. (Photo by D. Hildred Carlill.)

and in organic paralysis, are usually normal in functional cases. True ankle-clonus of organic disease is generally readily distinguished from the "pseudo-clonus" of functional disease. Absence of the deep reflexes may occur in organic, never in functional disease.

Incontinence of the bladder and rectum is not uncommon in organic diseases of the spinal cord and brain, but practically never occurs in functional paraplegia.

Where is the Organic Lesion?—Suppose we have come to the conclusion that the patient's motor paralysis is organic in type, we have to ask ourselves at what point in the motor path the lesion is situated. First, we must decide whether the lesion is in the upper (cortico-spinal), or in the lower (nucleo-muscular) motor neurone. The distinctive characters of these two types are as follows:—

ORGANIC MOTOR PARALYSIS.

Upper (cortico-spinal) Neurone. Supra-Nuclear Paralysis.	Lower (spino-muscular) Neurone. Nuclear and Infra-Nuclear Paralysis.
1. Diffuse muscle-groups affected, never individual muscles.	1. Individual muscles may be affected.
2. Spasticity and hyper-tonicity of paralysed muscles.	2. Flaccidity and atonicity of paralysed muscles.
3. May have superadded "associated movements" (synkinesiæ) on attempted voluntary movement.	3. No "associated movements."
4. No muscular atrophy, except from disuse.	4. Atrophy of paralysed muscles.
5. Electrical reactions normal.	5. Reactions of degeneration.
6. Deep reflexes in paralysed limbs present, and usually increased.	6. Deep reflexes of paralysed muscles diminished, and often absent.
7. If foot affected, plantar reflex extensor in type.	7. Plantar reflex, if present, is of normal flexor type (unless flexors of toes are themselves paralysed).

Let us consider some of these points more in detail. Paralysis due to an upper neurone lesion never affects an individual muscle, but always a diffuse muscular group. The converse, however, is not true, and we must remember that even a lower neurone lesion may produce a diffuse paralysis, where a series of adjacent nerves or nuclei are affected. But if individual muscles are picked out by paralysis, the adjoining or intermingled muscles being perfectly normal, the cause is certainly a nuclear or infra-nuclear lesion.

Paralysis from a cortico-spinal lesion is rarely permanently complete. It is more often a paresis than an absolute paralysis. In this respect it differs from the total palsy of a spino-muscular lesion.

Spasticity of the paralysed muscles in supra-nuclear lesions does not set in immediately after the onset of a sudden lesion, but usually develops gradually in the course of from one to three months. Thus in a typical supra-nuclear lesion, as, for example, in apoplexy, there is an initial period of flaccidity, gradually replaced by the so-called "late rigidity." The degree of this spasticity varies in different cases. We estimate it by moving the patient's joints passively, and comparing their resistance with that of a healthy limb.

Patients with motor paresis due to cortico-spinal lesions not uncommonly show superadded **"associated movements"** or **synkinesiæ** on attempting to execute a voluntary movement with the paresed limb (see p. 87). These associated movements are probably carried out by means of the extra-pyramidal and strio-spinal motor system (p. 12). Thus, for example, if the patient tries to draw up his hemiplegic leg, he cannot do so without at the same time dorsiflexing the ankle involuntarily. This is the so-called "*tibialis phenomenon*" of Strümpell. Similarly in the upper limb we may note an analogous "pronation

phenomenon," consisting of an involuntary pronation on attempting to flex the elbow. This can also be demonstrated by telling the patient to relax both upper limbs completely, so that they become flaccid and inert. The two forearms are then supported, palms upwards, on the observer's hands, and are tossed upwards several times in succession. In organic hemiplegia the paralysed hand turns whilst in the air, so as to face inwards and downwards, whereas the normal hand falls in its original supinated position. This is sometimes a useful sign in the diagnosis between hysterical and organic hemiplegia.[1]

Some cases of organic hemiparesis are associated with *tonic innervation* of the paresed limbs.[2] This phenomenon is usually best marked in the upper limb. It is shown by an inability to relax the muscles after a voluntary movement, exactly similar to the tonic spasm of myotonia congenita (see p. 245). The phenomenon of tonic innervation disappears if the paralysis becomes more profound and does not occur in complete hemiplegia: it apparently demands a relative integrity of the cortico-spinal motor path.

With an upper neurone lesion, in the vast majority of cases the muscles of the paralysed limb undergo no appreciable atrophy, save perhaps to a very slight degree from disuse. But there are occasional exceptions to this rule, as in some cases of hemiplegia which are associated with muscular atrophy, chiefly in the region of the shoulder or in the intrinsic muscles of the hand. Such atrophies are often (but not always) secondary to arthritic changes in the joints. But however intense the amyotrophy of hemiplegia may be, the electrical reactions of degeneration are never present. Degenerative reactions (commonly referred to as " R.D.") are pathognomonic of a nuclear or infra-nuclear lesion. Not that R.D. are necessarily present in every lower neurone lesion; for a slight lesion of a nerve-trunk may produce muscular palsy without R.D., and in many nuclear lesions, for example in progressive muscular atrophy, the reactions in the affected muscles are mixed, owing to the fact that degenerated and healthy muscle-fibres are intermingled in the same muscle, the former giving R.D., the latter being normal in reaction. Again, in the motor weakness occurring in the different varieties of myopathy, there is simple diminution both to faradism and galvanism, but no true R.D., even in the most advanced cases. The reflexes in upper and lower neurone lesions will be dealt with more fully in a later chapter (p. 312).

With reference to the differential diagnosis between an upper and a lower neurone lesion, it will be observed that no single sign of the six we have mentioned is pathognomonic, yet the sum of the

[1] Babinski, *Semaine médicale*, 1909, xxix. 3.
[2] Wilson and Walshe, *Brain*, 1914, vol. xxxvii., p. 109.

various points usually enables us without difficulty to settle with which of the two neurones we have to deal. Sometimes there is a combined lesion of upper and lower neurones, as in a transverse myelitis or a myelomalacia. Here the phenomena at the level of the lesion will be of a flaccid, lower neurone type, due to destruction of the anterior cornua and anterior roots, whilst below that level there is a spastic paraplegia of cortico-spinal type, from interruption of the pyramidal tracts.

Motor Palsies of Upper Neurone Type.—The signs and symptoms vary according to the level at which the cortico-spinal tract is damaged. The following are the chief sites at which a lesion may occur, and the diagnostic signs corresponding to each (see Fig. 6, p. 6).

A **cortical** lesion in the pre-central convolution is often localised to a single limb, and is more likely to produce a monoplegia than a hemiplegia, since only a very extensive cortical lesion would produce a complete hemiplegia, affecting face, arm and leg. What we usually find is either a pure monoplegia—crural, brachial, or facio-lingual, or, if the lesion be somewhat larger, an associated monoplegia—brachio-crural, or facio-brachial. Cortical motor paralysis is commonly associated with local epileptiform attacks of the paralysed limb, because disease may irritate the cortex in addition to paralysing it. The monoplegic limb frequently shows a cortical type of anæsthesia, which, as we have already seen, is slight in degree, more marked at the periphery of the limb, and often transient in character.

A strictly localised **subcortical** lesion is often indistinguishable from a cortical one, save by the absence of irritative epileptiform phenomena; and in many cases the lesion is both cortical and subcortical.

A lesion in the motor path at the level of the **internal capsule,** inasmuch as all the pyramidal fibres have by this time converged to form a compact strand, produces no longer a monoplegia, but a complete hemiplegia, affecting face, arm and leg. There are no Jacksonian convulsions as in a cortical lesion. If the capsular lesion extends backwards from the motor into the sensory tract, or into the optic thalamus, there may be a coexistent hemi-anæsthesia, but this is not common.

A **thalamic** lesion is sometimes associated with hemi-athetosis of the hemiplegic side; this athetosis does not appear immediately after the attack of apoplexy, but develops gradually in the course of many weeks. A still more extensive lesion, extending backwards along the capsule from the motor-tract, through the sensory path and into the optic radiations, will cause hemiplegia, hemianæsthesia and hemianopia.

In rare cases we may have an *ipso-lateral hemiplegia* in which, for example, a lesion of the left cerebral hemisphere, *e.g.* a tumour, abscess,

or hæmorrhage, produces a left-sided hemiplegia. Some of these cases, according to Marie, are due to congenital non-decussation of the pyramids; this must be very rare. More often the symptoms are due to compression of the opposite cerebral hemisphere. Owing to the anatomical configuration of the falx cerebri, which normally tends to prevent any gross lateral displacement of the hemispheres, the maximum pressure exercised by the original lesion (which may be in the frontal, temporal, parietal, or any part of the hemisphere, "silent" or otherwise) falls mainly upon the region of the opposite internal capsule and central nuclei. Later still, the opposite cerebral cortex

FIG. 94.—Lesion of *left* crus cerebri—"Weber's syndrome." Patient is looking upwards and attempting to show the teeth on both sides. There is dilatation of the *left* pupil, and paralysis of the *left* superior rectus, together with hemiplegia of the *right* face, arm and leg.

becomes compressed against the cranial vault.[1] From the surgical point of view, we must also bear in mind the occasional occurrence of an ipso-lateral hemiplegia when a blow on one side of the head, say the left, is followed by a left-sided hemiplegia. Such cases are generally due to injury of the opposite (*i.e.* the right) hemisphere by "contre-coup."

A lesion in the **crus cerebri** is recognised by the coexistence of third nerve palsy on one side, with hemiplegia of the opposite face, arm and leg, usually most marked in the face. This variety of alternate paralysis is known as *Weber's syndrome* (see Fig. 94). The third nerve

[1] Demole, *Revue neurologique*, 1918, p. 100.

palsy is often incomplete. When the lesion extends into the tegmentum and implicates the neighbourhood of the **red nucleus,** it may produce a unilateral tremor or a hemiataxy of the hemiplegic side, combined, as before, with a third nerve affection on the side of the brain lesion; this combination is known as *Benedikt's syndrome.* If the lesion extends outwards so as to implicate the optic tract as it winds round the outer side of the crus, there may be superadded a hemianopia.

As we come downwards along the pyramidal tract into the **pons and medulla,** the type of hemiplegia changes; there is no longer third nerve palsy, but on reaching the level of the facial nerve, another variety of alternate hemiplegia appears. This consists of facial palsy, peripheral in type, on the side of the lesion, together with hemiplegia of the arm and leg on the opposite side, the so-called *Millard-Gubler syndrome.* Other cranial nerves on the side of the pontine or bulbar lesion, for example, the trigeminal, the sixth, or the hypoglossal, may be affected together with the pyramidal tract. Paralysis of these, as in the Millard-Gubler syndrome, may coexist with hemiplegia of the opposite arm and leg, but such cases are rare. As they descend through the medulla the pyramidal tracts of opposite sides converge, and eventually lie so close together that at this level a strictly unilateral lesion seldom occurs, there being, as a rule, damage to both pyramidal tracts, affecting the limbs of both sides, though perhaps in unequal degree. And together with this, there are "bulbar" symptoms—disorders of articulation, phonation, or deglutition, from implication of the tenth, eleventh and twelfth cranial nerves or nuclei.

The diagnosis of motor paralysis due to lesions of the pyramidal tract within the **spinal cord** depends on the level of the lesion. The two pyramidal tracts decussate at the lower end of the medulla oblongata, so that a unilateral lesion of the spinal cord produces an ipso-lateral instead of a contra-lateral motor paralysis. If the lesion be in the cervical region, the arm and leg on the corresponding side will be affected; but if it be situated below the cervical enlargement, the leg on the side of the lesion suffers alone. A primary unilateral lesion of the cord generally interrupts not only motor, but sensory paths, and produces the well-known Brown-Séquard paralysis, to which reference has already been made.

Bilateral motor paralysis of upper neurone type is due to bilateral lesions, which may be situated either in the brain or in the spinal cord. When both pyramidal tracts are affected within the brain (and the commonest cause is a double focus of softening in the region of the posterior part of the lenticular nucleus, although less commonly the lesions are cortical or subcortical) a double hemiplegia is the result. In

these cases of double hemiplegia or diplegia there are, besides the signs of hemiplegia on both sides (frequently unequal in degree), what are known as "pseudo-bulbar" phenomena. In pseudo-bulbar paralysis, the symptoms of which we have already studied (p. 111), it is uncommon for the two attacks of hemiplegia to occur simultaneously on the two sides; they more usually occur successively, and it is only after the hemiplegia has become bilateral that the pseudo-bulbar symptoms appear. Such patients are generally excessively emotional, tending on slight provocation to laugh or, more frequently, to weep with a peculiar "spastic" wail, and an unnatural slowness of expressional movement.

Bilateral pyramidal lesions within the spinal cord produce paraplegia, affecting all four limbs if the lesion be above the cervical enlargement, but affecting the lower limbs alone if the lesion be below the cervical region; it is commonly of the ordinary spastic type, with increased deep reflexes. If the sensory tracts be interrupted by the same lesion as that which has affected the motor tracts, we have superadded an anæsthesia the upper limit of which corresponds to that of the highest affected segment. Such bilateral, combined, sensory and motor paralysis is usually accompanied by loss of control of the sphincters. (So long as a spinal cord lesion remains unilateral, we do not, as a rule, have sphincter trouble.) If the cord lesion be sufficiently extensive to implicate the anterior cornua, there will be muscular atrophy, localised to the segment affected, *i.e.* at the upper boundary of the spastic paraplegia. But it is important to remember that if the lesion of the cord be one which *completely* divides it (*e.g.* a stab or bullet-wound), so that there is no connection between the cord-segments above and below the lesion, the paraplegia is then flaccid in type and the deep reflexes, at first, are absent in the paralysed limbs. The plantar reflexes during the initial stage are of flexor type. If the patient survives, they may, after a few weeks, assume the extensor type. Vasomotor paralysis in the paraplegic limbs may cause the feet to be abnormally hot to the touch.

The differential diagnosis between tumours arising within the spinal cord and those growing from without is sometimes difficult. In **extra-medullary tumours,** arising from the nerve-roots or meninges on the posterior aspect of the cord, root-pains, unilateral or bilateral, usually precede the gradually progressive signs of a transverse lesion, more or less complete, of the cord. In intra-medullary tumours, root symptoms are absent, and trophic changes in the joints, bones, and skin are more common (see p. 306, Syringomyelia). An extra-medullary tumour situated laterally sometimes compresses the cord so as to produce an incomplete Brown-Séquard syndrome.

Thus in one of my own cases, in which an endothelioma was removed from the first thoracic root on the right side, the patient, in addition to root-pains along the inner border of the right upper limb, had asymmetrical spastic paraplegia, more marked in the right leg, together with impairment of thermal and pain sense in the left leg and left side of the trunk.

But if the extra-medullary growth starts in front of the cord, root-pains are absent or late. If the anterior roots be involved, muscular atrophy of root distribution is a valuable focal sign, and owing to the oblique direction of the nerve roots,such radicular atrophy is only seen above the level of the pyramidal symptoms. In cases of intra-medullary lesion, on the other hand, in which muscular atrophy is due to destruction of anterior cornua, the muscular atrophy corresponds in level to the maximum point of the lesion, and pyramidal symptoms (notably the reflexes of spinal automatism) may be present above the level of the muscular atrophy. Spontaneous reflex spasms of the lower limbs are commoner in extra-medullary than in intra-medullary growths. Both extra- and intra-medullary growths are often associated with an excess of globulin in the cerebro-spinal fluid and with xanthochromia (see p. 419).

The tendency is to localise a spinal tumour below its actual level. Sometimes valuable indications are provided by studying the vibration sense of the vertebral spines, for such sensibility is often lost up to the upper level of the growth.

Occasionally a diagnosis of extra-medullary tumour is made, whereas operation or autopsy shows the condition to be one, not of tumour, but of *circumscribed* subacute or chronic *lepto-meningitis*. This mistake may sometimes be avoided by studying the exact distribution of the initial root-pain. In tumour this pain is localised to a single root at the start; in meningitis the pain is more diffuse, affecting a considerable number of root-areas.

Often the lesion is not horizontal, but higher on one side than the other, and then the upper limit of the anæsthesia will be correspondingly uneven on the two sides, and the distribution of muscular atrophy from anterior cornual destruction correspondingly asymmetrical.

Another point which sometimes helps us to recognise the upper limit of a spinal cord lesion is by studying the skin-area of inhibition of knee- or ankle-clonus (see p. 324). To observe this, we first ask a skilled assistant to elicit the clonus; once started, this is sustained indefinitely, so long as the requisite tension of the muscles is maintained. Whilst the clonus is going on, we now energetically stimulate the skin of the lower limb or lower part of the trunk, *e.g.* by pinching; the clonus at once becomes arrested. This inhibition only occurs on stimulation of the skin-areas below the upper level of the cord lesion;

stimulation of the skin-areas above the level of the lesion produces no inhibition of clonus.

Occasionally a spinal tumour has a considerable vertical length, extending through several segments of the spinal cord. The lower limit of such a growth is more difficult to determine than its upper boundary. We can sometimes obtain valuable information by a study of certain **reflexes of spinal automatism,** which are often present in organic pyramidal lesions, but do not occur in hysterical paralysis.

These are analogous to phenomena demonstrated by Sherrington[1] in the dog whose brain-stem has been divided, whether in the upper cervical region (spinal dog) or at the level of the mid-brain (decerebrate dog), and described by him as the flexion-reflex, crossed extension reflex, "mark-time" reflex, etc.

In the human subject with organic pyramidal disease, *e.g.* in spinal cord lesions, the most constant reflex of spinal automatism is a movement of flexion or shortening of the lower limb at all joints, including flexion of the hip and knee, with dorsiflexion of the ankle and toes, especially the hallux: *phénomène des raccourcisseurs.* For this phenomenon Babinski[2] proposed the attractive title of "defensive reflex," but as Strohl[3] has pointed out, Marie's[4] term of "*reflex of spinal automatism*" is preferable. The phenomenon is elicited by stimulating the skin of the lower limb or lower part of the trunk (by pinching, pricking, scratching, localised heat or cold, faradism, etc.) and also by stimulation of deeper structures (*e.g.* by passive flexion of the toes, by deep painless stroking of the sole, especially along its outer half, or by firm lateral compression of the foot). The reflex movement of the stimulated limb does not always "defend" it by withdrawing it from the stimulus; on the contrary, it may sometimes bring it nearer (*e.g.* when the stimulus is on the dorsum of the foot or at the back of the calf). The *extensor plantar reflex* of pyramidal disease (see p. 315) is an intregral part of this larger flexion-reflex. Sometimes both lower limbs, and not merely one, become flexed. These flexion movements occur, apparently spontaneously, in the well-known "flexor spasms" seen in certain cases of paraplegia.

In cases of spastic paralysis with extensor rigidity, in addition to flexion of the lower limb thus stimulated, we also produce a simultaneous extension of the opposite lower limb, "*phénoméne d'allongement croisé,*" in which there is extension of the hip and knee, with plantar flexion of the ankle and toes. This phenomenon may also occur in hemiplegia on stimulating the sole of the non-paralysed foot.[5]

1 Sherrington, *Journal of Physiology,* 1910, xl., p. 23.
2 Babinski and Jarkowski, *Revue neurologique,* 1910, p. 666.
3 Strohl, *Presse médicale,* March 11, 1914, p. 195.
4 Marie and Foix, *Semaine médicale,* Oct. 22, 1913, p. 505.
5 Walshe, *Brain,* 1914, vol. xxxvii., pp. 269–336.

The cutaneous area from which these reflexes of spinal automatism can be elicited varies in extent in different cases, the sole of the foot being the most constant reflexogenous area. The upper level of the trunk, up to which they can be evoked by cutaneous stimulation, indicates the lower level of the lesion which is compressing the cord. In any individual case the skin of the trunk should be explored on repeated occasions, both from above downwards and from below upwards, noting the level at which the cutaneous reflexes of spinal automatism appear or disappear. There is one particular fallacy which we must be careful to avoid, viz. that a stimulus above the level in question, especially if it be a painful one, may produce a voluntary movement of the upper part of the body, which by dragging on the passive lower limbs may evoke a false reflex, thus leading us to locate the lower level of the lesion too high up.

Intra-thecal growths have, as a rule, a relatively short vertical extent, and they rarely compress more than one or two segments of the cord. On the other hand, extra-thecal growths, by the time they produce compression of the cord, are usually of considerable length. This maxim also applies to hypertrophic pachymeningitis and to the pachymeningitis associated with spinal caries. Therefore, in a case of compression paraplegia, in which the reflexes of spinal automatism are well marked, and in which the difference in level is considerable between the upper limit of the anæsthesia and that of the cutaneous reflexes of spinal automatism, we have probably to deal with an extra-thecal tumour, or with a pachymeningitis. If, on the other hand, the two levels practically coincide, we incline to diagnose an intra-thecal growth.

We also meet with cases of bilateral spastic paraplegia without any affection of sensation. Such cases may be examples of slowly progressive primary lateral sclerosis, a rare disease, or what is more usual, of amyotrophic lateral sclerosis, in which the signs of a progressive muscular atrophy are superadded to rigidity of the lower limbs with increased deep reflexes. A pure motor paraplegia is more frequently due to disseminated sclerosis, to an imperfectly recovered transverse myelitis, or to some other vascular lesion, such as thrombosis or hæmorrhage, at a stage in which the sensory functions have become restored, whereas the motor tracts remain permanently sclerosed. The history of the case is sufficient to distinguish between these diseases.

Syringomyelia, when it affects the pyramidal tracts, may also produce a spastic type of paraplegia; but it is readily recognised by the characteristic dissociated anæsthesia, to which we have already referred (p. 198), and by the frequent coexistence of atrophic changes in the bones, joints and muscles, and muscular atrophy when the anterior cornua are implicated in the gliomatous process.

CHAPTER XIV

ORGANIC MOTOR PARALYSIS OF LOWER NEURONE TYPE

Motor Palsies of Lower Neurone Type.—Here, as in upper neurone lesions, the signs and symptoms differ according to the level at which the spino-muscular neurone is diseased. The most important diagnostic fact, for localising purposes, is the presence or absence of sensory phenomena. If, in a lower neurone motor palsy, sensory changes are present, we have to do with a lesion of a mixed nerve, that is, of a nerve containing sensory as well as motor fibres. If, on the other hand, sensory changes are absent throughout the course of the disease, the spino-muscular neurone is probably affected, either before it is joined by the sensory fibres (*i.e.* the lesion is in the anterior cornu or anterior nerve-root), or after it has parted company with them (*i.e.* the lesion is in a purely motor nerve-branch or in the muscle itself).

A lesion of the *anterior cornu* within the cord (as of its homologue in the motor nuclei of the bulb) is unassociated with any sensory paralysis, and therefore produces a pure motor palsy of the corresponding muscle fibres. A lesion of the *anterior nerve-root*, emerging from the anterior cornu, produces identical signs, and is often indistinguishable from an intra-spinal nuclear lesion. In nuclear or anterior root lesions, therefore, we find pure motor palsy, of lower neurone type, unassociated with any sensory change. The commonest examples of such lesions are chronic anterior poliomyelitis (progressive muscular atrophy) and certain types of lead paralysis. Acute anterior poliomyelitis (infantile paralysis of spinal type) in the early days or weeks of the disease is frequently associated with pain and tenderness of the limbs. As the malady subsides into the chronic stage, the pain and tenderness pass off. Landry's paralysis is a pure motor paralysis of the whole spino-muscular neurone, to which we shall refer presently. A nuclear or anterior root lesion is further characterised by the "root" distribution of the motor paralysis, so that in this respect it differs from the paralysis due to a lesion of a peripheral nerve (see Tables of Root Distribution, p. 35). Lesions of peripheral mixed nerves are always associated, at the onset at least, with sensory changes. In the case of lesions of peripheral purely motor nerves (*e.g.* the nerve of

Bell to the serratus magnus), the distribution of the motor palsy is totally unlike that of a nuclear or anterior root lesion.

To distinguish between a nuclear and an anterior root lesion is sometimes difficult, and may in some instances be impossible. The coexistence of spastic phenomena corresponding to lower parts of the cord points to an intra-spinal lesion, and indicates a coexisting lesion of the adjacent pyramidal tract. Total escape of the pyramidal tract, on the other hand, would suggest an anterior root lesion, though not necessarily so, seeing that acute anterior poliomyelitis does not affect the pyramidal tract. Another point which may sometimes help us is the subsequent course of the disease; if the paralysed muscles recover, this is in favour of an extra-medullary anterior root lesion rather than an affection of the anterior cornu, inasmuch as regeneration of nerve-fibres only occurs in extra-spinal lesions, an intra-spinal lesion of the grey matter being irreparable.

FIG. 95. — Old acute anterior polio-myelitis, with atrophy of deltoid and biceps, and deficient growth of the humerus on the left side.

A pure anterior cornual lesion, with its absence of cutaneous anæsthesia, can only be confounded with a lesion either in a purely motor nerve, or with one in the muscle-fibres themselves. The history of the onset of the disease is of great importance, so also is the exact distribution of the muscular paralysis. The two chief diseases specially affecting the anterior cornua are infantile paralysis and progressive muscular atrophy.

Acute anterior polio-myelitis, or infantile spinal paralysis (Heine-Medin disease), is an acute infective disease in which paralysis is but an incidental occurrence. It is due to a minute, filterable micro-organism which may attack the nervous system, and which enters the tissues via the nasal and intestinal mucosa. Although no age confers immunity, children are much oftener attacked than adults. After an incubation period of six or eight days, during which there are no symptoms, there is an acute onset, usually febrile. The fever reaches its maximum about the third day, and it is generally at this stage that evidences of muscular paralysis are made out. Even before the onset of paralysis the blood shows a leucocytosis, and if we examine

the cerebro-spinal fluid at this stage we note the presence of pleocytosis and of globulin (see later, p. 424). The organism, whilst causing congestion of various organs, including the spleen and lymphatic glands, together with multiple necrotic lesions of the liver, is neurotropic, *i.e.* it has a specially intense effect upon the central nervous system and its meninges, and may attack any part of the grey matter. Most commonly its main incidence falls upon the spinal cord, where it produces a special perivascular infiltration around the anterior spinal arteries which supply the anterior horns. The spinal meninges being also hyperæmic, there are pains in the limbs, aggravated by passive movement. One attack of the disease almost always confers immunity, owing to the formation of immunity-bodies in the blood. When the anterior horns are attacked, as is commonly the case, a large number of muscles, sometimes in all four limbs, may originally be paralysed. But in a week or two most of the paralysis clears up, leaving a residuum, almost always unilateral, of paralysed muscles which undergo rapid wasting. There is no exaggeration of tendon reflexes below the level of the lesion, since the pyramidal tract is unaffected. The lower limb is more frequently affected than the upper. Figs. 95, 96, and 97 are examples of cases of old infantile paralysis, showing the extreme degree of atrophy which results, and if the disease occurs in childhood, as is most often the case, the subsequent want of growth in the limb. The wasted limb is often cold and blue, its local arterial pressure is diminished, and the patient can frequently tolerate, without pain, faradic stimulation of a strength which is intolerable in the sound limbs.

FIG. 96.—Old infantile paralysis with total loss of deltoid and biceps. Shows action of the supinator longus in flexing the elbow.

Chronic anterior polio-myelitis, or progressive muscular atrophy, has a gradual, insidious onset. It occurs almost always in adults and, though beginning unilaterally, generally becomes bilateral. It usually shows itself first in the small intrinsic muscles of the hands (Aran-Duchenne type, see Fig. 98); more rarely it begins in the shoulder muscles. In this disease we observe fibrillary worm-like tremors in the wasting muscles, with electrical reactions which are a mixture of R.D.

with healthy reactions. This is because here and there in the diseased area a healthy anterior cornual cell survives, together with its corresponding healthy muscle-fibre. If the adjacent pyramidal tracts be sclerosed, we have **amyotrophic lateral sclerosis**, in which the deep reflexes are exaggerated and the plantar reflexes extensor in type.

Neither in chronic anterior poliomyelitis nor in amyotrophic lateral sclerosis do we meet with any sensory changes. Sensibility to pain and to temperature should always be carefully tested in such cases, so

FIG. 97.—Old infantile paralysis (acute anterior polio-myelitis). Paralysis and atrophy of all the muscles below the elbow, with exception of supinator longus.

FIG. 98.—Progressive muscular atrophy in a man aged 32. The patient was also tabetic.

as not to overlook the early stage of a **syringo-myelia** in which the gliomatous affection tends to implicate not only the posterior, but also the anterior cornua.

There is a rare infantile variety of progressive muscular atrophy—*Werdnig-Hoffmann* type—due to degeneration of the anterior cornua. The disease begins in infancy, often during the first few months after birth. The muscles of the lower limbs are first attacked, and exhibit weakness, wasting and fibrillary tremors, though the atrophy and fibrillation may be masked by subcutaneous fat. The knee-jerks disappear and the atrophied muscles gradually lose their electrical excitability. This disease, which may affect several members of a

family, gradually spreads upwards to the medulla, and is fatal, with bulbar symptoms, in from one to six years.

There is another peculiar form of muscular atrophy which is hereditary and runs in families, known from its distribution as Tooth's "peroneal" type, or as the progressive neurotic amyotrophy of Charcot and Marie. It comes on in childhood, commencing in the distal muscles of the limbs, more often the lower limbs and the peroneal muscles, and

FIG. 99. FIG. 99A

FIGS. 99 AND 99A.—Peroneal type of muscular atrophy (Charcot-Marie-Tooth). In spite of total paralysis below the knees, the patient is still able to stand and walk.

gradually producing weakness with contractures. The electrical reactions in the affected muscles are diminished, but without other change. Talipes equino-varus appears, for which tenotomy is often done, as was the case in the patient shown in Fig. 99. But if the patient's feet be passively supported, say by metal supports at the ankles, until the paralysis of the limbs has become complete (as in the patient shown in Fig. 100), talipes does not appear even in the totally paralysed limb. Later, the intrinsic muscles of the hands undergo wasting (Fig. 100). In fact, early claw-foot and claw-hand in young people are almost

pathognomonic. (The only other disease of diagnostic importance in this connection is progressive hypertrophic neuritis.) The disease hardly ever extends to the muscles of the hips or shoulders. The facial and trunk muscles also escape. It is interesting to note that even when all the muscles below the knees are paralysed, the patient may still be able to walk alone, although the gait is high-stepping from drop-foot. This was so in both the patients here figured. The deep reflexes are lost in the atrophied muscles.

Fig. 100.—Peroneal type of muscular atrophy (Charcot-Marie - Tooth). Showing atrophy of intrinsic muscles of hands.

Thus in the little boy (Fig. 99) the ankle-jerks were lost, whereas the knee-jerks remained brisk, since the thigh muscles were unaffected; in the girl (Fig. 100) both the knee-jerks and ankle-jerks were lost.

Pathologically the disease is associated with atrophy of the anterior cornual cells, whilst the anterior nerve-roots are said to be healthy.[1] But there is marked degeneration in the intra-muscular nerve-fibres of the affected muscles. There is also a curious degeneration in the posterior columns, closely resembling that of tabes dorsalis.

Progressive hypertrophic neuritis is another family disease which begins in childhood or adolescence. In this disease, besides a flaccid muscular atrophy of the limbs, commencing peripherally and less intense in the proximal muscles, and tending to produce pes cavus and claw-hand, there are marked sensory changes, resembling those of tabes, *i.e.* shooting pains, anæsthesia, analgesia (especially at the periphery of the limb), loss of joint-sense, etc. The affected muscles show reactions of degeneration. There is marked ataxia of the limbs together with loss of the deep reflexes, kypho-scoliosis, and Argyll-Robertson pupils. In some cases exophthalmos has been observed.[2] Pathologically we find a sclerotic thickening of the peripheral nerve-trunks, extreme in degree, often palpable during life, or even visible if the patient be thin. There is also a degeneration of the posterior

[1] Dejerine and Armand-Delille, *Revue neurologique*, 1903, p. 1198.
[2] Boveri, *La semaine médicale*, March 30, 1910, p. 145.

columns, somewhat like that of tabes dorsalis. The muscles show atrophy, proliferation of sarcolemma nuclei, and fatty infiltration.

A lesion of a **spinal nerve** after the union of its anterior with its posterior root, but above the point where it divides into branches to form plexuses or individual nerves, is characterised by a combination of motor and sensory paralysis, the distribution of which is not according to peripheral nerves, but according to root-areas, motor and sensory (see Tables of Muscular Localisation, p. 35, also Fig. 25, p. 33).

Thus, for example, Fig. 101 is the photograph of a sailor who received a violent blow on the right side of his neck from an iron winch. This produced paralysis of the deltoid, supra- and infra-spinatus, biceps, brachialis anticus, and supinatores longus and brevis, together with an area of cutaneous anæsthesia along the outer side of the whole upper limb, from the shoulder to the hand. All this would be difficult of explanation on the theory of multiple injuries to the numerous peripheral nerves which supply these various parts. But the motor distribution is that of the fifth cervical root, whilst the anæsthesia of the hand corresponds to the fifth and a small part of the sixth root, and as a matter of fact this lesion was subsequently verified by operation.

FIG. 101.—Case of rupture of C_5 root in a sailor aged 29. There are atrophy and paralysis of deltoid, supra- and infra-spinatus, biceps, brachialis anticus, and supinatores longus and brevis, together with anæsthesia along the outer side of the limb, from the neck to the thumb and index finger (in the area indicated by black line). The figure shows the atrophy of the deltoid, with downward displacement of the limb at the shoulder-joint.

Lesions of **peripheral mixed nerves,** when complete, are usually easy of diagnosis, inasmuch as there are paralysis and atrophy of all the muscles supplied by the particular nerve, together with anæsthesia in the area of its cutaneous distribution.

It is unnecessary to discuss the signs of paralysis of all the various mixed nerves. The question is one of anatomy. Let us select one or two illustrative examples.

Ulnar paralysis affects certain muscles of the hand and forearm, of which the most important diagnostically are the lumbricales, which flex the proximal phalanx, and the interossei, which extend the two

distal phalanges, of each digit. This is specially marked in the two ulnar fingers, whose lumbricales are innervated by the ulnar nerve.

One of the most constant signs of ulnar palsy is the thumb-sign,[1] shown by the abnormal attitude of the thumb during the act of prehension. To demonstrate this, we hand the patient some thin object, *e.g.* a sheet of paper, and ask him to grasp it firmly, first with the healthy hand and then with the paralysed hand. On the normal side the whole length of the thumb is in contact with the paper, compressing it against the index finger, the terminal phalanx of the thumb being

FIG. 102. FIG. 102A.

FIGS 102 AND 102A.—Left-sided ulnar paralysis, from a bullet-injury of the nerve behind the internal condyle of the humerus. The area within the black line is anæsthetic.

meanwhile extended, or perhaps a little flexed. On the paralysed side, however, only the pulp of the thumb-tip presses the paper against the index, whilst the terminal phalanx of the thumb is markedly flexed and there is an empty space between it and the index finger (see Fig. 104).

Anæsthesia of one and a half fingers and of the corresponding part of the hand is also present (see Figs. 102 and 102A). In old-standing cases, the unopposed common extensor of the fingers undergoes contracture and produces a claw-hand, this being most evident in the two ulnar fingers. The hypothenar eminence also becomes flattened and the palm hollowed, so that the flexor tendons become visible beneath the skin.

Paralysis of the *anterior crural nerve* is a much rarer affection (see

[1] Froment, *Presse médicale*, 1915, Oct. 21.

Fig. 103). From paralysis of the quadriceps extensor the patient is unable to extend the knee on the affected side, and the quadriceps

Fig. 103.—Paralysis of *left anterior crural nerve* (from spontaneous hæmorrhage in a case of hæmophilia), showing atrophy and paralysis of quadriceps extensor. The black line indicates the limit of the anæsthesia on the outer aspect of the limb. On the inner side of the limb it extended down to the internal malleolus.

undergoes atrophy. In standing erect and in walking the knee tends to give way, and the patient is liable to trip over small objects. There is special difficulty in going up and down stairs, the patient taking

Fig. 104.—*Left-sided* ulnar paralysis: Froment's sign.

two strides on each step, instead of the normal alternate step upwards of each leg. When going upstairs he leads off with the sound leg, and drags the paralysed leg up to the same level: when going downstairs

he leads off with the paralysed leg. From affection of the middle and internal cutaneous nerves and of the long saphenous nerve there is anæsthesia of the front of the thigh and knee and of the inner side of the leg as far as the ankle.

Figs. 105 and 105A are from a case of division of the *sciatic nerve* from a bullet-wound in the thigh in a young soldier. It shows how all the muscles below the knee are atrophied and paralysed, the

FIG. 105.

FIG. 105A.

FIGS. 105 AND 105A.—Paralysis of great sciatic nerve on right side, from bullet-wound of thigh. Showing muscular atrophy below knee, with drop-foot. The black line indicates the upper limit of the anæsthesia.

hamstring muscles having escaped, since the nerve was divided below the level of the hamstring branches. Besides the muscular atrophy with the usual drop-foot, we have anæsthesia in the areas of the peroneal, musculo-cutaneous, anterior tibial, short saphenous and both plantar nerves.

As a mixed nerve recovers, sensation returns more rapidly than motor power, and protopathic sensation earlier than epicritic. Thus in a previously anæsthetic cutaneous area, as recovery begins, if we pinch the skin we produce a peculiar, specially disagreeable sort of

pain which is diffuse and badly localised by the patient. Later, as epicritic sensibility returns, this protopathic pain gradually becomes less intense. We must thus be prepared to find that in a long-standing case the sensory loss is less complete than in a recent one, or it may happen that sensation is already restored when motor power has not yet returned. This rule, however, is by no means invariable.

As a motor nerve recovers its functions there is a return of muscle-tonus and a diminution of the muscular atrophy long before voluntary movements begin to reappear. Moreover, primitive automatic and associated movements tend to return earlier than the more highly specialised and isolated movements (see Facial Paralysis, pp. 148-149).

As an example of paralysis of a purely motor nerve we may instance the posterior thoracic, or nerve of Bell, which supplies the serratus magnus. The usual cause of its paralysis is inflammation of the subscapular bursa, close to which the nerve runs. Pure serratus palsy is much less common than was formerly taught. When the serratus is paralysed alone, the scapula shows no deformity at rest, since the trapezius and rhomboids keep it in contact with the posterior chest-wall. But on raising the arms horizontally in front of the body the scapula on the affected side becomes detached from the chest-wall and is "winged." In practice, most cases of "winged scapula" are found to be due, not to serratus palsy, but to paralysis of the sub-trapezial plexus (see Fig. 281, p. 518), in which there is deformity of the scapula even at rest.

Recovery of a purely motor paralysis of lower motor neurone type indicates that the lesion must have been of extra-medullary origin, since regeneration of nerve-fibres does not occur within the central nervous system.

Besides such lesions of individual nerve-trunks, we have also to bear in mind so-called **multiple or peripheral neuritis**—a very common disease, affecting the mixed nerves symmetrically on both sides, sometimes in the arms, sometimes in the legs, sometimes in all four limbs, and even other nerves also, such as those of the soft palate, diaphragm, and so on. Such neuritis, when affecting mixed nerves, is easy of diagnosis. The distribution of the sensory and motor abnormalities is characteristic. The patient has subjective tingling feelings in the hands and feet, and on examination we find diminution of sensation to light touches in the "stocking" and "glove" areas of the limbs, often with extreme hyperæsthesia of the soles to pressure. Moreover, the muscles of the limbs are exquisitely tender on being grasped. The motor paralysis, of the lower motor neurone type, specially affects the anterior tibial and peroneal groups in the legs, producing drop-foot, and the extensors of the wrists and fingers, producing drop-wrist (Fig. 106).

The commonest causes of multiple neuritis are chronic poisoning by alcohol (commonly associated with a rapid pulse), arsenic (specially associated with cutaneous eruptions), the diphtheritic poison (specially associated with paralysis of the muscles of accommodation and with weakness of the soft palate), the use of carbohydrate food-stuffs in the absence of their accessory food-factors or "vitamines" causing beri-beri (associated with œdema of the limbs and of certain serous cavities), diabetes, septicæmia, and other poisons such as bisulphide of carbon (in rubber-factory employés), carbonic oxide, and lead. *Lead neuritis* is a peculiar form which practically never attacks the sensory

Fig. 106.—Alcoholic neuritis with drop-wrist.

fibres. The upper limbs are usually affected, the muscles attacked being the extensors of the fingers and wrists, producing wrist-drop. The long extensors of the thumb become paralysed later, the extensor ossis metacarpi pollicis remaining unaffected. The supinator longus usually escapes, so that the disease contrasts with musculo-spiral paralysis, with which it might be confused on superficial examination. The blue line on the gums and other signs of plumbism also aid us in the diagnosis.

Sometimes the lower motor neurones are paralysed in their entire extent, from anterior cornu to periphery, the disease commencing in the motor neurones of the lowest spinal segments and spreading upwards towards the bulbar motor neurones. This affection, known as *acute ascending paralysis*, or *Landry's paralysis*, might be confounded with an ordinary peripheral neuritis were it not for the absence of sensory changes. The paralysis, commencing in the legs and spreading up the trunk to the arms, is of the usual flaccid type with loss of reflexes.

There is no time for muscular atrophy or reactions of degeneration to develop, and if the respiratory muscles become paralysed the patient dies, generally within a week from the onset. The sphincters remain unaffected. Various organisms have been cultivated from the cerebro-spinal fluid and from the peri-dural tissues in such cases. The spleen is frequently enlarged, as in certain other infective disorders.

Before leaving the subject of nerve lesions of lower motor neurone type, we must refer to lesions of the **cauda equina,** that mass of nerve-

FIG. 107. FIG. 107A.

FIGS. 107 AND 107A.—Paralysis of cauda equina from S_5 roots downwards in a miner; due to vertebral injury from a fall of earth.

roots, lumbar, sacral and coccygeal, contained within the lowest part of the spinal theca. According to the roots affected, anterior or posterior, we have motor and sensory symptoms, both distributed in "root" fashion, not according to peripheral nerves. The clinical picture varies according to the level of the lesion. When the whole cauda is involved, we find paralysis (of lower motor neurone type) of all the muscles of the lower limbs, together with anæsthesia below the folds of the groins in front, including the genitals, and below the upper part of the buttocks behind, together with loss of control of the bladder and rectum. If the first, second, and third lumbar roots escape,

the anæsthesia is less extensive (Fig. 25, p. 33), sparing the upper part of the thighs. If the third lumbar roots escape, thereby sparing the quadriceps, the motor paralysis is correspondingly less, and the knee-jerks survive, though there is still paralysis of the glutei and hamstrings and of all the muscles below the knees, with loss of ankle-jerks and paralysis of bladder and rectum as before. If the lesion be lower still, the area of paralysis, motor and sensory, is correspondingly diminished. Below the second sacral roots there is no paralysis of the lower limbs, but there is a characteristic "saddle-shaped" area of anæsthesia on the buttocks, perineum, scrotum and penis, with a small strip running from the perineum down the postero-internal aspect of the thighs. Here also the bladder and rectum are uncontrolled, and the anal reflexes are lost, but there is no motor weakness of the lower limbs, and all the reflexes of the lower limbs are normal. And so on, the area of paralysis diminishing as we descend, until when there is a lesion of the fourth and fifth sacral and the coccygeal roots, the only signs are paralysis of the levator ani, with anæsthesia of the anus and perineum, the sphincter ani remaining intact.

FIG. 108.—Bullet-wound of cauda equina at level of S_2 root on the right side and S_3 on the left. The genitals were also anæsthetic with incontinence of both sphincters. There was no motor paralysis of the lower limbs. The pencil-point indicates the entrance wound on the right side: the exit wound is visible on the left side, at a similar level, immediately above the iliac crest.

The chief difficulty in the diagnosis of lesions in this region is to distinguish between a lesion of the cauda and one of the **conus medullaris**—that part of the spinal cord which extends below the third sacral segment. In both cases the motor power of the legs is unaffected, and there is anæsthesia of the "saddle" area, with loss of sexual power and of control of bladder and rectum. Cauda lesions, however, are more often gradual in onset than conus affections, and are usually accompanied

by intense sacral "root" pains, and the ultimate anæsthesia of a cauda affection is frequently preceded by cutaneous hyperæsthesia. In some cauda lesions the patient suffers from intense burning pains in the perineum and rectum, occurring only when in the sitting posture, and entirely absent when standing, walking, or lying down.[1] This pain is probably due to dragging on the sacral roots. A bed-sore is commoner in a medullary lesion than in a cauda lesion. Finally, any "dissociation" of anæsthesia, such as analgesia or therm-anæsthesia without tactile anæsthesia, points to a medullary lesion. If both cauda and conus are included in the same disease, the cauda symptoms mask the others.

Let us now turn to motor palsies resulting from **affections within the muscles** themselves. Some of these are really the effect of diseases of the intra-muscular fibrous tissue. This is the case in *acute myositis*, in which disease there is an interstitial inflammation within the muscle, often with a good deal of effusion, so that any sudden movement causes acute pain; tenderness on pressure is also present. Lumbago and the familiar "stiff neck" are common varieties, and their diagnosis usually presents no difficulty. **Trichiniasis** is a disease in which the muscle-fibres are invaded by the *trichina spiralis* worm. Here there is a history of the patient having eaten some meat, usually pork, which turns out to have been trichinosed. Within a day or two he develops gastro-intestinal symptoms and becomes feverish, with widespread muscular pains, rigidity, and stiffness, especially in the muscles of the limbs. In severe cases the pharynx, tongue, diaphragm, and even the laryngeal muscles may become affected. Together with this, there is a peculiar œdema of the face and eyelids, spreading thence to the limbs, and sometimes to the serous cavities. The blood contains a marked excess of eosinophile leucocytes, and the temperature is raised. The symptoms last usually four or five weeks.

Sometimes, when a patient has had his forearm fractured and put up in splints, the bandages may be applied too tightly and the blood-supply of the muscles is interfered with by the pressure. As a result, there is œdematous swelling with pain in the hand, and unless the bandages be loosened, **ischæmic paralysis** (v. Volkmann) may develop. This is a variety of myositis following a partial coagulation-necrosis, and usually confined to the muscles on the flexor aspect of the forearm. At first the affected muscles of the forearm swell from œdematous effusion; later they become shrunken, hard, and contractured by zones of interstitial fibrous tissue, with intervening surviving areas of muscle-fibres, the interphalangeal and wrist-joints being in a flexed position and the metacarpo-phalangeal joints extended (see Fig. 109). The

[1] Schlesinger, *Neurolog. Centralblatt*, 1915, p. 450.

thumb, which has a long flexor of its own, often escapes. Active movements are diminished or lost, and passive extension of the fingers or wrist is impossible. The "wooden" hardness and stiffness of the muscles and the absence of R.D. (since the surviving fibres of the affected muscles react normally), together with the normal condition of sensation, suffice, with the history of the case, to distinguish it from a neuritis.

But we also meet with cases of muscular weakness and atrophy localised to certain muscles, where the motor nerves and nuclei are healthy, but the muscle-fibres themselves are primarily diseased. This group of diseases is called **muscular dystrophy, idiopathic muscular atrophy,** or **myopathy.**

Fig. 109.—Ischæmic myositis.

Clinically we recognise two main classes of myopathy:—(1) those cases in which all the affected muscles waste from the outset; and (2) those in which certain muscles undergo a false enlargement before they ultimately become smaller—so-called pseudo-hypertrophic paralysis. But there is really no essential difference between these two varieties. Even in pseudo-hypertrophic cases, certain muscles undergo atrophy from the beginning, whilst in the others atrophy and enlargement may be combined in varying proportions.

Muscular dystrophy is a congenital disease. Not that the symptoms appear at birth, for the child is usually born apparently healthy. The age of onset of noticeable symptoms varies from two to sixty years, though most cases occur in childhood or youth.

The chief distinguishing features between myopathic atrophies and muscular atrophies of nuclear origin, spinal or bulbar, are as follows:—The age of onset is earlier, as a rule, in myopathy than in progressive muscular atrophy or amyotrophic lateral sclerosis. Myopathy often runs in families; progressive muscular atrophy does not. The muscles affected are different in the two cases. In progressive muscular atrophy and amyotrophic lateral sclerosis, the wasting most commonly begins in the small muscles of the hands, attacking muscle-groups corresponding to segments of the cord. In myopathy the larger muscles are generally affected, whilst the small muscles of the hands escape. Amyotrophic lateral sclerosis tends to spread up to the bulbar nuclei, and to produce bulbar paralysis. Myopathy does not cause

bulbar palsy. It is true that in one type of myopathy—the Landouzy-Dejerine—the face is affected, and that in pseudo-hypertrophic cases the masseters are sometimes enlarged; but myopathic palsy hardly ever affects the tongue, and never the larynx. In myopathy some of the diseased muscles may be enlarged, whilst others are wasted. Enlargement of muscles never occurs in nuclear disease. When a myopathic muscle voluntarily contracts, we may sometimes notice a ball-shaped swelling in the middle of the muscle, especially in the deltoid or quadriceps, which is due to the fact that the dystrophy is

FIG. 110.—Family of pseudo-hypertrophic brothers, æt. 4, 8, and 12. The youngest and the oldest can still stand and walk; the middle child can no longer do so. In the two older boys the lower fibres of the pectoral muscles are absent.

most marked at the extremities of the muscles. The long bones of the limbs corresponding to the myopathic muscles undergo a degree of rarefaction and atrophy, and the normal ridges for muscular attachments become smoothed down.[1] Fibrillary tremors, which are so common in progressive muscular atrophy, are rare in myopathy. Lastly, in myopathy, unlike amyotrophic lateral sclerosis, the deep reflexes are never increased. In fact, in myopathy the knee-jerk may disappear from wasting of the quadriceps.

The **pseudo-hypertrophic** variety of **myopathy** generally begins in childhood. This is the most rapidly progressive form of myopathy, and in most cases the patient dies before attaining adult age. Boys are

[1] Merle and Raulot-Lapointe, *Nouvelle Iconographie de la Salpêtrière*, 1909, No. 3.

affected four or five times as often as girls. The cases tend to run in families, and to select patients of the same sex in each family. Thus we often find several brothers affected whilst the sisters escape. But though the females generally escape themselves, they tend to transmit the disease to their male offspring, so that antecedent cases in a family are always on the mother's side. Children of the same woman by different husbands may suffer from the disease. It is therefore unwise to marry a widow, however young and charming, who has a pseudo-hypertrophic child. The symptoms of pseudo-hypertrophic paralysis are entirely motor. The first symptom which is usually noticed is

FIG. 111.—Pseudo-hypertrophic myopathy. Front view, showing enlargement of calves and thighs.

that the child falls easily, gets up with difficulty, and cannot run or jump like other children, nor can he walk on his heels, keeping the feet raised in front. This weakness gradually increases until in a few years the patient becomes unable to stand or even to sit up in bed. The arms become weak later than the legs. Figs. 111 to 114 show two such patients. In them we notice the characteristic "pot-belly" and the lordosis when standing. The gait is wide-based and waddling, somewhat like that of the comic-opera sailor, and there is often a high-stepping action to clear the toes from the ground. But most characteristic of all is the way in which the patient rises from the floor when placed flat on his back. He first rolls round and gets on to his hands and knees. Then, keeping his feet wide apart, he drags his hands along the floor towards his feet until the knees are straightened. Then he

shifts his hands up to his knees and proceeds to extend the hip-joints by climbing up his thighs. When he has reached the upright position, he leans his trunk backwards to keep the hips extended.

FIG. 112.—Pseudo-hypertrophic myopathy. Side view, showing absence of lordosis in sitting posture.

In pseudo-hypertrophic myopathy certain muscles are specially enlarged and hard—*e.g.* the calf muscles and the infra-spinati. Other muscles may also become enlarged—*e.g.* the quadriceps, glutei, deltoid,

FIG. 113.—Pseudo-hypertrophic myopathy. Showing method of attaining the erect attitude.

biceps, and triceps. On the other hand, certain other muscles waste from the first, without any initial stage of enlargement. Thus the latissimus dorsi, teres major, and lower fibres of the pectoralis major are often absent, so that the folds of the axillæ are poorly marked, and if

we lift up the child by the axillæ he slips through our grasp (see Fig. 110).

The enlarged muscles ultimately shrink and become smaller. As the calf muscles shorten, they produce a talipes equinus which still further hampers the walking powers. When the patient becomes bedridden, the contractures rapidly attain an extreme degree. As the quadriceps wastes, the knee-jerk diminishes and disappears.

Primary atrophic myopathy is a less common type, and owing to absence of muscular enlargement, it is more likely to be confused with progressive muscular atrophy of spinal origin. At least three varieties have been recognised, according to the muscles which are first attacked. Thus we have (*a*) Erb's juvenile type, affecting the muscles of the shoulder-girdles and upper arms; (*b*) Landouzy and Dejerine's facio-scapulo-humeral type, where the atrophy begins in the face; (*c*) a type beginning in the lower limbs, chiefly in the anterior thigh muscles.



Fig. 114.—Pseudo-hypertrophic myopathy. Side view, showing lordosis when standing.

In these atrophic varieties there is no striking preference for boys; both sexes are equally liable. The age of onset too is a little later, commonly between 15 and 35 years, except in facial cases, in which the atrophy may come on in early childhood.

In *Erb's juvenile type* the atrophy begins in the large muscles of the upper arms and shoulders, especially the biceps, triceps, and supinator longus. Figs. 115, 116, and 117 are from such a patient, aged 47, who was a professional "living skeleton" in a travelling "freak" show. In his case the wasting was first noticed at the age of 19. In some instances, as in this particular case, the arms and legs are attacked about the same time. Or the disease may begin in the arms and spread to the legs. The deltoids and spinati often escape, even when the biceps and supinator longus are wasted, the condition in this respect differing from atrophies of spinal origin; and the forearm muscles, except the supinator longus, generally escape too. From weakness of the glutei and quadriceps, the patient when rising to the standing posture may have to climb up his legs, as does a pseudo-hypertrophic case.

The *facio-scapulo-humeral* variety of *Landouzy-Dejerine* commences in early life, the facial muscles being earliest affected. The orbiculares oculorum and oris are weak, so that the patient cannot close his eyes tightly nor blow out his cheeks (see Figs. 118 and 118A). His lower lip droops and projects forwards, and his mouth habitually hangs open. The smile is peculiarly transverse and has a "forced" look, the angles of the mouth being drawn outwards but not upwards. The tongue, ocular and jaw muscles are unaffected. Later the disease spreads to the scapular and upper-arm muscles, and finally to the spinal muscles and lower limbs.

A third type of the disease, of which Fig. 119 shows an example, begins in the legs, and attacks the arms later. In this patient the legs became weak at the age of 12. When she came under observation at the age of 28 she was still able to use her arms, which were contractured at the elbows, for knitting and to feed herself, though she was no longer capable of walking, owing to claw-foot.

FIG. 115.—Muscular dystrophy. Erb's juvenile type. The patient was a professional "skeleton" in an American "freak-show."

Other Varieties of Muscular Wasting. — Wasting of muscles sometimes occurs as a secondary phenomenon in other diseases, in which there is no implication of the spino-muscular motor neurone. Thus the muscles may become small from disuse, as may be seen in any limb which, owing to a fracture, has been confined for several weeks in splints. Disease of a joint is generally accompanied by well-marked atrophy of its surrounding muscles. This *arthritic muscular wasting* specially affects the extensor muscles of the joint—for example, the quadriceps in disease of the knee-joint, the interossei in osteo-arthritis of the hands, the deltoid in disease of the shoulder-joint. A degree of muscular wasting also occurs in the paralysed limbs in ordinary *hemiplegia*. Part of this may be the result of disuse, but there are other

FIG. 116.—Muscular dystrophy. Erb's juvenile type. Patient endeavouring to rise to standing posture.

FIG. 117.—Muscular dystrophy. Erb's juvenile type. Patient rising to erect posture.

cases in which the degree of wasting is excessive, and disproportionate to the paralysis.

We may also meet with wasting of muscles in rare cases of *hysterical paralysis* (see Fig. 216, p. 387). But all these muscular wastings can

Fig. 118A.

Fig. 118.

FIGS. 118 AND 118A.—Myopathy: Landouzy-Dejerine type. Fig. 118 shows position at rest. Fig. 118A shows weakness of orbiculares oculorum and orbicularis oris on attempting to screw up the eyes and blow out the cheeks; also upward displacement of scapulæ and wasting of lower part of pectoral muscles.

be distinguished from that due to disease of the lower motor neurone by the absence of electrical reactions of degeneration.

Reflex Palsies.—Both in peace and in war we meet with motor disability, sometimes flaccid, sometimes spastic in type, localised to

muscle-groups of the upper or lower limb, following on some local trauma. The intensity of such reflex disorder is not necessarily proportional to the severity of the primary injury; a trivial injury may cause widespread physical signs extending proximally up the limb above the site of injury. The injury need not implicate any nerve or large blood-vessel, but may be in the bones, joints, or soft parts.

Fig. 119.—Muscular dystrophy commencing in lower limbs. Showing deformity of feet.

The motor weakness is usually incomplete, and is generally associated with a moderate degree of diffuse muscular atrophy. This muscular atrophy differs from that produced by nerve-injuries in that it never shows the electrical reactions of degeneration.

The affected limb is abnormally cold: its surface temperature may sometimes be as much as 8° C. (*i.e.* 14° F.) below that of its healthy fellow. This hypothermia is one of the most constant phenomena, and helps to distinguish the condition from hysteria, for which it is often mistaken. The skin of the affected hand or foot is sometimes cyanosed, and often moister than normal.

Together with hypothermia, there is increased irritability of the subjacent muscles to percussion, especially of the intrinsic muscles of the hand (or foot), with an abnormally slow muscle-wave. When the

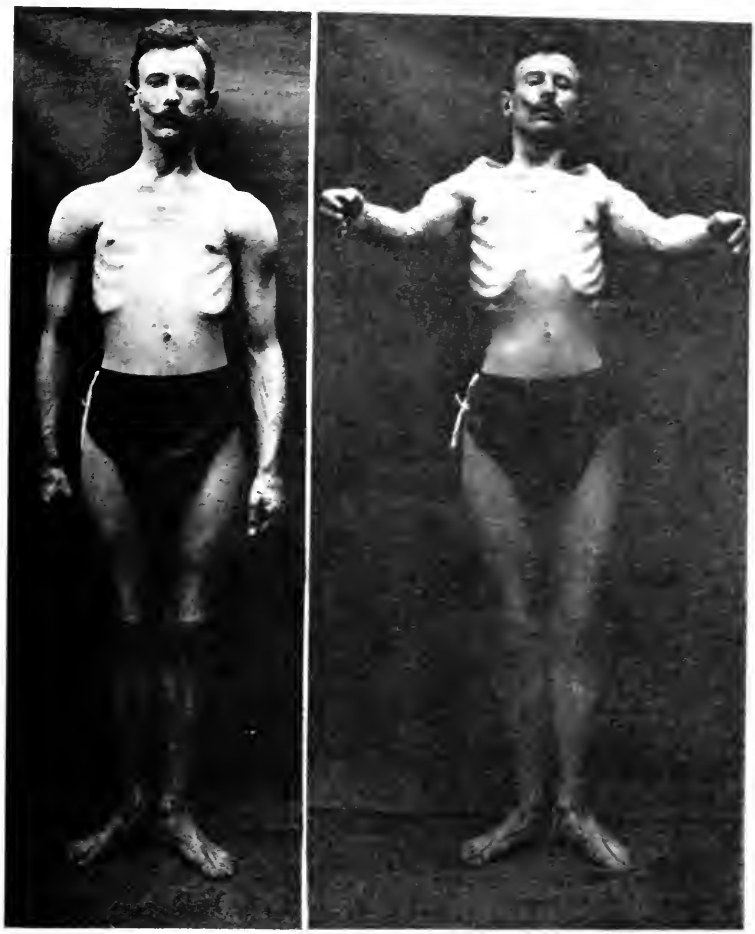

FIG. 120. FIG. 120A.

FIGS. 120 AND 120A.—Muscular dystrophy. Erb's juvenile type.

Fig. 120 shows absence of lower fibres of pectorals, together with pseudo-hypertrophy of deltoids and absence of serrati. The upper borders of the scapulæ are visible from the front.
Fig. 120A shows the increased deformity on raising the arms horizontally forward. The upper angles of the scapulæ are still more evident and the upper edges of the trapezii are now visible, passing from the vertebral spines towards the scapulæ.

muscular hyper-excitability is poorly marked, it can be rendered manifest by plunging both limbs into cold water: the hypothermia and mechanical irritability on the affected side are at once increased.

The deep reflexes in the affected limb are not necessarily affected;

sometimes, however, they become exaggerated, especially during the phase of recovery after deep chloroform anæsthesia.[1] In cases affecting the lower limb, the plantar reflex may be abolished; it is never of the "extensor" type.

Blunting of sensation in the affected limb, rarely confined to a single nerve-area, and occasionally of typically hysterical, segmental

FIG. 120B.—Muscular dystrophy. Same patient as in Fig. 120. Showing loss of trapezii, save for their uppermost fibres, with consequent "winging" of scapulæ. Also note lordosis.

distribution, may also be met with. But sensory changes are often absent.

The foregoing phenomena may coexist either with a hypertonic contracture or with a flaccid, hypotonic paralysis, or with a combination of the two, *e.g.* contracture of the flexor muscles of the hip,

[1] Babinski and Froment, *Revue neurologique*, 1915, p. 925; *Presse médicale*, fev. 24, 1916.

combined with flaccid paresis of the ankle and toes, following an injury of the thigh; or, again, spastic semi-flexion of the elbow together with flaccid paresis of the extensors of the wrist and fingers, following an injury of the forearm.

The peculiar hypothermia, in conjunction with the mechanical hyper-excitability of the muscles, serve to distinguish reflex palsy from mere hysteria, with which it is sometimes combined. Some observers, whilst admitting the existence of the foregoing syndrome, regard the condition as due to prolonged immobility of a hysterical limb. But the condition is sometimes met with in limbs which are not immobile.

The following is an illustrative example of reflex paralysis of the leg:—

A man, aged 35, had a hernial swelling of the left anterior tibial muscle of many years' duration. This was successfully repaired by operation subsequently, however, the patient developed pain in the region of the operation-wound with weakness of all the muscles below the knee.

When examined two and a half years later, the left foot was found to be much colder than the right and of a salmon-red colour. There was an old operation-scar running vertically down the peroneal region of the limb. The skin was hyperæsthetic all along the scar and also below it, in a vertical strip on the dorsum of the foot. The left ankle was completely paralysed, but the left toes could be feebly flexed and extended voluntarily. The circumference of the left leg was 1·5 cm. and that of the left thigh 1 cm. less than on the healthy side. All the paralysed muscles reacted briskly to faradism. The knee-jerks and ankle-jerks were brisk and equal. The plantar reflexes were absent on both sides. There was marked hyper-excitability of the left peronei, anterior tibial, and calf-muscles to direct percussion. The amplitude of oscillation, measured in the posterior tibial arteries by means of a sphygmo-manometer, was 0·75 mm. of Hg in the left leg, as compared with 1·5 mm. on the healthy side.

The condition is "functional," but not in the sense of being psychogenic in origin. It appears to be due to a hyper-excitable condition of the anterior cornual cells in the corresponding segment of the spinal cord, in cases with muscular hypertonia. In cases with hypotonia, the corresponding anterior cornual cells are inhibited. There is probably also some disorder of the intermedio-lateral group of cells (nucleus sympatheticus) to account for the hypothermia and vascular spasm.

CHAPTER XV

RECURRENT AND TRANSIENT PALSIES

THERE are certain forms of motor paralysis which come and go. They tend to recur again and again, and in the intervals between his attacks the patient is able to execute all voluntary movements in a normal or almost normal fashion.

Of these diseases **myasthenia gravis** is the most serious. Its clinical course is singularly variable: thus whilst some cases prove fatal within a few weeks or months, others may last for ten years or longer. In myasthenia certain muscles become infiltrated with deposits of small round cells resembling lymphocytes, especially the striated muscles innervated by the upper cranial nerves, though sometimes the muscles of the limbs and trunk, and even the respiratory muscles, may become affected. The disease is characterised by the fact that the patient becomes, even after very moderate exertion of the affected muscles, abnormally easily fatigued, and the affected muscles are, for the time, paralysed. The patient wakes up in the morning practically normal, but as the day goes on, certain muscles gradually become paralysed. Perhaps the muscles most often affected are the levators of the upper lids. Thus ptosis appears, often of unequal degree on the two sides (see Fig. 121). To this may be superadded an external ophthalmoplegia, generally incomplete. The facial muscles also become weak, and the patient has a peculiar "nasal" form of smile, in which the angles of the mouth are drawn upwards, but very slightly outwards. The masseters and other masticatory muscles may also be affected, so that the patient cannot chew more than a few mouthfuls. The palate, tongue and larynx may all be implicated, producing for the time the phenomena of bulbar palsy. In fact, the disease was formerly named "asthenic bulbar paralysis." To correct his ptosis, the patient may tilt his head backwards. But sometimes the neck muscles are affected, so that the head falls loosely backwards or forwards. In the limbs it is chiefly the large proximal muscles which are affected. But the most characteristic feature is the transitoriness of the paralysis, and its recurrence on slight exertion. Thus the patient can walk a short distance, but soon has to stop; he may speak a few sentences, and then his voice becomes weak and his articulation indistinct. In the affected muscles

the electrical reactions are altered and we have the "myasthenic reaction." Faradic shocks applied to the muscles produce, at first, brisk contractions, but on repeated stimulation the faradic excitability temporarily disappears. In contrast to true bulbar palsy, there is no muscular atrophy as a rule, although in very severe cases slight wasting may supervene.[1] The reflexes, deep and superficial, together with the sphincters, are unaffected. If the respiratory muscles become severely affected, the patient may die from respiratory failure. In addition to

FIG. 121.—Myasthenia gravis in a man of 35. Marked weakness of masseters and of lower facial muscles; also right-sided ptosis. The patient is making a maximum effort to clench the jaws and show the teeth.

motor phenomena, we may also have evidences of fatigue in the special senses and even in common sensibility. Thus the myasthenic patient may have temporary impairment of visual acuity with temporary contraction of the visual fields, and in rare cases temporary diminution of sensation has been observed in the limbs.[2]

Thomsen's disease, or **"myotonia congenita,"** is a rare congenital affection of the voluntary muscles, which appear to possess an excessive proportion of undifferentiated sarcoplasm and muscle-nuclei, and relatively too small a proportion of the anisotropic or fibrillar element. This latter contracts briskly, whereas sarcoplasm contracts very slowly.

[1] See E. Levi, *Rivista di patologia nervosa e mentale*, 1906, p. 450.
[2] Tilney and Mitchell Smith, *Neurographs*, 1911, vol. i., p. 178.

In Thomsen's disease, whenever the patient starts to perform a brisk voluntary movement, his muscles are thrown into a state of tonic spasm, which does not relax at once, but passes off gradually, the muscles slowly becoming supple, until at length he can perform the movement, say, that of walking, in a normal fashion ("*ce n'est que le premier pas qui coute*"). But if he stops and starts again, or if he tries to hurry his original speed, this stiffness and slowness of relaxation reappear, and have again to be, as it were, worked off. The lower limbs are most commonly affected, the affected muscles often being somewhat enlarged, but other muscles may also show the phenomena. Thus the patient's eyes may remain for a time firmly closed after a cough or sneeze, his mouth may remain open after a yawn, and so on. The sensory functions are unaffected. The reflexes are normal in type, but sometimes when the plantar reflex is elicited the flexor muscles of the toes remain tonically contracted for several seconds, instead of relaxing promptly as in health. A similar myotonic condition may also be observed in the cremasteric reflex. The affected muscles have a characteristic reaction to electrical stimulation. Their excitability is increased to both faradism and galvanism. To galvanism KCC is equal to ACC (instead of being greater, as in health), and the contraction set up, whether by galvanism or by faradism, is remarkably persistent, lasting for a time after the stimulus has ceased. The disease runs in families and affects patients of both sexes.

Eulenburg's disease, or "**paramyotonia congenita,**" is a family affection, somewhat like Thomsen's disease, in which a tonic spasm appears in certain voluntary muscles, more particularly in the face, so that the patient is unable, for a quarter of an hour or longer, to open his eyes or to speak. Less often the muscles of the limbs are affected. However, the condition differs from Thomsen's disease in its immediate exciting cause. The tonic spasm of Eulenburg's disease is excited, not by exertion, but by cold, and is generally relieved by warmth. Eulenburg attributed the symptoms to a temporary reflex vasomotor spasm of the voluntary muscles.[1] The two diseases, however, are closely allied, and have been observed coincidently in members of the same family.[2]

Myotonia atrophica[3] is a rare congenital disease, intermediate in its characters between the myotonias and the myopathies. On account of the overwhelming preponderance of dystrophic symptoms, it is better named **myotonic dystrophy.** It sometimes occurs in several members of the same family. The patients are more often males than females, and the symptoms usually appear between the ages of twenty

[1] *Med. Klinik*, 1916, No. 16.

[2] Delprat, *Deutsche med. Wochenschrift*, 1892, s. 158.

[3] Rossolimo, *Nouvelle Iconographie de la Salpêtrière*, 1902, p. 63. Batten and Gibb, *Brain*, 1909, p. 187. Rohrer, *Deutsche med. Wochensch.*, 1916, vol. lv., H. 4–6.

and thirty. The myotonic phenomena generally precede the muscular wasting. The first symptom is usually a difficulty in relaxing the grasp, *e.g.* after shaking hands. Myotonic phenomena in other muscles are slighter in degree, and are chiefly seen in the muscles of mastication, the facial muscles and the tongue; they are rare in the lower limbs. Atrophy of myopathic type appears later, irregular in its distribution, chiefly affecting the facial muscles (resembling the Landouzy-Dejerine type of myopathy), the sterno-mastoids and the vasti muscles of the thighs. It may also be present elsewhere in lesser degree, as in the supinator longus and other forearm muscles, and the peronei and dorsiflexors of the foot. The electrical reactions in the wasted muscles are simply diminished. Testicular atrophy with sexual impotence, or ovarian atrophy with premature menopause, is common. A considerable proportion of cases show other evidences of precocious senility, *e.g.* baldness, cataract, and mild dementia.

Another interesting variety of transient paralysis is known as **intermittent arterial claudication,** or **"dysbasia angio-sclerotica"** (*"claudication intermittente"* of Charcot, or the *"intermittirendes Hinken"* of German authors). The patient is most commonly a man of middle age, sometimes of gouty constitution, who very often has been an inveterate tobacco-smoker. The symptoms are very characteristic. At rest he feels no disability. But when he begins to walk, although he starts off normally, he soon begins to feel his legs tired, heavy and painful. A cramp-like pain appears and gradually becomes intolerable, making him limp; and if he perseveres with his attempt, he finally becomes, for the time, totally unable to walk a single step. He rests, the pain and weakness pass off, only to return when he starts to walk afresh. If we examine such a patient during a paroxysm of temporary incapacity, we find his feet and legs cold and perhaps purple or mottled red. But what is most characteristic of all is that the pulse in the feet, in the posterior tibial or the dorsalis pedis artery, is absent or nearly so. There are no sensory changes, the reflexes are normal, and, except during the paroxysms, the motor power of the limbs is unimpaired. *Goldflam's sign* can often be elicited, consisting in marked pallor of the foot, and sometimes of the lower part of the leg, when the patient, lying horizontal, with the leg extended, repeatedly raises it at the hip-joint. All these phenomena appear to be the results of a temporary spasm of the arteries of the limb (the arteries themselves often being already narrowed by arterio-sclerosis), so that during walking an increased blood-supply to the muscles is not forthcoming, hence there result temporary ischæmia, pain and weakness in the affected muscles. In rare instances similar phenomena have been observed in the arms.

Intermittent spinal claudication, due to spasm of the arteries of the spinal cord, also occurs. As in peripheral claudication, the symptoms occur on exertion. As a rule one leg is affected sooner than the other, and the malady may even remain unilateral for months or years. After walking a certain distance, say a mile or two, the patient develops temporary asymmetrical weakness of the lower limbs, of spastic type, with exaggerated deep reflexes, extensor plantar responses and delay or precipitancy of micturition. As the malady progresses, the amount of exertion necessary to induce the symptoms becomes less and less, until the patient becomes unable to walk more than a few steps without developing spastic paraplegia. Moreover, the spinal arteries ultimately undergo organic obstruction by arteritis (often of syphilitic origin), producing not merely intermittent, but permanent spastic paraplegia. The condition is distinguished from intermittent arterial claudication by the absence of coldness or blueness of the feet, by the occurrence of a sensation of heaviness rather than pain in the limbs, by the alteration of the reflexes and by the bladder affection.

Cases also occur in which a hemiplegia, partial or complete, sometimes accompanied by aphasia, occurs in an elderly patient, indistinguishable at first from an ordinary cerebral hæmorrhage or thrombosis. But within a few hours all the hemiplegic phenomena disappear suddenly, leaving the patient apparently normal. The patient may have a series of such attacks of transient hemiplegia at intervals of days, weeks or months. For over three years I watched the case of an elderly cabman who had numerous attacks of left hemiplegia lasting for a day or so, leaving him absolutely well in the intervals. Another case of mine was in a vigorous business man, aged fifty-one, who had frequent attacks of temporary aphasia with right hemiplegia. Similar cases have also been recorded by Grasset[1] and by Langwill.[2] Such cases may be termed **angio-spastic hemiplegia** or **intermittent cerebral claudication,** and are probably due to temporary spasm of one middle cerebral artery, analogous to the spasm of peripheral vessels in intermittent limp. They must be carefully distinguished from the transient hemiplegia which is not uncommon in general paralysis of the insane. Sometimes these transient attacks culminate in a final attack of hemiplegia which does not clear up, but remains permanent, due to actual arterial thrombosis.[3] In the business man above referred to, this occurred two and a half years after the first attack of his series.

Amongst the transient paralyses we must also bear in mind the various craft-palsies, professional cramps, or **occupation neuroses,** in

[1] *Revue neurologique,* May 30, 1906.
[2] *Scottish Medical and Surgical Journal,* June, 1906.
[3] See a case by Hunter and Robertson, *Review of Neurol. and Psych.,* 1913, p. 419.

which the limb is normal for all motor actions except one particular movement—often, unfortunately, the one on which the patient's livelihood depends. The commonest variety is the so-called writer's cramp or scrivener's palsy, though we also meet with similar conditions in the cramp of pianists, violinists, telegraphists, typists, tailor's cutters, hair-cutters, hammer-men, cow-milkers, watch-makers, harpists, cigarette-makers, sempstresses, and so on. The cramp comes on, not during the period when the sufferer is learning his occupation, but after he has become an expert and requires to perform the particular skilled movement repeatedly over prolonged periods. For all other movements except that particular one the limb is normal. Thus in writer's cramp the patient can use his hand normally for piano-playing or for grasping and using a heavy tool. This is because the weakness is not due to muscular, but to cerebral fatigue. A professional cramp does not appear in its fully developed form at first, but passes through different stages of severity. In the slightest variety there is simply a degree of stiffness or spasm in performing the act, with a subjective sensation of pain and of intense mental discomfort and fatigue. In other cases a temporary paralysis appears when the patient attempts to write, so that the pen can no longer be held in the hand. In still more severe cases tremor is superadded to spasm in the affected muscles. The diagnosis is easy, inasmuch as the phenomena, whether spastic or paralytic, or perhaps a combination of both, only supervene when the one skilled motor action is performed, and the same muscles can be used for all other actions without pain, spasm or weakness.

There is also a curious hereditary disease known as **"family periodic paralysis."** This malady may run through several successive generations of the same family, attacking one or more members of the same generation. Males and females are both liable. The patient, who is otherwise apparently healthy, has attacks of flaccid paralysis of all four limbs, recurring irregularly without apparent exciting cause. The duration of a paroxysm varies from a few hours up to two or three days. The attacks generally come on during the night when the patient is in bed. He wakes up and finds himself more or less widely paralysed. First the legs are affected, later the arms, and last of all the muscles of the trunk and neck. The cranial nerves usually escape. In the limbs the paralysis starts proximally, and the distal parts are affected last, so that the patient may still be able to move his toes and fingers when he has lost all power in the hips and shoulders. In severe cases the intercostal muscles may also be paralysed. Most striking of all is the fact that during these paroxysms of flaccid palsy the affected muscles lose, for the time, their excitability to faradic, galvanic, or mechanical stimulation (cadaveric reaction), and all the

reflexes in the affected limbs disappear. Sensation is unimpaired, and the sphincters are unaffected. An additional point is that during the paroxysm the left ventricle becomes temporarily dilated, as can be proved by percussion and occasionally by the appearance of a systolic mitral bruit. The muscular paralysis passes off in the reverse order to that in which it came on. The toes and fingers recover before the proximal muscles, and the muscles earliest attacked are the last to recover. The patient then remains apparently normal until his next attack, weeks or months later.

Sudden attacks of hemiplegia may also occur in **general paralysis of the insane,** constituting a variety of so-called " congestive attacks." But although the patient may recover rapidly from his hemiplegia, often within a few days, he is not a normal individual, for careful physical examination will always reveal evidences of the disease, mental or physical, *e.g.* facial tremors, pupillary changes, or, most constant of all, lymphocytosis of the cerebro-spinal fluid.

Amongst other transient affections we may mention those of **muscular cramp** and of **tetany.** The conditions are easily recognised, and may temporarily interfere with the movements of the affected limbs. Both are painful affections, tetany being most commonly seen in infants, whilst cramp is most often met with in healthy adolescents or adults who have been performing some unwonted prolonged muscular effort. Cramp is also a distressing symptom in cholera, in some cases of diabetes, and occasionally in exophthalmic goitre. Tetany is generally bilateral, and produces a characteristic posture of the hands and feet (see Fig. 39, p. 75).

Occasionally we see patients who complain that their legs suddenly give way in the street, causing them to fall. This may be due to various causes. For example, it is a not uncommon symptom in **tabes.** The tabetic patient often has hypotonia of the muscles about the knees and also deficient joint-sense, a combination of phenomena which may make him fall unexpectedly. In such a case the condition of the deep reflexes, the state of the pupils, and the other phenomena of tabes render the diagnosis easy. Other cases of sudden falling are due to **minor epilepsy,** where the patient has an attack of momentary unconsciousness during which he falls, but recovers consciousness at once and gets up again, not knowing why he has fallen. Here the diagnosis will depend on the observation of other epileptiform attacks, major or minor. We should particularly inquire for the occurrence of sudden pallor of the face or fixity of expression, indicating a passing attack of petit mal, too slight, perhaps, to produce a fall.

In other cases, again, we have to do with sudden **vertigo,** as in Ménière's disease, causing the patient to fall. Such cases are distin-

guished from petit mal by the concomitant auditory phenomena (see p. 156), and by the fact that they are not associated with loss of consciousness.

Sudden weakness of a limb may occur in **hysteria**, especially after some emotional shock. Hysterical paralysis may persist for variable periods of time, varying from a few hours to many weeks or months. The paralysis not uncommonly passes off as suddenly as it came on, sometimes under emotional or religious excitement, under hypnotic suggestion, or under energetic stimulation, electric or thermal, for example, that of a Pacquelin cautery. Hysterical paralysis never attacks a single muscle, but always a group of muscles. It is never accompanied by reactions of degeneration, no matter how much the hysterical limb may be wasted. We diagnose hysteria by a process of exclusion, noting not only the absence of certain signs of organic disease, but looking also for the presence of various hysterical phenomena, to which we shall refer later.

But we must not forget that in many cases of apparently hysterical and transient paralysis in young women, the patient after one or more of such attacks may afterwards develop the signs of **disseminated sclerosis.** The onset of disseminated sclerosis may be indistinguishable from an attack of hysterical paralysis; the weakness of the limb in both diseases may be transient and may apparently clear up completely for a time. But a series of such attacks should always raise in our minds the suspicion of an underlying disseminated sclerosis and should make us give a guarded prognosis, especially if the patient has had more than one attack of weakness, not necessarily in the same limb. We should pay particular attention to the optic discs and to the condition of the abdominal reflexes. Early optic atrophy will exclude mere hysteria, so also will an extensor plantar reflex or anything approaching a true nystagmus. In fact, the disease which is most often wrongly diagnosed as hysteria is incipient disseminated sclerosis.

CHAPTER XVI

INCO-ORDINATION

A NEWLY-BORN child cannot co-ordinate the movements of its limbs. Certain co-ordinated vital actions, such as sucking, swallowing, respiration, etc., are performed well from birth, but in an infant's limbs the movements are mostly of an aimless, restless character, with the exception, perhaps, of grasping movements of the hands. And even these latter differ from the co-ordinated grasp of later life, inasmuch as the infant's thumb is hardly used at all for opposition, and the flexion movement of the fingers occurs chiefly when some object comes in contact with the hand, the movement being reflex rather than voluntary.

The child only learns after long practice to use its muscles in such a fashion as to produce properly co-ordinated movements of the limbs. Walking, writing, swimming, the playing of any game, are all performed awkwardly at first. Skill is at last attained by frequent repetition, and once a co-ordinated action has been thoroughly learned, the effort for its performance becomes infinitesimal, so that in the course of time it is performed more or less automatically.

Every co-ordinated action involves contraction not only of the so-called prime-movers, but of their antagonists, and if these two groups are not properly balanced, the attempted movement is awkward and jerky. This condition occurs in a number of diseases, and is termed **ataxia** or **inco-ordination**. This means clumsiness, unsteadiness, or awkwardness in the performance of movements in a non-paralysed patient who was previously able to execute these movements in normal fashion.

In testing for ataxia of the upper limbs, we ask the patient to perform such an action as picking up a small object, say a pin, from a smooth surface. If he is ataxic, he fumbles during the attempt, or may perhaps pounce on the object in a sudden, jerky fashion. Another useful test is to ask the patient to lift a brimming glass of water to his lips and notice whether he spills it. Or we may ask him to touch rapidly the tip of his nose with each index finger in succession. If he is ataxic, his finger misses his nose by a greater or smaller interval, or, on reaching it, the finger shows additional oscillatory movements.

Other good tests for ataxia are to make the patient button or unbutton his coat or collar, or to write with a fine-pointed pen. In every case we should observe whether the unsteadiness is increased or unchanged when the patient shuts his eyes. Slight degrees of ataxia due to sensory impairment may be noticeable only when the patient is deprived of the help of his visual impressions.

In the case of the lower limbs we detect moderately severe ataxia by observing the patient's gait, asking him to walk "heel-and-toe" along a straight line, then to turn sharply and come back. In well-marked locomotor ataxia the gait is broad-based, the feet are lifted too high and the heels are brought down with a stamp. In cerebellar disease, on the other hand, the patient reels or lurches along, being especially unsteady when turning round (see later, "Postures and Gaits"). To detect ataxia of a single lower limb, we ask the patient to place one heel on the opposite knee, or to trace with one foot a circle or some other pattern on the floor, or we ask him when lying down to touch with his toe our own finger held in the air. And here also, in ataxia of the lower limbs, we should always note whether the patient's unsteadiness is increased or unchanged by shutting the eyes. In tabetic ataxia of the lower limbs, the unsteadiness is increased when the eyes are shut. *Romberg's sign* consists in the tendency of a patient, who can stand steadily with the eyes open, to fall when he closes them. Thus an early sign of tabes is the so-called "wash-basin" sign, where the patient falls into his basin when washing his face. A minor degree of Romberg's sign can often be detected in the earlier stages of tabes, where the patient is still able to stand with the eyes shut, but the tendons on the dorsum of the foot are seen to exhibit irregular restless contractions, the so-called "*danse des tendons*."

Ataxia of the bulbar muscles has already been referred to (see Dysarthria, p. 109). As to ataxia of the muscles of the trunk, its diagnostic significance is less than that of the limbs, inasmuch as by the time that the trunk muscles are recognisably ataxic, the limbs already show very marked unsteadiness. Ataxia of the head and trunk muscles is evidenced by swaying movements when the patient sits up.

Having detected ataxia in the movements of any limb, we must always determine the condition of the sensory impulses from that limb, testing not only the various forms of cutaneous sensibility, but also the deep sensations, especially the kinæsthetic sense and, still more important, the joint sense. Finally, we must determine the condition of the deep reflexes, noting their exaggeration as in disseminated sclerosis, or their abolition as in tabes or in Friedreich's ataxia. We also note the type of plantar reflexes.

The commonest variety of ataxia is that due to deficiency of peripheral impressions—not so much from the skin as from the deeper structures, the muscles and joints. Thus in lesions of *peripheral sensory nerves* an anæsthetic limb is often ataxic. Division of the *posterior roots* of the brachial plexus, the anterior roots remaining intact, causes marked ataxia of the upper limb. In fact, such a patient may be totally unable to move the limb if his eyes are closed, so that he no longer has the guiding influence of vision. Degeneration of the posterior roots and posterior columns, as in *tabes*, produces marked ataxia. A tabetic patient is ataxic because of deficiency of afferent impressions, more especially from his muscles and from his joints. If the muscle-tonus is lost and the muscles are hypotonic, as in many cases of tabes, the patient has, as it were, to "pull in the slack" before the muscles come into proper play, thereby making the movement jerky, inharmonious, and flail-like. Joint sense being impaired, he has to perform an exaggerated movement in order to get the sensation of having moved the joint at all. Thus in walking, when he lifts his leg, owing to want of proper joint sense, he throws the limb up with abnormal suddenness and to an unnecessary height in order to gain the sensation of flexion of the joint. He then stamps it down with excessive emphasis to make sure that it really is extended. Such a patient with ataxia of sensory origin compensates for the deficiency of sensory impressions from his limbs by means of his vision. When watching his partially anæsthetic limbs, he can control them better. Hence if he closes his eyes, the regulating influence of vision is lost and he becomes much more ataxic. This is the explanation of Romberg's sign in tabes.

Ataxia similar to that of tabes also occurs in other organic cord lesions implicating the posterior columns, as, for instance, in *tumours* or *chronic sclerosis of the posterior columns*, whether combined or not with lateral sclerosis—*e.g.* some cases of disseminated sclerosis or spinal syphilis. In such diseases the other signs and symptoms guide us to a correct diagnosis.

Ataxia combined with spasticity occurs in the early stage of *subacute combined degeneration* of the spinal cord, generally a disease of middle life. This disease occurs chiefly in conditions of profound anæmia. In the first stage of the malady joint sense is lost and there are subjective sensations of tingling in the lower limbs, not unlike those of tabes, but with increased knee-jerks and extensor plantar reflexes. Vibration sense in the bones of the lower limbs is lost long before any cutaneous anæsthesia develops. After lasting for weeks or months the disease then changes its type, and in this second stage the spastic paraplegia becomes severe and marked anæsthesia develops in

the lower limbs and trunk. Lastly, and usually abruptly, within a few days the type changes once more, and there is a terminal stage of flaccid paraplegia lasting a few weeks, with absolute anæsthesia of the lower limbs and trunk, loss of the knee-jerks, the plantar reflexes remaining extensor in type. The paralysed muscles rapidly waste and lose their faradic excitability. The bladder and rectum are uncontrolled, and the lower limbs become œdematous. The whole disease from start to finish lasts about two or three years.

Vestibular Ataxia.—A highly characteristic disorder of co-ordination appears temporarily in healthy individuals during the transient vestibular nystagmus produced, according to Bárány's method, by syringing the external auditory meatus with cold or hot water, by rotating the patient in a revolving chair, or by the stimulation of a galvanic current transmitted between the two mastoid processes. The effect produced is known as Bárány's "*vorbei-zeigen*," signifying deviation or misdirection in pointing to an object. It is elicited as follows:—The patient, with closed eyes, touches the physician's finger held steadily in front of him. He is now directed, without opening his eyes, to drop his arm vertically and to come up again, so as once more to touch the physician's finger, which forms the target. A normal person should succeed in touching the target with his eyes closed, on testing with either hand. The experiment is then repeated, but this time the patient approaches the target along a horizontal plane, from side to side. Here also the normal person succeeds without difficulty with either hand. After these preliminaries, by syringing the left ear with cold water (the patient meantime lying on his back), we now proceed to induce a horizontal nystagmus in the patient when he looks towards the right. When we try the pointing tests again, we now find deviation or mispointing (*vorbei-zeigen*) of all the patient's limbs towards the left, so that the patient's finger passes to the left of the target by several inches, *i.e.* he misses towards the direction of the slow phase of the nystagmus. If we produce a vestibular nystagmus on looking downwards (the slow phase being upwards), we have deviation of all the limbs in an upward direction. If we produce a rotatory nystagmus on looking to the right, the left arm shows deviation downwards, whilst the right arm deviates upwards, on testing in the horizontal or side-to-side plane.

This mispointing or "*vorbei-zeigen*" depends not only on the nystagmus, but also on the position of the head. By changing the posture of the head we can correspondingly alter the plane of deviation. Thus, during a horizontal nystagmus towards theright, if the head be suddenly bent through a right angle on to the right shoulder, the deviation to the left disappears and is replaced by deviation upwards. Again, during a rotatory nystagmus towards the right, if we rotate the head around a vertical axis through a

right angle towards the right, the deviation in the frontal plane disappears, and is replaced by deviation in the mesial plane, so that both arms deviate downwards.[1]

A patient may be ataxic when all his peripheral sensations are normal. This occurs in the different varieties of cerebellar ataxia

Fig. 122.—Friedreich's ataxia. Showing scoliosis.

Let us take, for example, **Friedreich's ataxia,** a developmental disease affecting mainly the afferent tracts in the postero-lateral columns of the cord leading upwards to the cerebellum, which is the centre for automatic co-ordination (the cerebellum itself being intact). In Friedreich's ataxia the patient becomes ataxic, as in tabes, but in the early stages of the disease there may be no sensory loss of any kind. The ataxia is unaffected by closing the eyes.

As the disease advances and the degeneration of the posterior columns becomes more profound, those sensory impressions which run upwards in the posterior columns (*i.e.* joint-sense, kinæsthetic sense, and vibration sense) become lost, and slight tactile loss occurs in the distal portions of the limbs, the lower limbs being earlier and more severely affected than the upper, whilst sensibility to temperature and pain, running upwards in the lateral columns, remains unimpaired to the end.[2]

The age of the patient, who is commonly an adolescent, the presence of scoliosis, of manus cava, and of pes cavus (Figs. 122 and 123), the normal pupillary reactions, the presence of nystagmus, the absence of lightning pains or of bladder trouble, all serve to distinguish this disease from tabes, though in both diseases the deep reflexes are absent. The plantar reflexes in tabes are flexor in type, whilst in Friedreich's ataxia they are of the extensor variety, and associated with well-marked "defensive reflexes."

[1] Bárány, *Wiener klin. Wochensch.*, 1912, pp. 2033–38.
[2] Saunders, *Brain*, vol. xxxvi., 1913, p. 163.

Well-marked ataxia combined with muscular atrophy, absence of deep reflexes, and deformity of the feet and hands, also occur in family **progressive hypertrophic neuritis** (see above, p. 222). In this disease, however, unlike Friedreich's ataxia, we never have an extensor plantar reflex, whilst from the start there are well-marked sensory changes in the limbs.

Fig. 123.—Friedreich's ataxia. Showing pes cavus and manus cava.

Ataxia also occurs in certain localised lesions of the **medulla oblongata.** Thus, for example, a unilateral lesion may interrupt the fibres of the direct cerebellar tract and thereby interfere with co-ordination of the ipso-lateral limbs. Such a lesion (commonly the result of *thrombosis of the posterior inferior cerebellar artery*), which usually interrupts at the same time the fibres of Gowers' tract, may extend inwards to implicate the inter-olivary arcuate fibres and the fillet, together with the nuclei of the lower cranial nerves. It produces a characteristic **unilateral bulbar syndrome.**[1] The symptoms are as follows:—From

[1] Babinski and Nageotte, *Revue neurologique*, 1902, p. 358.

interruption of the cerebellar afferent fibres there is ataxia (or asynergia) of the ipso-lateral limbs. From interference with the tract for pain and temperature we have a "dissociated" anæsthesia, viz. analgesia and therm-anæsthesia of the opposite side of the body (see Fig. 12, p. 15). From interference with the oculo-pupillary centre in the bulb there is myosis and pseudo-ptosis (see later, "Cervical Sympathetic Paralysis," p. 341), and there may be difficulty of deglutition due to affection of the cranial nerve nuclei. If the lesion extends forwards to implicate the pyramid of the same side, there is hemiplegia of the contra-lateral arm and leg.

Marie's **hereditary cerebellar ataxia,** ascribed to primary parenchymatous degeneration of the cerebellum itself, is somewhat similar to Freidreich's ataxia, but there is no loss of knee-jerks or affection of plantar reflexes, scoliosis does not occur, nor pes cavus, and the age of onset is somewhat later. Optic atrophy is fairly common.

Cerebellar ataxia also occurs in cerebellar tumours, in wounds or vascular lesions of the cerebellum, in disseminated sclerosis affecting the cerebellum or its peduncles, in cerebellar abscess, in encephalitis of the cerebellar cortex, an acute disease of febrile onset which is sometimes met with, chiefly in children; and it occurs occasionally in old age as the result of a primary senile atrophy of the cerebellar cortex, especially affecting the Purkinje cells.[1]

Olivo-ponto-cerebellar atrophy, described originally by Dejerine and Thomas, is a disease in which there is a primary atrophy of the cerebellar cortex, the bulbar olives, the grey matter of the pons, the middle cerebellar peduncles, and sometimes the restiform bodies. Clinically there is marked ataxia or asynergia of cerebellar type, usually with nystagmus. The disease does not run in families, and its onset is in advanced life, usually after the age of sixty.

Cerebellar ataxia or asynergia differs in several important respects from the ataxia due to deficient sensory impressions. There is no impairment of joint sense nor of kinæsthetic sense, as in the ordinary tabetic; in fact, in pure cerebellar disease there is no sensory impairment whatever.

A fundamental character of cerebellar ataxia is its *asynergia.* This consists in a want of synchronism at the different joints during a co-ordinated movement, so that the patient "decomposes" it into its separate elements. Thus, on performing the heel-knee test, instead of the hip, knee, and ankle becoming flexed simultaneously and harmoniously, the various joints move separately, lagging behind each other, so that the hip starts off with energetic flexion, whilst there is yet no appreciable flexion of the knee, the distal part of the limb remaining

[1] Rossi, *Nouvelle Iconographie de la Salpêtrière,* No. 1, 1907.

inert; then with a second movement he flexes the knee. Cerebellar asynergia is well seen in the typical *cerebellar gait* of diseases of the vermis, in which the patient, although his muscular power is unimpaired, cannot walk alone. When supported on both sides, he starts off with his lower limbs, with the characteristic over-action or hypermetria above described. Meanwhile his trunk, instead of inclining forwards, in harmony with the advancing legs, remains vertical, or even inclines slightly backwards, so that, when the advancing lower limb reaches the ground, the body as a whole lags behind and tends to fall backwards, *i.e.* there is relative inertia of the trunk during movement of the lower limbs. Hence the patient reels like a drunken man, yet without the stamping of the true tabetic. True cerebellar ataxia, unlike the ataxia of tabes dorsalis, is uninfluenced by closure of the eyes.

Rapid voluntary movements in cerebellar disease are, as Babinski has pointed out, badly estimated as regards their range (*mouvements démesurés*), so that the patient cannot arrest them at a given point. Thus when attempting the finger-nose test, the patient's finger reaches his nose but cannot be stopped there; the movement continues, and the finger pitches heavily on the nose, and may plunge past it on to the cheek. Similarly, in the heel-knee test, the heel overshoots the opposite knee, landing above the patella. Again, if the physician draws a vertical line on a sheet of paper and then asks the patient to draw a series of horizontal lines quickly across the paper (say from left to right), all stopping exactly at the vertical, the cerebellar patient overshoots the vertical line. Less commonly he under-estimates the range of movement required by the affected limb, and stops short before reaching the mark, finally swooping down on it with excessive force. The overshooting of the mark in cerebellar disease is termed *hyper-metria*. It is unaffected by closing the eyes, unlike tabetic ataxia.

A third characteristic of cerebellar unsteadiness is *dys-diadocokinesia*. This means the diminution or loss of the power to execute in rapid succession a series of antagonistic movements. If we make a patient perform a series of rapid alternate pronation-supination movements of the forearm, an individual with cerebellar disease performs the action twice or thrice as slowly as in health, the interval between the two alternate movements being prolonged.

In unilateral cerebellar disease we have *hemi-asynergia* and *hemi-hyper-metria* of the ipso-lateral limbs, most conveniently recognised by the heel-knee test, whilst the dys-diadocokinesia is also unilateral, being confined to the ipso-lateral upper limb.

Less frequently, in pure cerebellar lesions, chiefly in their later stages, we meet with *intention-tremors* similar to those of disseminated

sclerosis. (It is, in fact, probable that the intention-tremor of disseminated sclerosis is of cerebellar origin.) Intention-tremor is absent at rest, and occurs only on voluntary movement; the coarseness of its excursion depends on the extent to which the limb is outstretched. It is best demonstrated by making the patient pick up or touch a small object at a distance of an arm's length.

Ataxia also occurs in some affections of the higher **cerebral** centres. For example, there are certain *toxic* affections in which the patient becomes ataxic. The most familiar variety is that of acute alcoholic intoxication. Part of this ataxia may possibly be due to cerebellar intoxication, but a large part of it is cerebral, as evidenced by the "mental ataxia," the disordered articulation, etc. The temporary ataxia of *fatigue*, of writer's cramp and of other occupation neuroses is also probably of cerebral origin, so also is the transient ataxia which sometimes follows enteric fever or other exanthemata.

There are certain diseases of the cerebral cortex in which ataxia is distinct. In *chorea* the patient not only exhibits spontaneous involuntary movements, but he also has obvious ataxia on voluntary movement. In organic *monoplegia* or *hemiplegia*, especially when slight in degree and amounting merely to paresis, obvious ataxia often exists in the paretic limbs. Severe ataxia in the contra-lateral arm or leg is a common sign in some post-Rolandic cortical lesions, especially after bullet-wounds (see p. 483). Hemiataxia is one of the characteristic phenomena in lesions of the *optic thalamus*. In such cases the limbs on the side contra-lateral to the lesion are not only ataxic, but also partially anæsthetic with loss of joint sense, whilst spontaneous pains in the affected limbs are commonly present. Sometimes ataxia of the limbs precedes an attack of hemiplegia—*pre-hemiplegic ataxia*, especially in threatened softening from arterial thrombosis. More often the ataxia appears during convalescence from a slight hemiplegic attack—*post-hemiplegic ataxia*, when the patient has to learn the process of co-ordination again in his paretic limbs. This form of ataxia must be distinguished from athetosis, the involuntary slow writhing movements of the limbs which occurs in old and severe cases of hemiplegia, especially of infantile hemiplegia.

Ataxia is one of the most striking signs of **disseminated sclerosis**, where the unsteadiness of the limbs is often associated with a superadded coarse oscillatory tremor—the so-called intention-tremor. How much of the unsteadiness in disseminated sclerosis is due to cerebral and how much to cerebellar disease it is difficult to say in any individual case.

The tremor of hemiplegic distribution which is observed in the limbs in cases of *lesions of the red nucleus or rubro-spinal tract* (see p. 83)

is present at rest, but becomes exaggerated on voluntary movements, rendering them ataxic. In this respect it contrasts with the tremor of paralysis agitans, which can usually be controlled to permit of the performance of a voluntary movement.

Pseudo-sclerosis is a rare disease in which many of the clinical symptoms of disseminated sclerosis are present, including staccato speech, intention-tremors, and marked spasticity of the limbs. Its clinical phenomena resemble those of progressive lenticular degeneration (see p. 84). *Post mortem*, however, no sclerotic areas are detected in the central nervous system. In this disease there are certain additional features which help us to recognise the condition, notably a curious greenish pigmentation of the corneal margins, also shrinkage of the liver and enlargement of the spleen.[1] In pseudo-sclerosis, as in progressive lenticular degeneration, the abdominal reflexes are preserved, and the plantar responses are of the normal flexor type.

Finally, we may meet with ataxia of the most varied types in **hysteria.** Here the affection is one which implicates the highest psychical centres. The diagnosis of hysterical ataxia rests on the presence of other phenomena of hysteria, together with the absence of evidence of organic disease. Sometimes hysterical ataxia is associated with "cortical" anæsthesia of the affected limb. In such a case the patient may be able to move the limb normally with her eyes open, but when they are closed ataxia appears. This does not necessarily occur in every hysterically anæsthetic limb, for in many cases profound anæsthesia may be present without ataxia. The diagnosis of hysterical ataxia, however, seldom presents much difficulty to a careful observer. The disease which is most often mistaken for hysteria is disseminated sclerosis in its earlier stages. In both diseases we may have a history of transient weakness of a limb, apparently clearing up completely for a time. But in disseminated sclerosis there are objective evidences of organic disease in the form of pallor of the optic discs, nystagmus, alterations of the abdominal and plantar reflexes, sphincter trouble, and so on.

[1] v. Strümpell, *Neurolog. Centralblatt*, 1913, p. 1303.

CHAPTER XVII

POSTURES AND GAITS

Postures.—In health the posture of the body and of its various members is determined partly by gravity, partly by the relative strength of the muscles at the various joints. Therefore, inasmuch as the flexor muscles of our limbs are usually more powerful than the extensors, the ordinary posture of the limbs at rest is one of slight flexion. This is easily verified by observing a sleeping child. In the erect attitude the muscles of special importance in maintaining equilibrium are the extensors of the hips and knees. When standing on one foot the peronei are of particular importance, by inclining the whole lower limb outwards from the ankle upwards, and bringing the centre of gravity over the foot. The minor varieties of posture in different healthy individuals, which we learn to recognise as part of each man's personal characteristics, are largely the result of differences not only in muscularity, but of habit. The pose of a powerful, muscular man is widely different from that of a thin, debilitated invalid. Moreover, if from exercise, or want of exercise, certain groups of muscles are more or less developed than the normal, the posture is further modified, even in health. For example, we all know the characteristic straddling gait of the professional jockey.

Similar principles apply to those cases of organic disease in which certain muscles or groups of muscles are affected by paralysis. Paralysed limbs gradually assume characteristic postures, and these **postures of organic disease** are not matters of haphazard, but are determined by anatomical rules.

If the muscular paralysis be the result of a **lower motor neurone lesion,** in the anterior cornua, anterior nerve-roots, nerve-trunks or muscle-fibres, the paralysed muscles become wasted.

Sometimes the affected muscles undergo cicatricial contraction, and thereby fix the part in an abnormal posture. This is what occurs in ischæmic myositis, to which we have already referred (p. 231). It also occurs in **fixed** or **congenital torticollis** (which must not be confounded with spasmodic torticollis, described on p. 89). Congenital torticollis is due to shortening of one sternomastoid, resulting from an injury to the muscle during birth. The head deviates slightly to one side and cannot be turned, either actively or passively, towards the side of the

shortened sternomastoid. Unlike spasmodic torticollis, it is unaccompanied by active muscular spasm.

More commonly, in a case of lower motor neurone palsy, the unopposed non-paralysed antagonists slowly become contracted, and fix the limb in a certain definite posture which is best demonstrated if the

Fig. 124.—Chronic myelitis of fifth cervical segment, with atrophic paralysis of deltoid, biceps and supinators.

patient tries to throw the paralysed muscles into action, in which case the antagonists contract alone.

For example, Fig. 124 is a photograph of a woman who had a localised lesion in the anterior cornua of the cord at the level of the fifth cervical segment. Amongst the chief muscles supplied by the anterior cornua at that level are the deltoid, biceps and supinators. These muscles underwent atrophy and their unopposed antagonists became contracted. As a result we see that from paralysis of the deltoid and contraction of its opponents the shoulder is adducted,

similarly from paralysis of the biceps the elbow is extended by its opponents, and from paralysis of the supinators the forearm is hyperpronated by their antagonists. This posture is characteristic of a cord lesion at the fifth cervical segment.

Fig. 125 shows the posture assumed in a case of paralysis of the external popliteal nerve. This nerve was divided by a bullet-wound in an officer's right leg. In addition to anæsthesia corresponding to the cutaneous distribution of the nerve, the figure shows the presence of

Fig. 125.—Paralysis of external popliteal nerve of right leg, the result of a bullet-wound. Showing muscular atrophy and drop-foot. The patient is trying to dorsiflex both ankles.

foot-drop due to paralysis of the anterior tibial group of muscles, with unopposed contraction of the calf muscles. Here, of course, the action of gravity is a factor as well, for the weight of the foot tends to increase the foot-drop.

Fig. 127 shows the posture in a case of paralysis of the musculospiral nerve. The patient is trying to extend both his wrists. On the paralysed side we notice the atrophy of the supinator longus and the paralysis of the extensors of the wrist and fingers, also the characteristic swelling on the dorsum of the hand, probably bursal in origin, which appears in long-standing cases of drop-wrist.

Lower motor neurone lesions affecting the muscles of the hand produce certain highly characteristic postures:—

(1) The flattened-out, so-called monkey-hand (*main de singe*), in which there is a localised wasting of the thenar muscles with loss of the power of opposing the thumb, so that it falls backwards to the plane of the other digits. This is typical of median palsy.

(2) Claw-hand, or *main en griffe*, due to paralysis of the interossei and lumbricales, in which the fingers are now controlled by the long flexors and extensors alone. In this condition (most commonly resulting from palsy of the ulnar nerve below the level where it gives off its branch to the flexor profundus) the proximal phalanges become hyper-extended, whilst the two distal phalanges are flexed in a hook-like fashion. The deformity is more marked in the two ulnar fingers, since the lumbricales corresponding to the index and middle fingers (supplied by the median nerve) escape. Meanwhile the power of abducting the fingers by the interossei is lost.

FIG. 126.—Case of claw-hand from rupture of first thoracic root, following a dislocation of the right shoulder. Note the atrophy of intrinsic muscles of the right hand; also the pseudo-ptosis on that side, due to affection of cervical sympathetic.

(3) The preacher's hand (*main de prédicateur*), specially common in syringomyelia. In this variety, from survival of the long extensors, the hand is extended, or even hyper-extended, at the wrist.

The loss of the movements of adduction and abduction in the extended fingers, due to interosseal paralysis, develops when the "*main de singe*" becomes the "*main en griffe.*" As a matter of fact, these three positions of the hand occur in lesions not only of the anterior cornua (as in progressive muscular atrophy, syringomyelia, amyotrophic lateral sclerosis), but also in anterior radicular lesions, in lesions of the lower roots of the brachial plexus (see Fig. 126), in toxic or infective neuritis, in leprosy, in family neuritic diseases like peroneal muscular atrophy and progressive hypertrophic neuritis.

If the paralysis be due to an **upper motor neurone lesion,** the law which determines the posture is different. We no longer have atrophic paralysis, limited to a particular muscle or muscles, as in a lower motor

neurone lesion. Instead, there gradually develops a spastic paralysis, in which all the muscles of the affected limb or segment of a limb are more or less paralysed and in a state of hyper-tonus.

The condition is best studied in the lower limbs. There are two distinct clinical types of spastic paralysis, described by Babinski as "paralysis in extension" and "paralysis in flexion" respectively. The essential difference between these two types, as Walshe has shown,[1] is that in the "extended" form of spastic paralysis both extensor and flexor groups of muscles are in a state of exalted reflex activity, whereas in the "flexed" type only the flexor group of muscles retains this, the extensors showing diminished or absent reflex action.

Fig. 127.—Left-sided musculo-spiral paralysis. Showing drop-wrist and atrophy of supinator longus.

The *extended type of spastic paralysis* only occurs in pure pyramidal affections, as in ordinary hemiplegia and in pure lateral sclerosis of the spinal cord. Thus in a chronic hemiplegia the familiar posture of the upper limb is that of flexion with pronation, that of the lower limb being one of slight extension at the hip and knee, with plantar flexion and inversion of the ankle, and a tendency to dorsiflexion of the toes (see Figs. 128 and 128A), the limb as a whole thus becoming outstretched or lengthened. In the spastic limbs all the deep reflexes are increased, and there is a Babinski plantar response on stimulation of the sole.

The *flexed type of spastic paraplegia* (see Fig. 129) occurs only in diffuse spinal lesions, never in pure pyramidal disease. The posture of the lower limb is one of flexion of the hip and knee, with dorsiflexion

[1] *Brain*, 1914, vol. xxxvii., pp. 269–336.

of the ankle, the whole limb being pulled up or shortened. In this type of contracture the knee-jerks and ankle-jerks are feeble or absent, and there is no ankle-clonus. Nevertheless the hamstring-jerks are found to be excessively brisk. Frequent involuntary flexor spasms occur in the paralysed limb, temporarily exaggerating its flexed posture. The Babinski plantar response is present. To produce this flexed type of spastic paraplegia, the interruption of some other

FIG. 128. FIG. 128A.

Case of left-sided infantile hemiplegia in a patient aged 7 years. Onset of hemiplegia five years previously. Showing posture of limbs. In Fig. 128 note athetosis of left fingers. In Fig. 128A note inversion of ankle and drawing up of heel.

efferent tract, in addition to the pyramidal tract, is essential (see "sub-cortico-spinal tracts," pp. 10-12). The effect of such a lesion in the extra-pyramidal motor path is to abolish the reflex tonus in the paralysed extensor muscles without affecting the reflex activity of the paralysed flexor group.

The spastic posture in hemiplegia does not come on at once. There is an initial flaccid stage, lasting several weeks or even months, before the spastic rigidity sets in. (In a small number of cases the hemiplegia may remain permanently flaccid.) But even during this flaccid stage

the postures of the hemiplegic limbs are often different from those of the unaffected side at rest. One of the most characteristic signs is an apparent broadening of the lower limb (Heilbronner's[1] "*breites Bein*"). This consists in an outward rotation of the lower limb at the hip-joint, due to its own weight when in the recumbent posture (analogous to the displacement which occurs in fracture of the neck of the femur). The thigh, therefore, when looked at from the front, appears broader than on the healthy side. Moreover, the flaccid paralysed muscles fall back by their own weight, and on transverse section the thigh forms a flattened oval instead of an approximate circle as on the healthy side. This apparent broadening of the paralysed thigh can be well seen if the patient be seated on a hard, flat seat. It does not occur in hysterical hemiplegia.

FIG. 129.—Transverse softening of the spinal cord, producing flexed type of spastic paraplegia.

In **hysterical paralysis** the conditions are different. Hysteria, it is often said, may simulate organic disease—thus we may have functional hemiplegia, paraplegia, or monoplegia. But if we examine carefully we usually find that this similarity is more or less rough and inaccurate. And why? Because hysterical contractures are not governed by anatomical rules ensuring the preponderance of the stronger muscles. Hysterical contractures usually present some points in which they differ from the postures of genuine organic lesions. Thus, for example, we do not have loss of deep reflexes nor muscular atrophy with R.D. as in lower motor neurone lesions; nor do we have an extensor plantar reflex nor a true clonus as in genuine pyramidal disease. Moreover, if hysterical hemiplegia affects the face we have, not a true paralysis, but a glosso-labial hemispasm. Figs. 130 and 131 are from a case of functional hemiplegia, in which the contracture alone was enough to distinguish it from an organic case. Instead of the usual flexed and

[1] *Deutsche Zeitschrift für Nervenheilkunde*, Bd. 28, 1904, s. 1.

pronated posture of the upper limb, we observe that the elbow and wrist are extended, the forearm is supinated, and the fingers are half-bent in a hook-like fashion, whilst in the lower limb the inversion of the ankle is overdone, out of all proportion to the ordinary equinus

FIG. 130.

FIG. 131.

From a case of right-sided hysterical hemiplegia in a left-handed patient. Showing contractures of hand and foot. The right forearm was rigidly supinated, but is being passively semi-pronated by the physician to show the posture of the hand.

position. The contracture in this patient appeared suddenly, as is so often the case in hysteria, unlike the gradual development of an organic contracture. Fig. 132 shows a peculiar contracture of the soles

FIG. 132.—Hysterical paraplegia. Showing longitudinal fold of soles.

in another case of hysterical paraplegia, in which the feet had a fold running longitudinally along the soles, totally unlike any organic contracture.

Fig. 133 shows a case of left-sided hysterical hemiplegia, in which the contracture of the upper limb differs from that of organic disease; for whilst the shoulder, elbow and wrist are rigid, the fingers are flaccid

—a combination which does not occur in organic hemiplegia. We also observe that this patient has glosso-labial hemispasm. When she protrudes her tongue it deviates considerably to the paralysed side, but in such an exaggerated fashion that it is easy to recognise the deformity as spasmodic, not paralytic. We also note that, when the tongue is protruded, the face on the paralysed side goes into a state of spasm, so that the left naso-labial fold is deeper than on the healthy

FIG. 133.—Left-sided hysterical hemiplegia with glosso-labial spasm on protrusion of tongue. The left upper limb was also rigidly contracted at the shoulder and elbow, the hand being flaccid.

side, a condition which is the reverse of what we find in organic hemiplegia. *Glosso-labial hemispasm* such as this is not a common sign, but when it occurs, it is pathognomonic of hysteria.

One of the commonest types of traumatic war-hysteria is the characteristic *hysterical spinal curvature*:—so-called ***campto-cormia***, or *anti-algic spondylosis*, in which the patient holds his trunk stiffly bent forwards at the lumbo-sacral region, almost to a right angle, sometimes symmetrically, sometimes inclined to one or other side. The trunk is

almost horizontal, but the neck is usually bent backwards, so as to raise the head to the erect posture, with fixed facial expression and widely-staring eyes. Notwithstanding this deformity of the trunk, walking is usually easy, although the patient makes use of a stick or even a pair of sticks. Usually, but not always, the spinal deformity disappears on lying down. If the patient is told to stand up straight, he fails to do so, although he makes violent and dramatic muscular efforts with his spinal and abdominal muscles. Attempted passive reduction of the spinal deformity is energetically resisted, and, if persevered with, the patient becomes acutely emotional, with rapid heart, rapid respiration, a facies of terror and with severe lumbo-sacral pain.

Fig. 134.—Hyper-extension of knees in a case of tabes—"*genu recurvatum.*"

Hysterical spinal curvature comes on acutely. It usually follows some sudden fall or blow on the back, *e.g.* after a shell-explosion, whereby the soldier is thrown violently to the ground: he may even be temporarily concussed. Immediately on recovering from his mental confusion, he complains of pain in the lumbo-sacral region, somewhat alleviated by bending forwards, and aggravated by any attempt to straighten the trunk. This vicious posture becomes perpetuated by auto-suggestion, so that the muscular spasm persists long after the original organic cause of pain has passed away.

Hysterical contractures often, but not always, disappear during sleep or during deep anæsthesia. Even in the waking state we may occasionally succeed in momentarily correcting the vicious attitude if we take the patient unawares during the course of our examination. Further, we sometimes observe, when approaching the hysterical patient, that the muscles of his contractured limb tighten up under the skin, as if on guard against a possible attempt at passive movement, and we may also observe that this excessive spasm relaxes when the patient's attention is diverted to some other part of his body. If a hysterical contracture has persisted for months, adhesions may form in and around the joints, so that even under an anæsthetic the contracture may not completely relax, and we may have to break down the adhesions forcibly.

The postures of organic paralyses, then, whether supra- or infra-nuclear, are definite and comparatively simple, being governed by the anatomical rules we have mentioned. Hysterical postures, on the other hand, being under no such restrictions, may assume the most varied and weird appearances, examples of which might be multiplied indefinitely. Whether spastic or paralytic, the motor phenomena of hysteria are usually "systematised." As Babinski has pointed out, they merely affect one or more "systems" of voluntary movements which the muscles of the face or of a limb are called on to perform. Hysterical postures are caricatures or exaggerations of some spastic or paralytic posture, which, however, never corresponds in distribution to a

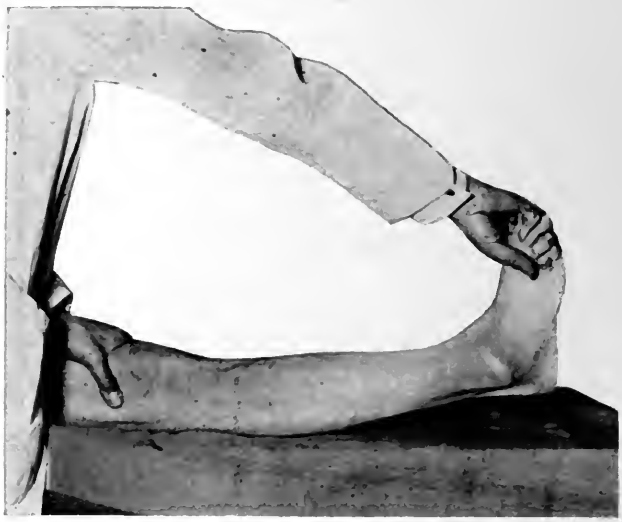

FIG. 135.—Tabetic hypotonia of popliteal muscles.

peripheral nerve nor to a spinal segment, but to some well-recognised attitude. Therefore a hysterical paralysis or a hysterical contracture can always be imitated, whereas an organic contracture is never accurately imitated by a hysterical patient.

In many cases of lesion of the posterior roots or posterior columns, *e.g.* in tabes dorsalis, there is marked deficiency of muscular tonus, a condition known as **hypotonia.** This slackness of the muscles has a remarkable influence on the patient's postures. Thus, for example, hypotonia of the peronei increases the difficulty of standing, since, whenever the patient lifts one leg, the other fixed leg is no longer pulled outwards as in health to bring the centre of gravity over the fixed foot. When the hamstrings and sural muscles behind the knee are hypotonic (see Fig. 134), the joint becomes hyper-extended in the

erect posture—the so-called "genu recurvatum"—unlike the knee-joint of a healthy individual, in which, however strongly the knee be extended, there always remains a concavity behind. This hypotonia of the popliteal muscles produces another very characteristic sign of tabes, which is that, when the patient lies in bed with the knee extended,

FIG. 136.—Tabetic hypotonia of gluteal and hamstring muscles.

the heel can be passively raised whilst the back of the knee remains in contact with the bed (see Fig. 135). Hypotonia of the muscles of the trunk and lower limbs, in tabes, may permit of the patient assuming

FIG. 137.—Tabetic hypotonia of muscles of lower limbs and trunk.

the most extraordinary postures without pain—postures which are impossible to any ordinary individual who is not a professionally trained contortionist (see Figs. 136, 137 and 138).

Hypotonia is met with in recent, acute cerebellar lesions, *e.g.* after bullet-wounds, vascular lesions, or acute encephalitis, being most marked

in the muscles of the ipso-lateral limbs (see p. 24). Cerebellar hypotonia is less profound than tabetic hypotonia, and after a few weeks tends to subside.

A slight degree of hypotonia is present in ordinary chorea.

Muscular hypotonia also occurs in some cases of reflex paralysis, following local trauma of a limb (see p. 242). In such cases the

FIG. 138.—Tabetic hypotonia of adductor muscles.

hypotonia is limited not merely to the affected limb, but is further localised to some particular group of muscles, and is often combined with hypertonia, or spasticity, of other muscle-groups in the same limb,

FIG. 139.—Amyotonia congenita in a child of 2½ years, showing inability to sit up.

e.g. hypotonia of the extensors of the wrist combined with hypertonia of the flexors of the elbow.

Amyotonia congenita (sometimes, though less aptly, called *myatonia congenita*) is a condition of extreme flaccidity of the muscles, which are soft and lax on palpation. When thrown into voluntary contraction they do not harden like ordinary muscles, and it may be impossible by palpation to distinguish them from the subcutaneous tissues. The

joints are flail-like, and can be placed in all sorts of fantastic postures (see Fig. 139). There is no true motor paralysis, although voluntary movements are devoid of vigour. The amyotonia is most marked in the lower limbs. The sphincters are unaffected. The electric excitability is diminished both to faradism and to galvanism, but without polar changes. The child can bear strong faradic stimulation with unusual stoicism. The deep reflexes are absent, whilst the cutaneous and organic reflexes are normal. The condition, which is congenital, is really a variety of myopathy. The phenomena are usually detected within the first twelve months after birth. Sometimes the symptoms improve, and the deep reflexes may even return, but the patient never attains normal muscular power. Pathologically the muscles show changes identical with those found in primary myopathy.

Gaits.—Unlike some of the lower animals—for example, the chicken or the lamb—the human infant at birth cannot stand or walk. It is not until the child reaches the age of about eighteen months that he begins to walk. First he learns to stand, and then after repeated efforts he succeeds in walking. During the process of learning, he reels and falls about just like an adult with cerebellar disease.

We do not all of us walk exactly in the same fashion. Even healthy individuals show minor differences in gait. An old man walks differently from a youth, a soldier differently from a sailor, and a woman advanced in pregnancy differently from a maiden. The wearing of ordinary boots with artificial heels also modifies the gait, so that in health the first part of the boot to show signs of wear is usually the back of the heel on the outer side. Ladies' high-heeled boots modify the gait still more, throwing the weight of the body unduly forwards towards the heads of the metatarsal bones.

When testing the gait in cases of nervous disease it is advisable to have the patient's lower limbs well exposed, and without boots. To get a good view of the limbs it is well to have a minimum of clothing on the patient. If we cannot have him *in puris naturalibus*, a good plan is to have him clad in some light garment like a shirt, whose tail is pulled forwards between the legs from behind and pinned in front, thereby leaving the upper limbs free. We ask the patient to walk straight away from us towards some given point, then to turn round and come back.

In a **normal gait** the limbs are moved forward easily, the feet neither scraping the ground whilst being lifted, nor being unduly stamped down as they descend. The forward-moving or "active" leg is the one which carries the weight of the body. The trunk and pelvis therefore lean a little towards the corresponding side during the "active" phase of each limb. This trunk movement is attained partly by the

action of the gluteal muscles, partly by the sacro-lumbar muscles of the same side. A short, thick-set person with a broad pelvis tends to have a "waddling" gait, as the weight of his trunk is shifted across from one side to the other. When the gluteal muscles are weak, the patient waddles excessively in his efforts to throw his weight to each side alternately.

The gait is altered in various diseases. Thus it may become spastic, ataxic, reeling, high-stepping, and so on.

Fig. 140. — Spastic diplegia. Showing "scissor-gait" and conjugate automatic movements of the upper limbs.

A **spastic gait** occurs in lesions of the pyramidal tract —for example, in hemiplegia, in diplegia, and in spastic paraplegia. In *organic hemiplegia* the active forward projection of the limb is especially difficult on the paralysed side, and the weight of the body has to be carried forwards by the aid of the other side *plus* gravity, unlike the normal gait in which the weight is carried entirely by the "active" advancing leg. Thus when the hemiplegic leg ought to be in the "active" phase, it is not properly flexed at the knee or ankle, nor is it actively pushed forwards, but merely dangles forward like a pendulum, not directly forwards, but swinging in a circular fashion round the opposite hip as on a pivot. When the "active" phase of the non-paralysed limb occurs, the hemiplegic foot (owing to weakness of the peronei and dorsiflexors of the ankle, with over-action of the invertors and calf muscles) stays on the ground too long, thereby scraping the front part of the foot, especially the ball of the great toe (see Fig. 141); the stride of the paralysed limb is therefore shorter than on the healthy side. In a case of *spastic diplegia*, or double hemiplegia, the patient is unable to project either leg forwards in the ordinary way, but has to jerk each forwards in turn with a circular swing, so that, in a well-marked

case, not only does the patient take abnormally short steps, catching the ball of each foot on the ground, but from the circular swing of the limbs, together with their adductor spasm, they cross alternately in front of each other, producing the cross-legged or "scissor" gait (see Fig. 140). Meanwhile the trunk and upper limbs make violent jerky movements, swinging the body from one side to the other. A milder degree of diplegic gait often occurs in old people who have had attacks of *lacunar hemiplegia* on both sides of the brain. In such cases the gait



FIG. 141.—Footprints in a case of right hemiplegia. Showing scraping of anterior part of foot.

shows an abnormal shortening of the stride (*"marche à petits pas"*) without actual scissor-gait.

There is a rare *atonic-astasic* type of cerebral diplegia, occurring in children, and characterised by generalised muscular hypotonia, with inability to walk, stand, or even sit up without support. It is usually accompanied by definite mental deficiency. Nevertheless, there is no actual paralysis: the deep reflexes and electrical reactions are normal, thereby distinguishing the condition from amyotonia congenita. Pathological examination of these cases has shown extensive sclerosis of the frontal lobes.

In ordinary *spastic paraplegia* from cord disease there is not the cross-legged gait of diplegia, but the patient moves stiffly along, taking abnormally short steps, the front part of the feet clinging to

the ground, thus wearing out the toes of the boots. Meanwhile the tendency to ankle-clonus causes a "trepidation" of the whole body in severe cases from tremor of the feet. Such a patient stumbles over the slightest obstacles.

The **gaits of hysteria** are of the most varied types. For example, in hysterical hemiplegia the patient often pushes the paralysed foot along the ground as if on a skate (see Fig. 145), or drags it helplessly along with its dorsum resting on the ground, as seen in Fig. 142. If this is bilateral, the patient is totally unable to walk or stand. Or the foot may be held in a position of talipes calcaneus, or the patient may walk on the outer border of the foot (see Fig. 147) when walking, even when no such posture is present at rest; or one lower limb may be acutely flexed at the hip and knee, so that the patient has to use crutches.

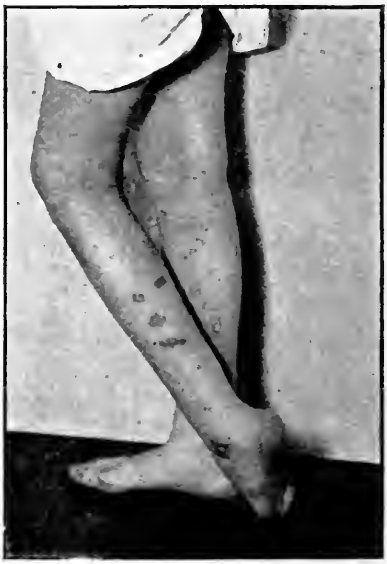

FIG. 142.—Gait in a case of left-sided hysterical hemiplegia. The marks on the left leg are scars of self-inflicted burns

Or, again, the patient may have a zigzag gait (see Fig. 146), or he may throw one leg about with a wild flourish before bringing it to the ground, or may suddenly kneel down every few steps—these are tics of gait.

Astasia- abasia is the term applied to a condition in which a hysterical patient is unable to stand or walk, although capable in the recumbent posture of performing all movements of the lower limbs normally. The varieties of hysterical gaits are practically unlimited, but every one of them differs in some respect from the gait of organic disease.

Staso-baso-phobia is a psychasthenic obsessional state in which the patient is acutely afraid of attempting to stand or walk, and displays violent emotional phenomena when asked to try (see later, p. 391).

The *side-gait* (Schüller's "*Flankengang*") is a useful means of diagnosing between organic and hysterical hemiplegia. To test it, the patient is placed on a line and made to move along it sideways in a given definite direction—say towards the right. A normal individual, during this movement, first leans his trunk to the left, then balancing his weight on the left leg, he lifts the right from the ground, abducts

it by a muscular effort, brings the trunk erect again, puts down the right foot, last of all lifting the left leg, adducting it and placing it alongside the right. How is this performed in organic hemiplegia? We find that the hemiplegic patient moves sideways towards the paralysed side well, but badly towards the healthy side, so that in right-sided hemiplegia the patient, when going sideways towards the right, moves normally, but when going towards the left he drags his right leg

Fig. 143. Fig. 144.

Fig. 143.—Spastic diplegia.

Fig. 144.—Footprints from the case of spastic diplegia shown in Fig. 143. The patient's heels do not touch the ground, and the feet as they are lifted are scraped forwards.

in the movement of adduction. This difference in the side-gait on the two sides in organic hemiplegia is often quite evident when the forward gait shows very little abnormality. To show the phenomenon properly, the patient must not be too severely paralysed to stand or walk, nor must he have shortening of the limb, as in old infantile hemiplegia. These two exceptions, however, are readily recognised by other signs. In hysterical hemiplegia the side-gait is impaired on both sides, not merely on the healthy side.

An **ataxic gait** is seen most typically in tabes dorsalis; but it occurs

also to a lesser degree in other diseases implicating the posterior columns of the cord—for example, in Friedreich's ataxia, in chronic meningo-myelitis, or in tumours of the posterior columns, also in ataxic paraplegia or postero-lateral sclerosis, whether due to disseminated sclerosis or to other causes. Of all these, the tabetic gait is the most characteristic. In this there is no motor weakness of the limbs, but they are characteristically unsteady. The patient walks on too broad a base, with his legs unduly wide apart. He lifts them suddenly and violently,

FIG. 145.

FIG 146.

FIG. 145.—Footprints from a case of right-sided hysterical hemiplegia, in which the right foot is pushed along the ground, whilst the left foot is lifted normally.

FIG. 146.—Footprints in a hysterical gait. The patient walked unsteadily, occasionally throwing the right lower limb behind her, causing her to pause momentarily. During this phase she sometimes lurched to the left, then recovered herself and tottered on again.

raising them too high, then bangs them down forcibly in flail-like fashion, stamping the heels on the ground. He tries to guide his tottering course by watching the ground. Therefore if his eyes be shut, or if he be in the dark, and especially if he narrows his base by placing the feet close together, he tends to fall. In slight cases of tabetic ataxia, when the patient is in this position, he may not actually fall, but we can see the tendons on the dorsum of the feet actively in movement, in the effort to preserve the balance. With this gait we usually

have absence of the knee- and ankle-jerks, and various other signs, such as Argyll-Robertson pupils, lightning pains, anæsthesiæ, crises, and lymphocytosis of the cerebro-spinal fluid. In *Friedreich's ataxia* the patient is commonly an adolescent, and though the knee- and ankle-jerks are absent, as in tabes, the pupils react normally, there are no lightning pains nor crises, and we usually find nystagmus, scoliosis, pes cavus, and a peculiar affection of articulation. In *ataxic paraplegia* or *postero-lateral sclerosis*, where the lateral columns are implicated as well as the posterior, the patient is ataxic, but with increased knee-jerks, possibly ankle-clonus, and usually an extensor type of plantar reflex.

Fig. 147.—Gait in a case of hysterical monoplegia of right leg.

A **reeling** or **titubating gait** is one of the commonest signs of *cerebellar disease*, although it is also met with in severe vertigo of any variety, whether from alcoholic intoxication, from ear disease, from diplopia, or other cause. In cerebellar disease the patient staggers along, with an occasional sudden lurch to one or other side, but neither lifting his feet too high nor stamping them down, as in tabes. Unlike tabes, cerebellar ataxia is unaffected by closing the eyes. Not uncommonly the cerebellar patient has a tendency to stagger persistently in some particular direction, depending on the position of the cerebellar lesion —thus he may tend to fall forwards, backwards, or to one side. In unilateral cerebellar lesions the foot on the ipso-lateral side is set down irregularly and incorrectly, hence the tendency to stumble towards the affected side. As a rule, he manages to pull himself up after he has deviated one or two steps from his straight course. In some cases of unilateral tumour of the cerebellum, in the region of the vesti-

bular nerve, the posture of the head is altered, the ear being tilted towards the shoulder on the side opposite to the lesion, and the face turned slightly in the reverse direction, *i.e.* towards the side of the lesion.

This is well seen in Fig. 148, which represents a woman who had a tumour originating from the meninges over the right petrous bone, and invading the right lateral lobe of the cerebellum. This growth was successfully localised and removed, but the patient unfortunately died shortly after.

FIG. 148.—Case of right-sided extra-cerebellar tumour arising from sheath of auditory nerve, showing "vestibular attitude" of head.

This "*vestibular attitude*," however, although common in lateral tumours, is not constant in its direction. For example, cases have been recorded in which the lateral tilting of the head was towards the side of the lesion, and the rotation of the face to the opposite side.

A **high-stepping gait** occurs in patients who have foot-drop. Such a patient, to clear his foot from the ground, lifts the leg too high, flinging the ankle up, as it were, instead of actively dorsiflexing it. This gait occurs typically in *peripheral neuritis*, also in *muscular dystrophies*, and occasionally in lesions of the *cauda equina* or lower part of the *lumbo-sacral region of the spinal cord*. It also occurs unilaterally in paralysis of the *external popliteal nerve*. The gait and posture of muscular dystrophy also possess other characteristic features. Thus from weakness of the gluteal muscles the patient, in the erect posture,

arches his back, in order to keep the hips extended (see Fig. 149); this produces lordosis and "pot-belly." Further, the weakness of the glutei, as already explained, causes a waddling gait, the legs being planted wide apart; and as we have already seen, the mode of rising from the ground in such cases is pathognomonic. Such a patient when placed on the ground and told to get up, rolls round on his face, then gets on his hands and knees. Then to get on his feet, he extends the knees, and suddenly, pressing his hands on one knee after the other, proceeds to extend the hips and straighten the

Fig. 149.

Fig. 150.

Fig. 149.—Muscular dystrophy in a lad of 17. Showing lordosis.
Fig. 150.—Muscular dystrophy with frog-like posture and gait.

spine by "climbing up" his own thighs until he reaches the erect posture.

In the later stages of muscular dystrophy, when the patient has lost the power of standing erect, he may still remain able, for a time, to get about with a characteristic **frog-like gait**, walking on his fingers and toes.

Fig. 150 is an example of the frog-like gait in a man of 26, with advanced myopathy, chiefly in the lower limbs. He was first noticed to walk badly at the age of 10, but until the age of 24 he was able to get about with

sticks, keeping his back arched, like an ordinary myopathic lordosis. He then rapidly got weaker in the extensors of the hips and knees, and these latter joints became contractured in the flexed position, so that he could only get about by resting his weight on the tips of the fingers and on the heads of the metatarsal bones.

In some cases of peripheral neuritis without muscular paralysis, but with acute hyperæsthesia of the soles, the patient cannot bear to

Fig. 151.—Case of peripheral neuritis from "trench-feet," with hyperæsthesia of soles.

support his weight on the feet. Standing and walking are therefore, for a time, impossible. When recovery sets in, the patient passes through a stage during which he stands and walks on the heels only, keeping the front part of the feet carefully off the ground (see Fig. 151).

The posture and gait of *paralysis agitans* are diagnostic, so much so, that patients have a strong family resemblance (see Figs. 152 and

153). In a well-marked case the patient stands with the trunk stooping forwards, the face appearing rigid, "starched," and expressionless—the so-called "Parkinsonian mask," in which there is little or no emotional play of features. The blinking reflex of the eyelids occurs much less frequently than normal, so that the patient has a characteristic stare. The upper limbs are slightly abducted at the shoulders, semi-flexed at the elbows, slightly extended at the wrists, flexed at the metacarpo-phalangeal joints, and extended at the inter-phalangeal joints, as if holding a pen—the "interosseal" attitude—and very often they show the familiar rhythmic, "pill-rolling" tremor. This tremor may affect the proximal joints as well, and even the lower limbs, face, jaw, palate and tongue. All the voluntary movements of the trunk and limbs are slow and stiff, the upper limbs no longer "swing" as the patient walks (in unilateral cases this loss of swing is confined to the arm of the affected side) and the gait is "festinant." The patient has to walk under the guidance of his cerebral and cerebellar mechanisms, being deprived of the normal assistance of the corpus striatum, and especially of its pallidal system. He moves forward with short, shuffling steps, and when he turns, his trunk moves slowly *en masse*, as if made of glass, whilst his steps in walking tend to get faster and faster, as if he were "chasing his own centre of gravity." This is called "propulsion." Still more frequently do we observe "retropulsion," in which the patient, when pulled gently from behind, tends to run backwards with short, hasty steps. This retropulsion may sometimes be induced even by the act of looking upwards. A slighter degree of this same posture and gait is not uncommon in simple old age, and may also occur in pseudo-bulbar paralysis and in the multiple lacunar softenings of the brain described by Marie and Ferrand (p. 277).

FIG. 152. — Paralysis agitans—bilateral.

The gait in *chorea* is sometimes peculiar, partly owing to a degree of ataxia, partly from the presence of additional irregular involuntary movements. Sometimes one foot seems as if it were momentarily entangled by an invisible obstacle, which holds the child back for an instant, the patient then hastily resumes his forward progress; or his knee may give way suddenly, causing him to fall.

Many chronic *epileptics* have a peculiar slouching posture and gait, the posture of the hands, as Spratling[1] has pointed out, being specially

[1] *New York Medical Journal*, 1905, p. 849.

characteristic. The fingers are habitually flexed, and the wrists bent to a right angle, and the patient often has a marked forward stoop of the shoulders.

FIG. 153.—Paralysis agitans—bilateral. Showing the fixed stare, the tonic contraction of the sterno-mastoids, and the characteristic posture of the upper limbs.

Various *deformities* produce abnormalities of gait and posture. If, for example, one lower limb is shortened from disease of the bones or joints, from malformations such as coxa vara or congenital dislocation of hip, or from infantile paralysis, the gait becomes correspondingly altered.

CHAPTER XVIII

TROPHO-NEUROSES

The central nervous system exercises a profound influence on the nutrition of all the tissues. There is, however, no evidence of the existence of special nerves whose function is trophic and trophic only. The control over nutrition which the nervous system possesses is probably exercised in a complex fashion, in which several factors are involved. Striated muscle, for example, undergoes atrophy when the cells of the corresponding motor nucleus in the cord or medulla are destroyed, or when the motor nerve-fibre leading from the nerve-cell to the muscle-fibre is interrupted. The result is muscular atrophy, the different varieties of which we have already studied (see p. 216).

Afferent nerve-fibres conveying sensory impressions, whether conscious or subconscious, have also a profound influence upon tissue-nutrition, especially upon that of the skin and its appendages. Therefore in anæsthetic skin-areas trivial injuries are liable to produce destructive tissue-changes. Lastly, the central nervous system indirectly influences the tissues through their blood-supply by means of its connections with the vasomotor system. The vegetative system may also be disordered primarily, apart from the central nervous system, not only in gross lesions of the sympathetic chain, but also in the so-called angio-neuroses.

Excluding, then, the muscular atrophies and the angio-neuroses, which are studied elsewhere, let us direct our attention to certain trophic disorders which are associated more or less directly with affections of the cerebro-spinal nervous system. Trophic disorders may be distributed widely all over the body, or they may be limited to certain circumscribed areas corresponding to a peripheral nerve, to a posterior root, or to some division of the spinal cord or brain.

Generalised Trophic Disorders.—Of these, one of the best examples is the well-known **anorexia nervosa.** In this affection, without evidence of structural disease of any organ, the patient (generally a young woman) loses appetite and becomes progressively emaciated, often to a profound degree. The condition sometimes follows a shock, physical or emotional, perhaps an *affaire du cœur*, though in other instances we can find no apparent exciting cause. In diagnosing this condition,

we have first to exclude other conditions, such as diabetes, tuberculosis, and malignant disease, which commonly produce emaciation. The patient generally exhibits other hysterical phenomena. Of these, perhaps the most frequent is a hemi-anæsthesia, usually slight in degree and generally left-sided (see later, p. 375).

In marked contrast to this is the rare affection known as **adiposis dolorosa**, or Dercum's disease, probably due to disorder of the endocrine glands. It occurs chiefly in middle-aged women, many of the patients being alcoholic or syphilitic. The patient is diffusely obese,

Fig. 154.—Adiposis dolorosa in a woman of 37.

and, in addition, she has localised fatty lumps in the subcutaneous tissue, forming large pendulous swellings, chiefly on the limbs and trunk. These swellings may be symmetrical or asymmetrical. They appear and steadily increase in size, and consist of fat and of an embryonic form of connective tissue. The arms are most frequently the sites of the swellings, which are usually tender on pressure and may have spontaneous pains. Certain areas, such as the hands, feet, and face, are always spared. The nerve-trunks are tender, and there may be areas of blunting or loss of cutaneous sensibility. Sometimes the pituitary and thyroid glands are indurated, but the patient has none of the mental or physical features of myxœdema, though she often complains of mental lassitude and muscular asthenia.

A curious condition of the bones results from hypertrophy or functional over-activity of the anterior lobe of the pituitary gland.[1] Hyper-secretion by this gland sets free in the body certain abnormal substances whose action is to cause an extraordinary growth of bony tissues. If the disease sets in before the age at which the epiphyses have become joined, the bones grow enormously in all their dimensions, and

FIG. 155. FIG. 155A.

Acromegaly of eight years' duration in a man aged 42. The patient had bi-temporal hemianopia.

the result is **gigantism.** But if the affection begins after the epiphyses have united, the overgrowth of the bones is confined to their ends, producing acromegaly.

The phenomena of **acromegaly** are very characteristic (see Figs. 155 and 155A). There is a progressive enlargement of the bones and soft

[1] Acromegaly cannot be ascribed, as was formerly thought, to deficient pituitary secretion, for as Tamburini and Modena have pointed out (*Rivista sperimentale di Freniatria*, 1903, fasc. 3 and 4), experimental destruction of the gland does not cause acromegaly, nor do malignant growths nor tuberculous disease of the gland produce it, but only conditions such as hypertrophy or adenomatous hyperplasia.

parts, most marked in the hands and feet, but also affecting other parts, notably the skull and face. The skull becomes enlarged and thickened, all its bony ridges are exaggerated; the margins of the orbits, the cheek-bones, and most striking of all, the lower jaw, become enlarged. The mandible becomes prognathous, the lower teeth biting in front of the upper, instead of *vice versâ*, and the teeth become widely separated. The soft parts also share in the hypertrophy. The lower lip, nose, tongue, uvula, tonsils, and the cartilages of the ears, all become en-

FIG. 156.—Left-sided hemi-hypertrophy.

larged, and the skin of the face becomes thick and coarse. The hands and feet increase in size (not the nails), so that the patient requires gloves and shoes several sizes larger than before. Spinal curvature is also present, usually a cervical kyphosis, and the thorax, pelvis, and even the external genitals become enlarged.

In addition, we meet with symptoms referable to disorder of the posterior lobe. Thus in the early stage of super-pituitarism there is often a spontaneous glycosuria, whereas in the later stage, when symptoms of sub-pituitarism supervene (low blood-pressure, dry skin,

subnormal temperature), there is found a high sugar-tolerance (see p. 25), so that excessive amounts of glucose, 400 grammes or more, can be taken without inducing an overflow glycosuria. In female patients amenorrhœa occurs.

In addition to these phenomena the acromegalic patient complains of severe headaches, owing to the intra-cranial pituitary tumour. This tumour, from its position in the *sella turcica*, frequently encroaches on the adjacent optic chiasma, and then there is produced a corresponding affection of the visual fields (see p. 121) usually commencing as a bi-temporal hemianopia, which may, as the disease advances, progress to complete blindness.

Apart, however, from pituitary disease, which, strictly speaking, although intra-cranial, is not primarily a nervous disorder, we sometimes have widespread overgrowth of the tissues, confined to one half of the body and probably of cerebral origin. Fig. 156 represents such a patient with left-sided *hemi-hypertrophy*, in whom all the bones of the left side (as verified by skiagrams), including those of the face, limbs, pelvis and thorax, together with the soft tissues of the face, tonsil, tongue and testicle, were larger than on the right side. But the right side of the cranium, and presumably also the right side of the brain, were larger than the left.

Passing next to trophic disorders of more limited distribution, it is convenient to discuss them in certain groups.

Trophic Changes in the Skin and its Appendages.—Complete section of a cutaneous nerve is often followed by loss of hairs, *hypo-trichosis*, more or less complete, in the corresponding skin-area, which is also anæsthetic. Together with this there is usually diminution of sweating, so that the skin is not only thinned and hairless, but also dry. This affected area of skin bleeds too easily when pricked, and tends to ulcerate after trivial injuries.

Incomplete section of cutaneous nerve-trunks, on the other hand, tends to produce *hyper-trichosis* of the corresponding area of skin, so that the hairs grow more abundantly than normal. Together with this, there is usually excessive localised sweating.

Traumatic lesions of peripheral nerves (altogether independently of septic infection and without injury to the main vessels of the limb) are often followed by progressive endarteritis of the arteries which are innervated by the affected nerve.[1] It will be remembered that incomplete nerve-injuries are sometimes followed by an early stage of primary vaso-dilatation of the corresponding skin-area, together with increased surface-temperature, excessive sweating and spontaneous pain (see Thermalgia, p. 183). Later on, these phenomena pass off and,

[1] Stopford, *Lancet*, March 30, 1918, p. 465.

concurrently with the development of local endarteritis and ischæmia, are followed by pallor, dryness and coldness of the affected fingers or toes, sometimes with small localised patches of gangrene; meanwhile, there is paralysis with sclerosis and contracture of the muscles, and decalcification of the bones supplied by the affected nerve. It is probable that the trophic disturbances following irritative nerve lesions are mainly due to vascular changes in the territory of the affected nerve.

Glossy skin is a condition met with chiefly in the hands in cases of long-standing peripheral nerve palsies, whether traumatic or neuritic in origin.

Fig. 157.—Right-sided brachial neuritis with glossy skin and tapering finger-tips.

Glossy skin is also a frequent accompaniment of osteo-arthritis, not only in the ordinary "rheumatoid" variety, but also in the arthritis which comes on in hemiplegic limbs. The skin of the fingers becomes thinned and atrophic, with a peculiar smooth, shiny surface The nails in many cases are altered, being longitudinally striated and excessively curved from side to side. The finger-pads are wasted and the finger-tips taper to a point, as is seen in Fig. 157, which is taken from a case of right-sided brachial neuritis.

Perforating ulcers occur most typically in tabes dorsalis. They are generally situated on the foot, on its plantar surface, especially at the metatarso-phalangeal joint of the great or little toe. They may also occur under the heel or under the terminal phalanx of the hallux. Each ulcer begins as a thickening of the epidermis, like a corn. Suppuration occurs under this, and the pus finds its way out through a

small opening in the centre (Fig. 158). A narrow sinus is thus formed which increases in depth until it may extend into the joint beneath, which is often disorganised, and carious bone may be felt at the bottom. Sometimes the ulcer heals up under treatment. The tabetic perforating ulcer is painless. Somewhat similar trophic ulcers are met with in certain cases of *spina bifida occulta* and also in *syringomyelia*, but in this latter disease they are commoner in the hands. *Diabetic neuritis* is also occasionally associated with perforating ulcers of the

Fig. 158.—Perforating ulcers in tabes.

feet, a minor variety of diabetic gangrene. In *leprous neuritis* perforating ulcers are not infrequent, though it is commoner to have a still more extensive loss of tissue, whole phalanges disappearing from the fingers and toes (see Fig. 177). *Painless whitlows*—in so-called "Morvan's disease," a sub-variety of syringomyelia, are found at the finger-tips. These whitlows are sometimes the result of trivial injuries which in a normal individual would not produce any serious results. In other cases the explanation is found in the absence of sensibility to temperature and pain, which is characteristic of the disease, so that the patient burns the fingers painlessly and produces blisters and even areas of sloughing.

In certain cases of tabes there may be a perforating ulcer in the mouth. First the teeth become loosened and fall out, then the alveolar margin of the jaw is absorbed, and if the upper jaw be affected a perforation into the nasal cavity may be established.

Herpes zoster is a very typical example of a trophic cutaneous disorder which has a direct nervous origin, viz. inflammation or thrombosis of the corresponding posterior-root ganglion. In this affection a crop of vesicles appear, which are distributed in a definite metameric

FIG. 159.

Herpes zoster in area of fifth dorsal root. Second day after appearance of eruption.

FIG. 159A.

Herpes zoster—the same patient as in Fig. 159. Eruption surrounds the nipple, and thence extends inwards to mid-sternum.

area, corresponding to the posterior root whose ganglion is diseased. In the case of facial herpes it is the Gasserian ganglion which is inflamed, in whole or in part, whilst herpes of the external auditory canal is associated with inflammation of the geniculate ganglion. The herpetic vesicles usually become pustular and subsequently permanent scars may remain. Herpes is sometimes preceded, for a day or two, by pre-herpetic pain in the area in which the eruption is about to appear; and not infrequently the eruption is followed by prolonged and intractable post-herpetic neuralgia (see p. 175). Figs. 159 and 159A are from a typical case of herpes in the area of the fifth thoracic root.

Sometimes herpes develops in the course of diseases of the vertebræ or of the spinal meninges. Such an occurrence signifies that the morbid process has attacked the corresponding posterior-root ganglion or ganglia. Even in simple herpes zoster we can sometimes elicit Kernig's sign[1] (see p. 60).

Bed-sores result from inflammatory and destructive changes in the skin and underlying tissues of bed-ridden patients, whether in persons merely enfeebled by prolonged illness (especially in enteric fever), or, more commonly, in severe organic paralysis, such as hemiplegia or paraplegia. Most bed-sores, occurring as they do at the sites of pressure, can be prevented by careful nursing, by keeping the patient's skin scrupulously clean and dry, by placing him on a water-bed, and by hardening the epidermis by local applications of methylated spirit. But sometimes, in spite of the most assiduous nursing, bed-sores develop within a few days or even within a few hours of an initial paraplegia or hemiplegia. This so-called *acute decubitus* is of grave omen.

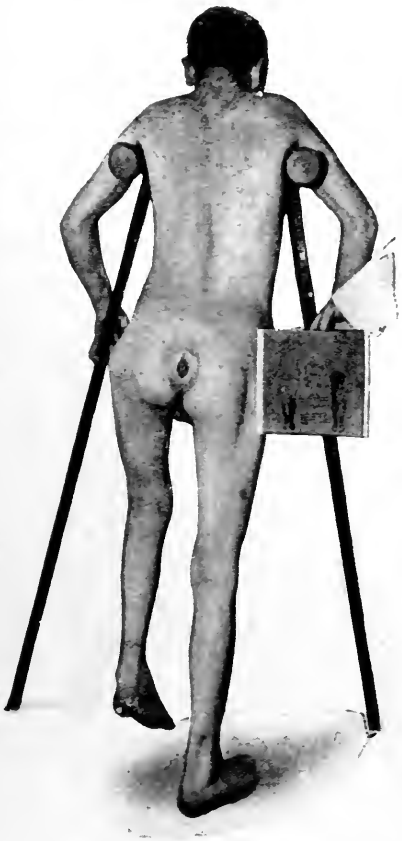

Fig. 160. — Lumbo-sacral myelitis with sacral bed-sore or decubitus. Showing atrophy and paralysis of muscles below left knee. The small chart on the right indicates the coexisting area of an æsthesia.

The commonest site for a bed-sore in a hemiplegic patient is over the great trochanter on the paralysed side. In paraplegia from cord lesions, *e.g.* acute myelitis, the bed-sore commonly forms over the middle of the sacrum (Fig. 160). A bed-sore commences as an area of redness of the skin, bullæ then develop and burst, leaving an ulcerating or sloughing surface beneath. The sloughing process may extend down to the periosteum and bones, and in sacral decubitus the infection may extend into the

[1] This fact, together with the frequent occurrence of lymphocytosis of the cerebro-spinal fluid, shows that in herpes zoster the pathological process is not limited to the posterior root-ganglion, but is part of a more widely diffused meningeal irritation. Bilbcza, *Archives générales de Méd.*, Feb. 27, 1906.

vertebral canal, producing a fatal cerebro-spinal meningitis, septic organisms gaining access not only from the skin, but from the intestinal discharges. Bed-sores are also met with in advanced cases of bedridden dementia, even where there is no paralysis. In these patients, as in cases of prolonged fever, the sores develop on the pressure points, viz. the heels, hips, backs of the scapulæ and even on the inner sides of the knees. We also meet with excoriations of the skin, which may amount to bed-sores, in cases of violent chorea in which the patient knocks his limbs against surrounding objects.

Before leaving the subject of destructive trophic lesions of the skin, we must mention *symmetrical gangrene*, a localised gangrene chiefly occurring in the tips of the fingers and toes, and preceded by pains or paræsthesiæ of the parts. But to this, the most severe phase of Raynaud's disease, we shall refer again when we consider the angio-neuroses.

The commonest points of incidence of *rodent ulcers* on the face are, as Cheatle[1] has shown, at the positions where the various branches of the trigeminal nerve become cutaneous, especially over the points of emergence of the infra-orbital, infra-trochlear, temporo-malar and lacrymal nerves, and also with particular frequency at the inner canthus of the eye and at the angle where the ala nasi joins the cheek. He has also shown that these spots are the favourite points of incidence of leucoderma and scleroderma. The precise significance of these facts is still obscure, but Cheatle has also recorded the curious fact that rodent ulcers are frequently limited to the distribution of normal nerve-areas and that the spread of a rodent ulcer ceases abruptly when it reaches a cutaneous area which has become denervated by division of its sensory nerves.

There are other trophic lesions unaccompanied by necrosis or ulceration, and consisting in local changes affecting one or more elements of the skin or subcutaneous tissues, whether in the direction of atrophy or of hypertrophy. Perhaps the most typical examples of this variety are scleroderma, leucoderma, and cutaneous nævi. **Scleroderma** is a disease in which the skin becomes abnormally hard and fibrous. The condition may be diffuse or circumscribed. In the rarer diffuse variety, large areas of skin, usually symmetrical, and especially on the upper limbs, become hard and rigid, losing their elasticity, so that the affected skin can no longer be pinched up with the fingers. Sometimes there is a preliminary œdematous stage. As the disease advances, the sclerotic process may extend to deeper structures such as tendons, and this, with the rigidity of the skin, limits the movements of the joints and may produce permanent deformities. If the fingers are affected,

[1] *Brit. Med. Journal*, April 29, 1905

they become tapering at the tips and permanently flexed. If the face is affected, it becomes immobile and mask-like. Circumscribed scleroderma, or *morphœa*, is the commoner variety, in which small patches of skin become hard, white and ivory-like, the distribution of the patches being somewhat similar to those of herpes zoster—*i.e.* metamerically, in the area of a posterior root, or of one of the divisions of the trigeminal nerve on the face.

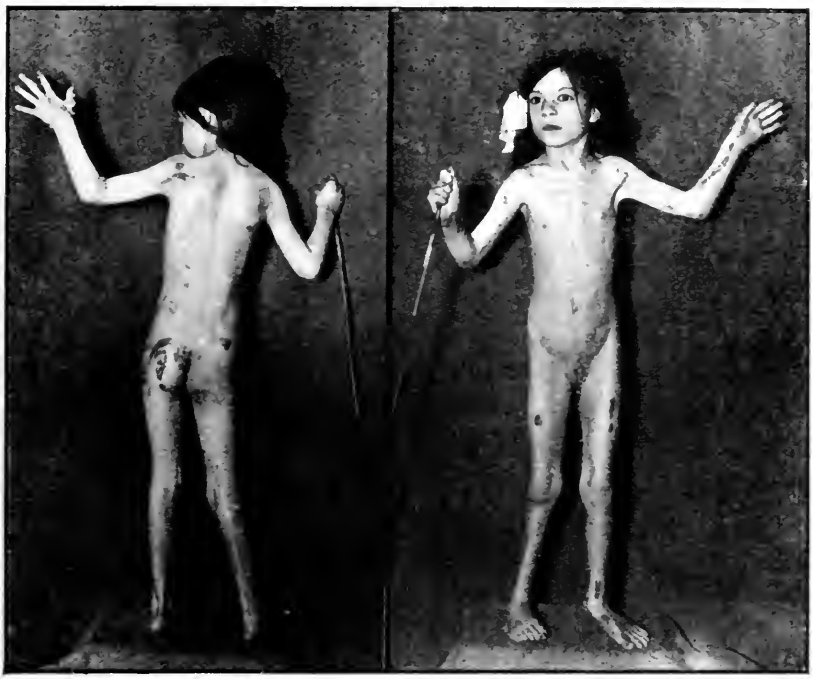

Fig. 161. Fig. 161A.

Congenital verrucosis of metameric distribution.

Leucoderma, or disappearance of pigment from circumscribed patches of skin, is also commonly distributed, more or less, in nerve-areas. The patch of absolute pallor has a pigmented edge where it joins the normal skin, and it tends to spread slowly along the particular area. This disease is, of course, most striking when it affects patients of sallow complexion or of dark-skinned race. Leucoderma also occurs in the maculo-anæsthetic type of *leprosy*, where the leucodermic patches are often red and hyperæsthetic at the edges and anæsthetic in the centre.

Figs. 161 and 161A represent a little girl aged eight, in whom

patches of warty growths were distributed in segmental spinal areas on the limbs and trunk.

Congenital **cutaneous nævi**—"port-wine stains"—are also commonly distributed in root-areas on the trunk or in the trigeminal distribution on the face. The trigeminal area is affected with special frequency, one, two, or all three divisions of the trigeminal being mapped out more or less accurately. It is an interesting fact that a cutaneous

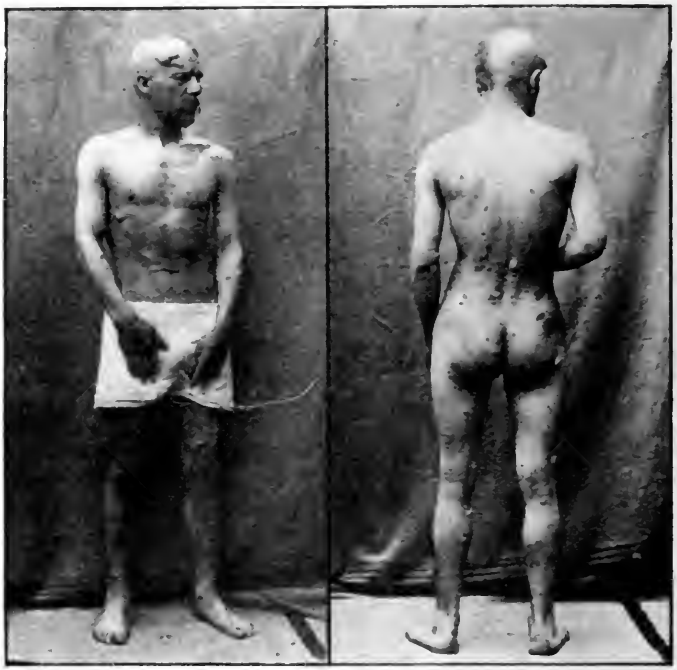

FIG. 162. FIG. 162A.

von Recklinghausen's disease in a man aged 38.

nævus on the face may be associated with hypertrophy of the subjacent deep tissues, with enlargement of the eyeball, and even with a nævoid condition of the nasal mucous membrane and of the dura mater on the corresponding side, all of which structures are innervated by the trigeminal nerve. More than this, cases of nævus of the face may be associated with recurrent epistaxis from the nævoid nasal mucosa, and sometimes they develop sudden infantile hemiplegia with epileptiform convulsions, due to sub-dural hæmorrhage from the dural nævus.[1]

Large neuro-fibromata—so-called **plexiform neuroma,** or *elephantiasis nervorum*—are more common on the trigeminal nerve, especially

[1] Cushing, *Journal of American Med. Association*, 1906, p. 178.

in its upper divisions, than on any other nerve of the body. Such a tumour is generally part of a more widespread affection known as **von Recklinghausen's disease** (see Figs. 162, 162A). In this disease we find, in a complete case, neuro-fibromata, often of fairly large size, forming painless swellings on the face or elsewhere, together with multiple soft fibromata of the skin forming sessile or pedunculated growths (known as molluscum fibrosum) and also patches of "*café au lait*"

FIG. 163.—Case of left-sided hemiplegia with hæmorrhages under all the finger-nails on the left side, and under the nail of the right little finger.

cutaneous pigmentation distributed more or less definitely in nerve-areas. The neuro-fibromata of von Recklinghausen's disease do not cause symptoms except by accidental mechanical compression of adjacent structures. The disease, which sometimes runs in families, often appears in childhood and remains stationary for many years, when it may suddenly resume its spread, new tumours cropping out all over the body.

Various cutaneous lesions are present in many cases of *arsenical neuritis*. A brownish macular pigmentation of the skin is, of course, common in chronic arsenical poisoning without neuritis. But in arsenical neuritis we frequently observe special cutaneous affections,

FIG. 164.

FIG. 164A.

Spina bifida occulta.

Fig. 164 shows a hairy mole at level of first sacral vertebra.

Fig 164A is a radiogram showing normal vertebræ down to level of third lumbar. The fourth lumbar arch is incomplete. Below that level all the laminæ are imperfect and are widely opened out, leaving the vertebral canal unroofed.

such as glossy skin, herpes zoster, falling of the hair, and, most characteristic of all, hyperkeratosis of the palms and soles, where the epidermis becomes much thickened and tends to desquamate. In addition to these skin lesions, we have the ordinary signs of a peripheral neuritis, such as drop-wrist, drop-foot, etc.

Progressive **descending lipodystrophy**[1] is another rare trophic disorder, nearly always confined to the female sex and commencing at ages varying from ten to thirty years. In this malady the subcutaneous fat disappears from the face and neck, and later from the upper limbs and trunk, so that the muscles become abnormally distinct. In the case shown in Fig. 165 the process of fat-absorption advanced from above downwards at the rate of about one inch every year. The lower limbs and buttocks, on the other hand, remain plump, and may even be excessively fat. The eyes become sunken from disappearance of orbital fat, although this is not constant. The mammary fat may remain unaffected.

Trophic changes are sometimes present in the hair. *Hypertrichosis*, or excessive growth of the hair, is met with most frequently on "hairy moles," which are, moreover, excessively pigmented in the skin as

[1] Parkes Weber, *Brit. Med. Journal*, 1913, p. 1154.

well. It is important to remember that a hairy mole in the lumbo-sacral region is often an indication of a *spina bifida occulta*. Fig. 164 shows a man, entirely devoid of paralytic signs or symptoms, in whom at the level of the first sacral vertebra there was a horizontal pigmented depression in the skin, at the middle line, from which a few long hairs

FIG. 165.—Descending lipo-dystrophy.

were growing. A gap could be felt in the vertebral spines at this level. Half an inch to the right of the fourth lumbar spine was another smaller dimple, attached by its deeper part to the bony structure. The radiogram (Fig. 164A) showed that the vertebral laminæ of the sacro-coccygeal and lower lumbar vertebræ failed to meet in the middle line. Local hypertrichosis also occurs occasionally in partial injuries of the

corresponding cutaneous nerve. The hair may also be affected in various ways in other nervous affections. Well-authenticated cases have been recorded of *blanching of the hair* of the scalp within a few hours as a result of profound emotion. It is not uncommon to meet with patches of whitened hair in nerve-areas which have been the site of severe neuralgia. Even in the ordinary greyness of advancing years, and in the idiopathic premature greyness of youth, as Cheatle[1] pointed out, the maximum greyness often appears in nerve-areas in the scalp and beard. We also meet with *localised alopecia*, in which the hair

FIG. 166. FIG. 166A.

Right-sided facial hemiatrophy, also implicating the corresponding side of the tongue.

falls out suddenly in a certain circumscribed area. Sometimes this occurs after an acute febrile illness, *e.g.* influenza. Other cases occur spontaneously after shell-wounds of the cranium, the hair falling out suddenly in one or more patches after an interval of several weeks from the original trauma. Such patches are not necessarily at the site of the wound, but may occur at any part of the scalp. Other cases of localised alopecia, again, are produced by the action of X-rays employed for the diagnosis of cranial fractures. Many patients with exophthalmic goitre, as Walsh pointed out,[2] have a bilaterally symmetrical band of alopecia at the frontal end of the scalp.

[1] *Brit. Med. Journal*, July 22, 1905. [2] *Lancet*, 1907, p. 1080.

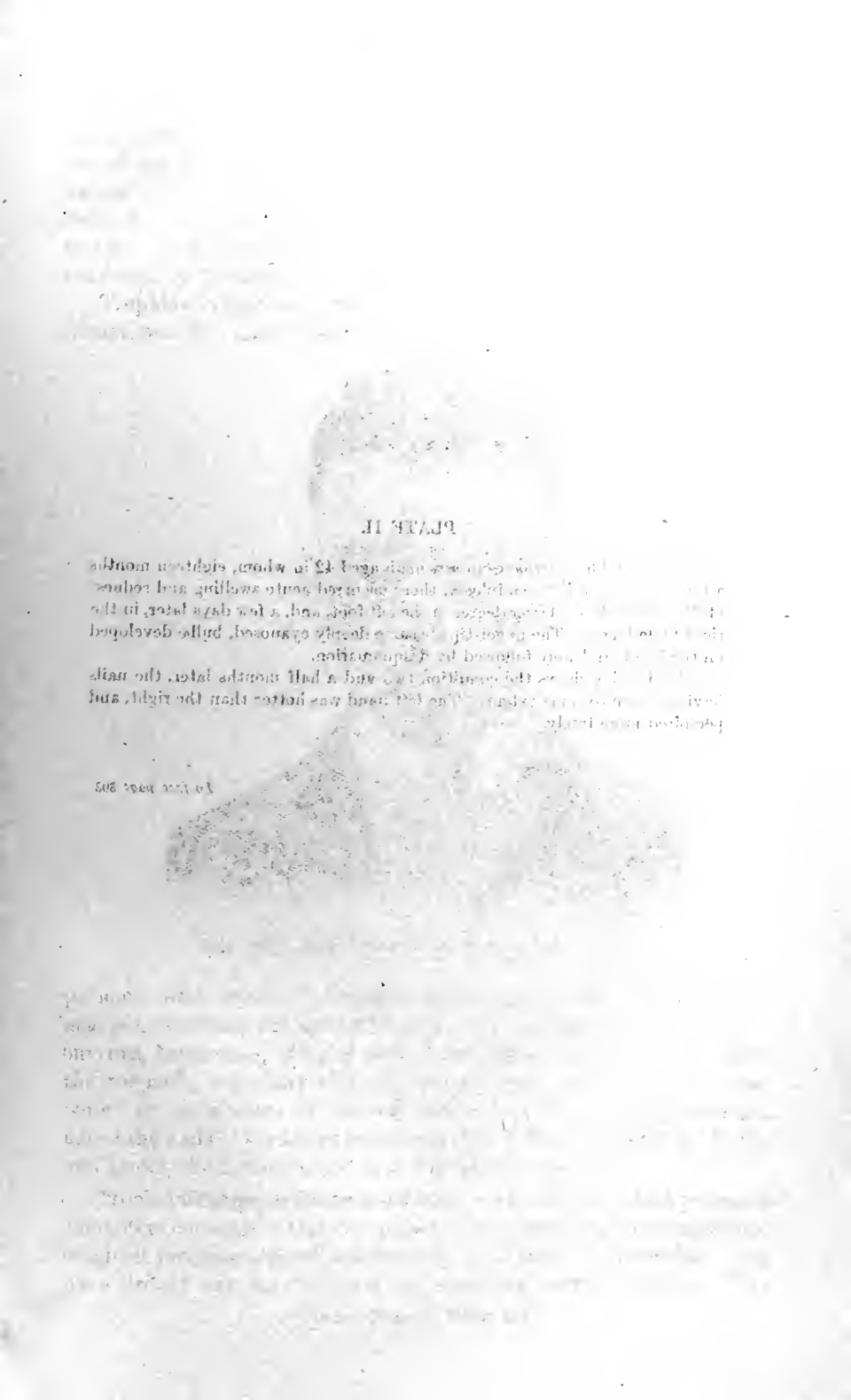

PLATE II.

Sub-ungual hæmorrhages in a woman aged 42 in whom, eighteen months after an attack of left hemiplegia, there occurred acute swelling and redness of the left hand, to a lesser degree in the left foot, and, a few days later, in the right little finger. The finger-tips became deeply cyanosed, bullæ developed on the hand, and were followed by desquamation.

The drawing shows the condition two and a half months later, the nails having grown to some extent. The left hand was hotter than the right, and perspired more freely.

To face page 303

Hypertrichosis of the eyebrows is sometimes associated with hyperthyroidism, whilst a varying degree of supra-ciliary alopecia is one of the signs of thyroid insufficiency (*signe de sourcil*),[1] and affords an indication for thyroid medication. We occasionally meet with cases of *universal alopecia*, in which the hairs all over the body fall out, and the patient remains permanently hairless, his skin meanwhile being considerably thinned.

Trophic changes in the *nails* occur in a number of nervous diseases. Sometimes the nails become hypertrophied, as in the toe-nails of

Fig. 167.—Hemi-hypertrophy of right side of face.

patients with *chronic paraplegia* from any cause. In *peripheral neuritis*, especially the arsenical variety, we may meet with excessive curving, brittleness, atrophy and even falling of the nails. In *tabes* the toe-nails, especially those of the big toes, are sometimes shed, whilst in some cases of *cerebral hæmorrhage* we find hæmorrhages under the nails of the hemiplegic hand (Fig. 163 and Plate II.). As the nail grows, the hæmorrhagic area is gradually cast off.

Trophic Changes in Bones and Joints.—An affection which possesses characters common to this group and to the group of cutaneous trophic lesions is *progressive facial hemiatrophy*. It is probably referable, as we have already seen, to a lesion of the trigeminal nerve or nucleus. Not

[1] Michel, *Thèse de Paris*, 1911.

only is the skin on the affected side of the face atrophied and wrinkled, but the bones, and especially the lower jaw, become smaller (Figs. 166 and 166A). Still more rarely we meet with cases of *facial hemihypertrophy*, in which the bones and soft parts of one side of the face become progressively larger. In the case shown in Fig. 167, the enlargement of the face followed an injury in childhood to the ipsolateral side of the forehead.

It is not uncommon to find atrophic changes in the bones of paralysed limbs. In paralytic affections of children, whether of the upper neurone type, as in *infantile hemiplegia* (Fig. 168), or of the lower neurone type, as in *acute anterior poliomyelitis* (Fig. 169), the bones of the paralysed limb become arrested in their growth and are smaller in all their dimensions than are the healthy limbs. Even in some cases of *hemiplegia in adults* the bones of the paralysed limbs become excessively brittle. I remember a case of hemiplegia in a middle-aged

Fig. 169.—Old poliomyelitis anterior acuta. Paralysis and atrophy of biceps, triceps, and deltoid on left side, with arrested growth of humerus.

Fig. 168.—Old infantile hemiplegia, left-sided, with arrested growth of limbs.

woman in whom moderate passive movements under an anæsthetic, during an attempt to break down adhesions in the hip-joint of the hemiplegic side, caused a fracture of the neck of the femur. The brittleness of the bones in certain *insane patients* and their liability to fractures from trivial injuries are well known. Moreover, there is a rare disease known as idiopathic *fragilitas ossium*, in which the patient,

Fig. 170.—Tabetic arthropathy of both knees and of right foot. The patient's right leg is tied to the chair to prevent involuntary tabetic movements.

otherwise healthy, may fracture his bones from minimal accidents, as, for example, where a lad fractured his humerus by throwing a cricket-ball. Similar spontaneous fractures also occur in certain cases of *tabes* and of *syringomyelia*, but in these two diseases the fractures are painless, so that the patient may continue to use the fractured limb in a fashion impossible to a normal individual.

The most typical trophic changes in joints—the so-called **arthropathies**—are met with in tabes (constituting Chacot's joint), in syringomyelia, and in some cases of leprosy.

In tabetic cases well-marked syphilitic arterial changes have been found in the affected joints. Hence it has been held that vascular rather than purely nervous influences may be the primary cause of such arthropathies.[1] On the other hand, experimental traumata of joints in animals without syphilitic infection, but in which the limb had previously been rendered anæsthetic by division of the posterior roots, have produced typical arthropathies.[2]

Fig. 171. — Syringomyelia with arthropathy of left shoulder-joint. Atrophy of intrinsic muscles of left hand.

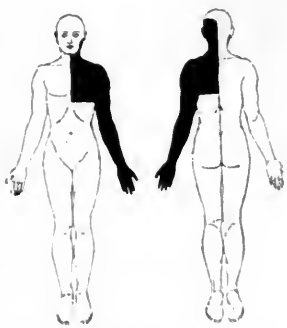

Fig. 172. — The same case of syringomyelia. Showing the area of thermanæsthesia and analgesia.

The large joints are more liable to be affected, the knee and the tarso-metatarsal joint being the joints most commonly attacked in tabes (Fig. 170), the shoulder in syringomyelia (Figs. 171 to 173). But in tabes even the smaller joints may be affected, as in the patient shown in Fig. 175, the terminal joint of whose thumb was thus diseased. Female tabetics seem to be relatively more liable than male patients to osteopathies and arthropathies. The exciting cause of a tabetic arthropathy is often some trivial traumatism, such as a twist or sprain in a joint in which the sense of pain is diminished or lost, hence the greater frequency of tabetic arthropathies in the lower limbs. The joint swells painlessly, and rapid destructive changes occur in its articular surfaces, which become eroded and may disappear, together with considerable parts of the adjacent bones. Fractures of the articular ends are common, both in tabetic and in syringomyelic joints. The ligaments become lax and the joint abnormally mobile, so that

[1] Barré, *J. de Psychologie und Neurologie*, 1913, ff. 5 and 6.
[2] Eloesser, *Annals of Surgery*, 1917, p. 201.

in the knee we may be able to produce lateral passive movements, or even to bend the joint into all sorts of curious positions (Fig. 176).

Fig. 173.—Syringomyelia (same case as Fig. 171). Radiogram of shoulder-joint. Showing fracture of upper end of humerus, also osteophytic outgrowth from axillary border of scapula.

The joint is sometimes distended with a glairy gelatinous fluid, which may be blood-stained. In the later stages this fluid may be reabsorbed, throwing into relief the deformity of the bones (Fig. 178). But the changes in such arthropathies are not entirely destructive. Osteophytic outgrowths are often formed in the muscles and peri-articular tissues, causing irregular thickening of the bones, and producing little islands of new bone amongst the tissues around the joint. These can be readily detected on palpation and verified by skiagrams (Figs. 179 and 180).

In some cases of paraplegia due to total transverse lesion of the spinal cord, or cauda equina, *e.g.* in war-injuries, curious rapidly-growing bony deposits occur in certain of the paralysed muscles. Osteomata of this sort make their appearance at a long interval, six months or more, after the original injury, after the flaccid stage of paraplegia has become replaced by a permanent spastic paraplegia. It is chiefly the larger muscles around the hip or knee-joint that are affected. New bone is laid down, sometimes at the periosteal attachment of the affected muscle, in other cases in discrete islands within the muscle, at a distance from the bony skeleton. These osteomata, whether starting periosteally or intra-muscularly, form ivory-hard lumps which steadily increase in size, spreading through the substance of the affected muscle or muscles. They can be recognised on

Fig. 174. — Syringomyelia with arthropathy of left shoulder-joint, [the] limb being swollen and displaced downwards *en masse* at the shoulder.

FIG. 175.—Tabetic arthropathy of left thumb.

FIG. 176.—Tabetic arthropathy of knee-joints.

palpation and verified by X-ray photographs. Their causation is obscure. They are not accompanied by any inflammatory reaction nor by any hæmatoma. It has been suggested[1] that they may be due to slight irritation or detachment of periosteum during the process of massaging specially vulnerable muscles.

In leprosy, arthropathies are commonest in the fingers and toes, and perforating ulcers, with sinuses leading into the disorganised joints, are much commoner than in tabes or syringo-

Fig. 177.—Leprosy. Showing absence of terminal phalanges of nearly all the digits. Rudimentary nails persist at the ends of all. The remnant of the terminal thumb phalanx is bent to an acute angle. Leprous keratitis is present, also ectropion of lower lids. The eyebrows are absent. The bridge of the nose is depressed.

myelia. Bony hypertrophic changes are usually absent in leprous arthropathies, the process being purely destructive. Curiously enough, a large proportion of male lepers have hypertrophy of the nipples.

Joint-affections of a different kind are met with in some cases of chronic hemiplegia. The joints of the paralysed limbs become swollen and deformed two or three weeks after the hemiplegic attack. But, unlike the tabetic and syringomyelic arthropathies, hemiplegic joint-affections are acutely painful. Moreover, the changes in hemiplegic joints are not destructive, but more of the nature of a subacute osteo-

[1] Mme. Dejerine and M. A. Ceillier, *Revue neurologique*, 1918, pp. 159 and 207.

arthritis, with pain and rigidity on passive movements and with a tendency to the formation of fibrous adhesions within the joint and to thickening of the joint capsule. When the fingers are affected, they lose their normal outline and become clumsy-looking and "sausagy" in appearance. Together with this hemiplegic arthritis it is not uncommon to have a degree of muscular wasting, but without electrical reaction of degeneration.

FIG. 178.—Syringomyelia with arthropathy of right shoulder-joint, and destruction of head of humerus. Well-marked scoliosis.

Finally, we must bear in mind that certain *hysterical* patients complain of joint-pains, usually mono-articular, which may more or less closely simulate organic joint-disease. The patient is commonly a young woman who, after some local injury to the joint, or after some emotion, or perhaps from being acquainted with another patient who has joint-disease, suddenly complains of intense joint-pain, together

FIG. 179.—Tabetic arthropathy of elbow-joint. Radiogram showing bony deposits in the tissues around the joint.

with cutaneous hyperæsthesia in that region. The joint is rigid and resistant to passive movement, and if the condition has persisted, as is sometimes the case, for weeks or months, fibrous adhesions may form.

But there is no true swelling of the joint when compared with the corresponding limb of the opposite side, although a false appearance of swelling may appear to be present owing to disuse-atrophy of the adjacent muscles. The presence of other hysterical phenomena often

Fig. 180.—Radiogram of tabetic arthropathy of knee, from patient shown in Fig. 170. Showing disappearance of articular surfaces and presence of bony deposits in peri-articular tissues.

aids in the diagnosis, but an accurate opinion is sometimes a matter of considerable difficulty and is arrived at by a process of exclusion. Accomplished surgeons have been known to operate on such joints, and only on opening the joint have discovered the absence of organic disease. Fortunately, the usual result of such an operation, if aseptic, is that the patient recovers from her pains.

CHAPTER XIX

REFLEXES

For clinical purposes we have to consider three varieties of reflexes:—

(1) Superficial or skin reflexes, *e.g.* the plantar reflex.
(2) Deep, tendon, or osseous reflexes, *e.g.* the knee-jerk.
(3) Organic or visceral reflexes, *e.g.* vomiting, micturition, parturition.

Of these three groups, the first two have to do with striated voluntary muscles. They have their reflex centres within the cerebro-spinal axis, and many of them can be inhibited by voluntary effort. The third group, that of the visceral reflexes, is concerned not with voluntary muscles alone, but also with involuntary non-striated muscles which are controlled by the vegetative nervous system and are incapable of direct voluntary restraint—*e.g.* the muscular walls of the stomach, bladder, rectum, or uterus. Such visceral reflexes can be performed, more or less perfectly, independently of the central nervous system. Normally, visceral functions go on, for the most part, unconsciously. But even they may occasionally evoke consciousness, as when visceral pain occurs, or when striated voluntary muscles are required to supplement an act originally initiated by non-striated muscles, or when the reflex act causes stimulation of a cerebro-spinal sensory nerve. Thus, to take an example, the act of defæcation is practically unconscious and uncontrollable, so far as the movement of the large intestine is concerned. But when the lower end of the anal canal has its mucosa stimulated, the perineal muscles come into action; the act then rises to consciousness and comes more or less under control.

Skin Reflexes.—These are movements obtained by slight stimulation of certain areas of skin or mucous membrane. The result is a movement, quick or slow, of the skin-tissues near the point of stimulation, but not exactly under it. In certain animals such as the horse, skin reflexes can be obtained by touching almost any part of the trunk. But in man the cutaneous tissues are less mobile, and it is usually only from certain special areas that skin reflexes can be elicited. If the stimulus be too strong, it may cause a reflex so violent as to involve almost all the voluntary muscles of the body. Or if the stimulus, even though slight, be a painful one, as for example a pin-prick, the result

is a rapid "defensive" movement—*e.g.* sudden flexion of a limb or abrupt closure of the eye (see "Defensive Reflexes," p. 215). The defensive reflexes are usually exaggerated in pyramidal disease.

The following table gives a list of the chief skin reflexes which are of clinical importance, and the mode of testing each. All of them are more easily elicited in young people than in old; in fact, if we wish to demonstrate the skin reflexes with certainty, we select a child for our subject.

	Method of Eliciting.	Result.	Segmental Level.
Corneal	Touching cornea.	Orbicularis oculi contracts.	
Pharyngeal	Touching posterior wall of pharynx.	Pharynx contracts.	
Palatal	Touching soft palate.	Palate is elevated.	
Scapular	Stroking skin in inter-scapular region.	Scapular muscles contract.	C5 to Th1.
Epigastric	Stroking downwards from nipple.	Upper fibres of transversalis contract and epigastrium dimples, on side of stimulus.	Th6 to Th8.
Upper Abdominal	Stroking below and parallel with costal margin.	Transversalis and rectus abdominis contract on side of stimulus.	Th8 to Th10.
Lower Abdominal	Stroking above and parallel with inguinal fold.	Transversalis (lowest fibres) and obliquus internus contract.	Th11 to Th12.
Cremasteric	Stroking inner and upper part of thigh. Or pressure over Hunter's canal, or over adductor tubercle.	Testicle is drawn up.	L1 and L2.
Gluteal	Stroking skin of buttock.	Gluteal muscles contract.	L4 and L5.
Plantar	Stroking sole of foot.	Tensor fasciæ femoris contracts, hallux and other toes flex, ankle is dorsi-flexed.	L5 to S2.
Bulbo-Cavernosus	Pinching dorsum of glans penis.	Bulbous urethra contracts.	S3 and S4.
Superficial Anal	Pricking skin of perineum.	External anal sphincter contracts.	S4, S5 and Coccygeal.

The normal **corneal reflex** is a bilateral affair, for, if we touch one cornea, blinking occurs in both eyes. Bilateral loss of corneal reflexes, on stimulating either cornea, occurs in coma from any cause, including the coma produced by general anæsthetics. In certain cases of hemiplegia the corneal reflex cannot be elicited from the paralysed side, especially in hemiplegias which are associated with hemianæsthesia. More commonly loss of the corneal reflex is due to a lesion of the reflex arc, either in its afferent (trigeminal nerve) or its efferent limb (facial nerve). In such a case, in order to decide whether loss of the reflex is due to affection of the trigeminal or of the facial nerve, we note the behaviour of the opposite eye when stimulating the cornea of the affected side. If no blinking occurs in the opposite eye, we have to do with trigeminal disease, whereas, if sensation is intact and the facial nerve alone is paralysed, the contra-lateral reflex still occurs. Unilateral loss or diminution of the corneal reflex is often the earliest clinical sign of trigeminal paresis, long before any sensory loss can be detected. This fact is sometimes of considerable value in the diagnosis of tumours of the posterior cranial fossa (see later, Extra-cerebellar Tumours).

Absence of the **abdominal reflex** is not uncommon in acute abdominal conditions, notably in appendicitis and enteric fever.[1] In young adults whose abdominal walls are apparently normal and in whom there is no œdema or excessive obesity, absence of this reflex on one or both sides is strongly suggestive of disseminated sclerosis. In acute meningitis the abdominal reflexes tend to disappear early and bilaterally. In brain abscess, however, with commencing hemiplegic symptoms, the abdominal reflex disappears on the hemiplegic side only, just as in an ordinary case of recent hemiplegia from a vascular lesion. Exaggeration of the abdominal reflexes is fairly common during the gastric or intestinal crises of tabes, being associated with cutaneous hyperæsthesia of the abdomen. It is sometimes exaggerated in paralysis agitans.

In the majority of normal individuals we can elicit Mayer's **thumb-reflex**[2] as follows:—The patient's supinated hand is laid on the palm

Fig. 181.—Normal plantar reflex.

of the observer, who grasps the wrist firmly and with the thumb of the other hand powerfully flexes the metacarpo-phalangeal joint of the patient's four ulnar digits, one after the other, from minimus to index. The thumb promptly becomes slightly flexed and opposed at the carpo-metacarpal joint; at the same time its proximal phalanx becomes flexed and its distal phalanx extended. Less commonly both phalanges of the thumb become extended. This thumb-reflex is diminished or lost in organic affections of the pyramidal tract, being analogous in this respect to the abdominal reflex. Cases of median or ulnar paralysis are, of course, incapable of showing this reflex. In acute meningitis the thumb-reflex is often exaggerated. It is temporarily abolished for a few minutes during post-epileptic coma.

Of all the superficial reflexes, the **plantar reflex** is the one which has the greatest practical importance. In order to test it, the patient should be lying down, his feet being comfortably warm. The limb to be tested is now partially flexed at the hip and knee, and also rotated

[1] Rolleston, *Brain*, 1906, p. 99.
[2] C. Mayer, *Neurolog. Centralblatt*, 1916, No. 1.

so as to rest on its outer side. Then with some hard object such as the end of a penholder (applying light pressure, not mere contact), we gently stroke the sole of the foot from behind forwards, towards its inner side. Meanwhile we watch carefully for the first movement of the great toe. Normally this is a movement of plantar flexion (see Fig. 181). Simultaneously with the toe movement we have a brisk contraction of the tensor fasciæ femoris (Brissaud's reflex), which may occur even in cases in which the toes show no movement. This shows that the plantar reflex is not a phenomenon confined to the foot, but that it implicates the whole lower limb. If we employ a stimulus which is too strong, we may have, in addition, dorsiflexion of the ankle, and this may obscure the toe movement. Hence the importance of a gentle stimulus, graduated so as just to elicit the toe phenomenon and no more.

This normal plantar reflex, flexor in type, occurs only when the

Fig. 182.—Babinski's extensor plantar reflex.

reflex arc is intact, and when, in addition, the lower reflex arc is in connection with the cerebral motor cortex by an uninjured pyramidal tract. In this sense it is a "cortical" reflex.

If the pyramidal tract, conveying motor impulses downwards from the cortical "leg-centre," be interrupted in any part of its course by injury or disease, or if it be non-developed, as in infants who have not learned to walk, the type of plantar reflex is different and is known as **Babinski's phenomenon,** or the **extensor plantar reflex.** This is a more primitive type of reflex, of strio-spinal origin, which is normally inhibited by cortical control. In the Babinski phenomenon, stimulation of the sole, especially towards its outer side, produces extension of the hallux instead of flexion (see Figs. 181 and 182). Dorsiflexion of the hallux may be the only visible effect, but it is never the only muscular contraction. It is always accompanied by contraction of the hamstring muscles, detected by palpation.[1] Moreover, this extensor

[1] Walshe, *Brain*, 1914, vol. xxxvii., p. 279.

movement of the great toe is slower than is the normal, brisk flexion response. Sometimes, in addition to extension of the hallux, we observe a fan-like spreading out of the other toes—"*phénomène d'éventail.*"

An extensor plantar reflex is practically always pathological, except in infants too young to walk (gradually disappearing after the age of six months), and if constantly present it indicates an organic lesion, and one which implicates the pyramidal tract.[1] It is therefore of the utmost value in the diagnosis between hysteria and organic disease. A bilateral extensor plantar reflex may also occur as a temporary phenomenon, *e.g.* during post-epileptic or uræmic coma and other transient affections of the pyramidal tract, often toxic in origin, such as acute morphine poisoning.

If the patient's foot is cold, the plantar response may be indefinite. In such cases, if we warm the foot by plunging it into hot water, the response sometimes reveals itself as definitely flexor or extensor.

The extensor plantar reflex can sometimes be elicited by other devices, *e.g.* by tapping with a percussion-hammer over the dorsal aspect of the metatarso-phalangeal joint of the big toe, just internal to the tendon of the extensor longus hallucis,[2] or by sudden, sharp upward pressure on the sole of the foot, just behind the ball of the great toe,[3] or by pressure on the deep flexor muscles, as in Gordon's[4] *paradoxical flexor reflex*, which consists in an extension movement of the great toe or of all the toes when we press deeply, through the calf muscles, between the heads of the gastrocnemius, on to the deep flexor muscles beneath. To elicit this reflex, the physician should place himself on the outer side of the patient's leg, the muscles of which must be completely relaxed. This is attained either by directing the patient to lie on his back or making him sit with his feet on a stool.

Oppenheim's reflex, a contraction of the extensor longus hallucis together with the tibialis anticus, is elicited in a slightly different way, viz. by firm stroking from above downwards with some hard object (such as the handle of a percussion-hammer) just behind the postero-internal border of the tibia, about the junction of its middle and lower thirds. Its significance is the same as that of Babinski's phenomenon.

The **adductor foot-reflex**[5] can sometimes be elicited in superficial organic lesions of the motor cortex, in which the plantar reflex may be indefinite in type. It consists in a contraction of the tibialis posticus muscle, raising the inner border of the foot and slightly extending the ankle. To test this reflex, the patient may either be sitting on a low chair with his lower limbs semi-extended and only the heels resting on

[1] There is one exception to this rule. This is in the case of a lower motor neurone lesion affecting the flexor muscles of the toes and sparing the extensors. In such a case the only possible movement of the toes would be extension. But the other signs of lower neurone lesion, especially the electrical reactions, will prevent error.

[2] Throckmorton, *Journal of American Med. Ass.*, May 6, 1911.

[3] Trömner, *Deutsche med. Wochenschrift*, 1911, No. 37.

[4] *American Medicine*, 1904, p. 971.

[5] Hirschberg, *Revue neurologique*, August 15, 1903, Marie and Meige, *ibid.*, 1916, p. 420.

the ground, or, better, lying on his face with the knees bent nearly to a right angle. With a blunt-pointed object we then stroke gently along the inner border (not the sole) of the foot, from the base of the hallux towards the heel.

The **cremasteric reflex** is very easy to elicit in young children by stroking the inner side of the thigh from above downwards. But in old men it is sluggish or apparently absent. Even in them, however, it can usually be elicited by sudden firm pressure backwards against the sartorius muscle in the region of Hunter's canal, or against the adductor tubercle of the femur; this often succeeds when stroking the skin in the usual fashion is of no avail. Unilateral absence of the cremasteric reflex occurs occasionally, but not constantly, in organic hemiplegia. The cremasteric reflex is sometimes exaggerated on the affected side in cases of sciatic neuralgia.

The **bulbo-cavernosus reflex** is of great diagnostic value in determining whether the lowest segments of the spinal cord are intact in a lesion about the level of the third sacral segment—where the ordinary reflexes of the lower limbs give us no help. To obtain the bulbo-cavernosus reflex, we place one finger behind the patient's scrotum, pressing upwards against the bulbous part of the urethra. With the other hand we pinch, or prick with a pin, the dorsum of the glans penis; the bulbous urethra is at once felt to give a brisk twitch. Loss of this reflex indicates a lesion somewhere in its reflex arc, either in the anterior cornua of the third and fourth sacral segments, or in the corresponding motor or sensory roots of the cauda equina. Loss of the bulbo-cavernosus reflex is a fairly common sign in tabes, being due in that case to a lesion of the afferent fibres of the reflex arc.

The **superficial anal reflex** can be easily obtained by placing the patient in the genu-pectoral posture and pricking the skin of the perineum with a long "bonnet-pin," and watching whether the external sphincter contracts. This reflex is sometimes lost in anæsthesia of the perineum, *e.g.* in lesions of the fifth sacral or of the coccygeal segment, or of their corresponding motor or sensory roots.

Organic hemiplegia usually produces, at first at least, loss of the unilateral superficial reflexes all down the paralysed side, with one exception—viz. the plantar reflex, which persists, but from the outset is changed into the extensor type. In hysterical hemiplegia, on the other hand, even though cutaneous hemi-anæsthesia be present, the unilateral skin reflexes on the paralysed side are usually preserved, with the exception of the plantar reflex, which is often lost. An extensor plantar reflex never occurs in pure hysteria. In hysteria there may be absence not only of any toe movement on stimulation of

the sole, but there may also be loss of the reflex contraction of the tensor fasciæ femoris. This "combined" absence of reflex movement both of the toes and of the fascia lata of the thigh is always strongly suggestive of hysteria. It is probably due to a latent muscular spasm.

Deep (Tendon or Osseous) Reflexes.—Some of these are elicited by percussing the tendon of insertion of a particular muscle; others by tapping the periosteum of a particular part of a bone.

FIG. 183.—Method of eliciting jaw-jerk.

The following table gives a list of the chief deep reflexes which we commonly study when investigating cases of nervous disease:—

	METHOD OF ELICITING.	RESULT.	SEGMENTAL LEVEL.
Jaw	Tapping lower jaw, supported in half-open position.	Jaw closes.	Pons.
Biceps . . .	Tapping biceps tendon.	Biceps contracts.	C5 and C6.
Radial . . .	Tapping styloid process of radius.	Supinator longus contracts.	C5 and C6.
Scapulo-humeral.	Tapping vertebral border of scapula, near base of spine.	Deltoid, teres minor, infra-spinatus, etc., contract.	C5 and C6.
Pronator or Ulnar	Tapping antero-internal surface of lower end of radius, or postero-inferior surface of head of ulna.	Pronators contract.	C6.
Wrist	Tapping upper part of radius.	Wrist and fingers extend.	C6 to C8.
Triceps . . .	Tapping triceps tendon.	Triceps contracts.	C7 to Th1.
Carpo-metacarpal	Tapping dorsum of wrist.	Fingers flex.	C8 and Th1.
Knee	Tapping patellar tendon.	Vastus internus, etc., contract.	L3 and L4.
Hamstring . .	Tapping hamstring tendon.	Biceps, semi-membranosus, or semi-tendinosus contracts.	L5 and S1.
Ankle . . .	Tapping tendo Achillis.	Calf muscles contract.	S1 and S2.

The **knee-jerk** may be taken as a type of these tendon reflexes.

It has been a matter of dispute whether it is really a true reflex or not. Strictly speaking, the jerk occurs too soon after the tap for a nervous

impulse to have time to travel up to the reflex centre in the cord and down again to the muscles. But so long as the reflex arc is intact, there is a constant "reflex tonus" in the vastus internus muscle which, when the tendon is struck, permits the jerk to occur. If this reflex tonus be lost from interruption of the reflex arc at any point, the jerk can no longer be obtained. Therefore, for practical purposes, the knee-jerk, though not a true reflex action itself, is an index of the integrity of the reflex arc.

To obtain the knee-jerk, we feel for the patellar tendon and strike it either with the edge of the hand or with some other fairly heavy

Fig. 184.—Knee-jerk. Reinforcement by Jendrassik's method.

object, such as a rubber percussion-hammer or a heavy paper-knife. The result is a brisk contraction of the quadriceps. Meanwhile we should grasp the vastus internus with our other hand, so that we may feel the jerk in cases where it is too feeble to move the knee-joint. The knee should be somewhat bent, to put the quadriceps slightly on the stretch, and the muscles must be absolutely relaxed. This latter point is of importance; for often it happens that a patient has his muscles in a state of excessive spasm, so that we may fail to elicit the knee-jerk, and yet, if we succeed in relaxing his muscles by preliminary passive movements, the knee-jerk is not only present, but found to be increased.

The knee-jerk in such a case is not absent, but only "concealed" by the spasticity of the muscles. In a normal knee-jerk, the muscular tightening is not limited to the quadriceps, but is accompanied by a contraction of the antagonists, *i.e.* the hamstrings.

In testing the knee-jerk the patient may be sitting on a table with his legs dangling in the air, or, better, on a chair with the soles of the feet flat on the ground and the knees gently semiflexed, or one knee

Fig. 185.—Knee-jerk. Reinforcement by Laufenauer's method.

may be crossed over the other. A feeble jerk may be "reinforced" by Jendrassik's method (Fig. 184), in which the patient hooks both hands together, pulling them one against the other, and looks up towards the ceiling, thereby diverting his attention and relaxing the leg muscles. A better method of reinforcement is Laufenauer's, in which we grasp the patient's quadriceps whilst the patient sits with his soles flat on the ground. The patient then grasps our upper arm with one hand, and suddenly squeezes when told to do so; meanwhile, down comes the percussion-hammer (Fig. 185). The advantage of this method is that we can feel for ourselves whether the patient is really directing

his attention to the act of reinforcement. Moreover, this method can be employed to reinforce feeble reflexes of the upper limbs, whereas Jendrassik's method is only available for reflexes of the lower limbs. Many other methods of reinforcement have also been suggested, *e.g.* by making the patient gaze at the ceiling and draw a long breath (Krönig[1]), or by making him read aloud as fast as possible from a newspaper or book (Rosenbach[2]).

Reinforcement will make a feeble jerk more evident; but it has no effect if the jerk be absent.

The **cerebellar knee-jerk.** In recent and acute cerebellar lesions the knee-jerk in the ipso-lateral limb is sometimes altered, so as to acquire a "pendular" character. Thus, whereas, in the normal limb, the leg falls back deliberately to its original position and quickly comes to rest, on the affected side in cerebellar cases it continues to swing to and fro for a time like a pendulum. This is probably due to muscular hypotonia (see p. 24). In cases of this sort there is, moreover, an absence of the normal contraction of the hamstring muscles, which normally contract synergically with the quadriceps at the time of the jerk.[3]

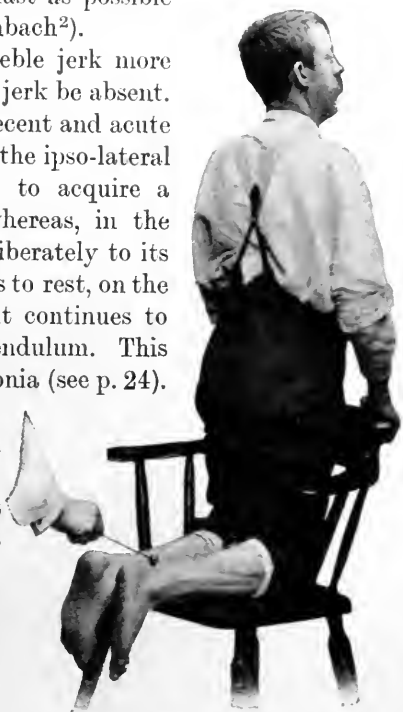

Fig. 186.—Method of eliciting ankle-jerk.

The **ankle-jerk** has a diagnostic significance equal to that of the knee-jerk. To test it, we make the patient kneel on a padded chair with his feet projecting over the edge. (If he kneels on a hard wooden surface, painful pressure upon the tibiæ may produce tonic dorsiflexion of the ankles, thereby interfering with the reflex.) We then tap the tendo Achillis (Fig. 186); a brisk extension movement of the ankle is the result. Some patients have a difficulty in relaxing the calf muscles when kneeling on a chair. In such cases we make the patient stand with one leg on the ground, resting his weight on the erect limb, whilst the other leg kneels on the chair, bent loosely to a right angle at the knee.

In tabes the ankle-jerk is often lost before the knee-jerk. In sciatica loss of the ankle-jerk indicates a neuritis as distinguished from a mere neuralgia.

In the upper extremity we have various deep reflexes at our disposal.

[1] *Berlin. klin. Wochenschrift*, 1906, No. 44.
[2] *Münchener med. Wochenschrift*, 1907, No. 2.
[3] Gordon Holmes, *Brain*, 1917, vol. xl., p. 507.

Of these, the **radial** or **supinator-jerk** is ordinarily the most accessible. In testing it, we support the patient's forearm in a semi-supinated posture, with the elbow loosely bent to a right angle. We tap with our hammer close above the styloid process of the radius (Fig. 187). The supinator longus at once contracts, and with it the other flexors of the elbow.

Sometimes the flexors of the fingers contract also. In health we do not induce reflex contraction of the finger flexors by themselves. When this occurs—so-called "inversion" of the radial reflex—it indicates a spinal cord lesion at or above the level of the fifth cervical segment.

Fig. 187.—Supinator-jerk.

To elicit the **triceps-jerk**, the best way is not, as stated in some text-books, to allow the elbow to hang over the back of a chair, but rather to support the upper arm horizontally, with the elbow loosely flexed at a right angle. Then, feeling for the triceps tendon, we tap it with our hammer, and the muscle at once contracts.

The **pronator-jerk** is elicited by holding the forearm midway between pronation and supination, and then tapping either on the antero-internal part of the radius or on the postero-inferior surface of the ulna. Percussion of this area of the ulna, in certain subjects, also induces, in addition to the pronator-jerk, a flexion movement of the wrist and fingers.

Loss of Deep Reflexes.—Sometimes these reflexes cannot be elicited, even on reinforcement. This is almost always pathological (although

in very rare cases a healthy individual is found to be devoid of deep reflexes), and generally indicates a lesion of the reflex arc. If this lesion be in the afferent limb of the arc, there may also be anæsthesia of the corresponding nerve- or root-area. If it be in the anterior cornu, or in the efferent motor path, there will be muscular paralysis, with atrophy of the particular muscle.

The following is a list of some of the chief conditions in which there is loss of the deep reflexes:—

Disease.	*Site of Lesion.*
Neuritis (Alcohol, Diabetes, Diphtheria, Lead, Arsenic, Tubercle, Cachexia, etc.)	Peripheral nerves, sensory or motor.
Peripheral Nerve Palsies	
Temporarily from compression by tourniquet	
Tabes Dorsalis	Posterior columns of cord.
General Paralysis of Insane (tabetic type—Tabo-paralysis)	
Freidreich's Ataxia	
Subacute Combined Degeneration of Posterior and Lateral Columns—late stage of	
Any focal lesion in Grey Matter of Cord	Reflex centre in cord.
Infantile Paralysis (Acute Anterior Poliomyelitis)	Anterior cornua of cord.
Progressive Muscular Atrophy (Chronic Anterior Poliomyelitis)	
Amyotrophic Lateral Sclerosis	
Syringomyelia	
Thrombosis of Anterior Spinal Artery	
Landry's Paralysis	Anterior cornua and peripheral motor nerves.
Myopathies (Pseudohypertrophic and Atrophic types)	Muscle itself.
Amyotonia congenita	
Family Periodic Paralysis (during attacks)	
Increased Intra-Cranial Pressure (especially Hydrocephalus and Tumours of Posterior Fossa).	
After acute meningitis.	
Pneumonia.	
Temporarily after attack of Major Epilepsy (post-epileptic coma).	
Toxic coma (uræmia, morphine, etc.).	
During Spinal Anæsthesia.	
Complete transverse lesion of Spinal Cord, during first three weeks or so.	

From the above list we see that, in addition to focal organic lesions within the reflex arc itself, there are other conditions in which the deep reflexes are abolished. Thus these reflexes are lost in the final stages of increased intra-cranial pressure, especially in hydrocephalus and in tumours of the posterior fossa.

This is attributed by Raymond and others to a curious degeneration of the posterior spinal roots, which sometimes occurs in such conditions, whereas van Gehuchten[1] ascribes it to loss of function of the rubro-spinal tracts, from pressure on the mesencephalon.

In patients who have recovered from acute meningitis (*e.g.* after war-injuries of the cranial meninges) the deep reflexes may remain permanently abolished when all the other clinical phenomena have cleared up.[2] Possibly this is due to affection of the posterior roots, whether from stretching or from toxic infection.

The knee-jerks are often lost during pneumonia. In the attacks of the rare disease known as family periodic paralysis (see p. 249),

[1] *Le Névraxe*, 1907, vol. ix., p. 39.
[2] Souques, *Société de Neurologie*, January 11, 1917.

the deep reflexes in the affected limbs are temporarily abolished, owing to temporary paralysis of the muscle-fibres. The deep jerks are abolished for a few minutes just after an epileptic fit, during the stage of coma and flaccidity. They may also disappear during coma from other causes, as in uræmic coma, or in morphine-poisoning. Spinal anæsthesia temporarily abolishes all the deep and superficial reflexes in the lower limbs (see p. 430).

As Babinski has pointed out, the application of an Esmarch tourniquet, from the toes to the middle of the thigh, for a period of 20 to 25 minutes, temporarily abolishes all the reflexes, deep and superficial, below the level of compression, even where there had previously been increased deep reflexes, clonus, and an extensor plantar response. Moreover, the plantar reflex as it returns, after removal of the tourniquet, may for a few minutes show a normal flexor response (especially on stimulation along the outer border of the foot) before the extensor response again develops.

We should also remember that in *complete* trans-section of the spinal cord all the deep reflexes below the level of the lesion are lost for a time, usually for three weeks or a month, during which the paralysed muscles are flaccid and toneless. This is followed by a stage in which muscular tonus and reflex activity reappear, together with the "mass-reflex" (see p. 331). Later still, if toxic febrile complications occur (*e.g.* from an infected bladder), these reflex activities gradually disappear again.

If, however, the lesion be not complete, and there still survives some nervous tissue connecting the upper and lower portions, then the deep reflexes are exaggerated.

Exaggeration of Deep Reflexes.—Sometimes the deep reflexes are exaggerated, so that the slightest tap on the tendon produces an abnormally brisk contraction. This may be the result of various poisons—*e.g.* tetanus, or strychnine poisoning—rendering the reflex centres unduly explosive; or it may occur in simple neurasthenia. But organic lesions of the pyramidal tract are by far the commonest causes of permanent exaggeration of the deep reflexes. In cases of organic disease, we look also for the presence of *clonus*. A clonus is a rhythmic series of muscular contractions produced by sudden passive stretching of the tendon, the clonus continuing so long as the tension of the tendon is maintained.

Clonus can be inhibited by pinching a large fold of the skin of the lower limb, especially of the thigh. This stops the clonus at once.

Ankle-clonus is the commonest clinical variety of clonus. To elicit it, the knee is passively flexed (the angle of flexion varying in different cases); the ankle is then suddenly dorsiflexed by upward pressure on

the sole of the foot (Fig. 188). Ankle-clonus is due, as Weir Mitchell has pointed out, to contraction, not of the gastrocnemius, but of the soleus muscle, since the position of the knee which is best for eliciting ankle-clonus is one in which the gastrocnemius is relaxed.

A *spurious ankle-clonus* is sometimes obtained in cases of hysteria. This can usually be distinguished from genuine clonus by a characteristic feeling as of voluntary contraction in the muscles, especially at the commencement of the clonus, difficult to describe in words. Spurious clonus is generally poorly sustained and often irregular in rhythm. It is never associated with an extensor plantar reflex.

Fig. 188.—Method of eliciting ankle-clonus.

Knee-clonus or rectus-clonus is best obtained by sudden downward traction on the patella, the knee being passively extended.

In chronic organic affections of the pyramidal tract, practically every one of the deep jerks may become exaggerated into clonus. Thus in advanced disseminated sclerosis we may find in the same patient jaw-clonus, elbow-clonus, wrist-clonus, finger-clonus, knee-clonus, ankle-clonus, toe-clonus, etc.

The presence of true clonus indicates that the reflex arc is hyper-

excitable, owing to withdrawal of the regulating or restraining influence normally exerted through the pyramidal tract. Exaggeration of the deep reflexes is therefore one of the cardinal signs of a chronic lesion of the upper or cortico-spinal motor neurone.

The *Bechterew-Mendel reflex* is elicited by tapping the dorsum of the foot, preferably over the cuboid bone. Instead of the normal extension of the four outer toes, due to stimulation of the extensor brevis digitorum, we have a flexor movement of these toes. This phenomenon only occurs in organic lesions of the pyramidal tract. *Rossolimo's sign* of pyramidal disease consists in a similar sudden flexion movement of the toes, produced by their previous extension, *e.g.* by striking on their plantar surface.

In the upper limb Trömner's *finger-phenomenon*[1] of pyramidal disease is elicited by lightly grasping the patient's semi-pronated hand and then lightly flicking the terminal phalanx of the index finger in a palmar direction. In health, the patient's thumb remains motionless, but in disease of the pyramidal fibres of the upper limb the thumb makes a reflex movement of adduction. A similar movement can also be elicited by firm, slow scratching along the ulnar side of the palm, from the base of the little finger towards the pisiform bone, or inversely.[2]

It is unnecessary to give a list of the various organic diseases in which the deep reflexes are exaggerated. Suffice it to say that any chronic lesion of the pyramidal tract will produce exaggeration of the deep reflexes below the level of the lesion. Thus in paraplegia due to myelitis, to lateral sclerosis, or to some other affection of the lateral columns, or in hemiplegia from organic brain disease, there is exaggeration of the deep reflexes in the paralysed limbs, owing to injury or disease of the pyramidal fibres.

There is an important exception to this rule, to which we have already referred, namely in *total* trans-section of the spinal cord, as in some cases of bullet-wound or of fractured spine. Such total lesion produces an initial flaccid paralysis of the lower limbs, with loss of the deep reflexes (Bastian's law). But if the lesion be incomplete, we have the usual spastic type of paraplegia from the outset, with increased deep reflexes. In both instances, whether the lesion be total or partial, we have the reflexes of spinal automatism in the lower limbs, and usually an extensor type of plantar reflex. In some total transverse lesions, however, the plantar reflex may be flexor in type, temporarily, for several weeks at least.

We should also mention that in the early stages of a *peripheral neuritis*, *e.g.* in localised neuritic atrophy in association with arthritis,

[1] *Neurologisches Centralblatt*, 1912, p. 603.
[2] Marie and Foix, *Revue neurologique*, 1915, p. 583.

the deep reflexes may be exaggerated. But this soon passes off and is succeeded by their diminution and loss. Again in *subacute combined degeneration* of the lateral and posterior columns of the cord, there is an early stage of spasticity with increased deep reflexes, and a terminal stage of flaccid paralysis with loss of reflexes.

Sometimes in the flexed type of spastic paraplegia (see p. 266) the muscular rigidity of the paralysed limbs is so extreme that it may be impossible to obtain the knee-jerks or ankle-jerks, which we should expect to find exaggerated in these cases. This is because the muscles are already in a state of tonic spasm. But if we succeed in temporarily relaxing them, by passive changes of posture, we can sometimes obtain the increased jerks and even the clonus. In most cases, the spasticity and the presence of an extensor plantar reflex will prevent errors in diagnosis.

Pupillary Light Reflex.—

This occupies a special category of its own. The reflex is elicited by exposing the pupil to light, after previous shading. Normally under such conditions the pupil contracts briskly, both when stimulated directly and when the pupil of the opposite eye is exposed to light (consensual reflex). In some respects the pupil-reflex to light, although occurring in a non-striated muscle, is analogous to a deep reflex, and it is useful to remember that in tabes this reflex disappears, as do the ordinary tendon-reflexes. But the subject of the various pupil-reflexes and their connections with the third nerve, with the ciliary ganglion, and with the cervical sympathetic is discussed elsewhere (see "Cranial Nerves," p. 125, and "Cervical Sympathetic," p. 341).

Organic Motor Reflexes.—These are concerned with the vegetative nervous system and with the contraction of non-striated, involuntary muscles. The contraction of non-striated or smooth muscles is a slow affair, unlike the brisk reflex twitch in a striated muscle.

The following is a list of organic reflexes which are of diagnostic interest. In some of them, such as the cilio-spinal or the scrotal, the reflex movement is executed entirely by non-striated muscle. In others, such as the vesical, uterine, or rectal, the non-striated muscle is reinforced by voluntary striated muscles.

	Method of Eliciting.	Result.
Cilio-spinal	Pinching or scratching skin of neck.	Pupil dilates.
Oculo-cardiac	Firm compression of eyeballs.	Slowing of heart.
Cutaneo-gastric	Light stroking along left costal margin.	Stomach contracts.
Scrotal	Repeated stroking of perineum or application of cold.	Dartos contracts.
Vesical	Distension or irritation of bladder or posterior urethra.	Bladder-wall contracts.
Rectal	Distension or irritation of upper part of rectum.	Rectum contracts.
Genital	From cerebrum or periphery.	Erection of corpora cavernosa.
Uterine	Distension or stimulation of uterus.	Uterus contracts.
Internal anal	Distension of anus by finger.	Internal sphincter ani contracts.

In many of these the reflex movement can be accomplished, more or less perfectly, independently of the central nervous system.

The **oculo-cardiac reflex** is elicited by firm compression of both eyeballs backwards into the orbits. In most normal individuals this produces an immediate slowing of the cardiac rate, amounting to six or eight beats per minute, lasting throughout the time of compression and sometimes accompanied by extra-systoles. The slowing ceases immediately the compression is discontinued. Compression of the right eyeball produces a slightly greater effect than left-sided ocular compression. The afferent path of this reflex is in the trigeminal nerve; its efferent path is in the autonomic fibres of the vagus. The oculo-cardiac reflex is specially marked in the "vago-tonic" type of individual, whereas in "sympathetico-tonic" individuals it may be diminished or absent. It is sometimes exaggerated in exophthalmic goitre and frequently lost in tabes. It can be temporarily abolished by the administration of atropin.

The **cutaneo-gastric reflex,** to which attention has been specially directed by Percy Mitchell,[1] is of considerable clinical interest. It is elicited by laying the patient flat on his back and gently stroking the skin along the left costal margin, beginning about the tenth costal cartilage, gradually ascending towards the xiphisternum, and descending slightly down the right costal arch. Meanwhile a fairly heavy phonendoscope is placed on the epigastrium, whereby the observer can hear the movement of stomach-contents, gas, or air, as each wave of reflex contraction passes along the stomach-wall from left to right. After a few seconds or minutes of stroking, we hear bubbles of gas being expelled through the pylorus. We cease our stroking until that particular contraction comes to an end, then proceed again, until by successive contractions the gas is all expelled. On continuing further strokings, we hear low, crunching sounds, "like a man walking on frozen snow," probably due to churning movements of the pyloric antrum. This sound increases in intensity as the muscular wave approaches the pylorus. When the pylorus opens, a sizzling and gushing sound is heard as the fluid passes through the pylorus. Towards the end of the séance we sometimes hear a long-continued powerful rush of fluid—a débâcle, when the stomach completely empties itself into the duodenum. When the stomach is at last empty, stimulation produces a soft, sighing sound, apparently due to peristalsis of the empty organ.

This reflex is of value in the treatment of atonic dilatation of the stomach. Before attempting to elicit the reflex, an interval of three or four hours should be allowed to elapse, after the preceding meal, in order to allow time for gastric digestion to be well advanced.

[1] *Lancet*, January 28, 1911.

Certain reflex centres for the bladder, uterus, and rectum are situated within the spinal cord. But clinical and pathological evidence has shown that the lowest **reflex centres for the contraction of the bladder,** and of the neighbouring hollow viscera possessing non-striated muscular walls, are situated extra-spinally, in the hypogastric and hæmorrhoidal plexuses of the vegetative nervous system, and in the bladder-wall itself, where nerve-cells and fibres are present, constituting a peripheral vesical plexus.

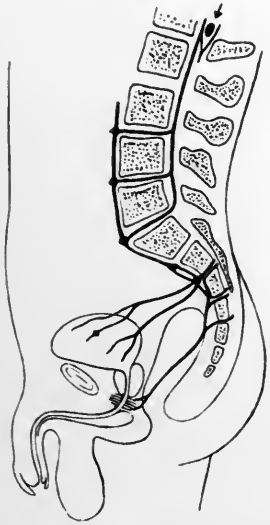

Fig. 189.—Nerves passing to bladder and its sphincters.

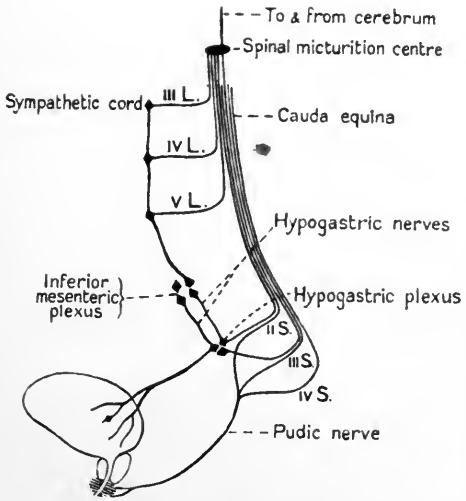

Fig. 190.—Diagram of nerves of bladder, explanatory of Fig. 189.

(*Thomson Walker.*)

Like all internal organs of the body, the bladder has a double innervation, partly from the sympathetic and partly from the autonomic system. The sympathetic fibres reach the sympathetic chain through the third, fourth, and fifth lumbar roots, and are conducted to the vesical plexus through the inferior mesenteric and hypogastric plexuses (see Fig. 190). The sacral autonomic fibres reach the bladder through the second, third and fourth sacral roots, *viâ* the pudic nerves or nervi erigentes. These two sets of nerves are mutually antagonistic. Thus stimulation of the nervi erigentes produces relaxation of the non-striped sphincter with contraction of the bladder-wall (detrusor urinæ), thereby producing emptying of the bladder; whereas stimulation of the hypogastric plexus causes accentuation of the tonus of the sphincter with inhibition of the detrusor, thereby producing retention of urine.

The vegetative vesical centre can be stimulated from the cerebro-spinal system. Micturition in the adult is a voluntary act, but only to this extent that it can be voluntarily initiated. This is accomplished by contracting the diaphragm and abdominal walls, producing a rise in the intra-vesical tension, which starts the reflex: the bladder-wall contracts, whilst the involuntary, non-striped sphincter is inhibited.

Meanwhile the voluntary, striated constrictor urethræ is relaxed. The non-striated bladder-wall itself, the so-called detrusor urinæ, is not under control of the will. Once started, the bladder empties itself spontaneously, and we can stop the act only by voluntarily innervating the constrictor urethræ, usually a matter of considerable effort. Reflex micturition is often excited by irritation of the urethra, especially of its vesical end. Thus if a few drops of urine trickle into the prostatic urethra, an imperious reflex act of micturition results, which is difficult to prevent. Similar phenomena are produced by the irritation of a posterior urethritis.

The sensory nerves from the bladder pass through the sacral autonomic by the rami communicantes, and along the posterior roots into the spinal cord (see later, pp. 335-336). They serve to inform us of the distension of the bladder. There are also higher micturition centres, some in the spinal cord (in the lower sacral segments), others higher still in the mid-brain, in the corpus striatum and optic thalamus; others, highest of all, in the motor cortex. One cortical micturition centre, which controls the voluntary external sphincter and the bulbo-cavernosus muscle, is situated in the pre-central gyrus, between the hip and shoulder motor centres. A second centre, controlling and inhibiting the internal bladder sphincter, is situated on the mesial aspect of each cerebral hemisphere, in the para-central lobule, close to the cortical centre for the toes.[1] These higher centres, one for the voluntary restraint or interruption of micturition, the other for voluntary inhibition of the internal sphincter and for the emptying of the bladder at a convenient moment, control the sub-cortical and spinal centres. When these higher centres, spinal or cerebral, are hyper-excitable, whether from disease or from emotion, we may have *precipitancy* of micturition, or even *enuresis*, a condition in which the brain and spinal cord on the slightest provocation send impulses which relax the compressor urethræ.

Periodic **reflex incontinence** is a condition in which the bladder contracts intermittently and automatically, expelling its contents at intervals of an hour or two. This is the normal condition in little infants, in whom it forms part of a **primitive "mass-reflex,"** comprising not only bladder-contraction, but also emptying of the lower bowel, flexion of the lower limbs, and sweating. In adults this mass-reflex is usually in abeyance, being dominated by higher centres in the mid-brain, but it may reappear in emotional conditions, especially in conditions of fear, when the bladder and even the rectum may contract involuntarily and the individual sweats profusely.

In an acute total transverse lesion of the spinal cord, there is an initial phase of **retention of urine,** due to tonic contraction of the internal sphincter, and requiring catheterisation. If no catheter be passed, the bladder becomes over-distended, and its muscular wall is so stretched that it will no longer contract. We then have a condition of **overflow-dribbling,** in which the excess of urine, which the flaccid,

[1] Adler, *Neurologisches Centralblatt*, 1919, p. 618.

distended bladder can no longer contain, runs away continuously through the urethra. Similar overflow-dribbling sometimes occurs in cases of coma, or in the deep insensibility of fevers such as typhoid, in which catheterisation has been neglected.

If, however, in cases of transverse spinal cord lesion, a catheter is being passed regularly to prevent distension and infection (as is usually done), the bladder within a few days begins to regain its contractile power. At first, its systole is feeble, so that it can only actively expel 2 or 3 ounces at a time through the catheter, and the residue of the bladder-contents runs out by gravity. But soon its systolic power increases, until it can actively expel, say, 7 ounces out of 10, the remainder, constituting the "residual urine," being drawn off by gravity through the catheter after the bladder systole is over. After five or six days of this sort of education, the bladder gradually becomes able to contract more completely and, eventually, to evacuate actively its entire contents, say 10 ounces, through the catheter. (The amount which each individual bladder can cope with, so as actively to empty itself completely, varies from one patient to another.)

Still later, say three weeks or a month after an acute total transverse spinal cord lesion, concurrently with return of muscular tonus, reappearance of the knee-jerks, and development of an extensor plantar response, reflex contraction of the bladder occurs, even against the resistance of the sphincter, so that catheterisation may no longer be required. In such cases, if we scratch the sole of the foot, we get not only an extensor plantar reflex and a drawing-up of one or both limbs (see "reflexes of spinal automatism," p. 215), but also **reflex bladder-contraction;** *i.e.* the primitive "mass-reflex" reappears. In such cases, bladder-contraction may be elicited by scratchings, not only of the sole of the foot, but also of the anterior surface of the thigh. Thus a patient who is totally paraplegic and anæsthetic in his lower limbs (unless a cauda equina lesion prevents impulses from reaching the spinal cord) may learn to utilise his reflex incontinence so as to empty his bladder when full, by scratching the front of his own thigh, thereby inducing a mass-reflex with concurrent flexion of the lower limbs. Conversely, automatic evacuation of the bladder or rectum may induce a flexor spasm of the legs. In such patients, when the bladder is becoming distended, violent sweating occurs over the area of skin supplied by sympathetic fibres below the level of the spinal lesion, and there may even be a gastro-intestinal reflex in the form of vomiting. If the bladder be emptied, whether by catheter or by scratching the thigh, this vomiting and excessive sweating no longer occur.[1]

The mass-reflex can only be elicited in patients with a "flexor

[1] Head and Riddoch, *Brain*, 1918, vol. xl., pp. 149-263. Riddoch, *Lancet*, December 21, 1918, p. 839.

type" of spastic paralysis (see p. 266). Therefore, if a case recovers still further, so as to lose its flexor type and to show extensor rigidity of the lower limbs, stimulation of the sole, although causing an extensor plantar response of that limb, will no longer produce an indiscriminate mass-reflex, and the reflex induced will no longer spread to the bladder, rectum or sweat-glands.

True dribbling of urine, as distinguished from intermittent contraction of the bladder, occurs most typically in cases of tabes and is most frequently due to anæsthesia of the bladder, which being now insensitive to distension, is no longer stimulated to contract by the normal accumulation of urine. The tabetic patient with an anæsthetic distended bladder expels his urine, not by contraction of the bladder but by pressure with his abdominal walls. This can readily be verified if we have to pass a catheter for the purpose of emptying a tabetic patient's bladder. True dribbling also occurs in an over-distended bladder which, from obstruction in the prostate or urethra, has become flaccid, paralysed and atonic.

But true paralytic incontinence also occurs in certain cases of spinal cord or cauda equina lesions in which there is an atonic sphincter combined with a flaccid bladder, in which the urine dribbles away continuously without accumulating.

The **internal anal reflex** is tested by inserting a finger within the anus. Normally the finger is tightly grasped by the non-striated internal sphincter, innervated by sacral autonomic fibres. This reflex is independent of the superficial anal reflex of spinal origin, to which we have already referred. When the internal anal reflex is lost, the anus no longer grasps the finger but remains open for several seconds, "yawning," after the finger has been withdrawn. Such loss is most commonly due to anæsthesia of the anal canal, as in tabetic or other lesions of the cauda equina. The result is incontinence of fæces. If there be a lesion within the spinal cord, above the spinal centre in the conus medullaris, there is intermittent rectal incontinence. But if the lesion be in the afferent nerves from the rectum, the internal sphincter loses its reflex tonus and remains relaxed, and the fæces, if fluid, dribble away continuously from the unwitting patient when they enter his anæsthetic rectum.

To test the **scrotal reflex,** which is an excellent example of a purely autonomic motor phenomenon, the patient stands bending forwards with his legs wide-spread and scrotum hanging free. The skin of the perineum is now stroked with some hard object five or six times in succession. After a few seconds an extremely slow, worm-like contraction appears in the non-striated dartos muscle, beginning near the perineal part of the scrotum and spreading forwards. This reflex can also be elicited by the application of cold to the perineum or scrotum.

In addition to the foregoing ordinary, innate, or stereotyped re-

flexes, which in normal individuals traverse relatively simple paths, the central nervous system also possesses the faculty of establishing new or acquired reflexes by a process of practice and repetition. These so-called **conditional reflexes** have been specially studied by Pawlow and his school. For example, the secretion of saliva can be induced as an ordinary reflex in an untrained animal by the introduction of food or of acid substances into the mouth. Other afferent stimuli can also induce reflex salivation, *e.g.* the sight or smell of food, and sometimes even the thought of food. Moreover, stimuli of an entirely extraneous and indifferent nature, by a process of training, can also be made to induce salivary secretion, thereby constituting a new or acquired reflex. Thus in the case of a dog, if a certain note be struck on a gong on every occasion immediately before food is placed in the animal's mouth (or if in another dog a painful electrical stimulus be applied to the skin within a few seconds prior to administering food), then in the course of time, by a process of repetition of the same experiment, the central nervous system comes in the one animal to associate the sound of the gong, and in the other animal to associate the painful electrical stimulus, with the administration of food and with its concomitant salivary secretion. Finally, after a time, the "conditional stimulus" alone suffices, even without the administration of food, to induce salivation, so that in the one animal the mere sound of the gong, or in the other the mere application of a painful electrical stimulus to the skin, at once induces copious salivation without producing the ordinary and natural reflex of fright or pain to which these stimuli originally gave rise. In other words, the stimulus has been diverted from one part of the nervous system to another. These are "conditional" or acquired reflexes, which are established by means of specialised "analysors" comprising the peripheral end-organ of the sense-organ (hearing, pain, etc.), the corresponding afferent nerve-fibre, and its ultimate termination in the sensory cortex. Such analysors are constantly at work regulating the reactions of the living organism to its varying environment.

Conditional reflexes are the cause of many psycho-motor and other phenomena of which familiar examples can be found. A large part of our elementary education is concerned with the establishment of conditional reflexes which are useful to us under circumstances which are of specially frequent occurrence. The maxim that "practice makes perfect" is based on the fact that complex psycho-motor actions, originally demanding a considerable effort of conscious attention (*e.g.* swimming, riding, driving a motor-car or an aeroplane), may in the course of time become conditional reflexes, so that the individual, whilst performing them, becomes able at the same time to direct his conscious attention to other things.

CHAPTER XX

AFFECTIONS OF THE VEGETATIVE NERVOUS SYSTEM

The Vegetative Nervous System is a highly-complex system of ganglia, nerve-fibres and nerve-plexuses, which innervates the non-striped muscles of the body generally, also the pupils, the various glands and viscera, the heart and blood-vessels, and the genital organs. It is developed by outgrowth from the cerebro-spinal system, with which it remains connected by afferent and efferent fibres, so that impulses from the central nervous system can affect the vegetative system, and *vice versâ*. Moreover, a number of specialised vegetative nerve-cells remain within the cerebro-spinal axis, thereby accounting for the occurrence of vegetative phenomena in certain central diseases. Unlike the nerves of the cerebro-spinal system, which pass directly from the nerve-cells of the lower neurons to the voluntary muscle-fibres which they innervate, no fibre of the vegetative system passes from the cerebro-spinal axis to an involuntary end-organ without the interposition of a ganglion-cell in its course. The vegetative nerve-fibres passing from the cerebro-spinal cells to the ganglion-cells are termed *pre-ganglionic ;* those passing from the ganglion-cells to the viscera are *post-ganglionic.*

The vegetative system has two great subdivisions—the sympathetic system proper and the autonomic or para-sympathetic system. These two divisions are not only anatomically distinct, but also physiologically antagonistic, mutually counterbalancing one another.

The sympathetic proper consists of two chains of gangliated cords, like two strings of beads, one on each side, close in front of the vertebral column, from the atlas to the coccyx.

In the thoracic, lumbar, and sacral regions the sympathetic ganglia correspond in number to the spinal nerve-roots, but in the neck, instead of eight ganglia, there are only three in each chain—superior, middle, and inferior. These cervical ganglia are connected with the spinal cord, not through the cervical roots, but through the first and second thoracic roots (see later, p. 341).

Each chain is made up of multipolar nerve-cells with nerve-fibres, all of them involuntary, destined for gland-tissue, for blood-vessels, and for organs which possess non-striped muscle-fibres.

The sympathetic chain is connected with the spinal cord by short *rami communicantes*, some of them white, some of them grey (see Fig. 191). The *white rami*, composed of very fine medullated fibres, are mainly efferent (viscero-motor) or spino-sympathetic. They are pre-ganglionic fibres,

arising from special cells in the intermedio-lateral region (nucleus sympathetieus) of the spinal cord. They emerge from the cord through the anterior roots, from the first thoracic to the second lumbar inclusive. These efferent visceral fibres never reach their peripheral terminations directly, but pass through the anterior root to terminate in the corresponding sympathetic ganglion, where a second (or post-ganglionic) fibre takes up the nervous impulse and transmits it to the terminal non-striped muscle or gland (see Fig. 191). Post-ganglionic nerve-fibres are usually non-myelinated. The white rami also contain afferent medullated viscero-sensory fibres which

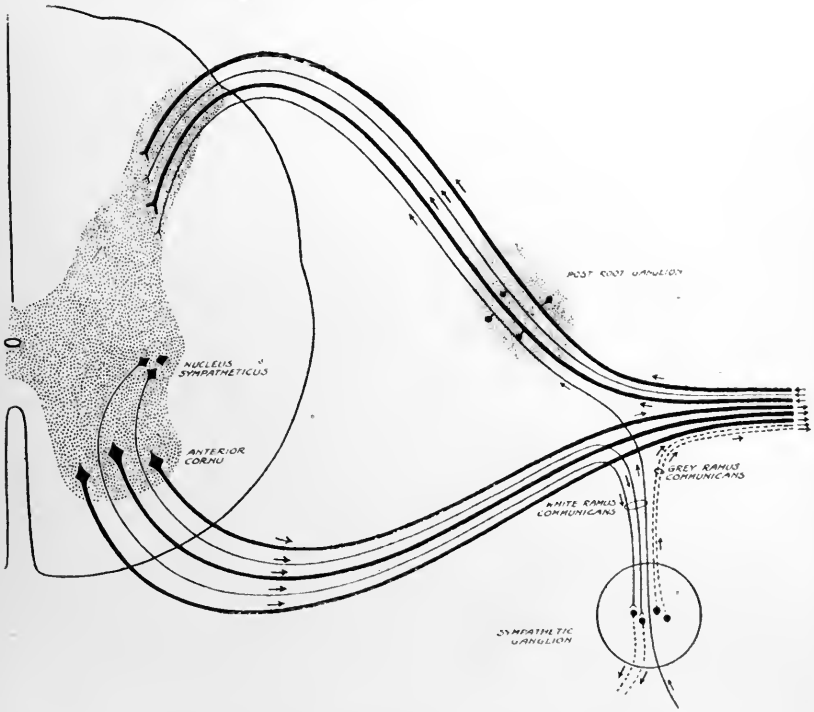

FIG. 191.—Diagram illustrating connections between a sympathetic ganglion and a spinal nerve in the thoracico-abdominal region.

belong to the cells of the posterior root-ganglion. Unlike the efferent fibres, these afferent fibres are not interrupted into a pre- and post-ganglionic portion, but traverse the sympathetic ganglion unbroken, running continuously from their peripheral sensory end-organs to the posterior root-ganglion.

The *grey rami* pass from all the ganglia of the sympathetic chain to the cerebro-spinal nerves; they are not limited, like the white rami, to the thoracic and upper lumbar regions. Most of their fibres are non-medullated. They originate as post-ganglionic fibres from the cells of the sympathetic ganglion, and pass directly to the spinal nerve, in which they are conducted to their destinations, supplying efferent involuntary fibres to the periphery. Their functions are viscero-motor, vaso-motor, vaso-

inhibitory, and excito-glandular or secretory to epidermal structures—*e.g.*, sweat-glands, etc.

The autonomic system (or system of the "extended vagus") does not form a chain like the sympathetic proper, but consists of nerve-fibres with peripheral ganglia arranged in plexuses on the surfaces of the viscera supplied. They also have their corresponding white rami.

Some come from higher levels (*cranio-cervical autonomic*), either (*a*) from the mid-brain (along the oculo-motor nerve to the ciliary ganglion, and thence to the iris and ciliary muscle), or (*b*) from the medulla (along the nervus intermedius, glosso-pharyngeal, and vagus to various ganglia—spheno-palatine, otic, and sub-maxillary).

These white rami have their cells of origin in special nuclei in the brain-stem (Edinger-Westphal nucleus in the mid-brain, and nucleus lateralis in the bulb), which are homologous with the intermedio-lateral nucleus in the spinal cord. The vagus nerve is the largest and most important constituent of the cranio-cervical autonomic system.

Other autonomic fibres (*sacral autonomic*) emerge from the spinal cord at a level lower than that of the sympathetic proper—viz., through the second, third, and fourth sacral nerves (see Fig. 192), and pass to the descending colon, sigmoid, rectum, bladder, urethra, and genital organs.

The vegetative system has three great **pre-vertebral plexuses** lying distal to the ganglion-chain, near the large blood-vessels—the cardiac, the solar (or abdominal aortic), and the hypogastric. These plexuses are all situated mesially, and they receive branches from the cerebro-spinal nerves as well as from the vagi and sympathetic chains. They are distributed exclusively to the viscera, and send no fibres to the spinal nerves.

The *cardiac plexus*, receiving autonomic pre-ganglionic fibres from the vagi, and sympathetic fibres from all of the cervical ganglia, has a superficial and a deep division. The superficial cardiac plexus is situated in the concavity of the aortic arch; the deep division, much larger, lies behind the aortic arch, between it and the trachea. From these two divisions fibres pass on to the coronary and pulmonary plexuses. Distal to these again are the terminal ganglia in the walls of the heart and other viscera.

The *solar* (or *abdominal aortic*) *plexus* lies in front of the upper part of the abdominal aorta and of the pillars of the diaphragm. It receives autonomic pre-ganglionic fibres from the vagi, and sympathetic fibres from the greater and lesser splanchnic nerves, derived from the thoracic part of the gangliated chains. The solar plexus gives off numerous branches forming subsidiary or terminal plexuses around various branches of the abdominal aorta, and innervating the abdominal viscera.

The *hypogastric plexus*, which supplies the pelvic viscera, lies in the space between the two common iliac arteries. It receives sympathetic fibres from the lumbar ganglia, and, after dividing into the two pelvic plexuses, one on each side of the rectum, or vagina, receives sacral autonomic fibres from the third and fourth sacral nerves. The pelvic plexuses subdivide and supply the terminal ganglia innervating the rectum, bladder, and genital organs.

There are two main classes of reflexes within the vegetative nervous system. In one variety the centripetal path runs in a cerebro-spinal nerve, and the stimulus, on reaching the brain-stem, is reflected outwards along a fibre of the vegetative system. Examples of this class of reflex are salivation, sweating, flushing of the skin, the genital reflex,

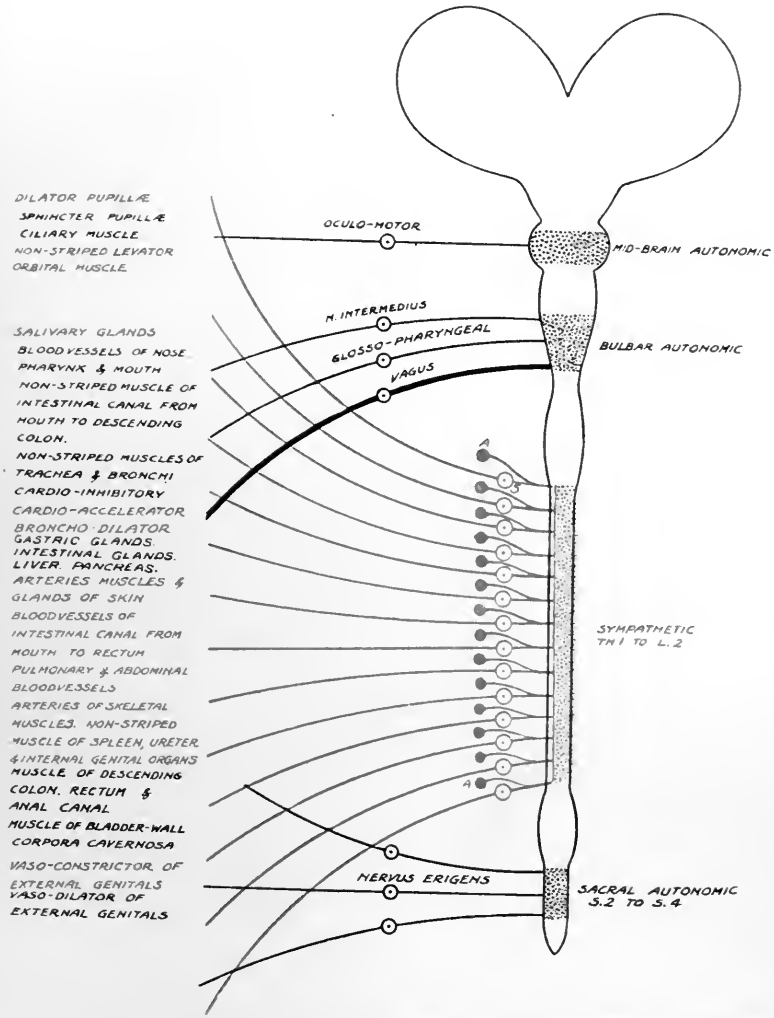

FIG. 192.—The vegetative nervous system, with its autonomic and sympathetic subdivisions. In the sympathetic, each nerve cell (S) has an adrenal secretory cell (A) in connection with it.

To face page 336.

etc. A second variety of vegetative reflex has both its afferent and its efferent limb running in vegetative paths, *e.g.* the ordinary movements of hollow organs which are under the control of peripheral plexuses (such as the gastro-intestinal tract, uterus, ureter, or bladder), all of which contract independently of cerebro-spinal stimuli.

The cutaneous and internal organs, containing non-striped muscle or secretory cells, are independent of our will. Nevertheless they can be profoundly influenced by the central nervous system through emotional stimuli such as anger, fear, pleasure, surprise, shame, sexual excitement, etc. Thus, for example, the processes of digestion are specially sensitive to emotional states, so that pleasurable experiences—an artistically laid table, a charming neighbour, a gently melodious orchestra—promote digestion, whereas painful or disagreeable sensations inhibit it.

With regard to the vegetative afferent fibres in the grey rami, it is well recognised that the viscera have a sensibility of their own, with special sensory end-organs, *e.g.* the Pacinian corpuscles, and are the starting-point of impulses which, like other sensory stimuli, are conveyed to the spinal cord along the posterior roots.

Normally these visceral stimuli do not reach our consciousness, so that in health we are unaware of the functional activity of our organs, except for occasional vague generalised sensations such as hunger[1] or thirst, or the sense of well-being following a meal or after certain local visceral activities, *e.g.* the emptying of a distended bladder or large intestine, or the sexual orgasm.

In diseased conditions, however, visceral sensory stimuli may be so intense as to give rise to conscious sensations. Such sensations may be generalised, as in the nausea of gastro-intestinal irritation or the air-hunger of respiratory obstruction. In other cases the sensations are localised, and are usually referred by the patient to the area of skin corresponding to the nerve-root which conducts the afferent impulse (see Fig. 191, p. 335). Thus we get the various "referred pains" of visceral diseases, and areas of cutaneous and muscular tenderness, *e.g.* pain along the inner border of the left arm in angina pectoris, hyper-æsthesia and localised muscular rigidity of the left upper abdomen in gastric ulcer, pain in the ipso-lateral testicle and hyper-æsthesia of the scrotum in renal calculus, and so on. Moreover, certain symptoms in hysterical and neurasthenic patients are strongly suggestive of visceral hyper-æsthesia (*cenæsthopathy*), where normal stimuli, which in health are unperceived, reach a morbidly sensitive consciousness.

Every organ, whether hollow muscular organ, blood-vessel, or gland,

[1] In addition to craving for food, and general malaise due to weakness and tissue-starvation, hunger may also be associated with specific *hunger-pains*, apparently due to waves of muscular contraction in the stomach; a variety of muscle-sense.

which is innervated by the vegetative system, has a double innervation, derived partly from the sympathetic proper and partly from the autonomic system, cranial or sacral. This innervation is not only a double one, but its two elements are mutually antagonistic, like a pair of reins. Under normal conditions these two forces are in equilibrium. According as the sympathetic or the autonomic influence predominates, so do we have variations in the activity of the particular organ.

Thus, for example, the heart receives autonomic (inhibitory) impulses from the vagus and sympathetic (accelerator) fibres through the superior cervical ganglion of the sympathetic. The pupil receives autonomic (sphincter) impulses through the oculo-motor nerve and sympathetic (dilator) impulses through the cervical sympathetic (see later p. 341). The intestine receives autonomic (motor and secretory) fibres from the vagus and sympathetic (inhibitory) impulses through the splanchnic nerve. At the lower end of the intestine the vagal autonomic fibres are replaced by those of the nervi erigentes derived from the sacral autonomic system. The genital organs receive their autonomic (vaso-dilator) fibres through the nervi erigentes and their sympathetic (vaso-constrictor) fibres from the hypogastric plexus.

Relation of the Vegetative System to Various Drugs and to the Ductless Glands :—

Autonomic fibres and end-organs are specially stimulated by cholin bodies and by pilocarpin. They are paralysed by alkaloids of the atropin group (belladonna, hyoscyamus, stramonium). Cholin, a product of normal tissue-metabolism, circulates in the blood-stream and acts as a hormone, exercising its specific action on the autonomic system. Autonomic stimulation is evidenced by some of the following phenomena:—myosis, deficient gastro-intestinal peristalsis, contraction of the uterus, ureter, bladder, and bronchial muscle, slowness and diminished force of the heart-beat, paresis of the abdominal blood-vessels, lowered blood-pressure, pallor of the skin, increase of glandular secretions throughout the body, etc. These effects, however, are not produced all at one and the same time.

Sympathetic fibres and end-organs, on the other hand, are unaffected by the cholin group. They are not paralysed by any agent yet known to us, but are readily stimulated by the hormones of chromophile glands, *i.e.* by adrenalin and its allies. This reaction of sympathetic fibres to adrenalin is intensified by certain other substances, such as cocaine, thyroid secretion (as in patients with exophthalmic goitre, in whom a few drops of adrenalin, instilled into the eye, may produce mydriasis markedly in excess of the normal), pituitrin (with its special action on the intestinal and uterine walls), etc.

The emotions of fear and rage are found to liberate an excess of adrenalin into the blood-stream. Thus the blood of a caged cat which

has been terrified by the barking of an excited dog outside the bars of the cage, shows an excessive percentage of adrenalin. This excess of adrenalin liberates sugar from the liver-cells into the blood to such an extent that transient glycosuria may supervene. Sugar, as we know, is the most convenient form in which energy can be rapidly supplied to exhausted muscles. In this way adrenalin lessens muscular fatigue for the time being, and this is of assistance in the physical struggle which may be called forth by the emotion.

It will be remembered that the cells of the supra-renal medulla, constituting the so-called para-ganglion cells, are derived from the same source as those of the sympathetic ganglia. The supra-renal gland is thus, in a sense, a part of the nervous system, and its para-ganglion cells secrete the adrenalin which maintains the sympathetic cells in their normal state of activity.

Morphine has a special action in depressing the sympathetic nuclei situated within the central nervous system, so that the autonomic system becomes unopposed, and as a consequence we have myosis, bradycardia, excessive sweating, etc.

Vago-tonus and Sympathetico-tonus.—Individuals may be classified into two great vegetative types, according as their autonomic sensitiveness prevails over their sympathetic, or *vice versâ*. The character of an individual may thus depend largely upon his reaction to cholin or adrenalin, or upon the relative abundance with which cholin and adrenalin are produced in his organism.

The autonomic or vago-tonic type of person is reserved and "cold-blooded," with slow pulse, contracted pupils, deep-set eyes, cool, pale skin, which sweats easily and sometimes in patches, also clammy hands and feet. Vago-tonic individuals often show other evidences of excessive vagal activity in the form of gastric hyper-acidity, bradycardia, asthma, mild respiratory arrhythmia, and sluggish bowel action, analogous to the asthmatic bronchial spasm. Sugar tolerance is high, so that relatively large amounts of glucose can be taken without inducing glycosuria. The blood shows a tendency to eosinophilia. They are also hyper-sensitive to vagal stimulation by vago-tropic substances such as pilocarpin (evidenced by bradycardia, ready sweating, salivation, nausea or vomiting, intestinal peristalsis, etc., produced by this drug), and to vagal depression by atropin (shown by acceleration of the pulse and slowing of intestinal movements).

The symptoms of sea-sickness are often vago-tonic in origin, and may then be obviated by atropin hypodermically.

Vago-tonia may be a family stigma. It may be generalised all through the body, or we may find a localised vago-tonia, limited to the cranial, the cervical, or the sacral division of the autonomic system.

Vago-tonic women sometimes have a masculine distribution of the pubic hair, which, instead of being bounded above by a horizontal line, extends upwards along the linea alba towards the umbilicus. These women have small mammary glands, and often a ring of hair around the nipples.

The sympathetico-tonic individual, on the other hand, is lively and excitable, with rapid heart, bright eyes, dilated pupils, rosy colour,

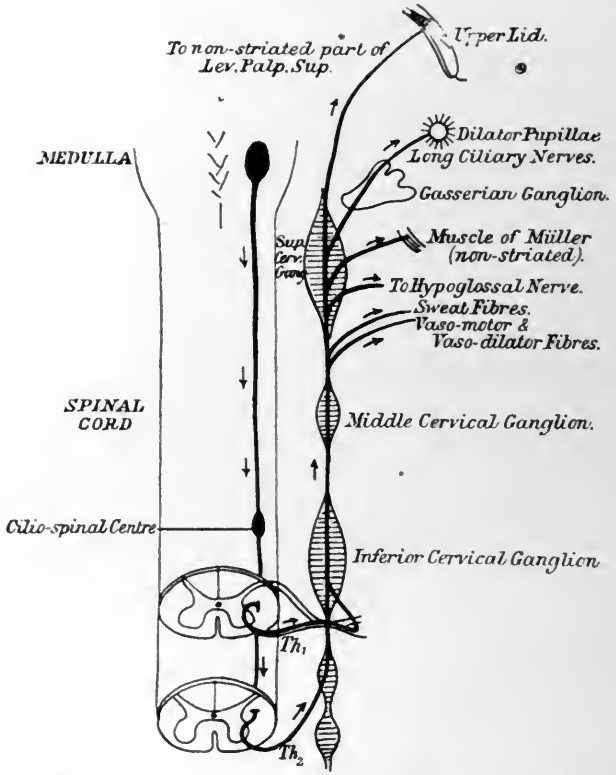

Fig. 193.—Diagram of course of oculo-pupillary fibres of cervical sympathetic.

and a warm, dry skin. Sympathetico-tonic individuals are specially sensitive to adrenalin, to thyroid secretion and to pituitrin, any one of which exaggerates all their characteristics.

The **cervical part of the sympathetic chain** has very special "oculo-pupillary" fibres, which are of considerable clinical importance. These supply the dilator pupillæ, the non-striated part of the levator palpebræ superioris and the orbital muscle of Müller—a small bundle of non-striated muscle which lies behind the globe of the eye and bridges across the spheno-maxillary fossa at the back of the orbit. The cervical sympathetic also supplies secretory fibres to the submaxillary gland, and, like the sympathetic elsewhere, it supplies fibres to the cutaneous blood-

vessels, also (through the hypoglossal nerve) to the vessels of the tongue, and, lastly, secretory fibres to the sweat-glands of the head and neck.

The pupil-dilating fibres have a peculiar course, which it is important to remember (see Fig. 193). Arising from the cortical centre in the frontal lobe, traversing the brain-stem to the pupil-dilating centre in the medulla, they descend in the lateral column of the spinal cord to the cilio-spinal centre in the lower cervical region. They emerge from the cord as pre-ganglionic fibres through the anterior roots of the first and second thoracic segments, and enter the inferior cervical ganglion of the cervical sympathetic by white *rami communicantes*. They then ascend

FIG. 194.—Paralysis of cervical sympathetic on the right side. The black line encloses an area of anæsthesia, due to division of cutaneous nerves.

as post-ganglionic fibres in the cervical sympathetic, behind the carotid sheath in the neck, up to the Gasserian ganglion, and pass thence to the orbit (along the ophthalmic division of the fifth cranial nerve), and *viâ* the long ciliary nerves to the pupil. They do not traverse the ciliary ganglion (see Fig. 61, p. 126).

It is evident that ocular and other symptoms may be produced not only by lesions of the ascending fibres of the cervical sympathetic in the neck, but also by lesions within the cord, affecting the fibres in their downward course from the medulla (this being remarkably frequent in syringobulbia and in unilateral lesions of the medulla), or by lesions of the first two thoracic nerves or of their anterior roots, or even by lesions of the ophthalmic division of the fifth cranial nerve, though this last is rare.

The signs of **paralysis of the cervical sympathetic** are very characteristic. Fig. 194 shows a woman who was sent to hospital with

the history that six years previously she had some tuberculous glands removed from the right side of her neck. When she recovered from the anæsthetic, she learned that the jugular vein had been damaged during the operation. But other structures had also been injured, and amongst them was the cervical sympathetic (which lies behind the carotid sheath), because afterwards she noticed that the right eyelid drooped a little, that the right side of the face flushed less than the left, and that when she chewed, a small patch of excessive perspiration appeared below the right eye. We observe from the photograph that the right pupil is smaller than the left, from paralysis of the dilator pupillæ. Moreover, the affected pupil does not dilate when shaded, yet it contracts briskly to light and on convergence, since the third cranial nerve, which through the ciliary ganglion innervates the sphincter pupillæ, is unaffected. Further, we notice that the upper lid droops, making the palpebral fissure narrower than on the healthy side. This is due to paralysis of the non-striated part (tarsalis superior) of the levator palpebræ, which is inserted into the upper edge of the tarsal cartilage. The voluntary, striated fibres of the levator, inserted into the skin of the upper lid and supplied by the oculo-motor nerve, are unaffected, and the patient is therefore able to elevate the lid voluntarily to its full extent. This, therefore, is not a true ptosis, but a "pseudo-ptosis."

Fig. 195.—Paralysis of the left cervical sympathetic from a tumour at the root of the neck.

We also notice that the right eye has sunk into the orbit, owing to paralysis of the non-striated orbitalis muscle of Müller, which normally keeps the globe pressed forwards. This "enophthalmos" narrows the palpebral fissure still more. The difference in antero-posterior projection between the two eyes is seen best if we make the patient lie down: we then stand behind and look down at the forehead and eyeballs from above.

On palpating the two globes, we find that the intra-ocular tension is diminished on the affected side.

Such are the "oculo-pupillary" symptoms of cervical sympathetic

paralysis. There are, however, one or two additional points. When the cervical sympathetic is paralysed, it no longer responds to stimulation. There are two clinical ways of stimulating it. One is by pinching or pricking the side of the neck, when we produce a dilatation of the pupil on the same side; this "*cilio-spinal reflex*" is abolished in cervical sympathetic palsy. Another method of stimulating the cervical sympathetic is to drop into the conjunctiva a few minims of a 5 to 10 per cent. solution of cocaine. The result is that the pupil dilates, the upper lid retracts, and the eyeball is pushed slightly forwards. All these phenomena were absent in the patient just referred to. She also told us that when her face flushes, it does so only on the

Fig. 196.—Radiogram, showing tumour at apex of left lung, in patient represented in Fig. 195.

healthy side. Moreover, her face on the affected side no longer sweats except in one little patch below the orbit, where it sometimes sweats spontaneously when she chews. To verify this point we made her sweat profusely by means of pilocarpin, and found that the right side of the face remained dry, except in a small area below the inner canthus of the eye. This survival of a little oasis of sweating on the dry side might perhaps mean that a small twig of the sympathetic had escaped injury, or more probably that sweat fibres to that part of the face are supplied through cranial autonomic fibres.

So much for lesions of the cervical sympathetic chain itself. But the oculo-pupillary and other fibres may also be damaged at some point between the spinal cord and the inferior cervical ganglion.

Fig. 195 represents a boy of seventeen who had felt a tingling sensation down his left arm for several months. A few weeks before he came under observation, he noticed that a swelling had appeared in the lower

part of the neck on the same side. At a glance we see that the cervical sympathetic is affected. There are pseudo-ptosis, myosis, and enophthalmos. The left cheek is a little fuller than the right. The cilio-spinal reflex was absent on the left side. On examining the root of the neck, we found that the left clavicle was bulged forwards at its inner end, the supra-clavicular fossa being filled up. Further, there was percussion-dulness all over the apex of the left lung, with diminution of breath sounds and of vocal resonance. There was also a strip of diminished sensation to touch and pain along the inner side of the left upper limb, reaching to the wrist and corresponding to the cutaneous areas of the first and second thoracic roots. Moreover, there was slight wasting of the hypothenar muscles of the left hand, supplied by the first thoracic root. The skin of the left hand was dry, whilst that of the right was moist, and the patient himself noticed that in hot weather only the right side of his face sweated. On comparing corresponding arteries of both sides we found that the pulse in the left upper limb was smaller than in the right. All this pointed to the presence of a solid mass behind the left clavicle, compressing the subclavian artery, affecting the first and second thoracic nerves, including not only their sensory and motor fibres, but also the cervical sympathetic fibres. This diagnosis was confirmed by radiography, which showed clearly (Fig. 196) a tumour at the apex of the left lung. This tumour grew rapidly, compressed the subclavian vein, producing œdema of the left upper limb, and within six months the patient died.

Fig. 197.—Rupture of brachial plexus on right side. Total anæsthesia of right upper limb below black line.

Fig. 197 is that of a seaman on an Atlantic liner who was thrown against an iron rail by a heavy sea, rupturing the whole of the brachial plexus on the right side. He was unconscious for a number of days, and during this period he was trephined over the left Rolandic area, on the supposition that the paralysis of the arm was of cerebral origin. In addition to complete motor and sensory paralysis of the upper limb, obviously of lower motor neurone type, resulting from the brachial plexus palsy, he showed very beautifully the oculo-pupillary signs of cervical sympathetic paralysis on the right side—enophthalmos, myosis and pseudo-ptosis (see Fig. 198). In this patient, however, the pupil still dilated to cocaine, probably because some pupil-dilating fibres, entering the cervical sympathetic from the second thoracic root, had escaped injury.

Figs. 199 and 199A are those of a soldier who came under my observation during the South African war in 1901. He had been wounded in the neck by a Mauser bullet. At the time of his injury he was lying on his face, firing at the enemy. The bullet entered his neck an inch and a half below the left mastoid process, crossed the

middle line in front of the vertebral column, and came out through the seventh right interspace in the posterior axillary line, lodging in his bandolier. He immediately felt a sensation "like an electric shock" all over his body, but especially in the right upper extremity, which became at once totally paralysed. He had hæmoptysis owing to perforation of the lung, and for a few days some difficulty of swallowing, probably due to injury of the œsophagus. In about three weeks the hæmoptysis gradually ceased, and the right upper limb recovered power, so that when I first saw him, two and a half months

FIG. 198.—Paralysis of right cervical sympathetic from rupture of brachial plexus.

after the injury, he was able to move it freely at all joints. Ever since the accident he had noticed that he did not sweat on the right side of the face and neck, nor in the right upper limb.

The photographs show that the patient has an area of slight analgesia (bounded by the thick black line) along the inner border of the right upper limb, corresponding to the areas supplied by the eighth cervical, first thoracic, and second thoracic nerve-roots. He also has slight weakness of the small muscles of the thumb, innervated by the first thoracic root. We also observe that the right cervical sympathetic is paralysed, so that he has contraction of the pupil, enophthalmos, and pseudo-ptosis on that side.

But there is a point of special interest in this patient's photographs. They demonstrate a point which, so far as I know, had not previously been mapped out in the human subject, viz. the extent

of skin supplied with sweat-fibres by the cervical sympathetic. In the tropical heat to which we were exposed, this patient sweated profusely, except in an area on the right side of the head, neck, upper limb, and upper part of the trunk. That area remained dry, and the boundary between sweating and non-sweating skin was sharp and distinct. In order to show this in a photograph, the happy thought occurred to blow powdered charcoal on the skin. This stuck on the sweating side, and was blown off on the dry side. We were then able to photo-

FIG. 199.

FIG. 199A.

FIGS. 199 AND 199A.—Paralysis of the right cervical sympathetic, from a bullet-wound of the lower roots of the brachial plexus. The area of the right upper limb within the black line is anæsthetic. The crosses on the trunk indicate the boundary of an area of anidrosis.

graph the non-sweating area, to which the cervical sympathetic should have been distributed. As may be seen from the pictures (Figs. 199 to 200), the boundary of this area, marked by crosses, runs down the middle line of the head and neck, and turns horizontally across the chest at the level of the third rib in front and of the spine of the scapula behind, including the whole of the upper limb.

Before leaving the subject of cervical sympathetic palsy, it should be mentioned that *excision of the cervical sympathetic* has been employed therapeutically in certain diseases. Thus in cases of glaucoma, ophthalmic surgeons have recommended this operation to diminish the intra-ocular tension, and a certain amount of benefit has resulted.

Bilateral excision of the cervical sympathetic has also been tried for the relief of epilepsy, in the hope of paralysing the vasomotor nerves to the cerebrum and thereby rendering the brain hyperæmic, especially in cases in which fits were ushered in by blanching of the face. But the results recorded have not been sufficiently good to warrant us in recommending this procedure.

Let us now consider briefly the reverse condition, viz. **irritation or stimulation of the cervical sympathetic.** The signs are exactly the opposite of those produced by paralysis. We therefore have dilatation

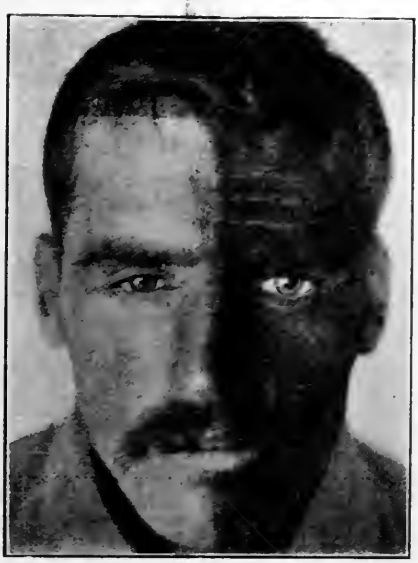

Fig. 200.—Paralysis of the right cervical sympathetic, showing oculo-pupillary phenomena and area of anidrosis.

Fig. 201.—Stimulation of the right cervical sympathetic.

of the pupil, exophthalmos or forward projection of the eyeball, widening of the palpebral aperture (Stellwag's sign), and delayed descent of the upper lid when the patient looks downwards (von Graefe's sign). All these phenomena can be produced, to a certain degree, by dropping into a healthy eye a solution of cocaine, which stimulates the cervical sympathetic.

Fig. 201 is that of a man who had lymphadenomatous enlargement of the lymphatic glands. During his stay in hospital, we noticed that quite rapidly, within a day or two, he developed on the right side exophthalmos, widening of the palpebral fissure, and some dilatation of the pupil. There was also in hospital at the same time a soldier who had similar signs in one eye due to an aneurism at the root of the neck,

pressing on and irritating the cervical sympathetic. If such pressure continues, the signs of stimulation may pass off and be replaced by those of paralysis. Our lymphadenomatous patient, however, died nine weeks after the appearance of stimulation phenomena, without any change in the direction of paralysis.

Certain cases of apical phthisis and apical pneumonia are accompanied by inequality of the pupils, probably due to irritation of the cervical sympathetic by changes in the pleura.

FIG. 202. FIG. 202A.

Exophthalmic goitre, the ocular symptoms being more marked on the right side. Fig. 202A shows von Graefe's sign in the right eye on looking downwards.

Many of the signs of **exophthalmic goitre** are sympathetico-tonic, resulting from excessive or perverted thyroid secretion. The disease is ten times more frequent in women than in men. Sometimes it comes on slowly; in other cases its symptoms develop rapidly after some emotional shock, such as fear or grief. Figs. 202 and 202A are from a case of exophthalmic goitre in which the symptoms are preponderatingly right-sided. The tachycardia of this disease is probably due to stimulation of sympathetic cardio-accelerator fibres. The thyroid enlargement may be in part the result of vasomotor paralysis of the cervical vessels, including those of the thyroid gland itself. The excess of lymphocytes and of eosinophiles in the blood, together with the

diminution of polymorphs, is probably also a result of the disordered thyroid secretion, which induces these blood-changes indirectly, by producing hyperplasia and hyper-activity of the thymus and of the lymphatic glands.

But though affections of the cervical sympathetic are the most readily recognised, we must not forget that the **thoracic and abdominal portions of the sympathetic** may also be diseased, although the symptoms thereby produced, being mainly visceral, are less easy of diagnosis. Thus some cases of angina pectoris may be the result of irritation of aortic fibres from the cardiac plexus, while the peculiar reflex vaso-constriction of the pulmonary vessels, with transient dilatation and irregularity of the right heart, met with in certain gastric and hepatic disorders, has been regarded as an affection of the thoracic part of the sympathetic.

Affections of the abdominal vegetative system produce still more striking clinical phenomena. An important group of *nervous dyspepsias* is associated with excessive vago-tonus, notably cases with hyper-acidity, pyloric spasm, and excessive gastric contraction evidenced by loud peristaltic rumbling noises. In such cases (as also in lead poisoning) treatment by atropin often has a markedly beneficial effect. The rare condition known as acute dilatation of the stomach, and many of the symptoms of acute peritonitis, such as the intestinal paralysis, meteorism, small pulse, and general collapse, may be the result of acute paralysis of the autonomic fibres of the solar plexus—the "abdominal brain"; while irritation of the solar plexus, and especially of its autonomic fibres, is exemplified in cases of lead colic, with its pain, constipation, and increased arterial tension. The various visceral "crises" of tabes—gastric, intestinal, renal, etc.—are probably due to irritative changes in various parts of the autonomic system. To the same cause also may be attributed the intestinal symptoms of exophthalmic goitre, consisting not in ordinary diarrhœa with loose motions, but rather in an abnormal frequency of defæcation. Spastic constipation, with its hard dry stools, and also muco-membranous colitis, with its paroxysms of increased peristalsis, accompanied by an excessive secretion of intestinal mucus, are probably both evidences of vago-tonus, and are often relieved by atropin. The apparent contradiction in ascribing constipation and diarrhœa to the same cause is explicable by the fact that in the one condition the circular muscle-fibres of the intestine are affected, producing constipation, whilst in the other the longitudinal fibres are affected, permitting diarrhœa. To solar or splanchnic disease may also, perhaps, be attributed such affections as orthostatic albuminuria and certain forms of glycosuria, and diabetes insipidus.

Acute vascular and degenerative changes can sometimes be demonstrated in the suprarenal bodies, *e.g.* in the algid type of malignant malaria and in fulminating meningococcal meningitis.[1] Such cases, clinically, show the symptoms of profound collapse with low blood-pressure, and call for the prompt administration of adrenalin intravenously, in addition to the other measures employed.

In addition to visceral disorders, disease of the abdominal sympathetic is also associated with certain pigmentary changes in the skin. Of these, the most striking examples are furnished by the cutaneous pigmentation which is occasionally present in exophthalmic goitre and, still more, by Addison's disease, with its characteristic bronzing of the skin, its asthenia, its extraordinarily low blood-pressure, and its paroxysmal diarrhœa. The symptoms of Addison's disease are probably the result of two factors—irritation of the abdominal sympathetic and inadequacy of suprarenal secretion, the proportional rôle played by each of these varying in different cases.

Angio-Neuroses.—These comprise a group of diseases which depend on disorders of the vegetative fibres regulating the heart and blood-vessels.

Amongst the commonest of these affections are the curious paroxysms to which Gowers has given the name of **vaso-vagal attacks.** These appear to be due to disorder of that part of the cranial autonomic system which comprises the vagal distribution to the heart, lungs, and other organs. The attack generally begins with an epigastric aura, quickly followed by violent, irregular, and rapid beating of the heart (transient auricular fibrillation), together with a sense of suffocative dyspnœa and sometimes a feeling of impending death. Meanwhile the limbs become very cold, followed either by burning flushes or clammy sweat, and by a distressing tension of the muscles. The paroxysms, varying in duration from a few minutes to several hours, recur at irregular intervals. They are specially common in women at the menopause. They can often be alleviated by small doses of nitro-glycerine.

A considerable amount of evidence[2] points to the conclusion that the paroxysmal unconsciousness of epilepsy is associated with sudden cerebral anæmia and that the tonic stage of a major epileptic fit is accompanied by cortical anæmia, whilst the clonic stage is associated with return of arterial circulation. It is uncertain what proportion of these phenomena is due to sudden stoppage of the heart (we may sometimes feel the patient's pulse stop at the onset of a fit) and how much to vasomotor spasm of cortical vessels.

[1] Maclagan and Cook, *R.A.M.C. Journal*, August, 1917, p. 228.
[2] A. E. Russell, *Lancet*, April 3, 10, and 17, 1909.

The paroxysmal expiratory dyspnœa of **asthma,** with its slow and laboured breathing, is doubtless due to excessive vago-tonus. The phenomena may either be the immediate result of a sudden vascular engorgement of the bronchial mucous membrane, or may be produced, according to another view, by spasm of the non-striated bronchial muscles, innervated by autonomic fibres in the vagus. Asthma is often relieved by atropin or by adrenalin, both of which drugs depress the vagus. In any case, the paroxysmal nature of the affection, its apparent toxic origin in some cases, its connection in other cases with nasal or other reflex sources of irritation, its frequent association with the gouty diathesis—all indicate a functional affection and not an organic lesion of the autonomic nervous mechanism.

Most angio-neuroses, however, affect the blood-vessels of the more superficial parts of the body, such as those of the skin or of the muscles. Amongst the cutaneous angio-neuroses, perhaps the commonest is the syndrome known as angio-spastic gangrene, or **Raynaud's disease.** The mildest degree of this is *local pallor* ("local syncope" or "dead finger"), where the affected parts, usually the fingers, less frequently the toes, the edges of the ears, or the tip of the nose, suddenly become cold to the touch and of a waxy white colour. Together with this, the patient feels a tingling or other peculiar sensation (acro-paræsthesia). Actual blunting of sensation to touch may be present. One or both hands may be affected, sometimes identical fingers in both hands; the thumb is less often affected than the other digits. The attacks last from a few minutes to several hours and are commonest in winter. They are often brought on by washing the hands in cold water, or by fine digital movements such as sewing or piano-playing. As the attack passes off, the patient feels a sensation of tingling or even of pain. A more severe variety is that of *local asphyxia* or cyanosis, in which the affected digits suddenly become discoloured, varying in tint from a dusky blue or slate-colour to an intense purplish-black. Pressure on the discoloured area causes a white mark which persists for several seconds, before the lividity slowly reappears. The pain is usually more intense than in local syncope. As the attack passes off, the affected part often sweats freely. But the most severe variety of Raynaud's disease is *symmetrical gangrene*, which is usually preceded by local asphyxia and sometimes by local syncope. As a rule, the gangrenous process is confined to a small part of the cyanosed area. In its mildest form the necrosis is limited to the epithelium, so that only desquamation results; more often a small blister forms, with blood-stained contents. This bursts, leaving an ulcer which subsequently cicatrises. The nails may be lost and subsequently reproduced. Or the necrosis may extend deep into the tissues, forming a dark slough.

Whole phalanges may undergo dry mummification and be cast off, leaving a conical stump. The bones as a rule escape necrosis. Pain is usually severe during the initial cyanosis.

The symptoms of Raynaud's disease are due to local spasm of the vessels, their sudden onset and disappearance being incompatible with any other hypothesis. The coexistent sensory symptoms are probably due to imperfect blood-supply. A paroxysm of local syncope or cyanosis can usually be relieved, as Cushing has pointed out, by applying a tight flat rubber tourniquet around the limb above, so as to occlude all the vessels, both arteries and veins, and leaving it on for several minutes. When the tourniquet is taken off, there is a temporary vasomotor paralysis, the whole limb flushes to the fingertips, and a wave of redness wipes out the local pallor or cyanosis. In rare cases paroxysmal impairment of vision has been noted, and during such attacks the retinal arteries on ophthalmoscopic examination have been seen to be spasmodically contracted. In paroxysmal hæmoglobinuria, Raynaud's syndrome is constantly present, to a greater or less degree.

In striking contrast with Raynaud's disease is the condition known as **erythromelalgia** (see Plate III.), which usually attacks one or other foot. There is pain of a burning or stabbing character, often of excruciating severity, occurring in paroxysms, lasting from a few minutes to several hours. This pain is always aggravated by dependent posture of the limb, by voluntary movement, or by warmth, whereas it is diminished by a horizontal or elevated posture, by rest, and by cold applications. The earliest attacks consist simply of pain. As the disease progresses, however, redness and swelling of the foot are superadded; more rarely, redness precedes pain. The redness is of a bright tint, often confined, for instance, to the ball of the big toe or to small areas of the sole or edge of the foot. Sometimes it is diffused over the foot. The redness increases in intensity, and if the limb be allowed to hang down, the " vascular storm " continues, with bounding arteries, local rise of temperature, and intense cutaneous hyperæsthesia. As the attack subsides the redness is replaced by cyanosis. In one case which I observed, desquamation of the affected area occurred after each paroxysm.

But there are other cases in which the vasomotor symptoms are intermediate in type between the two extremes of Raynaud's disease and erythromelalgia. These two diseases may coexist, or may succeed each other in the same patient. Erythromelalgia is sometimes one of the earliest signs of organic cord disease, such as disseminated sclerosis, and this points to its origin from an affection of the spinal vasomotor centres, probably in the " intermedio-lateral " group of smaller nerve-

PLATE III.

Case of **Erythromelalgia** in a man aged 52. The condition affected both lower limbs.

The upper drawing shows the appearance of one foot during a paroxysm when the limb is supported in a horizontal position. The sole of the foot is of a bright pink colour, this colour also extending on to the dorsum of the terminal phalanx of each toe.

The lower drawing shows the effect of allowing the other foot to hang dependent for a few minutes. There is extreme cyanosis extending as high as the ankle. There was also severe pain, partially relieved by re-assuming the horizontal posture of the limb.

To face page 352.

cells (nucleus sympatheticus lateralis) between the anterior and posterior horns.

In cases of recent total transverse lesion of the spinal cord, the lower limbs are usually abnormally warm, the temperature rising in a paradoxical fashion, as we approach the feet. This is due to vasomotor paralysis.

Fig. 203.—Family gangrene in three brothers, affecting the feet.

A few rare cases have also been observed of *family gangrene*, somewhat resembling Raynaud's disease.

Fig. 203 represents three brothers, aged, five, four and three years respectively, in all of whom, one winter, areas of local necrosis appeared in the feet. The eldest child had necrosis of the skin of both heels, followed by similar areas on the dorsum of the right foot and on the fourth left toe. The second child had cyanosis and some necrosis of the dorsal surfaces of both feet, whilst the youngest had severe necrosis of the hallux, fourth and fifth toes on the right side, and a smaller area of necrosis on the plantar surface of the left hallux.

It is possible that the paroxysms of *family periodic paralysis* (see p. 249) may be the result of a recurring vasomotor spasm of the anterior

spinal artery, which, as we have seen, supplies the anterior cornua of the spinal cord.

Another paroxysmal disease of angio-neurotic origin is intermittent arterial claudication, the symptoms of which we have already described (p. 241). Here the arteries not of the skin but of the deep structures are in a state of temporary spasm.

Amongst soldiers defending trenches in the winter season, *e.g.* in the 1914-15 campaign in Flanders—there occur numerous cases of **trench-foot.** Very few of the cases, however, are due to actual frost. True *frost-bite*, which is usually the result of intense dry cold, is characterised by sudden, massive tissue-death of the tip of an extremity, whereas trench-foot has a progressive invasion of the tissues, and when it shows gangrene does so in circumscribed patches. The factors producing trench-foot are prolonged exposure of the feet to cold mud and thawing snow, want of exercise of the leg muscles, together with prolonged constriction by tight putties and boots which undergo shrinkage when soaked. The signs are primarily vascular in origin, to which may be superadded the sensory phenomena of a peripheral neuritis. The toes become cold and pale, in some cases cyanosed and in rarer cases gangrenous. There is slight impairment of cutaneous sensation in the toes, with considerable pain and tingling. At the outset the peripheral arteries of the feet are tightly contracted, and there is a local rise of blood-pressure in the legs, which can be measured with a manometer. The vascular spasm produces local ischæmia, with numbness and pain. When the surrounding atmospheric temperature rises, the vessel-walls now become relaxed and even paralysed, so that vascular dilatation occurs, with exudation of serum into the tissues through the damaged capillary walls. Thus œdema of the feet may supervene, and in severe cases is associated with excoriation and secondary infection of the skin. This œdema may extend up to the knees. As the circulation begins to return, the pain becomes aggravated, and even after the circulatory phenomena have apparently recovered, pain may persist, with characteristic signs of peripheral neuritis. This is shown by the combination of impairment of sensation to light touches together with intense hyperæsthesia on pressure, so that for weeks the patient may be unable to stand or walk, owing to pain in the soles of the feet, especially in their anterior parts (see Fig. 151, p. 284).

Acute angio-neurotic œdema, or Quincke's disease, is undoubtedly a vaso-neurosis. It is characterised by paroxysmal attacks of sharply localised, hard œdema in the cellular tissue of various parts of the face, trunk or limbs. After lasting a few hours or days, the swelling, which is remarkably firm and does not readily pit on pressure, passes off spontaneously. It may also attack mucous membranes, for example,

those of the respiratory or gastro-intestinal tract. A gastric attack may cause urgent vomiting, an intestinal attack meteorism, colic, and bloody diarrhœa, and if the patient happens to have an attack in the larynx, death may result from asphyxia. In the skin, the parts most often attacked are the lips, cheeks and eyelids. The disease sometimes runs in families.

In recent hemiplegia we frequently notice that the skin on the paralysed side of the body is warmer than on the normal side, the difference in temperature between the two axillæ being as much as 1° F. or more.

In chronic hemiplegia it is not uncommon to find œdema of the hand or foot on the paralysed side. Œdema of the legs occurs in beri-beri, probably from special degeneration of the vegetative fibres in this variety of peripheral neuritis. Permanent coldness and cyanosis are very common in the paralysed limbs in cases of old anterior poliomyelitis. Even in warm weather the flaccid limb remains cold and sometimes blue in the hand or foot, as the case may be. Such cyanosis differs from that of Raynaud's group in being permanent and not paroxysmal.

Certain varieties of *urticaria* may be referable to affection of the nervous system, as in certain cases in which the characteristic itching wheals appear on sudden emotional excitement. These patients appear to have a specially low coagulability of the blood due to deficiency of calcium salts in the liquor sanguinis. But urticaria is much more often toxic in origin. *Dermographism*, on the other hand ("factitious urticaria" or "urticaria scripta"), is a reflex cutaneous phenomenon. It is elicited by stroking the skin firmly with a smooth, hard object, such as the head of a pin or the finger-nail. If, for example, we draw a diagram or write on the patient's skin in this way, a red area appears within a few seconds. The skin then becomes elevated into a hard, white ridge, which can not only be felt, but seen, as if the pattern or writing had been embossed on the skin (see Fig. 223, p. 398). This lasts for many minutes and passes off gradually. Unlike true urticaria, dermographism is unaccompanied by itching. The phenomenon is commonest in neuropathic people, but is not confined to them; it is particularly common in exophthalmic goitre,[1] and may sometimes be found in apparently healthy individuals. The strange malady known as intermittent hydrarthrosis appears to have an affinity with giant urticaria.

Lastly, we have to refer to certain **abnormalities of sweating** which are due to nervous disorders. We have already alluded to localised anidrosis or absence of sweat in certain cases of cervical sympathetic

[1] Dreschfeld, *Brit. Med. Journal*, November 18, 1905.

palsy. But sometimes we meet with *paroxysmal localised hyperidrosis* or excessive sweating. Figs. 204 and 205 show the areas of excessive sweating in two patients. In one the condition was congenital, and consisted in excessive sweating on the left side of the scalp and face, corresponding to the whole of the first division and part of the second division of the trigeminal. In the other, the whole area of the trigeminal on the right side was affected and the condition appeared at the age of twenty-eight. In both these patients, who were otherwise healthy, the paroxysms of sweating occurred only on chewing highly flavoured articles, such as onions or pickles. This condition suggests some hyper-excitability of the reflex sweating centre for the face, pos-

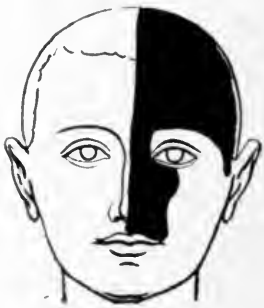

Fig. 204.—Area of localised sweating during mastication of pungent substances. From a man aged 29. The condition was congenital.



Fig. 205.—Area of localised sweating during mastication of pungent substances. From a man aged 35, in whom the condition appeared at the age of 28.

sibly within the pons. Fig. 206 is a photograph of an area of hyperidrosis on the left hand and wrist of a young woman of nineteen. In her, the paroxysms occurred three or four times a day, spontaneously, chiefly about the time of the menstrual period or when she was excited. In this case the distribution suggested a segmental area, apparently about the eighth cervical and first thoracic segments, and counter-irritation over the lower part of the neck, front and back, near the exit of these roots, produced rapid amelioration of the condition.

Thermalgia from partial lesions of mixed nerve-trunks, especially the median or sciatic, in which the vegetative fibres for the cutaneous vessels and sweat-glands are implicated, is usually associated with excessive sweating of the affected hand or foot (see also pp. 183 and 513).

In certain chronic cases of hemiplegia, we not infrequently observe excessive sweating of the hand and foot on the paralysed side. This is doubtless due to changes in the sweating centres in the central nervous system.

Transverse lesions of the spinal cord may also be associated with abnormalities of sweating, owing to affection of the nucleus sympatheticus in the intermedio-lateral column of the grey matter. This is conveniently demonstrated by means of a hypodermic injection of pilocarpin, the patient's body being previously, by a suitable cradle, protected from contact with the bed-clothes. Profuse sweating is



Fig. 206.—Localised hyperidrosis along ulnar border of forearm and hand. The dark area is due to powdered charcoal adherent to sweating skin.

produced in the parts above the level of the lesion, whereas the skin of the lower limbs and trunk remains dry, up to the level of the affected segment of the spinal cord.

For the first few days or weeks after a total transverse lesion of the spinal cord, during the stage of flaccidity with absence of deep and superficial reflexes, the skin of the lower limbs is dry. When the stage of reflex activity supervenes, with return of muscular tonus, reappearance of reflexes and reflex incontinence of urine, the skin begins to sweat excessively, as part of the "mass-reflex."

We have already referred to the vasomotor paralysis in the lower limbs, which occurs in recent acute total transverse lesions of the cord (p. 353).

CHAPTER XXI

THE NEUROSES

The boundary between organic diseases and the so-called functional diseases or neuroses is entirely imaginary. The old definition of a neurosis as a nervous disease devoid of anatomical changes is inadequate. Disease is inconceivable without some underlying physical basis. The lesion may be minimal in degree; it need not be visible microscopically; it may be molecular or bio-chemical.

The mere transiency or temporary character of nervous phenomena is no criterion of the absence of an organic cause. We need only recall the familiar subjective tingling produced in the ulnar side of the hand and fingers by a knock on the ulnar nerve (the familiar "funny-bone"); or the transient paralysis of the dorsiflexors of the ankle which may follow pressure upon the external popliteal nerve by sitting on a hard bench. In both these instances prompt recovery occurs, and yet the underlying cause was undoubtedly physical, organic. In the case of the ulnar nerve we may imagine some momentary oscillation of its nerve-fibrils: in that of the popliteal nerve, some transient interference with the lymph circulation within the nerve-trunk. If the physical force be more severe, or more prolonged, organic changes of a more lasting nature may be produced, *e.g.* contusion or effusion of blood, together with compression and degeneration of nerve-fibres, as in the well-recognised crutch-palsy of the musculo-spiral nerve. But the difference between these various examples is merely one of degree.

In certain chronic diseases, such as epilepsy or myoclonus, the essential underlying lesion is still disputed or undiscovered, yet we no longer class them as neuroses in the strict sense of the word.

A **neurosis** may be defined as a molecular abnormality of the nervous system (whether cerebro-spinal, or vegetative, or both together) characterised clinically by abnormal reactions to ordinary stimuli. These stimuli may be physical or emotional; they may arise outside or from within the patient's body. The abnormality of reaction may consist in excessive response, in diminished or absent response, or in some unusual or strange response.

We should never diagnose a neurosis on negative evidence alone, *i.e.* merely from the absence of signs of organic disease. To establish

a secure diagnosis, characteristic positive phenomena, physical and psychical, must also be present. We must recognise that the neuroses are real diseases, with positive clinical phenomena, as real as smallpox or cancer.

A sharp distinction must be drawn between a hysterical or a neurasthenic patient and a person who is deliberately shamming or malingering.

The hysteric is deficient in will-power and "cannot will." He usually has no knowledge of the disease which he may unconsciously simulate. The imitation of other diseases, *neuro-mimesis*, which is so often seen in hysteria, is not a voluntary affair. The various paralyses and pains from which hysterics suffer, although the result of suggestion, are as real to the patient as if they were due to gross organic disease.

The **malingerer,** or simulator, on the other hand, constructs his apparent disability, knowing all the while that he can perform the movement which he alleges he has lost.

The recognition of a malingerer is important. The essential point to determine is whether the patient has or has not intent to deceive the observer. This question is sometimes difficult to answer, for malingering includes not only the feigning of nervous disorders *de novo*, which is rare, but also the voluntary exaggeration of previously existing maladies, functional or organic, which is common.

The commonest variety of malingerer is the "perseverating" type, in which, after some real organic injury or illness, more often trivial than severe, the patient "keeps it up," *i.e.* he pretends that his symptoms are still persistent. Such a man, until suitable and tangible consolation (preferably in cold cash) is obtained, may either actively obstruct his own cure, or, passively, may do nothing to help to get well. A less frequent type is the "constructive" malingerer, who acts, from the outset, with deliberate intent to deceive, and constructs an artificial collection of dramatic symptoms. This patient, however, usually tends to overdo his part, and stumbles into pitfalls devised for him by the skilled observer, so that the self-contradictory nature of his alleged symptoms can generally be demonstrated. The pure malingerer usually dislikes being examined, whereas the hysteric thoroughly enjoys the chance of displaying his symptoms.

The three chief neuroses proper are neurasthenia, psychasthenia, and hysteria. Neurasthenia is an "exogenous" neurosis; psychasthenia is essentially "endogenous," or innate in the individual; so also is hysteria, although outside factors may act as exciting or precipitating causes. Each of these neuroses has distinctive characteristics of its own, but in practice they are often combined with each other and may also coexist with organic diseases. Thus a hysterical patient

may suffer from neurasthenia, or a psychasthenic patient from hysteria; nor is there anything to prevent a neurasthenic or hysterical patient from having, say, an attack of cerebral hæmorrhage. Moreover, any gross organic disease may induce hysterical or neurasthenic phenomena in addition to the signs of organic lesion, as in the well-known concussion-neurosis following a head-injury (see later, p. 545). In fact, certain forms of grave organic disease (especially disseminated sclerosis and some cerebral tumours) may at first produce symptoms which are indistinguishable from those of functional disease—which are, in fact, functional. In such cases the neurologist must be on his guard to detect the underlying organic affection, and to distinguish its symptoms from those of the superadded hysteria or neurasthenia. Functional symptoms, then, may coexist wth gross organic disease.

In studying the neuroses it is useful to recall certain preliminary psychological conceptions with regard to the processes of normal thought.

According to modern psychological teaching, the processes of our ordinary thoughts are guided in two entirely different ways. Firstly, by means of intelligent arguments or propositions, logical and "cold-blooded," whereby each element of thought follows from the one before, as in a mathematical proposition. This variety of thought, contrary to what might perhaps have been expected, is the less frequent of the two. The other, and much commoner, process which guides the stream of consciousness is the directing force of "complexes." By a "complex" the psychologist means a system of ideas strongly influenced by an emotional feeling-tone. Such an emotional tone, *e.g.* in the complex of love, disappointment, or hate, while it lasts, tinges all the mental processes of the individual, so that he regards everything, not in the cold, clear light of logic, but, as it were, through glasses tinted by his emotion. Every complex may be analysed into several fundamental forces or "instincts," combined in different proportions in each complex, *e.g.* the elemental instincts of self-preservation, self-assertion, self-abasement, the reproductive or sex-instinct, the herd-instinct, and so on. Man is, therefore, largely a creature of the emotions.

The modern conception of consciousness regards it as comprising several grades or layers. Firstly, there is the "active consciousness," comprising those thoughts which are actually in the individual's mind at a given moment. Secondly, there is the "liminal consciousness," or sub-consciousness, containing thoughts which can be recalled or reproduced by a slight effort of memory. Lastly, there is the "subliminal consciousness," a deeper grade of sub-consciousness, containing thoughts, usually of a painful nature, which can only be brought into

the active consciousness with difficulty, or by some round-about method. Thoughts in this sub-liminal consciousness are retained at that level by a mental effort of so-called " repression," so as to spare their owner from distress. Sometimes this process of repression succeeds; often, however, the painful thoughts will not be denied, but, from time to time, force themselves up to the level of active consciousness, *e.g.* during dreams, when the higher inhibitory centres are in abeyance, or in waking hours, when the individual's attention happens to be relaxed.

In certain individuals these sub-liminal complexes conflict one with another, one complex pulling the individual one way, and another complex in a different direction. For example, a soldier who is under shell-fire, and during the emotion of fear, may have two conflicting complexes; one, dominated by the instinct of self-preservation, urges him to run away; the other, based on the herd-instinct of discipline and pride of race, urges him to fight on. Of these two, the herd-instinct ought normally to be the dominant one. But if the two forces are so equally balanced that neither of them is strong enough decisively to influence the conflict between self and duty, a conflict which is complicated by the natural desire to get away from the danger and horror of his environment, he fails to solve the mental dilemma, and may develop some sort of psycho-neurosis.

This conflict is sometimes a conscious struggle; in other cases it is buried in sub-consciousness and is not realised by the patient. But in either case, so long as the conflict is undecided, the patient's psycho-neurosis persists, until he can be got to realise and to solve his conflict one way or another.

Clues to the existence and nature of such conflicts are often afforded by mental exploration (a better term than " psycho-analysis "). This may be carried out either in the waking state or in the hypnotic state, although this latter is seldom necessary. Mental exploration comprises a study of the patient's past emotional history, and of his present nocturnal dreams, which are indicative of his sub-conscious distresses or fears or unrealised desires. It also includes an investigation of his day-dreams, which are identified by inquiring of the patient what he tends to think of, when his thoughts wander of their own accord. We may thus discover that some special trouble inclines to crop up, which the patient instinctively tends to push away.

Let us briefly recall some of the characteristic symptoms of the chief neuroses—neurasthenia, psychasthenia, and hysteria—and note in what respects they differ, if at all, from analogous symptoms produced by gross organic diseases.

The syndrome known as **Neurasthenia,** or **nervous exhaustion**, is not a primary disease. It is exogenous, the result of something else. The commonest cause is over-strain, mental or physical, combined with some emotion of a disagreeable kind. It may also be produced by the abuse of drugs such as alcohol, tobacco, or cocaine; by sexual excess; or, again, by the toxins of various infective diseases such as influenza, enteric fever, etc., or by the auto-intoxication associated with dilatation of the stomach or with other forms of gastro-intestinal disease. Or neurasthenia may result from organic diseases, whether these be of the nervous system (*e.g.* tabes, disseminated sclerosis) or of other systems (as in gout, rheumatism, cancer, and so on). Eye-strain from uncorrected astigmatism is a common cause which is frequently overlooked. Lastly, a particularly frequent cause is traumatism, especially in railway accidents, which produce a common type of neurasthenia, including the so-called "railway spine." The worry and uncertainty of litigation after accidents of this sort are often an aggravating factor, both in traumatic neurasthenia and in traumatic hysteria. Patients with a low power of resistance are, of course, specially liable to become neurasthenic from any accidental cause, but we must remember that even healthy individuals, without neuropathic taint, may be rendered neurasthenic, as a result of over-strain or trauma, *plus* emotion.

The symptoms of neurasthenia are chiefly subjective. The patient complains of undue fatigue and feebleness of attention, so that sustained mental effort becomes impossible—so-called "brain fag." There is "irritable feebleness" and loss of emotional control, with general gloominess and depression of the whole nervous system. Painful and disagreeable sensations are felt too acutely, trifling causes excite him to anger or tears, whilst the reaction to pleasurable emotions is diminished. The patient's memory is, however, unimpaired, and he relates his woes with great wealth of detail. He is full of aches and pains, but on physical examination there is nothing to be made out in the way of anæsthesia or of true motor paralysis.

The sensory symptoms of neurasthenia include subjective sensations *ad infinitum*, all of them disagreeable. Pains and dysæsthesiæ of various sorts are specially common in the head and along the vertebral column. A tight occipito-frontal headache is the commonest variety.

Amongst the motor symptoms, the chief is muscular *asthenia* or excessive tendency to fatigue, so that every movement requires a painful effort of volition. When this affects the internal ocular muscles it constitutes *asthenopia* or tiredness of the eyes on attempting to accommodate as in reading. The tongue and limbs are often

tremulous, with a fine intention-tremor. Myokymia is not uncommon in the muscles of the face or limbs. But there is never a true motor paralysis. Individual movements, although they may be feeble, tremulous, and associated with an intense feeling of fatigue, are never impossible. The sense of fatigue in a neurasthenic patient, unlike that in hysteria, is, as a rule, uninfluenced by suggestion.

Cardio-vascular symptoms are common, including paroxysmal palpitation and a curious violent pulsation of the abdominal aorta, which may feel almost subcutaneous. Perhaps the commonest objective phenomenon of neurasthenia is shown by the rate of the pulse on change of posture. The normal difference between the recumbent and upright pulse-rates is from 8 to 10 beats per minute. A normal recumbent rate which becomes tachycardiac in the upright posture indicates severe loss of tone in the peripheral vessels, probably due to suprarenal insufficiency. In neurasthenia a wide difference between the pulse-rates in these two positions is practically always present. The blood-pressure is usually lower than normal. The hands and feet tend to be cold. The patient often complains of sudden flushes of heat or cold traversing the trunk, limbs, or face, also of paroxysmal sweating on slight exertion, whether physical or mental, or on emotional excitement, and so on. Sometimes we can see transient blotches of redness at the sides of the neck, spreading upwards over the angles of the mandibles on to the cheeks. The appetite of the neurasthenic is usually good, contrasting in this respect with the melancholic patient, who refuses food. Gastro-intestinal atony, however, is common, accompanied, almost invariably, by gastric dilatation, dyspepsia, and constipation. An element of auto-intoxication is thus superadded, which aggravates the general malnutrition. Sexual disturbances, *e.g.* frequent seminal emissions, premature ejaculations, deficient erections, etc., are not uncommon, and, when present, they loom large in the mind of the patient, who exaggerates their importance and misinterprets their significance.

The super-emotional condition of the neurasthenic patient can be physically demonstrated by means of the *psycho-galvanic reaction*. To elicit this, the patient sits with each hand in a bowl of water. Joining the two bowls is a galvanic circuit, in the course of which a delicate galvanometer is placed, carrying a small mirror, which magnifies the excursion of the needle by the reflection of a beam of light on to an enlarged scale. The galvanometer deviates markedly when any acute emotion affects the individual, there being a latent period of about three seconds before the reaction occurs. Thus, fear, anger, or even surprise, as from an unexpected loud noise, will induce a psycho-galvanic reaction. The neurasthenic patient is commonly

super-emotional, so that his reaction is excessive in amount. This is in strong contrast with the reaction of the hysterical patient, who is usually found to be sub-emotional, as demonstrated by his psychogalvanic reaction. The hysterical patient is really an actor, playing his part under the influence of suggestion, and although he may perform violent and dramatic fits, or other movements, his psychogalvanic reaction remains diminished or absent.

The superficial reflexes in neurasthenia may be exaggerated, especially the abdominal reflexes. Sometimes if we stroke the abdomen in a circular direction the umbilicus moves so smartly that it seems to be chasing our finger round. The knee-jerks in neurasthenia are sometimes abnormally brisk and accompanied by a sudden feeling of shock in the spine, making the patient start. True ankle-clonus, however, does not occur, and the plantar reflexes, if present, are of the normal flexor type. The sphincters are unaffected. Most neurasthenics are poorly nourished, but not all of them.

Psychasthenia, or **Mal-adaptation Neurosis**, is a much more serious affection, in which the mental phenomena overshadow the physical. The psychasthenic individual is one who cannot adapt himself to the realities of his ordinary life. Unlike neurasthenia, which is usually a disease of adult life resulting from some extraneous cause, psychasthenia is an endogenous disease, the culmination of an ingrained neuropathic heredity, and its earliest indications appear in adolescence or even in childhood. In short, the psychasthenic, like the poet, is "born, not made." Moreover, while neurasthenia is an eminently curable affection, the psychasthenic patient remains psychasthenic all his life, though his symptoms may be in abeyance.

The outstanding clinical symptoms of psychasthenia are the psychasthenic "stigmata," the obsessions, and the imperious acts.

The *stigmata* of psychasthenia may be psychical or physical. The psychical stigmata of psychasthenia are mental anergia and irresolution. The psychasthenic feels himself incapable of fixing his attention, whether for physical or mental effort; he has a feeling of general hesitation and doubt, and has to lean for moral support on others possessing a stronger character than his own. This anergia or defective will-power (*aboulia*) in psychasthenia differs from the anergia of true melancholia in that the psychasthenic is distressed by his anergia, and whilst desirous to act, finds himself unable to do so, despite extraordinary and even agonising efforts. The melancholic patient, on the other hand, is not merely anergic, but also apathetic, and his failure to act causes him little or no distress. Sometimes the psychasthenic has a feeling of double personality, in which he feels as if he had two

co-existing "egos." The double personality of psychasthenia differs from that of hysteria, in which the duality is an alternating one, and, as a rule, unknown to the patient.

The physical stigmata of psychasthenia are evidenced in the patient's actions. Everything he does tends to be clumsy and *gauche;* his very gait may be ungainly; sometimes he is a stammerer, and he may be so anxious about his stammer that the dread of stammering amounts to an acute "phobia." He is often a "*tiqueur*"; he is full of affectations and mannerisms. In addition he may have numerous neurasthenic symptoms, amongst which all sorts of cephalic sensations are specially common, *e.g.* sensations of fulness or emptiness in the head, of looseness or tightness, of creaking or sawing, and so on. Physical or mental over-exertion or excitement may even induce an epileptiform fit. Gastro-intestinal atony is common, with all its train of symptoms in the form of dyspepsia, constipation, etc.; the circulatory and vaso-motor systems may be affected, *e.g.* by paroxysms of palpitation, attacks of blushing or pallor, excessive sweating or abnormal dryness of the skin. The sexual functions are usually diminished; in male patients spermatorrhœa is particularly common. The general nutrition, as in neurasthenia, is usually below par.

The second great characteristic of psychasthenia is the presence of systematised *obsessions* or dominant ideas of various sorts. These are almost always of a depressing type and may be of the most varied forms. A psychasthenic obsession comes on spontaneously in paroxysms and cannot be inhibited by any effort of the patient. When the obsession arrives, it occupies the patient's entire attention, so that, for the time, he can think of nothing else. In the intervals between his paroxysms the psychasthenic is a fairly normal person, taking an interest in the ordinary incidents and pleasures of life. In this respect he differs essentially from the melancholic, whose depression is continuous, who lives in constant gloom and derives no pleasure from life. Although the obsession is often an idea which is repulsive to the patient, yet it is most insistent and tends to recur again and again. The patient recognises it as being a morbid idea, yet he cannot throw it off. The different obsessions vary in their tendency to become translated into actions. Thus, though psychasthenics often have obsessions of suicide, they very rarely attempt suicide; on the other hand, obsessions to steal (kleptomania), to drink (dipsomania), and to perform sexual acts are more difficult to resist. A certain proportion of professional "tramps" are simply psychasthenic individuals apparently of average intelligence, but obsessed by the impulse to wander from place to place and unable to settle down, even when offered the work for which they profess themselves to be looking.

We should note that though the psychasthenic patient may have obsessions, he has no delusions or hallucinations; his reasoning powers are unimpaired. He must therefore be clearly distinguished from the insane patient.

The third characteristic feature of psychasthenia is the occurrence of *imperious acts* (*i.e.* an irresistible tendency to perform some special act), and of paroxysmal *imperious ideas*. Imperious acts include the innumerable varieties of *tics* (see p. 89). As to the paroxysmal imperious ideas, these include such varieties as the mania for perpetually asking questions (*folie de pourquoi*), the mania of fussy tidiness, the mania of counting things over and over (*arithmomania*), the mania of searching for objects, and so on. *Manias* of this sort, of course, interfere with normal mental processes, interrupting them to such an extent that the patient finishes by accomplishing practically nothing in the way of mental work. Imperious ideas may also be of an emotional nature; these include the innumerable forms of **phobia** or morbid fear, such as agoraphobia (fear of being in open spaces), claustrophobia (fear of being inside shut doors, especially of public buildings), anthropophobia (fear of crowds), monophobia (fear of being alone), aichmophobia (fear of sharp objects), rupophobia (fear of dirt), toxicophobia (fear of being poisoned), ereutophobia (fear of blushing), fear of darkness, fear of death, fear of illness, fear of performing organic functions such as micturition or defæcation (*coprophobia*), unreasonable fear of certain animals or insects, and so on, *ad infinitum*.

In most of these psychasthenic phobias there is, coexistent with the repulsion for the particular act or object, a strong attraction to that same object or act. This mixture of apprehension and attraction, as Raymond[1] has pointed out, is one of the causes of the mental agitation which accompanies a psychasthenic phobia.

Lastly, we come to the subject of **Hysteria, Suggestion Neurosis,** or, as Babinski prefers to term it, **Pithiatism** (from ἠπειθώ, to persuade, and ἰατός, curable). This is a psychical condition manifesting itself chiefly by symptoms which can be reproduced by suggestion, and which can be made to disappear again by persuasion and suggestion. *Persuasion* is the endeavour to destroy a morbid mental process by the logical force of arguments, whilst *suggestion* attempts the same thing in the absence of logically adequate grounds, and by the employment of emotional factors.[2] This modern and precise definition of

[1] *Bulletin Médicale*, 1907, No. 30.

[2] It must be remembered that the dramatic sudden removal of some bodily functional disability by means of suggestion is not necessarily a permanent cure of the hysteria. So long as a psychical conflict is allowed to persist in the patient's sub-conscious mind, the same (or some other) disability is liable to develop later, on

hysteria has the great advantage of clear limitation, whereas in former days hysteria was regarded merely as a collection of symptoms in which each observer included such phenomena as he fancied.

Hysteria is a disease which is much commoner in women than in men, in peace-time, at any rate. It is more frequent during adolescence and adult life than in childhood or old age, although it may sometimes occur in little children of 8, 6, or even 4 years. Whilst no race and no people is exempt from hysteria, it is relatively more frequent in the Latin races and amongst the Jews. Many cases of hysteria have a nervous heredity. Hysterical, alcoholic, or tuberculous parents are prone to have hysterical children. We frequently find physical or emotional shocks as exciting causes, or a combination of the two, as for example after a shell-explosion in war-time, an earthquake, a stroke of lightning, an electric shock, or a railway accident, especially if this latter be followed by litigation. Suggestion by other hysterics may produce epidemics of hysteria, whether in adolescents as in girls' schools, or in adults as in certain religious "revival meetings."

In some cases there is a sexual element in the causation, though much less constantly than Freud and his followers would have us believe. According to **Freud's hypothesis,** hysteria and other psychoneuroses are supposed to be due to "repression" of some old emotional trauma, usually of a sexual character.

If we discard the narrow pan-sexual dogma and approach the matter with open minds, it will be found that mental exploration sometimes yields important information, valuable both for diagnosis and for treatment. At the time of some original emotional incident, the feeling to which it gives rise, instead of gaining vent, as in health, either in satisfaction of the desire or in vigorous refusal to yield to it, in the hysterical individual becomes repressed or thrust back into the patient's subconscious memory, thenceforward gaining expression from time to time in an abnormal fashion under the guise of some nervous symptom or some phobia or obsession. If this "repressed" trauma, this skeleton in the secret cupboard of the mind, can somehow be dragged forth to the patient's consciousness, the hysterical symptom is supposed to become dispersed by a process of "mental catharsis," so that conscious control is substituted for automatic expression.

The original trauma is "dug up" by the process of mental exploration or so-called **"psycho-analysis."** This consists in a detailed scrutiny of the patient's past history, from childhood onwards, so as to try and identify the precise circumstances under which the symptom first arose.

---

the slightest provocation. The nature of the underlying psychical conflict is detected by the process of mental exploration or analysis. Therefore, successful psychotherapeutics rests upon a tripod of persuasion, suggestion, and analysis.

For this purpose Jung's **word-association method** is sometimes employed, in which a long series of test-words (stimulus-words), consisting of carefully-selected nouns, verbs, and adjectives in everyday use (of which a certain number have been specially selected in view of the physician's previous study of the patient),[1] are one by one read to the patient, who has been previously instructed to listen attentively and to reply as quickly as possible to each test-word with the very first word or phrase which the stimulus-word suggests to his mind (*e.g.* "snake—poison, pain—tears, sister—darling, yellow—hideous," etc.). The physician not only makes a note of the response-word given to each stimulus-word, but at the same time, by means of a stop-watch registering fifths of a second, he records the interval of time in each case between the stimulus-word and the reaction-word. In ordinary persons the average reaction-time is from six-fifths to twelve-fifths of a second.

In hysterical patients various peculiarities in the responses indicate the existence of certain trains of thought of high emotional value, so that the patient hesitates, pauses, or sticks over certain words in the list, has a difficulty in responding, or shows other abnormalities of response. One of the chief peculiarities in response consists in undue delay in reaction-time with certain test-words, a delay which may amount to twice or three times the average reaction-time taken for the other test-words. In some cases delay is due to distraction of attention, in others it is due to sub-conscious emotion, in which case it has an important diagnostic significance. Or there may be a failure to respond at all, or a senseless, silly reaction. Or the response may be a mere repetition of the test-word, or a repeated use of the same response-word, indicating an emotional reaction of some kind. "Clang" reactions, depending on sound (*e.g.* "window—winter," "Moses—noses"), are generally indicative of disturbances of attention.

On looking through the complete list of test-words, reaction-times, and responses, and having discovered one or two peculiar responses of this sort, the psycho-analyst proceeds to cross-examine the patient as to the thread of sub-conscious thought which connects the stimulus-word with the delayed or peculiar response-word. This thread, in Freudian hands, always proves to possess a sexual continuity.

The psycho-analyst also studies the patient's dreams. These are supposed to represent either the imaginary gratification of ego-centric desires that have undergone repression in daily life—*i.e.* a wish-fulfilment; or sometimes they may represent a fear-fulfilment, as in war-dreams, which are nightmares in which the patient dreams of being relentlessly shelled. Dreams include not only night-dreams, but also day-dreams. The physician inquires as to what the patient tends to think of when the mind is, as it were, running of its own accord, and tries to discover whether any special thoughts incline to come into his mind, which he tends to push away. On the theory that the latent content of dreams and of neurotic symptoms is always of a sexual nature, the Freudian enthusiast submits the patient's dreams to similar "analysis" and constructs ingenious comparisons between the dream and the patient's symptoms.

[1] The following is a series of test-words taken from Jones's book:—

Coal, brother, mount, tea, drop, cow, pin, blood, tree, snow, rail, plate, touch, train, roof, rub, bag, watch, jump, mouse, post, blue, pot, stick, chair, ball, sheet, egg, wood, note, fire, sister, cup, warm, turn, waste, dog, hand, tongs, stone, table, ride, paper, room, red, live, back.

To the non-Freudian physician many of these "analyses" appear prurient and far-fetched. As Jones admits, "particularly with the more complex analyses, doubt must always arise concerning the trustworthiness of the results."[1] Freud deserves credit for emphasising the sexual element underlying a considerable proportion of cases of hysteria and of other psycho-neuroses, but it is a grotesque exaggeration to attribute every case of neurosis to a trauma of purely sexual origin, and to ignore innumerable other sorts of traumata, physical or emotional.

Hysterical states shade imperceptibly into normal mental states, there being no hard and fast line of demarcation. A certain susceptibility to suggestion and a certain emotional reaction exist, in normal individuals, in widely varying degrees. Such phenomena are especially marked in children. In fact, as Schnyder[2] has said, we may speak of the "physiological hysteria" of childhood. But if an adult reverts to the childish susceptibility to suggestion and to infantile emotional reactions, we consider him or her pathological, hysterical in fact.

Hysterical individuals, with few exceptions, belong to the category of the inefficient and unsuccessful members of the community. It is true that the hysterical individual may be free from gross intellectual deficiencies, but nevertheless he is sub-normal.

The symptoms of hysteria tend to vary, to some extent, with the social education of the patient. It is chiefly hospital patients and litigants of the so-called working-classes who show the grosser phenomena such as paralyses, contractures, deafness, blindness, etc.; whereas in patients from the middle and "upper" classes, hysterical phenomena are usually expressed by more complex symptoms, visceral or psychical.[3]

For purposes of convenience we shall consider the symptoms of hysteria in four groups—psychical, sensory, motor, and lastly, visceral and vascular. In each of these groups we may find excess, diminution, or perversion of the normal nervous processes.

Psychical Symptoms.—These are invariably present in hysteria to a greater or less degree. The most outstanding feature is *deficiency of inhibition* or psychical instability. The patient *reacts* in an abnormal fashion *to suggestions* or stimuli, whether originating in the outside world or within her own body. One of the most striking instances of this is found in the phenomena of hypnotic suggestion, whereby a peculiar form of temporary hysteria—the hypnotic trance—is artificially induced by suggestion, and can be made suddenly to disappear

[1] Ernest Jones, *Psycho-Analysis*, London, 1913.
[2] *Journal de Neurologie*, 1907, p. 281.
[3] Dercum, "Rest and Suggestion in Nervous Disease," 2nd edition, 1917, p. 96.

by the same means. This disappearance of symptoms during or after hypnosis is sometimes taken advantage of in the treatment of hysteria by hypnotic suggestion. It is open to the objection that, instead of strengthening the patient's feeble inhibition, it temporarily multiplies that fault, by increasing the suggestibility of an already abnormally-suggestible individual. Yet if the result be that the patient has a hysterical suppression of her hysterical symptoms or an inhibition of the inhibitory centres (on the mathematical principle that $- \times - = +$) it is, none the less, of therapeutic value. But results obtained by this

FIG. 207.

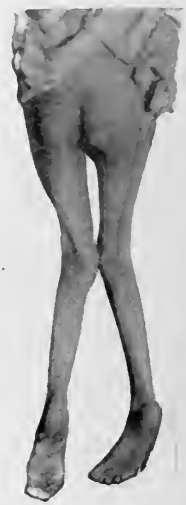

FIG. 207A.

FIGS. 207 AND 207A.—Case of hysterical paraplegia of fourteen years' duration. Showing a characteristic hysterical posture of the feet when the patient is passively supported.

plan are less likely to be permanent than when we strengthen the patient's inhibition or self-control without hypnosis.

Abnormal suggestibility and deficient inhibition being the keynotes of the hysterical "ψυχή," we find, accordingly, that the patient is unstable, reacts dramatically to emotional stimuli, is changeable in disposition, often excitable and perhaps passionate. She giggles or cries on slight provocation, and one of the most familiar forms of hysterical "fit" consists merely in an emotional reaction of alternate loud laughter and crying. Her will-power is feeble, her mental field of vision is narrowed, and she is morbidly introspective and swayed by passing whims; and this want of self-reliance leads to another very characteristic symptom—the craving for sympathy. If that sympathy be shown, as is so often the case, to an injudicious extent by the patient's

relatives and friends, her recovery may be indefinitely delayed. Hence it is generally of supreme importance to remove the hysterical patient completely from her old surroundings, and to isolate her from the baneful influence of unwise suggestions.

Figs. 207 and 207A are photographs of a woman aged 37, who for over fourteen years had lain on a bed of sickness unable to move her legs, a case of hysterical paraplegia. But she was cherished by the sympathy of a devoted mother and of various benevolent lady-visitors, anxious to soothe her dying moments. She was at last admitted to hospital, where, as a result of six weeks of isolation, massage and persuasion, she recovered the power of walking, as will be seen from the other photograph (Fig. 208).

FIG. 208.—The same patient as in Figs. 207 and 207A, after six weeks' treatment, showing restoration of power of walking.

It is convenient to mention here, in connection with the psychical symptoms, the *hysterical affections of speech.* Sometimes there is excessive volubility —a *diarrhœa verborum.* In other cases we find the reverse condition of **hysterical mutism,** in which the patient is absolutely dumb. This is a common variety of war-hysteria following shell-explosion. Sometimes it is combined with hysterical deafness, thereby producing hysterical deaf-mutism. The hysterically mute patient can usually express himself fluently, both by writing and by pantomimic gestures. Hysterical aphasia usually deviates in some gross or paradoxical fashion from organic aphasia. It is often accompanied by curious tricks of pronunciation or of intonation. In less severe cases we find merely loss of voice, or **hysterical aphonia**—where the patient can only utter her tale of woe in a whisper, breathing it softly into the ear of a sympathetic listener. Hysterical aphonia has characteristic laryngoscopic appearances, in the form of adductor paralysis of the cords, with which we are familiar (Fig. 80., p. 160).

Patients with mutism or aphonia sometimes suddenly recover their voice when the dominant obsession is loosened, *e.g.* by administration of chloroform (by the physician), or of an excess of alcohol (by the patient), or by some sudden shock, physical or mental. Intra-laryngeal faradism cures immediately many cases of hysterical aphonia.

Articulation in hysterical and psychasthenic patients may be affected in all sorts of curious fashions. I have seen several patients who drew a breath after each separate syllable, *e.g.* "hos—pi—tal." Some hystero-psychasthenic "*tiqueurs*" interpolate curious barking, grunting, or snorting noises amongst their words. One lady was afflicted in this way to such an extent that new neighbours who settled in an adjoining house thought the noise was made by a sick dog, and made a humane suggestion that the animal should be put out of its pain. And yet this lady could recite long dramatic passages of poetry and prose, though in ordinary conversation, or even when not talking, her bark made her society a mixed pleasure.

Stammering in its different varieties is not uncommon in hysterical and psychasthenic individuals. Unlike ordinary psychasthenic stammering which comes on in childhood, hysterical stammering may develop suddenly in adult life. Thus in a hospital nurse aged 33, who stood up sharply and knocked her head against a mantel-shelf, severe hysterical hemiplegia came on next day, followed, some six weeks later, by stammering, which lasted for several months. A patient with a hysterical stammer usually takes it more or less as a matter of course, and it does not cause the same emotional reaction as in a psychasthenic stammerer.

Sensory Symptoms.—These are of great diagnostic importance. We owe mainly to the work of Babinski the recognition of the fact that all the sensory phenomena of hysteria (whether in the form of hyperæsthesia, paræsthesia, or anæsthesia) are the result of suggestion. This may originate from the patient himself (auto-suggestion), or from without (hetero-suggestion), and especially from an incautious examining physician. Of these two varieties, auto-suggestion commonly plays the more important rôle. In a normal adult, suggestion fails to produce the sensory phenomena of hysteria.

Pain of some sort occurs in many cases of hysteria. Unlike ordinary pains, which are generally caused by some peripheral irritation, hysterical and neurasthenic pains are entirely central in origin—*psychalgia*—and should really be classed as hallucinations. But in every case we must be careful to see and to examine the painful spot, and to exclude peripheral irritation, before labelling any pain as hysterical or neurasthenic.

Hysterical pains may be referred to any part of the body; but they

are especially common in certain situations. For example, hysterical headache is often of the "clavus" type, which is a boring pain localised to one small spot on the skull. Occipital headache is particularly common, so is hemicrania. Pain in the breast—mastodynia—or in the joints may lead to difficulties in diagnosis. Hysterical pains in the spine often simulate those of organic disease. They frequently follow a local trauma of some sort, and are a fruitful source of litigation. The spinal pain may either be vague and diffuse, or it may be localised to some special spot. It is usually associated with stiffness of the back, due entirely to muscular rigidity, not to bone-disease. At first the vicious posture can be reduced comparatively easily by gentle passive movement, but gradually it tends to become permanent and irreducible (until after the claim for compensation is settled, one way or the other). Differential diagnosis of such cases is often difficult, and demands the greatest caution on the part of the physician. This difficulty of diagnosis is increased by the fact that there may originally have been some organic lesion of sorts, *e.g.* bruising or laceration of the spinal muscles, to which a psychical element has been superadded, persisting long after the original cause has passed away. Moreover, an element of malingering is often superadded. These are amongst the most difficult cases with which the physician has to deal. It is only by careful local and general examination, revealing the presence of other hysterical phenomena and the absence of signs of structural disease, that we can avoid errors. Cases have been known in which amputations have been performed for hysterical joint-pains. Some time ago I saw a young lady who, on account of intractable pain, had already had one toe removed by a surgeon, but the pain recurred in another toe, and the case was undoubtedly hysterical.

Closely related to these pains are the *areas of hysterical hyperæsthesia*, and especially of hyperalgesia or excessive tenderness. Pain on pressure over certain spots, whether such pain be functional (hysterical or neurasthenic) or organic in origin, has occasionally to be differentiated from the simulated tenderness of a malingerer. In such cases *Mannkopf's sign* is sometimes useful. This consists in a change in the pulse-rate whilst the painful spot is being pressed upon—usually a temporary acceleration of from 10 to 30 beats per minute. This is commoner in neurasthenic and hystero-neurasthenic cases than in pure hysteria. Sometimes, on the other hand, the pulse is slowed, especially in cases of scars from organic injuries.[1] In cases of malingering, however, no alteration in the pulse-rate is produced. The psycho-galvanic reaction, to which we have already referred (p. 363), is also a valuable means of distinguishing true from simulated pain.

[1] Hudovernig, *Neurolog. Centralbl.*, 1910, s. 408

Universal hyperæsthesia occurs, though rarely, and we also meet with cases of hemi-hyperæsthesia. More usually this excessive tenderness is limited to small areas—little islands of skin or subjacent tissues of the head, trunk or limbs. Sometimes the tenderness is cutaneous and elicited by gentle stroking of the skin; sometimes it is subcutaneous, and only elicited on deeper pressure.

Such tender points are chiefly situated in the vertebral, infra-mammary, epigastric, and inguinal regions, and except when mesial, are more frequently left-sided (except in left-handed people, in whom they are more commonly right-sided). Tender points are less common on the head, and rarest on the limbs.

Of all the tender spots, that in the left inguinal region is perhaps the best known. From some supposed connection with the ovary, it has been called "ovarian" tenderness, but the symptom is as frequent in male hysterics as in females, so that the term is a misnomer. Moreover, in this connection, Steinhausen[1] examined 500 healthy soldiers—males, not Amazons—and found that in no less than 88 per cent. brisk pressure in the inguinal region on either side produced a reaction of some sort, the phenomena being either sensory (unpleasant tickling or pain), motor (hardening of abdominal muscles, various reflex and protective movements), emotional, or vaso-motor and sympathetic (dilatation of pupils). And yet there was not a single ovary amongst them.

These tender points may be associated not merely with pain, but with so much emotional disturbance as to be actually *hysterogenic*. This does not mean that they induce hysteria—the hysteria is already present. It means that pressure on such a spot induces a hysterical fit or paroxysm. The best-known hysterogenic area is in the left inguinal region, but such areas may be anywhere. I remember one patient who had a hysterogenic spot in one axilla and who wore a sort of truss over it, to protect it from accidental pressure.

Sometimes deeper pressure on the hysterogenic spot or elsewhere may arrest a hysterical fit when in progress. Areas, pressure upon which causes cessation of the paroxysms, are called *hysterofrenic*. The inguinal region is the best known of these. Strong faradism over the inguinal region will stop most hysterical fits; so also will a hypodermic injection of apomorphine with its resultant vomiting.

Hysterical hyperæsthesia may also affect the special senses, so that there may be hyper-sensitiveness of smell, vision, hearing, or taste. This is less common than loss or diminution of special senses, to which we shall refer later. For some time I had under my care a patient

[1] Steinhausen, *Ueber die physiologische Grundlage der hysterischen Ovarie. Deutsche Zeitsch. f. Nervenheilk.*, xix., s. 369.

who could not tolerate bright light, especially if the room had a blue wall-paper. He preferred to stay in a darkened chamber; or if the blinds were up, he shaded his eyes with his hand. After some weeks of psycho-therapeutic treatment, he completely lost this photophobia.

In rare cases an actual enlargement of the visual field has been observed, generally in one eye only. Thus, in a soldier with hysterical wry-neck and anæsthesia of one side of the body, the visual field on the non-anæsthetic side, when measured with the perimeter, was much larger than in a normal individual.

Hysterical anæsthesia is extremely common, and is of great diagnostic value. If we test a casual series of individuals for hemi-anæsthesia, making free use of suggestions at the same time, the normal individual fails to develop anæsthesia, whereas many of the hysterical individuals, owing to their special vulnerability to suggestion, will show an anæsthesia of characteristic type.

Hysterical anæsthesia, although fundamentally due to suggestion, usually auto-suggestion, is usually unnoticed by the patient herself, and only discovered on examination by the physician.[1] Sometimes, however, the patient complains of spontaneous numbness, and this is chiefly in cases when the affected limb has motor paralysis as well, so that her attention is called to it.

Janet showed an ingenious method of demonstrating that in some cases of hysterical anæsthesia, sensory impulses really reach the brain-centres, where they are actively suppressed by the patient. Taking a case of complete hemi-anæsthesia, he makes the patient shut her eyes, and tells her to say "Yes" each time she feels a touch or prick and to say "No" when she does not feel it. In certain cases the patient not only says "Yes" every time she is touched on the normal side, but also says "No" every time she is touched upon the anæsthetic side. In other words, the patient feels, though she does not know that she feels. This so-called "Yes-No" test is pathognomonic of hysteria, and demonstrates the "unreality" of the anæsthesia. It is often difficult or impossible to elicit this test successfully at a subsequent séance, for the patient soon learns its significance and does not readily fall again into the trap.

Cutaneous anæsthesia in hysteria may be complete or partial in

[1] Babinski considers that hysterical anæsthesia is always the result of suggestion by the examining physician. With this view I cannot entirely agree. Many hysterical patients who are highly susceptible to suggestion have no anæsthesia. Moreover, undoubted cases of hemi-anæsthesia have been known to develop before any medical examination had taken place, the anæsthesia being discovered accidentally either by the patient or by some lay observer. Moreover, why should we pick out sensory symptoms and say that they are suggested by the physician? Why not include motor symptoms also? Why not all the symptoms? If, as Babinski admits, the patient is capable of producing his motor symptoms by auto-suggestion, why can he not produce sensory symptoms at the same time?

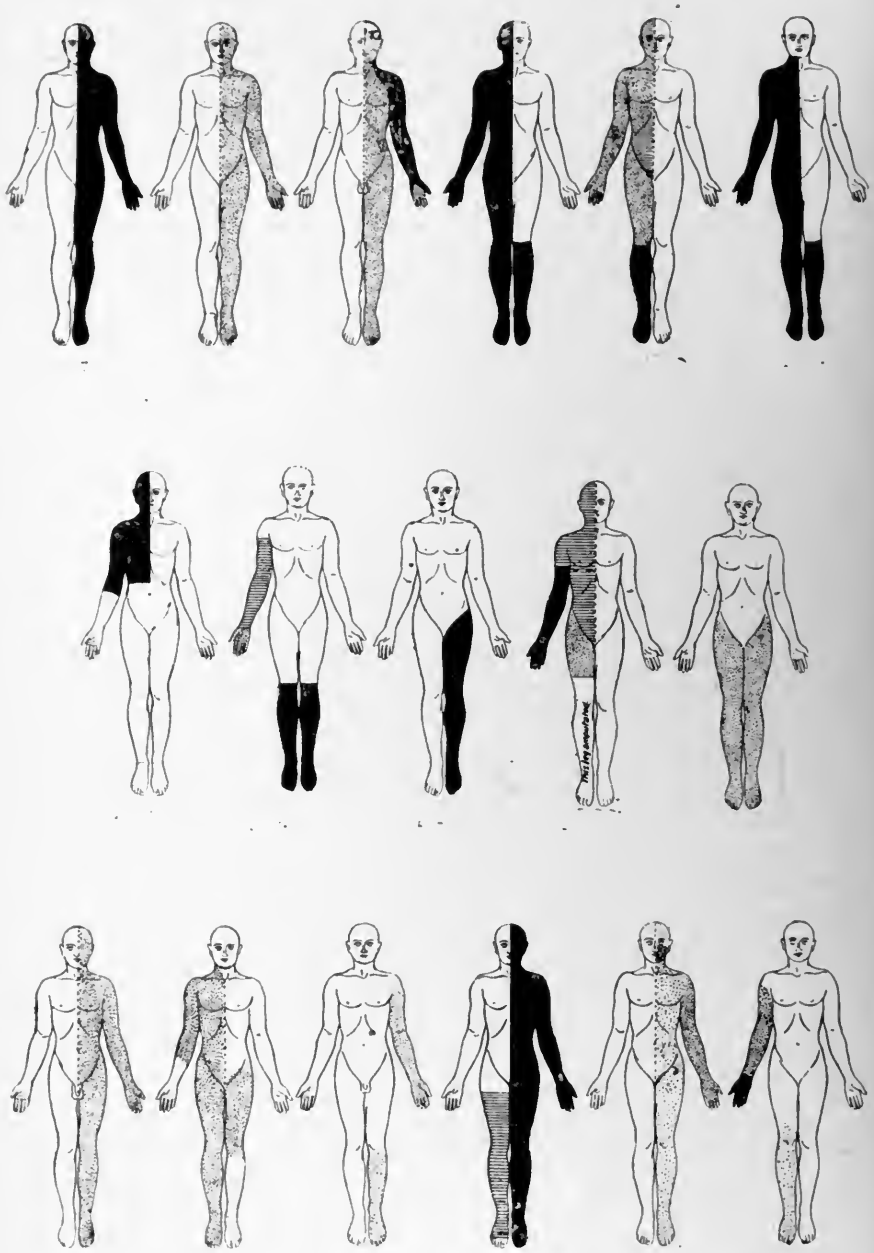

FIG. 209.—Various types of hysterical anæsthesia. Dotted areas indicate slight sensory loss, shaded areas more severe impairment, and black areas total loss of sensation.

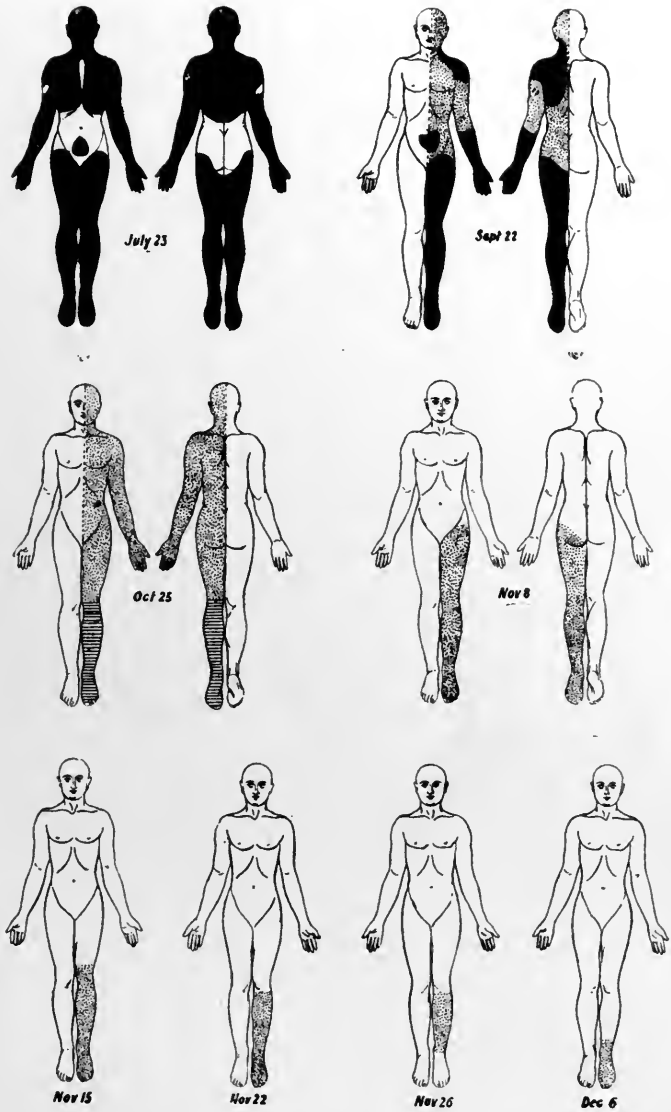

Fig. 210.—Case of hysterical paralysis in a girl aged 17, showing progressive improvement in the anæsthesia.

degree, or it may be dissociated. Diminution or loss of painful sensations is even commoner than tactile anæsthesia. Many of the mediæval witches were simply hysterics. Their hysterical analgesia (*sigillum diaboli*) was usually demonstrated by sticking pins into them. If an analgesic area was discovered, they were promptly thrown into the nearest pond or stream. If they sank and were drowned, their innocence was established; but if they floated, it was additional evidence of guilt.

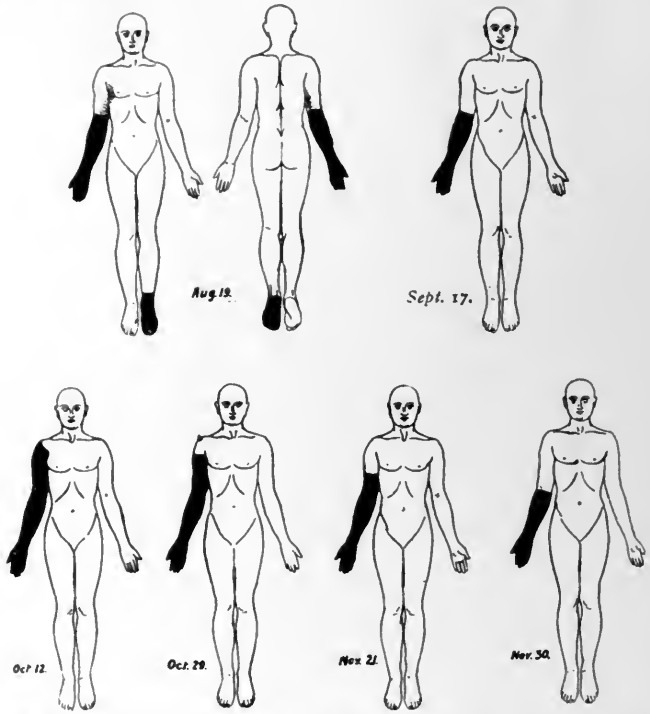

FIG. 211.—Case of hysterical paralysis in a left-handed patient, showing progressive improvement in anæsthesia.

Whatever be its degree of intensity, hysterical anæsthesia never maps out an individual nerve-area such as that of the radial, median, ulnar, or external popliteal. Its commonest distribution is a *hemi-anæsthesia* which is mostly left-sided, except in left-handed patients.

It is a remarkable fact that a hysterical patient never suffers any physical disability owing to the existence of anæsthesia, no matter how profound. Thus she can carry out the most delicate movements with an anæsthetic hand. Unlike a patient with organic anæsthesia, the hysteric never cuts or burns herself unconsciously in an anæsthetic area.

Hysterical hemi-anæsthesia, including the accessible mucous membranes of the eye, nose, mouth, pharynx, vagina and rectum, is usually accurately bounded by the middle line; but not always. It may either extend farther over and encroach on the non-anæsthetic side, or certain areas may remain with sensation normal even on the hemi-anæsthetic side, especially the head, the nipple, and the genitals, as may be seen from the charts (Figs. 209 and 210). The escape of such patches is undoubtedly due to auto-suggestion.

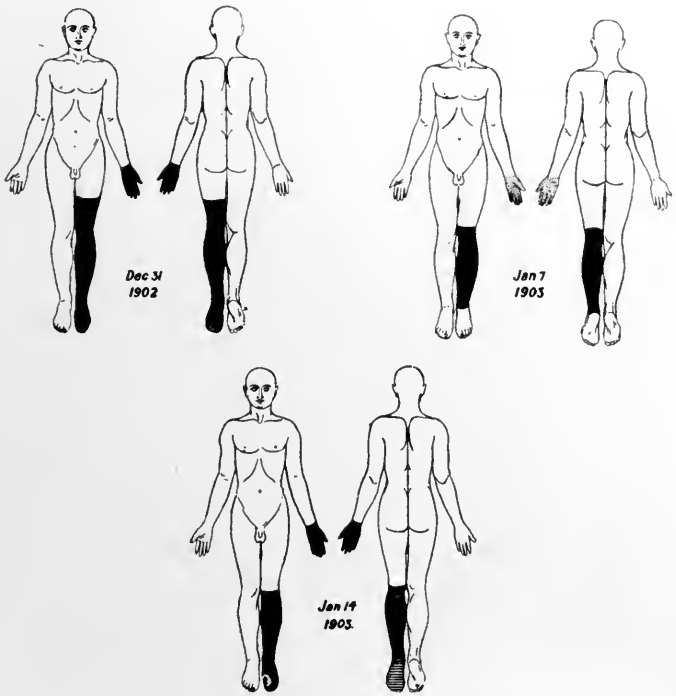

FIG. 212.—Case of hysterical hemiplegia, showing variations in anæsthesia.

Bilateral universal anæsthesia is rare (see Fig. 87, p. 194). We generally find, somewhere or other, one or more islands of normal sensation, or even of hyper-sensitiveness. Pharyngeal anæsthesia is one of the commonest hysterical phenomena. It is not necessarily accompanied by loss of the pharyngeal reflex.

In many cases the anæsthesia, though unilateral, is more marked on the face or limbs than on the trunk. It may affect special levels of a limb (knee, elbow, or shoulder), or it may stop abruptly at some horizontal line (shoe, sock, stocking, mitten, glove, sleeve). This "*segmental*" *anæsthesia* sometimes occurs in association with hemi-

anæsthesia, or may be present by itself on one or both sides (Figs. 211 to 213).

After mapping out the upper boundary of a "sleeve" or "stocking" anæsthesia, by a series of observations from below upwards, running in the long axis of the limb, it is useful to repeat the observations, running up the limb in a zigzag track. In many cases the upper limit of the anæsthesia will be found to have receded by several inches.

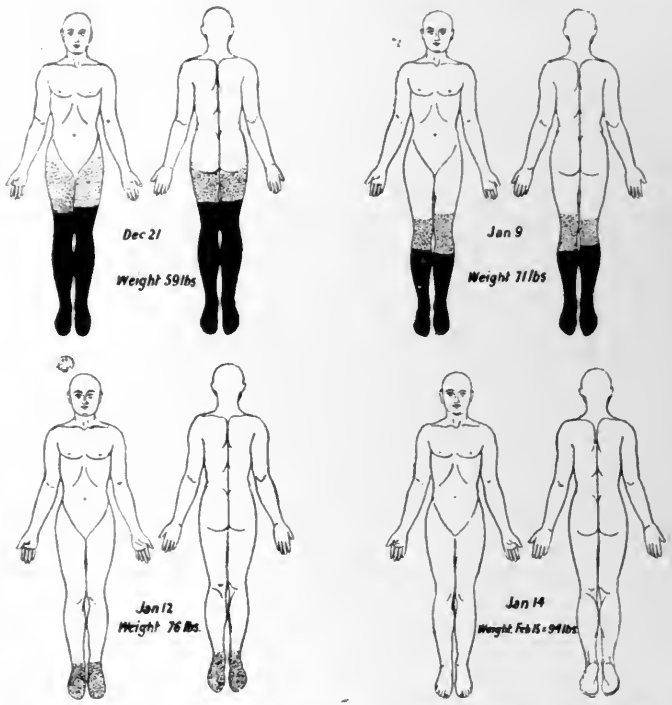

FIG. 213.—Case of hysterical paraplegia with anæsthesia in a girl aged 19, showing progressive improvement.

The mode of onset and disappearance of hysterical anæsthesia is interesting. Sometimes the anæsthesia comes on gradually, and the patient is unconscious of the defect. In other cases it occurs suddenly, especially after a hysterical fit, and the patient is then more likely to notice her "numbness."

We seldom have the chance of watching the onset of hysterical anæsthesia, but we may often study its mode of disappearance, and Figs. 210 to 213 show charts of several cases of hysterical anæsthesia in various stages of recovery. Unlike organic anæsthesia, which, if recovered from, fades gradually all over the recovering area, hysterical hemi-anæsthesia may suddenly fade to segmental (Fig. 210), and

segmental anæsthesia recedes by jumps from a higher to a lower level, bounded usually by an "amputation line" drawn transversely across the limb. Sometimes it relapses temporarily to its old level before resuming its progress towards recovery (Figs. 211 and 212). More rarely it clears up first at the periphery.

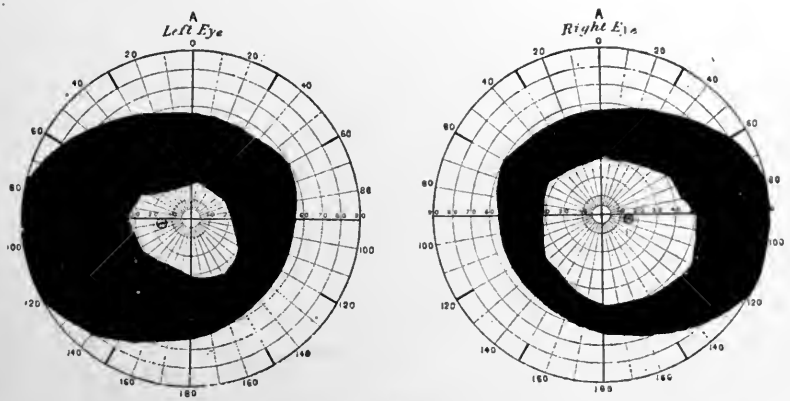

Hysterical crossed amblyopia.

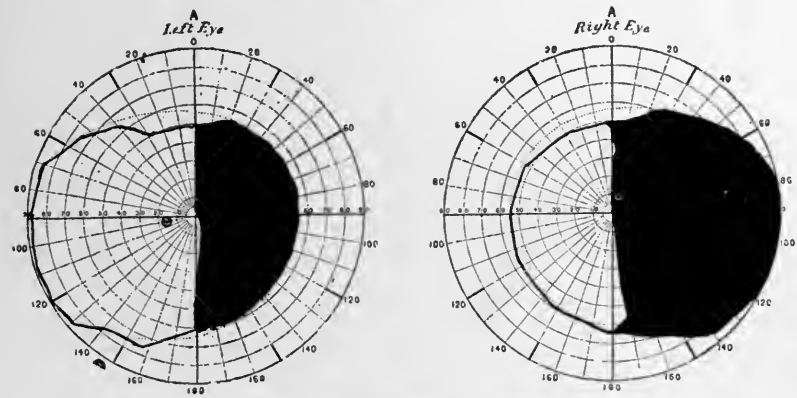

Organic right homonymous hemianopia.

FIG. 214.—Visual fields from cases of hysterical and organic hemiplegia respectively, in which vision was affected.

Affections of Special Senses.—Most cases of hysterical anæsthesia also have diminution or loss of the special senses—smell, vision, taste, and hearing—generally unilateral and on the same side as the cutaneous anæsthesia, rarely on the opposite side. This combination of unilateral affection of special senses and of cutaneous sensation is pathognomonic of hysteria, and does not occur in organic disease.

The affection of vision in hysteria is never a hemianopia such as we often get in organic hemiplegia. It is a concentric contraction of

the whole visual field, as will be seen from the accompanying perimetric charts (Fig. 214). It is more marked in one eye than in the other—"crossed amblyopia"—the smaller field being on the hemi-anæsthetic side, usually the left.

Sometimes, when charting the visual field of a hystero-neurasthenic patient, we notice that the field becomes progressively smaller and smaller as we continue our examination, whether produced by rapid fatigue of attention or by suggestion from the examining physician, so that our perimetric outline has a *helicoid* or spiral shape (Fig. 215). This form of perimetric tracing does not occur in organic disease.

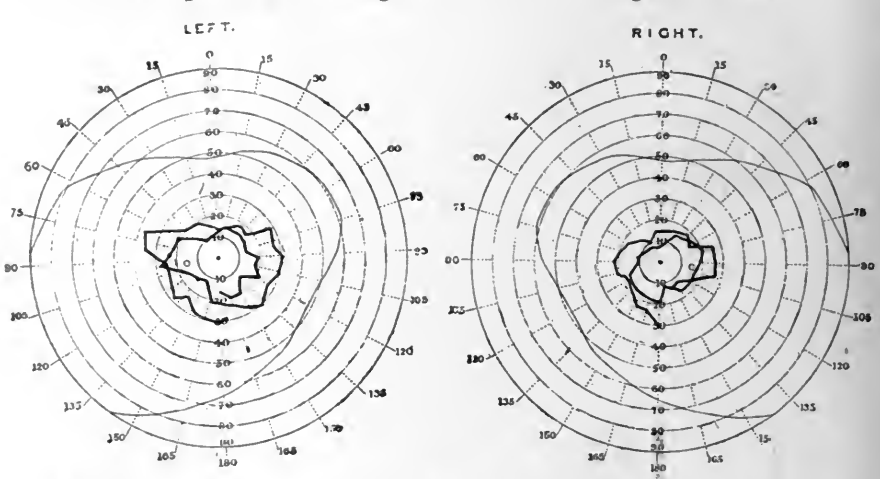

FIG. 215.—Helicoid contraction of visual fields in a case of hystero-neurasthenia.

Sometimes we have hysterical blindness or apparent amaurosis in one eye. That this loss of vision is unreal is easily demonstrated by simple tests; thus, by means of prisms we may produce diplopia, a condition of affairs which would be impossible in an organic case; or, again, we may cover the affected eye with a plane glass and the good eye with a lens so strong that the patient cannot possibly see distinctly through it. We then ask him to read; he succeeds in so doing, unconscious of the fact that he is reading with his supposed blind eye. In rare cases complete bilateral hysterical blindness has been observed.

Perhaps the most striking variety of hysterical blindness is the traumatic amblyopia which sometimes follows the bursting of a high-explosive or a lacrymatory shell a few yards away.[1] The patient is

[1] The term "shock-amblyopia" is better than "shell-amblyopia," since the condition may follow shocks other than those produced by the bursting of a shell or grenade. Thus in case of Griffith's* it was produced by a kick on the head from a mule.

* *Lancet*, June 24, 1916, p. 1245.

usually concussed, and may even be temporarily unconscious. In other cases he is able to walk, in a dazed condition, to the nearest field dressing-station. He at once finds himself to be totally blind, and this blindness is often accompanied by complete and bilateral loss of smell, taste, and hearing. In the early days of such shock-amblyopia there is usually intense blepharospasm, with photophobia and corneal hyperæsthesia, so that voluntary opening of the lids is impossible and passive opening is excessively difficult (see Fig. 48, p. 92). In a few days the blepharospasm usually passes off, but the patient remains for a time blind in one or both eyes. He then gradually recovers vision, generally passing through a stage in which there is contraction of the visual fields, often unequal in degree in the two eyes. Ultimately he makes a complete recovery.

Analogous to hysterical blepharospasm is the condition of hysterical pseudo-myopia in which there is spasm of accommodation so intense that the patient cannot see distant objects clearly without the aid of powerful concave lenses. In such cases the instillation of atropine, by temporarily paralysing the ciliary muscle, at once renders the refraction normal.

We have already referred to the hysterical affections of smell (p. 116) and hearing (p. 152), and we may mention, in passing, that complete bilateral loss of taste, as Hughlings Jackson pointed out, is practically always hysterical.

Hysterical Paræsthesia, or Perversion of Sensation.—In some cases of hysteria a touch on one limb or one side of the body is felt by the patient at the corresponding spot on the opposite side—*allocheiria* (Obersteiner). In another variety, of which I have seen an example, a touch on the radial border of the limb was felt on the ulnar, and *vice versa*. The *synæsthesalgia* (p. 184) which is met with in certain cases of thermalgia following incomplete nerve-division is probably hysterical in nature. *Haphalgesia* (Pitres) is the term used when intense pain is caused by touching the patient with certain substances, such as metals, which normally should only cause a tactile sensation.

All these paræsthesiæ are the result of suggestion, generally auto-suggestion, but sometimes suggestion by the examining physician.

Paræsthesiæ of the special senses are also met with, as, for example, in *monocular diplopia* or *polyopia*, which is always hysterical. *Micropsia*, where everything looks very minute, and *macropsia*, where surrounding objects seem gigantic, are both frequently hysterical.

Motor Phenomena.—These may be subdivided into irritative and paralytic. Amongst the *irritative phenomena*, the most striking are the so-called **hysterical fits** or **paroxysms**. These are rarely induced by emotional excitement alone. It has been wisely remarked that "when

a real and intense emotion rends the human soul, there is no room for hysteria." Suggestion, on the other hand, whether from within or from without, plays a fundamental part in the production of hysterical attacks.

Hysterical fits vary enormously in type and in severity, from a simple emotional outburst of uncontrollable laughter or weeping, accompanied perhaps by the hysterical "globus" or "ball in the throat," to the most prolonged, dramatic and violent muscular movements, together with apparent unconsciousness.

One variety of hysterical fit is sometimes mistaken for epilepsy, and there is all the greater liability to make this mistake since the fit is generally over before we reach the patient, and we are dependent for our information upon the accounts, more or less accurate, of unskilled witnesses. But if the physician is lucky enough to be present during a fit, there is seldom any difficulty in diagnosis. Thus, for example, the patient never hurts herself in falling; there is no stertorous breathing; her face is not livid, nor does she bite her tongue as in epilepsy; she may, however, bite her lips or snap at the fingers of the bystanders. She never empties the bladder or rectum during the fit; her eyes are usually tightly closed, and if the physician tries to open them, the patient resists actively. A hysterical fit is not followed by coma nor by a transient extensor plantar reflex and hardly ever by vomiting. Finally, the hysterical fit can often be reproduced by medical (especially hypnotic) suggestion, and then promptly made to disappear by the same means, whereas a true epileptiform attack cannot be induced by suggestion.

But we must remember that sometimes we have hysterical fits which are post-epileptic—*i.e.* which immediately succeed an attack of true epilepsy. The antecedent epileptic fit in such cases is usually of the "petit-mal" type, consisting perhaps in a mere transient pallor of the face, with momentary loss of consciousness, and then passing directly into a hysterical fit. Therefore, in every case it is important to inquire very carefully as to the precise mode of onset, lest we overlook a case of combined epilepsy and hysteria.

Charcot's "*grande hystérie*," with its initial period simulating epilepsy and its subsequent phases of contortions, kicking, and struggling (clownism), *attitudes passionées* (opisthotonos, crucifixion attitude, etc.), and delirium, often with hallucinations of animals, is rare in this country, and nowadays it is uncommon even in France; but, once seen, it is a magnificent performance and can never be forgotten. It is totally unlike any kind of epileptic or organic fit, and its diagnosis is easy. It may last from a quarter of an hour to several hours at a time. It can usually be arrested by energetic faradism, by dashing cold water

on the face and chest, or by the hypodermic administration of apomorphine. This "status hystericus" is commoner than the "status epilepticus," but the patient, although perhaps a little tired, has no subsequent stupor such as that which succeeds a severe epileptic fit.

Amongst other varieties of fits, to which we can only briefly refer, we may mention *catalepsy*, in which the patient suddenly becomes speechless, motionless, and stiff. Sometimes she is conscious all through the fit, at other times she is in a dreamy mental state. Meanwhile, if the limbs be passively moved into any posture, however fantastic, they remain fixed there like a doll's limbs. I remember a case in which the patient, a woman of 28, could be lifted up during the attack by the head and heels and laid across two chairs like a log. Catalepsy in its most severe form is also met with in dementia præcox.

Hysterical trance may come on spontaneously, or may succeed a hysterical paroxysm. It is a condition in which the patient appears as if in a deep sleep; but the muscles are seldom completely relaxed, and we may observe slight tremors of the eyelids. In more severe cases the heart and respiration may become so feeble and slow that the condition simulates death. Hysterical trance may last hours, days, or weeks; and several cases have been authenticated in which such a patient has been buried alive, either deliberately, as in the case of some Indian fakirs, or by accident in this country. Novelists know this, and when the heroine is thus buried, she is exhumed in the last chapter by the villain for the sake of a magnificent diamond ring on her finger; whilst her finger is being cut, to get the ring off, the patient awakes.

We can only mention other varieties, such as *somnambulism* and *double consciousness;* this latter, when in extreme degree, being a condition in which the patient's character alternates between normal and abnormal, the two individualities being mutually unconscious of each other, but each one, as its turn comes, takes up the thread where it had previously left off.

A minor degree of double consciousness can be demonstrated, by a simple experiment, in many cases of hysteria in which there happens to be hysterical anæsthesia of the upper limb. If in such a case we screen the anæsthetic limb from the patient's view, she does not feel pin-pricks or touches on the limb, nor does she recognise familiar objects when placed in the hand. But if a pencil be placed in the "screened" hand, it is grasped in a position suitable for writing, and if we now trace a letter or a word on the back of the anæsthetic hand (the patient's attention meanwhile being diverted by another observer) this letter or word is reproduced in writing, entirely unknown to the patient's consciousness. Analogous sub-conscious phenomena can be demonstrated in many apparently normal people by means of a small wheeled platform or "planchette" carrying a pencil.

We also meet with a hysterical type of amnesia with *ambulatory automatism* where the patient (more often a man than a woman) has attacks in which, without adequate motive, he has a sudden and irresistible impulse to wander from home. He makes a long journey, sometimes undergoing great hardships *en route*. Finally, days, weeks, or even months afterwards, he suddenly wakes up in some strange town or country, entirely unaware of how he got there. For example, I have known of a boy who disappeared from school in this way, of a young officer who deserted from his regiment, and of a business man who left his wife and family, in all these cases without any adequate cause. These cases are closely related to the somnambulistic stage of the hypnotic trance, and if such a patient he hypnotised he becomes able to give a complete account of his wanderings from the moment of his disappearance to the time when he woke up and "found himself." The diagnosis between hysterical and post-epileptic ambulatory automatism, to which we have already referred (p. 69), is not always easy. We should carefully inquire for evidences of epilepsy, major or minor, we should look for the presence of other hysterical phenomena, whilst the reconstruction of the "lost" period of time when in the hypnotic trance is highly suggestive of its hysterical origin.

Various *localised motor disturbances* also occur in hysteria and psychasthenia. Such, for example, is the large group of "tics" and "habit spasms" which we have already studied (p. 89). A true tic is essentially and primarily a psycho-motor act, either an emotional expression or a movement which has become a habit. Of these tics, the commonest are grimaces, jerkings of the head, trunk, or limbs, and tremors of various parts, rapid or slow.

Thus, for example, a lady's maid, aged 46, had tonic spasm of the orbicularis oculi on both sides (blepharospasm), and could open her eyes only by opening the mouth as well. Another girl, æt. 19, had a clonic or jerking paroxysmal blepharospasm, associated with "humping up" of one foot. Another girl of 19 had rapid "twiddling" movements of the left thumb and fingers, with pronation-supination movements of the forearm and a pseudo-clonus of the left ankle. Another girl, aged 20, who previously had suffered long from recurrent vulval abscesses, had attacks of rapid antero-posterior movements of the pelvis. Another patient had rapid violent flexion-extension movements of the left elbow whenever a thunderstorm occurred, the hand meanwhile dangling loosely at the wrist.

Such cases of localised motor disturbances might be multiplied almost *ad infinitum*. The tremors which occur in war-neuroses will be considered in a later chapter (pp. 551 and 555).

Hysterical Paralysis may be either *flaccid* in type, simulating a lower motor neurone lesion, or *spastic*, simulating an upper motor neurone

lesion. It may affect any of the voluntary muscles; but, unlike paralysis due to organic lesions, it never attacks a single muscle nor the muscles supplied by a single nerve, nor are the electrical reactions of degeneration ever present. A further point about hysterical paralysis is that, though it may roughly resemble the posture of an organic paralysis, it never does so with accuracy; there is always some point of difference to be detected. The reason for this we have already discussed (p. 268).

Let us study examples of hysterical monoplegia, or paraplegia, and of hemiplegia.

FIG. 216. — Hysterical monoplegia of right upper limb, accompanied by muscular atrophy, but without changes in electrical reactions.

Fig. 216 is that of a nurse, aged 32, with hysterical monoplegia of the right arm of eight months' duration, in whom there was extreme muscular wasting and claw-hand. This paralysis came on after a strain of the shoulder in lifting a heavy patient, and roughly resembled a lesion of the brachial plexus. But we observed that the trapezius was paralysed, and that the whole scapula was displaced downwards — unlike an organic brachial-plexus case, in which the arm would be displaced downwards only at the shoulder-joint. Moreover, the electrical reactions were normal in the wasted muscles, and there was a "glove" of anæsthesia, unlike the "root" anæsthesia of an organic case. The patient was treated for several weeks by battery and massage, without effect at first, but the result proved our diagnosis to be correct, for subsequently at a religious meeting she was suddenly cured.[1]

Fig. 217 shows a case of hysterical monoplegia of the left upper limb in a young man of 21 who was screwing on the bulb of an electric lamp when the current became short-circuited, the bulb burst, and he had a sudden electric shock through the left hand. When examined nine months after this accident, there was total flaccid paralysis and complete anæsthesia of the left upper limb, which dangled helplessly in a flail-like fashion. The latissimus dorsi, however, although paralysed for voluntary movements, contracted briskly when coughing. All the muscles of the limb reacted briskly to faradism.

In spite of assiduous suggestive treatment of various kinds in hospital (including powerful electrical stimulation, the application of cutaneous irritants, and attempts at hypnotic suggestion), no improvement occurred. Eleven months after the onset of his symptoms, before discharging the patient, it was decided to try the effect of a general anæsthetic in the hope of loosening his obsession during the stage of excitement. The result was dramatic. Within a few seconds after commencing the inhalation of ether

[1] An analogous case is recorded by St. Luke, chap. vi., verses 6-10.

and nitrous oxide, freely mixed with air, the patient began to move the paralysed limb, and in a short time he was fighting violently with it. The anæsthetic was then discontinued, and the patient passed into a hypnotic state, during which voluntary movements of the previously paralysed limb were normally executed in obedience to verbal commands, accompanied by occasional painful stimuli, such as twisting the ear, pricking the previously anæsthetic limb, etc. It was then suggested to him that all his motor and sensory disability should disappear, and as the effects of the ether passed off, this was found to be actually the case. Ever after the

Fig. 217.

Fig. 218.

Fig. 217.—Hysterical paralysis and anæsthesia of left upper limb, of eleven months' duration. Patient trying to shrug both shoulders.
Fig. 218.—The same patient after cure.

foregoing séance he remained able to move his limb normally, the anæsthesia also remaining absent (see Fig. 218).

Figs. 207 and 207A are from a case of hysterical flaccid paraplegia of fourteen years' duration in a woman of 37, which at first sight might be mistaken for a cord-lesion with muscular atrophy and anæsthesia. But the anæsthesia was of the "stocking" type, the reflexes, deep and superficial, and the electrical reactions were normal, the sphincters were unaffected, and there were no bed-sores; and the result of six weeks' isolation with curative suggestions and massage was to restore the power of walking (Fig. 208).

In some cases of hemiplegia the posture is sufficient to diagnose hysteria. For example, in the patient shown in Figs. 130 and 131

(p. 269), instead of the ordinary posture of an organic case, with the upper extremity flexed and pronated, the lower extremity flexed at the hip, extended at the knee and ankle, and slightly inverted, there was a curious posture of the hand and foot unlike that of organic disease. Moreover, her face entirely escaped, in spite of the severe paralysis of the arm and leg; and she had hemi-anæsthesia and loss of special senses down one side, a combination which never occurs in organic hemiplegia.

Fig. 219.—Left-sided glosso-labial hemi-spasm.

The face and tongue are rarely affected in hysterical hemiplegia. But in certain cases we may find, instead of weakness, spasm of the face and tongue on the affected side, when the patient shows the teeth or protrudes the tongue. This hysterical *glosso-labial hemi-spasm* is rare, but Figs. 219 and 133 (p. 270) are good examples of the condition.

We may also refer to "Lasègue's symptom" (Nothnagel's "*Seelenlähmung*") in which a patient with an anæsthetic limb cannot move it when the eyes are closed, but is able to move it when she opens her eyes and looks at it.

Another feature worthy of mention is hysterical pseudo-ptosis. In organic ptosis due to lesion of the third cranial nerve there is almost always a compensatory over-action of the frontalis muscle. But in hysterical pseudo-ptosis this is usually absent, and the condition is

Fig. 220. Fig. 220A.

Fig. 220.—Astasia-abasia of twelve months' duration.
Fig. 220A.—The same patient five minutes later.

really due, not to paralysis of the levator palpebræ, but to spasm of the orbicularis oculi (see Fig. 66, p. 133).

Before leaving the motor phenomena of hysteria, it may be well to refer to the gaits of hysterical and psychasthenic patients, which are sometimes most peculiar.

Astasia-abasia is a hysterical condition in which, although the patient can move his legs normally when lying or sitting, he collapses at once when he tries to stand or walk. Children are more often

affected than adults, but in war-time it is a frequent type of hysteria in soldiers, following the emotional shock of a shell-explosion. A little girl, aged 10, had this symptom for twelve months (see Fig. 220), but was cured in a couple of minutes by an application of high-frequency sparks in a darkened room, accompanied by the suggestion that she could now walk (Fig. 220A). One patient, a doctor aged 55, used to flourish his left leg in the air and bring it down with a stamp like that of a unilateral locomotor ataxia. This phenomenon, an ambulatory tic, was so dramatic that he had to carry a stick to beat off the crowds of little boys who studied his gait in the streets. Another patient was a worthy married lady who every now and then, when walking, sat down suddenly on the ground, rolled backwards and spread out her lower limbs like the letter V.

Roughly resembling astasia-abasia is the condition termed *staso-baso-phobia*, in which the patient, following an emotional shock (say a shell-explosion), not merely has difficulty in walking, as in ordinary astasia-abasia, but has acute emotional phenomena when he is placed upright and told to make the attempt. He is excessively afraid, and his anxiety may amount to positive terror. He is pale, tremulous and bathed in perspiration, complains of giddiness and begs to be held up, being acutely afraid of falling. He clutches desperately at surrounding persons or objects. Sometimes, when supported on both sides, his lower limbs drag helplessly along the ground or he may timidly move them, carefully avoiding bearing his own weight.

This condition is essentially an obsession, or phobia of walking, and should be classed under the heading of psychasthenia rather than of true hysteria.

Perhaps the commonest hysterical gait is a dragging gait, in which the patient trails the limb helplessly along, often scraping the inner border, or even the dorsum of the foot, on the ground, unlike organic hemiplegia in which the outer side of the sole is dragged.

A girl of 20 woke up one morning and suddenly found her left foot stiffly inverted at the ankle. The heel then gradually became drawn up, in the course of months, so that it assumed the posture of equino-varus. An enterprising surgeon divided the tendo Achillis, but the deformity persisted and the toes gradually became flexed into the sole. When seen at the age of 24, she had a typical hysterical "stocking" anæsthesia of the left leg (see Fig. 221). She walked with crutches, resting her entire weight on the right leg. She was able to stand alone on the right foot, but the left lower limb was slightly flexed at the hip and knee, so that the left foot did not touch the ground. There was total paralysis of the left ankle and toes, with slight wasting of all the muscles below the knee, but without electrical changes.

Some authorities state that muscular atrophy does not occur in a hysterical limb. But this is not accurate, for in certain rare cases, one of which is shown in Fig. 216, we may meet with profound atrophy. But this atrophy is due to disuse and is not associated with the electrical reactions of degeneration.

Fig. 221.—Hysterical contracture of left foot.

Contractures of the most pronounced type may be met with in hysterical paralysis. But here, again, they always differ in some respect from those of organic cases.

Carefully to be distinguished from hysterical palsies are the curious varieties of **reflex paralysis** following traumata of the limbs, especially after war-injuries, but also from injuries in time of peace.

The motor disability in reflex paralysis is usually incomplete. The intensity of the paralysis is not necessarily proportional to the severity of the antecedent trauma; the most trivial injuries sometimes cause well-marked clinical signs, which may extend proximally above the site of injury. As a rule, however, reflex palsies are most marked at the periphery of the limb. Perhaps the most frequent cases are those which follow slight injuries in the region of the thigh or hip-joint.

The phenomena may appear immediately after the injury. More often they are not noticed until several weeks later. They may persist for many weeks or even months.

A patient with an injury of this sort finds that the affected limb does not recover its normal power, but remains weak and sometimes painful. The weakness is often grossly disproportional to the slightness of the original trauma. It may be either spastic or flaccid in type, or some muscle-groups may be hyper-tonic, whilst others are hypo-tonic.

There is usually a slight degree of diffuse muscular wasting, but without changes in electrical reactions, save perhaps a slight quantitative increase or diminution of faradic excitability.

The affected limb, or part of the limb, is usually colder than on the healthy side. The difference in surface-temperature between the two limbs may amount to as much as 12° or 15° F. (8·5° C.). The systolic blood-pressure is the same in both limbs, but the amplitude of oscillations, as shown by a manometer, is much diminished and may be almost imperceptible on the affected side.

The muscles and nerve-trunks of the affected limb are hyper-excitable to direct percussion and the muscle-wave is abnormally prolonged. The deep reflexes are somewhat increased. This hyper-excitability of the muscles and of the deep reflexes is proportional to the degree of hypothermia. In doubtful cases they can be rendered manifest by plunging the limbs into cold water, when the deep reflexes on the affected side are at once increased. This exaggeration of deep reflexes in the affected limb persists even when all the muscles are relaxed during chloroform anæsthesia.

Fig. 222.—Contracture of the left hand and elbow, following an injury to the elbow.

The condition is influenced only partially, if at all, by psychotherapy or suggestion, but tends ultimately to spontaneous recovery. Babinski and Froment,[1] who originally described the condition, call it "physiopathic," *i.e.* it is functional, but not in the sense of being psychogenic in origin like hysteria. Sometimes reflex paralysis is combined with hysterical contracture or with hysterical paralysis. In such cases the hysterical element can be removed by suggestion, but the reflex muscular wasting may persist for months or even years.[2]

Fig 222 is the photograph of a soldier, aged 32, whose horse rolled on him at the Tugela in 1900, bruising the left elbow. He afterwards developed a spastic left arm, flexed at the elbow and wrist, and with the thumb and index finger held stiffly parallel. At that time, we diagnosed the condition as hysterical, owing to the absence of signs of any organic

[1] Babinski and Froment, *Revue neurologique*, 1915, p. 975, and 1916, p. 410.
[2] Vincent, *Revue neurologique*, 1918, p. 460.

lesion. No note was made as to the temperature of the limb. Now, however, in the light of more modern knowledge, it seems a probable case of reflex paralysis.

A study of the **reflexes** is of great importance in the diagnosis between hysteria and organic disease. The deep reflexes in hysteria are normal or exaggerated, and sometimes accompanied by a feeling of acute indescribable discomfort. In pure hysteria they are never lost, although sometimes they may be "concealed" by the presence of muscular spasm. True ankle-clonus does not occur, but a pseudo-ankle-clonus is often met with. In a girl of 19, the subject of thread-worms and pruritus ani, this pseudo-clonus used to come on spontaneously when sitting or standing at ease. One can often distinguish it from a true organic clonus by its irregular rhythm and by the peculiar upward start of the foot before it sets off on its first downward push. Further, pseudo-clonus is, as a rule, poorly sustained.

The superficial reflexes are sometimes diminished, especially on the hemi-anæsthetic side. The pharyngeal reflex is frequently abolished. The plantar reflex in hysteria, if present, is always of the normal flexor type, never of the extensor or Babinski type. A persistent extensor plantar reflex only occurs in cases of disease of the pyramidal tracts, and in infants who have not learned to walk and in whom the pyramidal tracts are not yet myelinated.

The pupil-reflex to light is never lost in pure hysteria, though in rare cases it may be "concealed" by the presence of pupillary spasm. I remember one case of fixed dilated pupils in a hysterical woman, but this was due to the taking of belladonna by the patient.

Another useful test is afforded by Leri's *forearm sign*.[1] This consists in an involuntary flexion movement of the elbow when the observer passively flexes the fingers and wrist, rolling them up, as it were. In organic hemiplegia this forearm sign is lost, whereas in health and in hysterical paralysis it remains positive.

As to the bladder and rectum, although we may have frequency of micturition in hysteria, we never have true incontinence. In war-time, however, some hysterical soldiers develop a pseudo-incontinence of urine, characterised by frequency of micturition night and day. Superadded neglect, conscious or subconscious, may cause such a patient to be constantly wet with urine, so that he is a nuisance to himself and still more to his comrades. Some of these cases arise, in the first instance, from the emotional shock of a shell-explosion; others develop spontaneously in patients who suffered from enuresis in childhood. In all cases we must be careful to exclude organic lesions of the urinary apparatus, also of the cauda equina or conus medullaris, before diagnosing the condition as hysterical.

[1] *Révue neurologique*, March 15, 1913.

Retention of urine, on the other hand, is a fairly common symptom. It once broke out as an acute epidemic in a school for young ladies, and continued until the doctor judiciously handed over the duty of catheterisation to a female nurse of mature years. The symptom promptly subsided in a gratifying manner.

Visceral and Vaso-motor Phenomena.—It is important to remember that acute emotions manifest themselves in normal individuals not only by psychical and motor phenomena, but also by transient visceral and vascular reflexes. It is therefore readily understood why hysterical patients, being specially sensitive to emotional stimuli, should ocasionally show vegetative symptoms. Let us refer very briefly to some of the visceral and vascular phenomena.

We may meet with abnormal rapidity of the heart, with paroxysmal palpitation, constituting a variety of pseudo-angina, especially in hysterical or neurasthenic young mothers who have been lactating too long. The actual attack is usually induced by the revival of some emotion, and the condition is easily distinguished from true angina by the absence of signs of organic cardio-vascular disease.

In the digestive system we meet with curious hysterical phenomena. Aërophagy, or swallowing of air, is achieved chiefly by gulping movements of the pharynx. I remember a little schoolboy who could swallow air and distend his abdomen till his waistcoat could not be buttoned. We are all familiar with hysterical dysphagia or spasm of the œsophagus, with its sudden intermissions and the difficulty experienced equally with liquids and with solids, in which nevertheless a large stomach-tube can be easily passed. The hysterical "globus" or "ball in the throat," which the patient tries to swallow, is an emotional phenomenon often met with at the onset of a hysterical paroxysm. Hysterical vomiting has always to be excluded in gastric disorders of young women. The so-called "pernicious" vomiting of pregnancy is often hysterical in character, due to the perpetuation, by auto-suggestion, of the physiological vomiting of the first few weeks of pregnancy. Hysterical vomiting is also met with occasionally in hysterical soldiers. The patient, who shows no other sign of organic gastric disease, and whose general nutrition is generally good, eats with a good appetite but vomits several times a day. The vomiting occurs without effort, and is unaccompanied by the nausea or collapse of a true stomach case. Sometimes there is regurgitation of food rather than actual vomiting. Hysterical vomiting is sometimes associated with *anorexia nervosa*, where the patient will take hardly any food. "Fasting girls," of whom we now and then read in the newspapers, are generally examples of this kind of hysteria. They may become extraordinarily emaciated, but even they do take a little food now and then.

Rhythmic movements of the stomach or intestine accompanied by curious rumbling noises are sometimes met with. They are usually vagotonic neuroses. The commonest variety is the intestinal, and at dinner-parties one sometimes hears these noises in nervous young servant-maids waiting at table. Much less frequently we hear violent gastric borborygmi. One young girl whom I saw had constant, noisy to-and-fro gurgling in the upper part of the abdomen, like a steam-pump, and on palpating the abdomen the stomach could be felt rhythmically contracting and relaxing, blowing and sucking air backwards and forwards. This phenomenon was so startling to strangers that the unfortunate girl had to retire to her own room if friends came to call on the family. Somewhat similar abdominal noises in another hysterical patient, a lad of 19, were apparently produced by spasmodic contractions of the diaphragm, for they ceased when he drew a deep breath and held it.

The *artiste* who earned an honest living at a Parisian music-hall by making musical noises with his anus was probably another example of visceral hysteria.

Hysterical rapidity of breathing is often accompanied by dramatic groaning or moaning noises, but is unassociated with cyanosis or other physical sign of pulmonary or cardiac disease. Meanwhile the rate of the heart-beat is not noticeably increased. These paroxysms of hysterical tachypnœa are always worst in the presence of sympathetic observers and rarely or never occur when the patient is alone.

We must also bear in mind the pseudo-pregnancies which now and then occur, in which spurious enlargement of the abdomen sometimes goes on to a spurious labour. Then "parturiunt montes, nascitur ridiculus mus"—all that is produced being, at the most, a small uterine cast. Phantom abdominal tumours can best be differentiated from genuine ovarian or uterine enlargements by giving a general anæsthetic, when the abdomen at once collapses.

It is sometimes more difficult to diagnose pseudo-appendicitis. Thus one patient whom I saw, aged 33, had had her abdomen opened twice in different London hospitals for supposed appendicitis, the symptoms being those of recurrent pain and tenderness in the right iliac fossa, with constipation and vomiting. But she had also right-sided hemi-anæsthesia, with loss of special senses all down that side. We were thus led to suspect the hysterical nature of the abdominal symptoms, and accordingly her next attack was cured by sal volatile, without laparotomy, and she has had none since.

Hysterical diarrhœa of emotional origin sometimes occurs, as in the case of a public speaker who was often attacked in this awkward way just when his turn arrived to address the audience. Cases like this are

transient and unaccompanied by fever, anorexia, or general malaise, as in diarrhœa from organic causes.

Spontaneous hæmorrhages have been described in hysteria, but the proof of their existence is unconvincing. A certain number of cases of pseudo-hæmoptysis and pseudo-hæmatemesis occur. In one girl, otherwise healthy, whom I watched, the phenomenon seemed to be produced by sucking of the gums; in another it was apparently the result of pharyngeal suction.

Sometimes a limb affected by hysterical paralysis or anæsthesia may show abnormal vasomotor spasm, so that if pricked or cut it bleeds less freely than normal. This is readily demonstrated in patients during the hypnotic trance. A soldier at the battle of Ypres was presenting his rifle to fire, when it was struck by a shell without wounding the man. He at once developed hysterical paralysis of the upper and lower limbs, of flaccid type, and without sphincter trouble, lasting for several weeks; this was accompanied by coldness and cyanosis of the hands and feet, the radial pulses being impalpable. All the symptoms gradually disappeared.

Secretory phenomena have been described, as for example blood-stained tears or blood-stained sweat or mammary secretion, which may be unilateral. Personally I have not yet met with a case of this sort. Transient polyuria often occurs after a hysterical fit, whereas the occurrence of hysterical anuria or suppression of urine is more than doubtful.

Certain skin affections have been described in hysterical patients. Cutaneous hæmorrhages are generally the result of voluntary traumatism. Bed-sores do not occur. The gangrenous patches described as hysterical gangrene are always self-inflected, by means of caustics or other methods (see Fig. 142, p. 278). Hysterical blue œdema, described as occurring especially in contractured limbs, is generally a fraudulent phenomenon, self-produced by the patient, who ties a constricting band around the limb. It usually affects the skin over a joint and produces a degree of cyanosis and swelling, but this swelling does not pit on pressure. It may last for weeks or months, and generally disappears suddenly. Thus in a case recorded by Raymond, it suddenly cleared up when the patient received the glad stimulus of an unexpected legacy.

Dermographism is commoner in hysterics than in normal people. Fig. 223 is an excellent example in a girl with hysterical tremor of the legs, in whom, when the skin was stroked with the finger-nail, a white raised wheal appeared and remained for an hour or more. This "factitious urticaria" or "urticaria scripta," unlike ordinary urticaria, does not itch.

Hysterical cough is very common; it is usually loud and hacking,

going on all day and ceasing during sleep. It is not accompanied by expectoration, and is commonest in young hysterics. We may have other peculiar modifications of respiration. Thus in a girl of 24 who had hysterical fits, expiration was a curious grunting noise of a bigeminal type—two grunts between each inspiration. We also meet with paroxysmal rapid breathing, sneezing, hiccup, and yawning. One girl, aged 10, the subject of hysterical hemi-anæsthesia, yawned persistently

Fig. 223.—Case of dermographism in a hysterical young woman.

for three weeks during her waking hours. She then stopped and had an attack of hysterical mutism lasting for two months.

When hysteria occurs in childhood it is often mono-symptomatic. Girls are much more frequently affected than boys, even before the age of puberty. Perhaps the commonest symptoms of hysteria in childhood are astasia-abasia and hysterical aphonia. Various forms of habit-spasm are common in young psychasthenics.

The diagnosis between hysteria and organic disease is sometimes easy; in other cases it is a matter of extreme difficulty. In doubtful

cases we have several groups of signs and symptoms on which to fall back:—

Firstly, certain physical signs, if present, are conclusive evidence of structural disease, *e.g.* optic atrophy, optic neuritis, changes in the cerebro-spinal fluid, the presence of reactions of degeneration in cases with muscular atrophy, etc.

Secondly, there are reflex and other phenomena which occur independently of voluntary control, *e.g.* absence of the pupillary light reflex, irregularity or marked inequality of the pupils, loss of deep reflexes, presence of true ankle-clonus, or of an extensor plantar reflex, Babinski's pronation-sign (p. 209), true incontinence of urine, and so on.[1] These, when present, are strong evidence of organic disease.

Thirdly, the mode of incidence, the condition of the special senses, the type of anæsthesia when present, the posture of the limbs in cases of motor paralysis, the variability or otherwise of the palsies or contractures, and the whole group of other phenomena which can be produced by suggestion, whether auto-suggestion or hetero-suggestion, are of great diagnostic value.

Lastly, we must never forget that combinations of hysteria, reflex paralysis and organic disease may coexist in the same patient.

[1] Hurst, *Rev. of Neurol. and Psychiatry*, 1918, p. 6.

CHAPTER XXII

ELECTRO-DIAGNOSIS AND ELECTRO-PROGNOSIS

It is not necessary to enter into a full discussion of the various physiological phenomena produced by electrical stimulation of different tissues, still less to discuss the nature of electricity itself or the *rationale* of its effects. It will suffice here to recall a few of the more practical points in the physiology of electrical stimulation.

Clinically, electrical stimulation is of value chiefly in the examination of muscles and of motor nerves. Electrical examination of sensory functions is of but little practical importance, except perhaps in mapping out areas of loss of taste, when a mild galvanic current is an excellent gustatory stimulus (p. 141), and in testing for galvanic vertigo (p. 154).

For diagnostic purposes the most important forms of electricity are the *faradic*, interrupted, or induced current, the *galvanic* or continuous current, the *condenser* discharges, and the *vibrant* electricity, which is the result of discharging a powerful induced current through a Crookes' vacuum-tube, producing the well-known X-rays. The application of this latter—so-called skiagraphy—though of great practical importance, does not specially concern the neurologist. We have to consider more particularly the faradic, the galvanic, and the condenser currents.

To produce the **galvanic current**, we employ a galvanic battery (preferably a dry-cell battery, which can be carried about without spilling), and this battery must have sufficient electro-motive force or voltage to overcome the resistance of the skin, which is a bad conductor, and to stimulate the muscles and nerves underneath. In cities where there is an electric-light system run by the continuous current, we can utilise this current to charge an accumulator which can be carried about. Or we may use the current direct from the main, provided we are careful to reduce the voltage sufficiently; this is accomplished by means of shunts, resistances, or rheostats.

Faradic, or **induced electricity**, is obtained by induction. In a faradic machine there are two coils of wire, concentrically placed—the primary coil within the secondary. When a galvanic current passes along the primary coil, there is produced, at the moment of closure and again at the moment of opening of the primary current, an instantaneous faradic shock in the secondary coil, no shock occurring during the period of flow of the primary current, so long as its strength remains constant. Within the primary coil there is usually a bundle of soft iron wire, which becomes

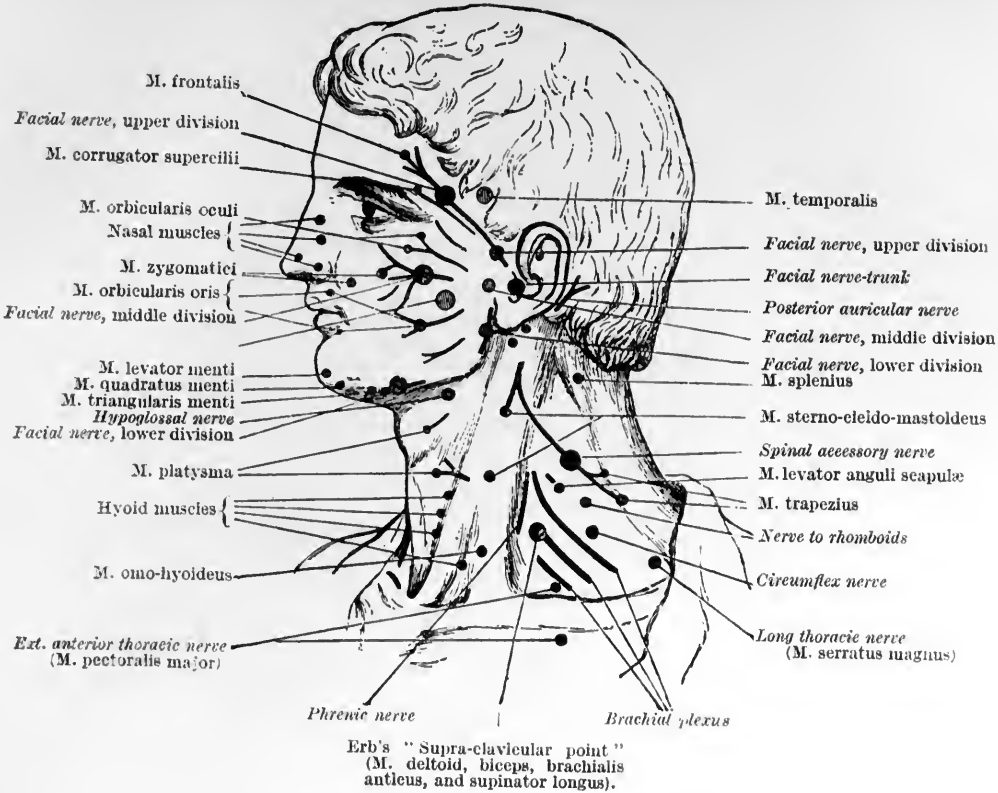

FIG. 224.—Motor Points of Face and Neck. (Erb.)

converted into a magnet when the galvanic stream flows round the primary coil. Now a magnet pushed within a coil produces an instantaneous faradic or induced shock in that coil; so that as the soft iron is alternately magnetised and then de-magnetised by the primary coil, we have the effect of the magnet superadded to that of the primary coil. We can vary the strength of the faradic shocks in the secondary coil in several ways, by pulling the iron bundle in or out, or by sliding a cylindrical brass shield between the primary and secondary coils (the effect on the secondary coil being greatest when no shield is interposed), or lastly, by having the secondary coil on a sliding sledge, so that we can pull the two coils apart. This last is the best and most delicate way of varying the intensity of the faradic shocks in the secondary coil.

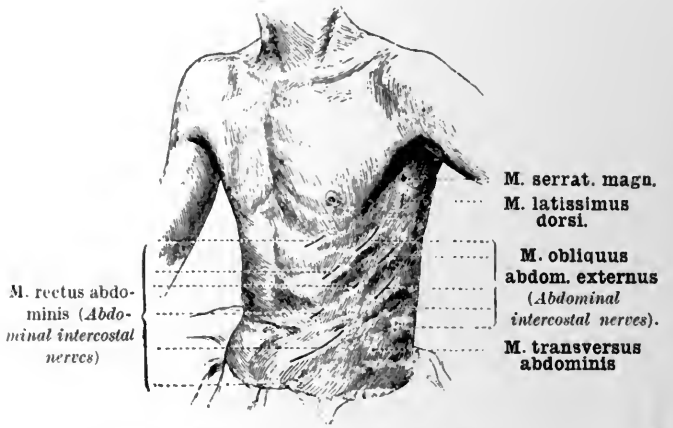
M. serrat. magn.
M. latissimus dorsi.
M. obliquus abdom. externus (Abdominal intercostal nerves).
M. transversus abdominis
M. rectus abdominis (Abdominal intercostal nerves)

Fig. 225.—Motor Points of Abdominal Wall. (Erb.)

We apply the electrical current to muscles and nerves by means of metal electrodes of various sizes, some flat and disc-like, others with rounded bulbous ends. The metal surface of the electrode should be covered with chamois-leather. The electrode is screwed on to a holder, which must have a contact-key whereby we can interrupt the current at will. The chamois-leather should be soaked before use, and the skin should also be well moistened in warm water, to which a little salt has been added, to render it a better conductor. The salt, however, spoils the leather, which must, in consequence, be frequently renewed.

We should have a galvanometer in the circuit of the galvanic current, so as to measure the strength of current which penetrates the tissues. There should also be a commutator or sliding switch, whereby we can reverse the direction of the current. The galvanic battery should be fitted with a collector whereby we can switch on the different cells, one by one, gradually increasing the strength of the current.

In testing the electrical reactions of muscles, one electrode should be placed on the spot we desire to stimulate, whilst the other is placed on some far-distant "indifferent" spot, where any muscular contractions that may occur will not interfere with the part we are observing.

Thus the indifferent pole may be placed on the back of the neck, or on the front of the abdomen, or the patient may sit upon it, or he may hold it in the opposite hand. We then fix our attention on the other pole which we are watching. To stimulate isolated nerves or muscles, either the electrode should be a small one, or we may employ the edge of a disc electrode.

The patient must be placed in a good light, so that we can see the slightest movement of the muscle we are examining. Sometimes by

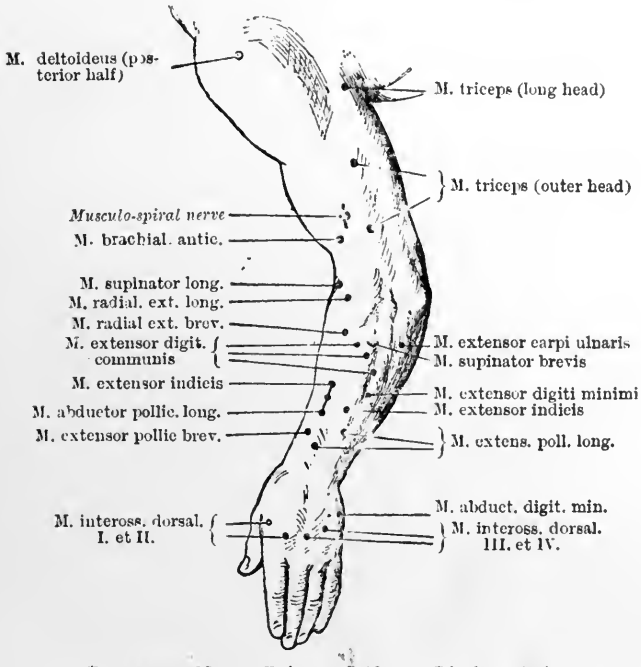

FIG. 226.—Motor Points of Upper Limb. (Erb.)

placing our finger on the tendon of the muscle, we can feel a contraction too faint to be visible. The patient should be made to relax all the muscles of the region which is under examination. Before applying the electrodes to the patient, we should make it an invariable rule to test the strength of the current on our own skin, to avoid startling him by too violent a shock.

Electro-Diagnosis.—We should commence with faradic shocks. Ordinarily these are produced in rapid succession by a vibrating Neef's hammer, "making" and "breaking" the circuit of the primary coil. If these are too painful to be borne, we may often overcome the difficulty by loosening the spring of the Neef's hammer and making and breaking the primary current by moving the spring with our finger.

This produces an isolated faradic shock each time we press the spring into contact with or remove it from the screw. Such single shocks are often tolerated by a patient who cannot bear the ordinary series of shocks in rapid succession. In children, however, it is sometimes impossible to get the patient to submit even to single shocks, and it may be necessary in them to give a general anæsthetic, in order to make an accurate electro-diagnosis.

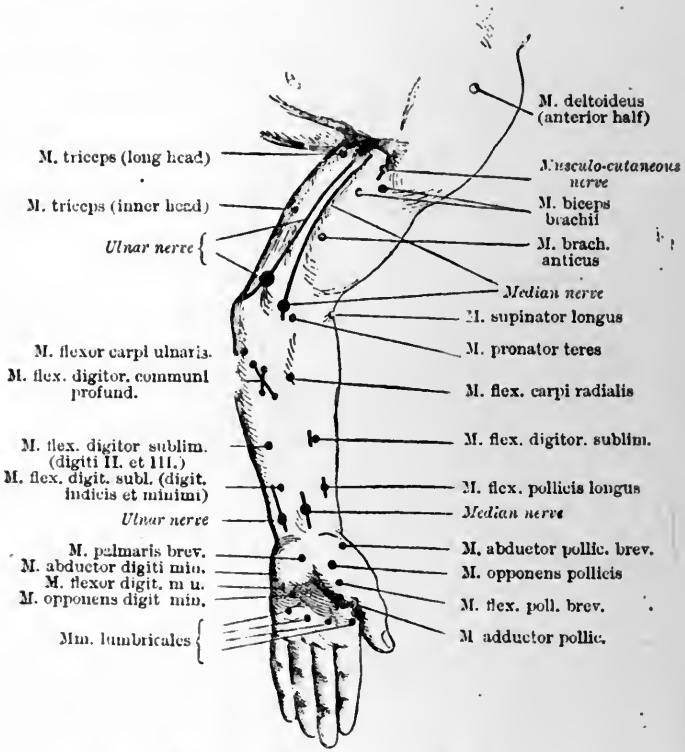

FIG. 227.—Motor Points of Upper Limb. (Erb.)

Whenever possible, we should compare the reaction of the suspected muscles with that of other muscles which are healthy, preferably the corresponding muscles of the opposite limb. Of course, when the disease is bilaterally symmetrical, this is impossible. An electrical examination, to be complete, would have to include observations on every accessible muscle and motor nerve in the body; this, however, is practically unattainable, and we usually content ourselves with selecting a group of muscles in the affected area and testing each muscle carefully, both with faradic shocks and with the continuous current, commencing with the faradic.

To be of real use, especially for prognosis, electrical examination must be repeated from time to time. A single determination of electrical reactions has about the same value as a single determination of a patient's temperature. It follows that a standard technique of examination should be adopted in electro-diagnosis.

Faradic Reactions.—Faradism stimulates a muscle most efficiently, not by direct action on the muscle-fibres, but through the motor nerve. To stimulate an individual muscle by faradism we seek for the place where the nerve enters the muscle. In a long muscle there is usually a well-defined spot known as the "*motor point.*" Faradism applied at such a "motor point" provokes a maximal contraction in that

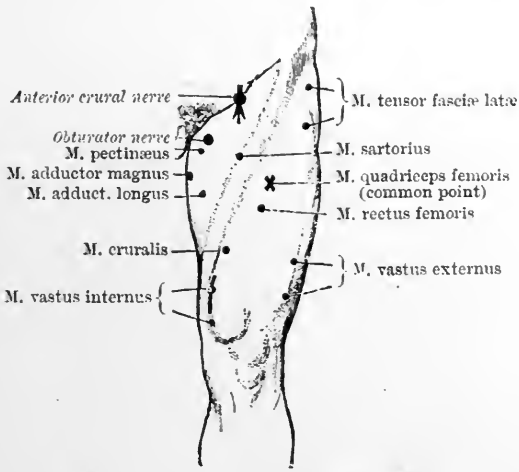

FIG. 228.—Motor Points of Anterior Thigh Muscles. (Erb.)

individual muscle. The positions of the chief "motor points" are indicated in Erb's well-known diagrams (Figs. 224 to 230). In a normal muscle, a faradic shock of a given strength produces a much greater effect when applied at such a "motor point" than when applied directly over an indifferent bundle of muscle-fibres.

Besides stimulating individual muscles, we can stimulate whole groups by applying our electrode over a nerve-trunk, such as the ulnar or musculo-spiral.

In testing faradic reactions we commence with feeble shocks and gradually increase their strength until we just get a contraction of the muscle. We then compare this contraction with that produced by the same strength of shocks applied to a healthy muscle, preferably the same muscle of the opposite limb, if available.

Galvanic Reactions.—The galvanic current stimulates a motor nerve-fibre at the moment of closure, and again at the moment of

opening of the current, but not during the period of flow, so long as the strength of the current remains constant. In the case of muscle-fibres, galvanism stimulates them at closure and again at opening, and even throughout the whole period of flow, provided the current be strong enough. Even when a nerve is degenerated, directly-applied galvanism is still able to produce contractions in the muscle-fibres.

A normal muscle is more excitable at its motor point than at any other part, whereas a degenerated muscle is equally excitable at all points on its surface. The "**polar reactions**" of a muscle to galvanism are of great clinical importance. Normally, in a healthy muscle, when

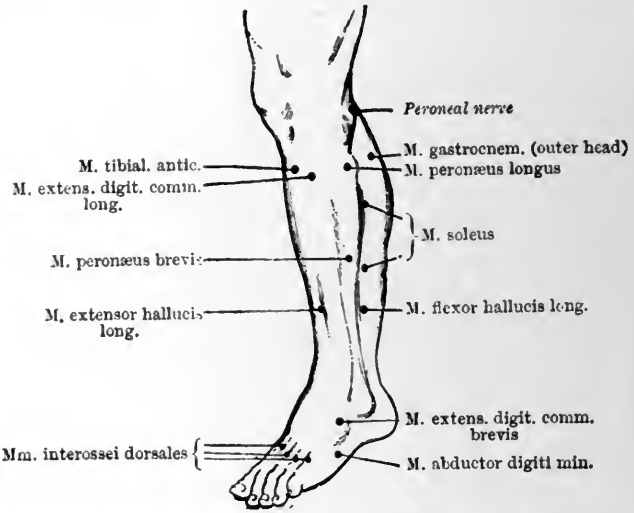

FIG. 229.—Motor Points of Leg. (Erb.)

we stimulate it with a galvanic current, not too strong, we get a brisk twitch at closure, then during the period of flow the muscle remains relaxed until the current is suddenly opened, when we may get another twitch at opening. The contraction at closure is greater if we stimulate with the kathode (negative pole) than if we employ the anode (positive pole). This is expressed by the formula KCC>ACC (kathodal-closure-contraction greater than anodal-closure-contraction). To verify this clinically on a healthy muscle, we gradually increase the strength of our current by means of the collector. Meanwhile, we make an occasional double movement of the commutator, whereby the testing pole is suddenly changed from kathode to anode and back again. Presently, as the current is increased in strength we find that at one position of this double movement we get a brisk twitch of the muscle, whilst in the

reverse position we get none. The first twitch in a healthy muscle always appears at the kathode. Then if the current be still further increased, a twitch appears at both phases of the commutator, but the kathodal contraction remains the greater. As a matter of convenience it is best to employ the minimal current strong enough to give KCC, whilst as yet there is no ACC. Meanwhile we notice on the galvanometer the number of milliamperes of current which are required to produce the earliest twitch at closure.

If the strength of the galvanic current be still further increased we obtain a twitch at opening, the anodal contraction being produced

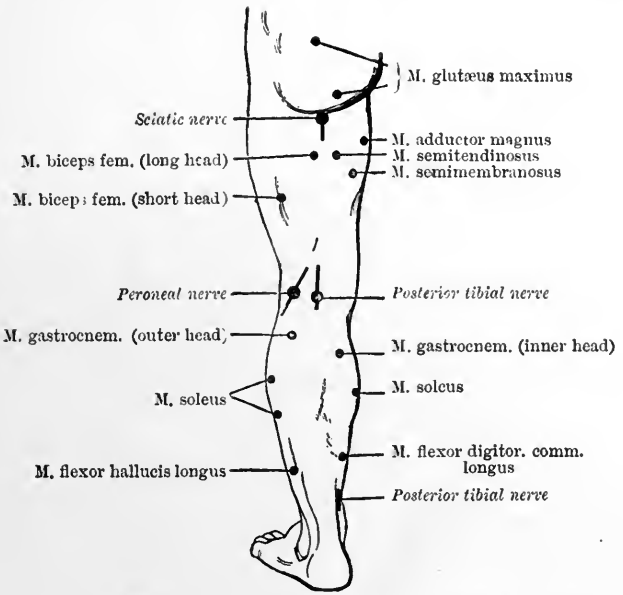

FIG. 230.—Motor Points at Back of Thigh and Leg. (Erb.)

first and the kathodal opening contraction last of all. The order of appearance of these different contractions in a healthy muscle, as the current progressively increases in strength, is therefore as follows: KCC>ACC>AOC>KOC, and is indicated in the following amplification of the same facts:—

1. Weak current - - - -	KCC	..	..	..
2. Medium current - - -	KCC	ACC	..	..
3. Moderately strong current - -	KCC	ACC	AOC	..
4. Very strong current - - -	KCC	ACC	AOC	KOC

Of these phenomena, we usually concern ourselves, for practical purposes, only with the first two, that is, with the contractions on closure, observing whether the kathodal closing contraction is greater than the anodal closing contraction, as it ought to be in health.

To recapitulate, in a normal nerve-muscle organ we obtain a good contraction on faradic stimulation, while to galvanism there is a brisk twitch on closure, KCC being greater than ACC.

Abnormalities in Electrical Reactions.—Sometimes the excitability of the nerve-muscle organ is increased, both to faradism and to galvanism. This condition of hyper-excitability is met with most typically in *tetany*, where both nerve and muscle are too easily thrown into contraction.

Somewhat similar is the so-called "*neurotonic*" *reaction*, described by Marina[1] in certain cases of hysteria, by Remak[2] in patients with progressive muscular atrophy, and by Handelsman[3] in syringomyelia. This phenomenon consists not only in excessive excitability both to faradism and galvanism, but also in a tendency for the muscle to remain in a state of tetanus for 10 to 30 seconds after the stimulus has ceased. The phenomenon is not provoked by stimulation of the muscle itself, but only by excitation of the nerve.

We sometimes meet with simple diminution of excitability, both to faradism and to galvanism, but without alteration of polar reactions —that is to say, KCC remains greater than ACC. Such *diminution of electrical excitability* is met with in simple arthritic muscular atrophy, in the atrophy of disuse and also in the various myopathies, whether pseudo-hypertrophic or atrophic in type.

Temporary loss of faradic excitability occurs in myasthenia gravis, though not in every case. When present, the *myasthenic reaction* consists in the fact that after a certain number of faradic shocks, the muscle gradually reacts less and less, until at last it shows no contraction to the strongest faradic shocks. We wait a few minutes and then test again, when we find that the faradic excitability has reappeared, but can again be exhausted in a similar fashion. The galvanic reactions of the affected muscles remain unchanged throughout the disease. A myasthenic reaction can also be produced experimentally, *e.g.* in the frog's muscles, by poisoning with yohimbine.[4] This suggests that the phenomenon is toxic in origin.

During the paroxysms of the rare disease known as *family periodic paralysis*, the paralysed muscles are, for the time, totally inexcitable either by faradism or by galvanism. This is termed the *cadaveric reaction*. In the intervals between the attacks of paralysis the muscles react normally.

The *myotonic reaction* is met with chiefly in Thomsen's disease (myotonia congenita), but has also been observed in certain types of syringomyelia accompanied by myotonia. It consists in the fact that

[1] *Neurologisches Centralblatt*, 1896, No. 17. [2] *Ibid.*, 1896, No. 13.
[3] *Ibid.*, 1911, s. 418. [4] Gunn, *Rev. of Neurol. and Psychiat.*, 1908, p. 150.

on faradic stimulation the muscular contraction persists for some time after the stimulus has ceased, as if the muscle, once contracted, cannot relax. Moreover, in this disease galvanic stimulation of the muscle produces curious wave-like contractions, and KCC is equal to instead of greater than ACC.

Condenser Reactions.—Condenser discharges are a valuable means of electro-diagnosis, and the results thus obtained can be usefully compared with those observed on faradic and galvanic stimulation.

The apparatus is simple. It consists of a set of ten or twelve condensers of varying capacities, ranging from 0·01 of a micro-farad in the smallest condenser up to 3·00 micro-farads in the largest. Between these two extremes there are eight or ten condensers of intermediate capacity. By means of a revolving commutator and a metronome any one of these condensers can be alternately charged from the main and discharged through the patient's muscles. The voltage at which the current is delivered from the main is regulated by a volt-meter, which is conveniently set at 100 volts. The condensers of different capacities differ in one essential feature, viz. their wave-length, *i.e.* the duration of their discharge through the body. The smallest condenser of the series, with a capacity of 0·01 micro-farad, takes $\frac{1}{30000}$ of a second to pass through the body, which is vastly shorter than the wave-length of any induction-coil, whose shortest duration is about $\frac{1}{400}$ of a second, or slightly less. The largest condenser, that with 3·00 micro-farads, has a duration of discharge of $\frac{1}{130}$ second. Healthy muscles respond to the smallest condensers of 0·01 to 0·05 micro-farad. As a muscle degenerates, it requires impulses of longer and longer duration, from condensers of larger and larger capacity, to induce it to contract.

In this variety of muscle-testing we place our electrodes in position, attach our box of condensers to the main, set the metronome going at a speed of about one beat per second, and then, by moving a key over successive studs on the switchboard, we find out the smallest condenser which just causes the muscle to contract and produces the first flicker of response.

One defect of this method is that the condenser discharges vary with the resistance of the patient's body and with other factors, so that, even using the same apparatus on each occasion, our observations are less precise than would at first sight appear.

The process of testing by means of condensers, unlike faradic or galvanic testing, is entirely painless, the only sensation produced being that of the sudden muscular twitch. Moreover, it is unnecessary to decide whether the contraction produced by the condenser discharge is brisk or sluggish, strong or weak. All we have to decide is whether the muscle contracts at all, and, if so, to which condenser.

In healthy muscles, contractions are produced by the smallest condensers of the series, viz. from 0·01 to 0·02 micro-farad.

Reactions of Degeneration.—By far the most important modification of electrical reactions is the condition known as the " reactions

of degeneration," or, colloquially, as R.D. This condition is present when the nerve-muscle organ has undergone degeneration, from disease or destruction of the spino-muscular motor neurone. As a result of such a lesion, the motor nerve-fibre disintegrates within a few days and loses its power of conducting impulses. The corresponding muscle-fibre undergoes important changes; it loses its fibrillar or anisotropic element, the element which contracts with a brisk twitch and can be stimulated with a faradic shock; whilst it retains only its sarcoplasm, a much less excitable element, which contracts slowly but can still be stimulated by galvanism and by condenser shocks of a slow wave-length.

In a typical case the phenomena are as follows:—to *faradism* there is no response, since the nerve has degenerated; to *galvanism* the muscle-fibres still respond—in fact, for a short time they become hyperexcitable, contracting to a weaker current than in health. But their polar reactions are altered. The anodal contraction on closure is now equal to, or greater than, the kathodal (ACC>KCC). Moreover, what is equally characteristic, the response of the muscle is no longer a brisk twitch; it is a slow, sluggish, almost vermicular movement. Further, the degenerated muscle is equally excitable at all points on its surface, and no longer shows a maximal excitability at its motor point.

In cases yielding complete R.D. by farado-galvanic methods, if we examine the muscles by condenser discharges we find that, instead of giving a response to condensers of 0·01 to 0·02 micro-farad, they will not respond to condensers smaller than 0·50 micro-farad, and may require 1·00, 2·00, or even 3·00 micro-farads, *i.e.* an impulse whose duration is from 100 to 300 times as long as that required in health.

Sometimes by doubling the voltage (*i.e.* 200 volts instead of 100) a condenser of half the capacity may produce a contraction in a muscle which previously failed to contract. Thus, for example, a muscle which has failed to respond to 2 micro-farads at 100 volts, may perhaps respond to 1 micro-farad at 200 volts. This phenomenon is often present in muscles which are beginning to regenerate after previous degeneration, and is therefore of prognostic significance.

If a nerve be divided, the reactions of degeneration do not appear at once. It is only after some ten days or so that they develop. Once established, the reactions of degeneration persist, unless the nerve regenerates and re-establishes a connection between the muscle and the motor nucleus. In the process of recovery, voluntary motor power reappears before faradic excitability returns. In many cases recovery does not take place and the nerve-muscle organ remains permanently

degenerated, as, for example, when the motor nucleus in the cord or medulla is destroyed, or when a nerve-trunk is completely divided and its ends have not been reunited.

In certain cases we meet with **partial or incomplete reactions of degeneration**. These consist in a sluggish contraction to galvanism, ACC being greater than KCC, but the reaction to faradism is not lost, but only diminished. This condition indicates a less severe injury of the nerve-fibres than if typical R.D. be present.

Conditions of partial R.D. can be further differentiated into those of mild and severe degree, according to the response of the muscle to condenser-shocks of increasing wave-lengths. As a muscle degenerates, instead of responding to condensers of 0·01 to 0·02 micro-farad, larger condensers of 0·25 or 0·50 micro-farad, with longer wave-lengths, are required.

Sometimes we have *mixed reactions*, some fibres of a muscle retaining their normal reactions whilst adjacent fibres have reactions of degeneration. This is best exemplified by cases of progressive muscular atrophy where degenerated muscle-fibres are interspersed amongst the healthy.

To sum up, then, the presence of R.D. always indicates a lesion somewhere in the lower or spino-muscular motor neurone. We should be careful to wait ten days or a fortnight from the onset of the paralysis before giving a verdict, inasmuch as we have seen that it takes some time for degeneration to become established. R.D. occur in lesions of peripheral motor nerves, also in gross nuclear diseases such as acute anterior poliomyelitis, hæmorrhage or thrombosis in the anterior cornua or motor nuclei. Mixed reactions, on the other hand, are found in progressive muscular atrophy and in bulbar palsy, where the nerve-cells of the motor nuclei are picked out one by one, leaving adjacent nerve-cells unaffected.

Electro-Prognosis.—In many paralyses due to organic lesions of peripheral motor nerves (of which the commonest instance is that of a neuritis of the facial nerve), it is of importance to be able to estimate not only the degree of degeneration which has occurred, but also the prospects of recovery. To make an accurate prognosis we must wait at least ten days, and preferably a fortnight, before making our investigation, so as to allow time for degenerative changes to have occurred. Electrical examination at any earlier date is practically valueless for purposes of prognosis.

If, after a fortnight's motor palsy—say, in a case of Bell's paralysis—we get typical R.D., the degeneration of the nerve is severe and recovery will not commence for three months at least, possibly not for a year, and the patient may even remain permanently paralysed. And at the

best, if recovery does occur, it will probably be imperfect and associated with some contracture.

If partial R.D. be present, the prognosis is less grave and recovery may be expected within six or eight weeks.

If the reactions be normal, or if there be simply a diminution to faradism and galvanism, but without polar changes, recovery may be looked for in from three to six weeks, or even sooner.

In a regenerating muscle, voluntary power reappears before any improvement occurs in the faradic or condenser reactions, except in some cases complicated by a functional element in which the patient does not realise the existence of his voluntary muscular power.

CHAPTER XXIII

THE CEREBRO-SPINAL FLUID

The cerebro-spinal fluid is secreted by the glandular ependymal cells which cover the choroid plexuses and constitute the "choroid gland." The fluid flows from the ventricles into the sub-arachnoid space, bathing the brain and spinal cord. The total amount of fluid normally present is estimated at from 100 to 150 cubic centimetres. Normally the fluid is constantly secreted in a quantity sufficient to replace that which is continually reabsorbed into the general circulation, partly by way of the lymphatics, veins, and intra-cranial sinuses of the dura mater, and partly by osmotic diffusion through the sub-arachnoid space into the capillaries. In cases of cranial or spinal injury when the sub-arachnoid space is in communication with the surface, as much as 2 to 4 litres daily have been observed to escape. In some patients, as St. Clair Thompson and others have shown, a spontaneous flow of cerebro-spinal fluid occurs through the cribriform plate and drips constantly from the nose.

The posterior lobe of the pituitary body pours its secretion through the hollow infundibulum into the cerebro-spinal fluid of the third ventricle. Experiments by Cushing and Goetsch[1] have demonstrated that normal cerebro-spinal fluid contains a substance which gives the same reaction as extracts of the pars nervosa itself. The fluid also receives various products of metabolism from the nerve-centres. It may undergo changes in lesions of these centres or of their meninges; hence the clinical importance of its examination.

Various drugs, taken by the mouth, can be detected in the cerebro-spinal fluid. Thus urotropin taken by the mouth can be shown to yield formic aldehyde in the fluid, whilst in acute alcoholic poisoning alcohol can be demonstrated in the fluid, in a proportion of from 1·5 to 4 per cent., within two or three hours after the alcohol has been taken. In delirium tremens, on the other hand, due to sudden withdrawal of alcohol in a chronic alcoholic subject, the cerebro-spinal fluid contains little or no alcohol.

In the adult, the spinal cord terminates at the level of the lower part of the first lumbar vertebra. Below that level the arachnoidal

[1] *Am. J. of Physiology*, 1910, vol. xxvii., p. 60.

sac extends as a hollow cavity as low down as the second sacral vertebra (see Fig. 231). There is thus a considerable extent of arachnoidal cavity devoid of spinal cord, occupied simply by the roots of the cauda equina and by the cerebro-spinal fluid which bathes them. From this region we can withdraw cerebro-spinal fluid without risk of injury to the spinal cord. In order to do so, we enter the cerebro-spinal cistern from behind, somewhere between the laminæ of the second lumbar and the second sacral vertebra.

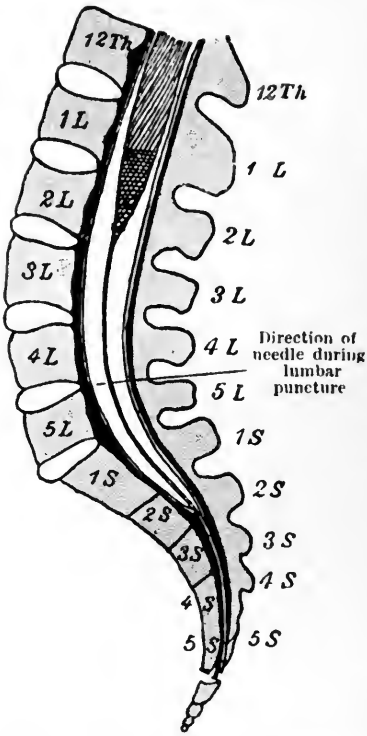

Fig. 231.—(After Raymond.) Diagram of lower end of vertebral column and its relations to the spinal cord and cauda equina. The double-shaded portion of the cord is the conus terminalis, with which the filum terminale is continuous.

The two widest inter-laminal spaces are the one between the third and fourth, and the other between the fourth and fifth lumbar laminæ. Of these we usually select the space between the fourth and fifth laminæ, because, as a rule, it is slightly the larger. These two inter-laminal spaces are very easily found as follows: we draw a horizontal line across the patient's back, at the level of the highest margin of the iliac crests. This line intersects the vertebral column at the tip of the fourth lumbar spine. We make our puncture immediately below this spine (Fig. 232).

It is convenient to use an all-glass syringe which is readily sterilisable on which to mount our needle, which should be of fairly large calibre. The needle itself is made of platinum and iridium, which is less liable to snap and can also be boiled without rusting, unlike a steel needle. It must be long enough to reach into the arachnoidal sac, and yet short enough to stop short within the sac without penetrating to the dura on the far side. For this purpose the most suitable length of needle is about 8 centimetres, or just over 3 inches.

As to the patient's posture during **the operation of "thecal puncture,"** he may be lying on a bed or couch, in the left lateral position, with the knees and shoulders approximated. But it is better, if possible, to have him sitting on a low seat, stooping well forwards, with his knees separated, his arms hanging loose, and his hands touching the

ground. In this way the laminæ are separated to their widest extent (see Fig. 232).

We carefully sterilise the skin at the site of puncture and render it anæsthetic by means of a spray of ethyl chloride. The operator places his left index finger on the fourth lumbar spine as a guide, and with his right hand pushes in the needle about half an inch below and half an inch to the right of this spot (so as to avoid the dense interspinous ligament), directing the point of the needle horizontally forwards and a little inwards. The ligamentum subflavum, deep in, between the laminæ, is somewhat resistant, and the needle is felt to be checked here. But we push firmly on, if no bone is struck, and suddenly the needle penetrates the ligament and dura-arachnoid and is now in the arachnoidal sac (see Fig. 233). If we strike on a lamina instead of the ligament, we withdraw slightly and try a point above or below.

Fig. 232.—Lumbar puncture. Fluid dropping from needle into test-tube.

Sometimes during the operation the patient feels a sudden, sharp pain shooting down his right thigh and leg. This simply means that our needle has touched one of the roots of the cauda equina *en route*, and is of no other significance.

We now detach the syringe and allow the cerebro-spinal fluid to escape through the needle, collecting from 3 to 5 c.c. in a sterilised test-tube. It is better not to employ suction by the syringe, unless some difficulty be experienced in getting the fluid to run. The pressure of the fluid as it escapes may be measured, if desired, by means of a rubber tube with a manometer attached. Normally the fluid trickles out slowly, drop by drop, at the rate of about 60 drops per minute. The first few drops should be discarded, since they may be mixed with blood from our needle-wound of the superjacent tissues.

Occasionally it happens that even when we have successfully penetrated within the ligamentum subflavum no fluid will flow. This is usually due to blocking of the needle by a small plug of blood-clot or shred of muscle or connective-tissue during the process of puncture. Or it may be due to one of the cauda equina roots floating against the end of the needle. Such conditions are easily rectified by passing a

sterilised stilette along the needle to clear it. Sometimes it happens that the needle pierces the ligamentum subflavum, but pushes the spinal theca in front of it, so that, even though the stilette shows the needle to be free from obstruction, no fluid comes. In such cases it is best to withdraw the needle and puncture at the next space above.

The normal pressure of the cerebro-spinal fluid, in the recumbent posture, is from 10 to 15 centimetres of water. This is the result of the secretory pressure of the choroidal epithelial cells. In the sitting position the pressure is higher, amounting to 20 to 25 centimetres. Coughing causes a slight elevation of 2 to 4 centimetres. Respiratory variations are not noticeable in the normal subject, but in cases in which the intra-thecal pressure is increased to 30 centimetres and upwards, slight respiratory waves may occur, not amounting to more than 2 or 3 centimetres.

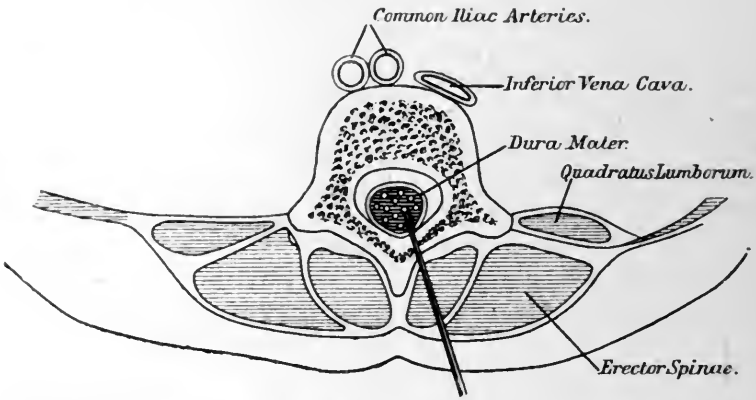

FIG. 233.—Horizontal section at the level of the fourth lumbar vertebra, showing the relations of the parts concerned in thecal puncture.

Sometimes the intra-thecal pressure is increased, so that the fluid escapes in a jet, instead of drop by drop. This occurs chiefly with intra-cranial tumours and in the various forms of meningitis, although even in these conditions an increased fluid-pressure in the lumbar region is by no means constant, for sometimes in meningitis there is occlusion of the foramen of Magendie, in the roof of the fourth ventricle, or of the foramina of Key and Retzius, at its lateral angles, or the cerebellum may be partially impacted in the foramen magnum, cutting off the intra-ventricular from the spinal pond.

The fluid may be accidentally mixed with blood from the wounding of an arachnoidal vein during the puncture; this is an accident which cannot be guarded against. In most cases such local bleeding clears up after a few seconds, the fluid becoming progressively clearer and

clearer. But admixture of blood also occurs in cases of pre-existent sub-arachnoid hæmorrhage, cerebral or spinal, as in fracture of the skull, intra-ventricular hæmorrhage, or in trauma of the spinal cord.

We can usually distinguish between hæmorrhage due to the local puncture and hæmorrhage which results from a previous intra-thecal lesion. We do this by centrifuging the fluid. In local hæmorrhage due to puncture, the blood-corpuscles fall to the foot of the centrifuge-tube, leaving the superjacent fluid clear and limpid, whereas in a pre-existing cerebral or spinal hæmorrhage the fluid (which during its flow is equally tinged from start to finish, and generally less deeply tinged than in local hæmorrhage) remains of a yellow colour even after centrifuging (xanthochromia).

In most cases the withdrawal of a small quantity of cerebro-spinal fluid causes the patient no discomfort. But in a small proportion of cases he may complain of severe headache, appearing an hour or two later, and lasting perhaps for several days. This is most often the case in patients who walk about as usual after the puncture, and headache can generally be prevented by recommending the patient to rest for a day or so, or at least to avoid physical exertion.

Normal cerebro-spinal fluid is absolutely colourless, like water. It is an alkaline, saline fluid:—a natural, physiological, saline solution, with a specific gravity of 1006 to 1008. It contains sodium chloride, together with a trace of serum-globulin and of albumose (the total albumin being from 0·025 to 0·05 per cent.), and also glucose, which reduces Fehling's solution and forms osazone crystals. Microscopically it contains a few large, flat, endothelial plates, and perhaps an occasional lymphocyte. It contains no organisms.

The Diagnostic Significance of Cerebro-spinal Fluid.—For diagnostic purposes the fluid may be examined in various ways.

(1) **Physical Characters.**—Instead of being clear and limpid like water, the fluid may be opalescent, turbid, cloudy, or even purulent, as in some cases of meningitis. In severe jaundice it has been observed to be yellow and clear, whilst in cases of recent hæmorrhage either into the brain or cord it may, as we have mentioned, be blood-stained. In hæmorrhages of older date, say a week or more, the fluid may be of a clear yellow colour—xanthochromia. The coexistence of xantho-chromia, with spontaneous coagulation of the fluid on standing, generally points to chronic compression of the spinal cord (see later, p. 419.)

The mere absence of cloudiness or coloration, however, does not necessarily mean that the fluid is healthy, since we obtain perfectly clear cerebro-spinal fluid in such diseases as tabes, general paralysis, and certain forms of meningitis.

In spinal injuries the presence of blood in the cerebro-spinal fluid may be of considerable diagnostic importance (see later, p. 496).

In cases of sudden hemiplegia we are sometimes in doubt whether the lesion is hæmorrhage or thrombosis. The diagnosis between these two conditions may be very difficult. But the treatment of the two is diametrically opposite. In a case of thrombosis we stimulate the heart and, if necessary, push our antisyphilitic remedies, whereas in cerebral hæmorrhage we try to lower the intra-cranial blood-pressure and diminish the force of the heart. If in a doubtful case we perform lumbar puncture and obtain blood-stained fluid, or fluid which has a yellow tinge after centrifuging, the diagnosis is simplified. In traumatic cases this is of great value in indicating the presence of sub-arachnoid intra-cranial hæmorrhage. But in compound fracture of the skull lumbar puncture may yield nothing if the fluid happens to be escaping by other channels, viz. through the lacerated membranes.

(2) **Chemical Characters.**—These are of value. Thus, for example, a marked excess of albumin is found in acute meningitis, and to a lesser degree in tabes and in general paralysis of the insane, the protein concerned in tabes and general paralysis being globulin. This is the so-called "phase i." reaction of Nonne.

One method of examining for globulin is by Noguchi's test,[1] which is performed as follows:—

To two parts of cerebro-spinal fluid are added five parts of 10 per cent. solution of butyric acid in normal saline solution. This mixture is heated to boiling-point, and then one part of a normal (4 per cent.) solution of sodium hydrate is added and the mixture is again boiled briefly. After standing for two to thirty minutes, if a globulin be present, there is a flocculent or granular precipitate.

A simpler method of detecting globulin (and one which is free from the olfactory discomfort of Noguchi's method) is by means of ammonium sulphate.[2]

On to the surface of a saturated solution of ammonium sulphate in a test-tube a small amount of cerebro-spinal fluid is allowed to flow by means of a fine pipette. If globulin be present, a fine white ring appears at the junction of the two fluids.

The Nonne-Apelt test consists in mixing together equal quantities of cerebro-spinal fluid and saturated solution of ammonium sulphate, and shaking them together. If globulin be present, cloudiness appears within three minutes.

Another delicate test for protein is by means of a solution of salicyl-sulphonic acid.

[1] *Journal of Experimental Medicine*, 1909, vol. xi., p. 84.
[2] Jones, *Review of Neurol. and Psychiatry*, 1909, p. 379.

One or two drops, added to 1 or 2 c.c. of cerebro-spinal fluid, precipitate the protein. With a 10 per cent. solution of salicyl-sulphonic acid, even a normal fluid gives a precipitate. But if we dilute our solution down to a 2 per cent. strength, no precipitate now occurs with a normal cerebro-spinal fluid; whereas, in paralytic dementia a precipitate occurs in over 80 per cent. of cases, and in cerebro-spinal syphilis and tabes in nearly 70 per cent.[1]

In some cases this excess of protein is so great that the fluid, on standing, coagulates into a jelly-like clot, usually of a golden yellow colour. This is always pathological, and has been found in certain tumours of the spinal cord or meninges, and even in cerebral tumours. It is not necessarily accompanied by any excess of cells. It has more often been observed in syphilitic or tuberculous meningo-myelitis, in which conditions there is superadded a considerable increase in the cell content.[2] To recognise the pleocytosis, we wait until the coagulum has retracted, then decant the supernatant fluid, centrifuge it, and examine the deposit microscopically. This combination of *massive coagulation with xanthochromia* is apparently due to annular constriction of the spinal meningeal space, damming up of the cerebral from the spinal fluid, and the formation of a stagnant lumbo-sacral meningeal pouch or cul-de-sac.

In acute meningitis, whether tuberculous or pyogenic, sugar is almost always absent, the sugar being broken up by the organisms, with the formation of lactic acid. Hence the alkalinity of the fluid is reduced. In chronic meningitis, in tabes, and in general paralysis of the insane, sugar is often diminished.

The **Wassermann reaction** in the cerebro-spinal fluid (consisting in an abnormal fixation of the blood-serum complement, whereby the normal hæmolysis no longer occurs in the presence of red blood-corpuscles) is frequently of the greatest diagnostic value. In cerebro-spinal syphilis, whether of meningo-vascular type or of parenchymatous type, as in tabes and general paralysis, the reaction is positive in varying proportions. Thus in general paralysis and tabo-paralysis (both of them actively-progressive syphilitic diseases), it is positive in from 98 to 100 per cent. of cases, in tabetics in from 48 to 50 per cent., and in meningo-vascular cerebro-spinal syphilis in from 8 to 25 per cent.,[3] being more marked in affections of the spinal than of the cerebral meninges.

The *urea* content of the normal cerebro-spinal fluid is approximately the same as that of the blood, *i.e.* from 0·02 to 0·05 per cent. But in

[1] Hudovernig, *Neurologisches Centralblatt*, 1917, pp. 657 and 699.
[2] Raven, *Deutsch. Zeitsch. f. Nervenheilkunde*, 1912, Bd. 44, s. 381. Greenfield, *Lancet*, 1912, ii., p. 685.
[3] Mott, *Brit. Med. Journal*, November 18, 1911, p. 1337. Eichelberg, *Neurologisches Centralblatt*, 1912, p. 931. Head and Fearnsides, *Brain*, 1914, vol. xxxvii., p. 79.

cases of uræmia the cerebro-spinal fluid may contain urea in quantities of 0·1 to 0·2 per cent., or even higher.[1]

A simple chemical test for meningitis is by means of a solution of **potassium permanganate** (0·1 per cent.).[2] Equal parts of cerebro-spinal fluid and perm nganate solution are mixed in a test-tube. With normal cerebro-spinal fluid the colour of the mixture remains pink. If meningeal changes be present, however, the permanganate becomes reduced, and a yellow or brown colour appears within two or three minutes. This reaction can also be carried out as a "ring-test," the permanganate solution being carefully poured on the top of the cerebro-spinal fluid. The brown and yellow zones then appear at the junction of the two fluids.

Lange's **colloidal gold reaction**[3] also enables us to detect the presence of inflammatory changes in the cerebro-spinal fluid. It further indicates whether these are syphilitic in origin or due to other varieties of infection.

Its underlying principle consists in the fact that colloidal solutions, whether organic or inorganic, are protected against precipitation in the presence of a small amount of albumin, by means of electrolytes. When the amount of albumin is increased, precipitation occurs, but if the albumin increases beyond a certain point, protection against precipitation again sets in.

Only a small quantity of cerebro-spinal fluid (0·2 c.c.) is required for the test, which is carried out as follows:—

To a litre of freshly distilled water are added 10 c.c. of a 1 per cent. solution of chloride of gold, together with 5 c.c. of a 5 per cent. solution of glucose. This is heated to boiling-point, and then, drop by drop, to the boiling fluid is added a 5 per cent. solution of caustic potash, until a deep red colour is produced. This is usually obtained with from 3·6 to 4 c.c. of KOH solution. All the above-mentioned reagents must be made with freshly distilled water, using vessels of specially pure glass, free from any trace of soda, sterilised in distilled water. If the resulting solution has a blue tinge, it is useless. It must be deep red.

A row of 10 or 12 narrow test-tubes is set up in series. Into the first of these we place 1·8 c.c. of a 0·4 per cent. solution of NaCl (made up with freshly distilled sterilised water), together with 0·2 c.c. of cerebro-spinal fluid, constituting a 1/10 dilution. In each of the remaining tubes of the series we place 1 c.c. of NaCl solution. From the first tube (which contains 2 c.c. of a 1/10 dilution) we now remove 1 c.c. by means of a pipette, and transfer it to the second tube, thus making a dilution of 1/20. After thorough mixing, we again transfer 1 c.c. from the second to the third tube, making a dilution of 1/40, and so on, throughout the series of tubes, obtaining dilutions of 1/10, 1/20, 1/40, 1/80, 1/160, 1/320, etc., down to 1/10,240.

[1] Soper and Grant, *Archives Int. Med.*, 1914, p. 131.
[2] Boveri, *Münchener med. Wochenschrift*, June 2, 1914, p. 1215.
[3] Lange, *Berlin. klin. Wochensch.*, 1912, No. 19. Eicke, *Münch. med. Wochensch.*, 1913, No. 49.

To each of these tubes, containing 1 c.c. of progressive dilutions of cerebro-spinal fluid, we now add 5 c.c. of the gold solution. The whole technique is carried out in about five minutes.

Normal cerebro-spinal fluid gives a negative reaction, *i.e.* in all the tubes the red colour remains unchanged, even after standing twenty-four hours. If inflammatory changes are present, however, the albuminoid substances precipitate the gold, changing the colour from the original red to a bluish-red, to lilac, dark blue, pale blue, or even to a colourless solution. In the latter instance the precipitated gold falls

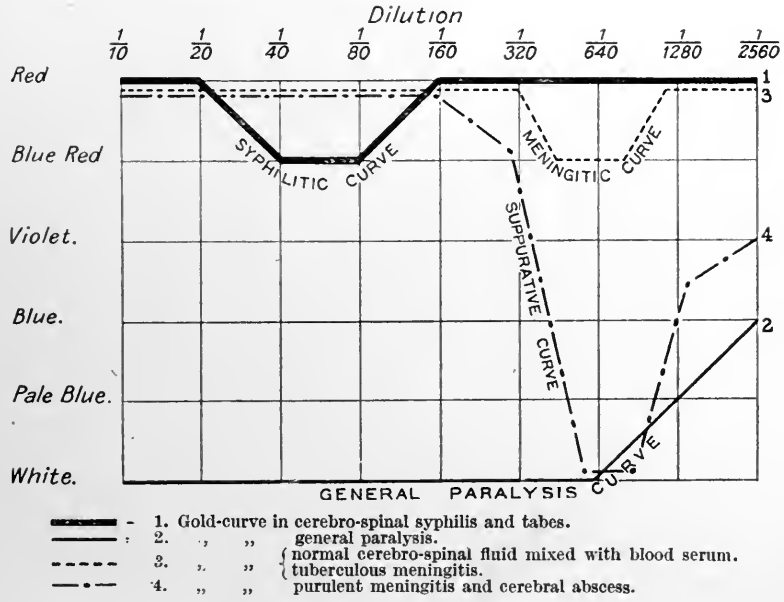

FIG. 234.—Lange's gold reaction.

down as a blue-black precipitate. We might expect this decolourisation to be proportional to the concentration of the cerebro-spinal fluid and to diminish steadily according to the dilution. This, however, is not so. Each pathological fluid has its curve of precipitation—"gold-curve," whose maximum lies at a special place in the series of dilutions. In syphilitic infection of the fluid the maximum of the curve occurs at dilutions of 1/40 to 1/80 (see Fig. 234). Stronger or weaker dilutions produce no precipitation of gold. This curve is pathognomonic of syphilis. The syphilitic gold-curve occurs also in tabes. Other diseases associated with albumin in the cerebro-spinal fluid yield quite different curves, in which the maximum is displaced to the right, so that with the stronger concentrations the gold solution remains unchanged, the maximum of the curve occurring further down the series.

In *general paralysis* the gold-curve appears different, inasmuch as all the tubes from 1/10 to 1/640 are completely decolourised. Nevertheless we observe, immediately after adding the gold solution, that precipitation always begins first at 1/40 and 1/80, just as in cerebro-spinal syphilis, whilst in the other tubes of the series it occurs much more gradually.

The addition of *blood-serum* to a normal cerebro-spinal fluid gives a gold-curve whose maximum is displaced considerably to the right, when compared with the syphilitic gold-curve. Thus the accidental contamination of cerebro-spinal fluid with traces of blood during the puncture does not obscure a syphilitic curve if present.

Tuberculous meningitis gives the same curve as blood-mixed fluid, whereas *purulent meningitis* and *brain abscess* give a still more pronounced "meningitic" curve, whose maximum is always to the right of the syphilitic.

(3) **Bacteriological Characters.**—These are chiefly of value in cases of meningitis, to determine the particular organism causing the disease. Thus, for example, in epidemic cerebro-spinal meningitis one or other strain of the meningo-coccus (*diplococcus intra-cellularis*) is found; in tuberculous meningitis, the tubercle bacillus; and in other varieties of meningitis we may find staphylococci, streptococci, pneumococci, typhoid bacilli, anthrax bacilli,[1] and so on. We should remember that failure to discover tubercle bacilli does not necessarily exclude tuberculous meningitis, though their presence confirms such a diagnosis.

To demonstrate the bacilli in tuberculous meningitis it is convenient to allow the fluid to stand from 12 to 24 hours, by which time a fine flocculent coagulum has usually formed. This is removed by a needle, spread on a slide, fixed and stained in the usual manner.

In doubtful cases inoculation experiments on guinea-pigs are of value. In Landry's ascending paralysis various organisms (tetracocci and others) have occasionally been isolated from the cerebro-spinal fluid and blood.

(4) **Microscopic Characters.**—For the clinical physician, microscopic investigation is probably the most valuable mode of examination of the cerebro-spinal fluid.

A good method is to centrifuge a given quantity of the fluid, say 5 c.c., for five minutes, thereby collecting into a small deposit all the cellular elements which may be present. We then carefully decant off all the superjacent fluid, turn the empty tube upside-down and scrape the bottom with a fine, newly made capillary pipette. In this way we collect the sediment, which is transferred to a slide, fixed by heat or alcohol-ether, stained by methyl blue or by Jenner's stain, mounted in Canada balsam and examined with the microscope.

[1] Reece, *Lancet*, March 17, 1917, p. 406.

Specimens prepared as above described afford a permanent record of the variety and intensity of the cellular contents present. To obtain absolute accuracy of counting we employ Fuchs and Rosenthal's[1] counting-chamber, a modification of the Thoma-Zeiss blood-counting chamber. In using this, a small quantity (10 cubic mm.) of cerebro-spinal fluid is mixed, by means of a special graduated pipette, with 1 cubic mm. of a staining fluid containing methyl violet and acetic acid. A drop of the mixture is placed on the counting-stage, and the cells are counted. The results so obtained correspond with those found in centrifuged deposits, but are more accurate. But the preparation so obtained is not a permanent one, and I am, therefore, now in the habit of employing both the centrifuge and the counting-chamber, the one to yield a permanent specimen, the other to ensure accurate counting of the cellular contents of the fluid.

In rare cases we may find parasites. Thus, for example, Castellani and Bruce[2] found the trypanosome of sleeping-sickness not only in the blood of such patients, but also in the cerebro-spinal fluid, where it is accompanied by lymphocytosis. In fact, it is easier to identify the trypanosome in the cerebro-spinal fluid than in the blood, wherein it is likely to be obscured by blood-corpuscles. In trichiniasis the motile embryo worms may be detected not only in the muscles, but also in the cerebro-spinal fluid.

In a few cases of metastatic malignant growths of the spinal cord or of its meninges, tumour-cells have been found in the fluid. But this is inconstant, though tumour-cells, if present, have a high positive diagnostic value.

By far the most valuable point to be determined microscopically is the presence or absence of leucocytes, observing not only their number, but their type. This is the so-called **cyto-diagnosis.**

Normal cerebro-spinal fluid contains no polymorpho-nuclear leucocytes and only an occasional small mono-nucleated lymphocyte, with now and then a few endothelial plates. Examination of the centrifuged deposit with a magnification of 400 diameters, according to the technique described, should show an average of not more than two or three lymphocytes to the field, or from 1 to 3 per cubic mm. Sometimes we find no cells of any sort.

But in certain organic diseases of the central nervous system or its membranes, there may be a pleocytosis or excess of leucocytes, whether polymorphs or monomorphs. Briefly stated, in cases of acute microbic infection of the brain and meninges, especially the suppurative varieties, we find a polynuclear pleocytosis, where the leucocytes are mostly polymorphs, with some large monomorphs as well. But it is the acuteness of the inflammatory process, not its microbic origin, which is the chief factor in producing polynuclear pleocytosis. Thus I have experi-

[1] *Wiener medizinische Presse*, 1904, s. 2084.
[2] *Brit. Med. Journ.*, November 21, 1903.

mentally produced abundant polynuclear pleocytosis in monkeys by injecting sterile salt solution or a sterile emulsion of coloured particles into the spinal theca.

When recovery begins, in acute meningitis, the polynuclear leucocytes in the cerebro-spinal fluid diminish in numbers and become replaced by lymphocytes. These latter in turn disappear as convalescence becomes complete.

If a brain abscess be present without implication of the superjacent meninges, as sometimes occurs, the cerebro-spinal fluid shows no excess of leucocytes. Examination of the fluid is therefore a valuable means of distinguishing between meningitis and brain abscess. In both conditions a blood-count shows a great excess of polymorphs in the blood: these may number from 10,000 to 25,000 or more (instead of from 8,000 to 10,000 per cubic millimetre as in health), the leucocytosis of the blood being, as a rule, higher in meningitis than in brain abscess.

In subacute and chronic affections of the meninges, whether tuberculous, syphilitic, or from other causes, *e.g.* lead-encephalopathy, also in certain chronic degenerative diseases of the central nervous system, we usually find a lymphocytosis, *i.e.* an excess of small monomorphs, sometimes accompanied by a small proportion of large monomorphs. In cases of acutely advancing tuberculous meningitis we often find a considerable proportion of polymorphs (30 per cent. and upwards) amongst the monomorphs. There is occasionally a marked lymphocytosis in cases of mumps, and in this disease acute encephalitis sometimes develops. During an attack of herpes zoster and for a number of days afterwards there is often a lymphocytosis of the cerebro-spinal fluid.

In the early days of an attack of acute anterior poliomyelitis, before the onset of paralytic symptoms, we find well-marked changes in the cerebro-spinal fluid, consisting of a mixed pleocytosis (chiefly monomorphs, with some polymorphs), together with an excess of globulin. Meanwhile the blood also shows a distinct leucocytosis, with a relatively high proportion of monomorphs.[1] In cases of acute chorea we occasionally find a mixed pleocytosis, indicating that this disease is not to be classed as a pure neurosis.

In several cases of lymphatic leukæmia at the Westminster Hospital, and in a case of chloroma, Hebb also observed marked lymphocytosis of the cerebro-spinal fluid.

In functional nervous diseases the fluid is normal.

Let us study some illustrative cases.

One case was an example of epidemic cerebro-spinal meningitis, in a patient who was comatose and apparently moribund. The cerebro-spinal

[1] Fressell, *Journal of American Med. Assoc.*, March 4, 1911.

fluid was under excessive pressure, of turbid appearance, and the centrifuged deposit showed microscopically an average of 87·3 polymorphs to the field. Within many of the leucocytes the meningo-coccus was readily distinguished. The withdrawal of about an ounce of fluid caused prompt improvement in the symptoms and the patient made a good recovery.

Another case was that of an officer who had chronic otitis media on the left side. He rapidly developed mental dulness and slight aphasic symptoms, with some fever. In his case the fluid was turbid, and showed no fewer than 371 polymorphs to the field. Operation was at once undertaken and an inflamed area of brain tissue in the temporal lobe was exposed. No abscess was found. The symptoms rapidly subsided and the patient made a complete recovery.

As an instance in which the cerebro-spinal fluid was normal may be mentioned the case of a child, in whom, as is so often the case, a deep-seated pneumonia was ushered in by head symptoms simulating meningitis —so-called "meningism." There were marked headache, some head-retraction, and squint. Moreover, an older child in the same family had previously died from tuberculous meningitis, and the parents were therefore in considerable anxiety as to the possibility of this case being another of the same nature. The cerebro-spinal fluid, however, showed no excess of cells, glucose was present in it in normal amount, and Kernig's sign was absent. Meningitis was therefore less likely than a transient toxic meningism, and an encouraging prognosis was given, which proved correct.

Meningism occurs chiefly in children, and especially in those with a tuberculous diathesis. The symptoms appear during the course of some other acute febrile illness, especially measles and mumps. After the meningitic symptoms have subsided there is often a stage of transient cerebellar ataxia, which also ultimately clears up.[1]

With regard to cases of lymphocytosis, the most striking results are those observed in parenchymatous cerebro-spinal syphilis, which include general paralysis of the insane, tabes dorsalis, and "optic tabes." The lymphocytosis in these affections (which are essentially the same disease etiologically, and which clinically are not infrequently combined in the same patient) is more marked than in any other form of organic nervous disease.

Thus in a series of forty cases of general paralysis examined by me, the average number of lymphocytes was 98·7 per cubic mm., the lowest count in any one case being 34·4, and the highest 462.

In a series of twenty-two tabetics, the lowest count was 19 2, the highest 477·1, and the average number per cubic mm. for the whole series was 144·3.

A point of importance noticed in cases of tabes and general paralysis is that not only is lymphocytosis present in practically every case, but it is often extremely marked when the other symptoms of the disease are very slight.

Thus, for example, one patient had lightning-pains, analgesia of the tendo Achillis, but no ataxia, no abnormality of the pupils, and brisk knee- and ankle-jerks. Yet his cerebro-spinal fluid showed 150 lymphocytes per

[1] Foerster, *Neurolog. Centralblatt*, 1913, p. 1414.

cubic mm., and his was undoubtedly an early case of tabes. The same applies to general paralysis. One patient with 239·6 lymphocytes per cubic mm. was an early case, with practically no mental symptoms, simply a slight loss of memory and a history of two attacks of unconsciousness followed by transient aphasia and weakness of the right hand—"congestive attacks."

In general paralysis the fluid practically always contains "plasma cells."

These are mononuclear cells, somewhat larger than the ordinary lymphocytes, with an eccentrically-placed circular nucleus which has a characteristic "clock-face" arrangement of its chromatin granules. The surrounding protoplasm is abundant and stains deep pink with the pyronin methyl-green stain.[1]

We therefore possess in the cytological examination of the cerebro-spinal fluid a valuable means of recognising tabes and general paralysis in their earliest stages. If no excess of lymphocytes be present, these two varieties of parenchymatous or central syphilis can usually be excluded.[2] Another point of interest is that during the pyrexial attacks of general paralysis there is a **temporary polynuclear pleocytosis,** not only of the blood, but of the cerebro-spinal fluid. Thus in a case of my own there were 118 polymorphs and 25 monomorphs per cubic mm. Pappenheim [3] also has recorded similar cases.

Another point of importance is that syphilis by itself, unless there be an active syphilitic lesion of the central nervous system, or of its meninges, as in the well-known syphilitic headache, produces little or no excess of cells in the cerebro-spinal fluid. A transient lymphocytosis may, however, occur during the secondary eruption of syphilis, not only in patients with symptoms of headache, insomnia, etc., but also, though less frequently, in patients without any symptoms pointing to cerebral nervous disease. In tertiary syphilis, again, without nervous phenomena, the cerebro-spinal fluid is usually normal.

Thus we see that the presence in the cerebro-spinal fluid of a positive Wassermann reaction, with a large lymphocytosis, and the presence of globulin, in a patient who has had syphilis, is of grave significance, and

[1] Rehm, *Histol. u. histopath., Arbeit über die Grosshirnrinde*, Bd. 3, September 2, 1909. Henderson and Winifred Muirhead, *Rev. of Neurol. and Psychiat.*, 1913, p. 195.

[2] This rule, however, is not without exceptions, for I have seen a case of tabes, with ataxia, Argyll-Robertson pupils, and absent knee- and ankle-jerks, in which the cerebro-spinal fluid contained only 3·3 lymphocytes per mm.^{3}, and another advanced case with only 4 lymphocytes per mm.^{3} and a negative Wassermann reaction. Erb,* Head and Fearnsides,† and others, have also recorded similar cases, which signify that the disease is no longer progressive, but is in a quiescent stage, either spontaneously or as a result of treatment.

[3] *Monatschrift für Psychiatrie und Neurologie*, 1907, s. 536.

* *Deutsche Zeitsch. f. Nervenheilkunde*, 1907, p. 438.

† *Brain*, 1914, vol. 37, p. 101.

indicates cerebro-spinal syphilis, either of the meningo-vascular type or of the parenchymatous type, as in tabes or general paralysis. In such cases we should carefully examine for other signs of organic disease, especially for Argyll-Robertson pupils, early optic atrophy, alterations in the reflexes, and sensory changes. Even if no clinical sign of organic disease be present, the presence of globulin, lymphocytosis, and a positive Wassermann reaction in the cerebro-spinal fluid is an indication for energetic anti-specific treatment, in the hope of preventing further developments.

The presence of lymphocytosis in tuberculous meningitis is readily understood, also that which occurs in tuberculous tumours on the surface of the brain. It is more difficult at present to account for the occasional excess of lymphocytes in cerebral neoplasms.

Thus one case of glioma of the centrum ovale had no fewer than 75 lymphocytes to the field, a count which led one to expect a tuberculous mass, there being no probability of syphilis. Yet the autopsy showed a glioma which had in no way approached the meninges; and a hæmorrhage into the substance of the tumour had caused death by bursting into the lateral ventricle.

Lymphocytosis also occurs in some extra-medullary tumours, especially in the region of the cauda equina.

The occurrence of eosinophile cells in the cerebro-spinal fluid is practically pathognomonic of cysticercus infection of the brain or spinal cord.

Therapeutic Applications of Thecal Puncture.—Lumbar puncture was originally introduced by Quincke for the purpose of relieving intracranial pressure in tuberculous meningitis. This it does for the time, though it is more often palliative than curative. In one case of mine the patient, a young man, comatose and apparently moribund, regained consciousness for a day, after the withdrawal of 22 c.c. of cerebro spinal fluid. The fluid was allowed to flow until the increased intra-thecal pressure fell to normal. The importance of this procedure, not only from sentimental reasons, but possibly on medico-legal grounds, is obvious. In any case, we can usually diminish or abolish the convulsions which are so distressing to the onlookers. But sometimes lumbar puncture has proved curative, even in tuberculous meningitis. Thus in cases recorded by Freyhan,[1] Henkel,[2] Barth,[3] Pitfield,[4] and in others under my own care, tubercle bacilli were demonstrated in the cerebro-spinal fluid and yet the patients ultimately recovered, after repeated punctures.

[1] *Deutschemedizinische Wochenschrift*, 1904, No. 36.
[2] *Münchener medizinische Wochenschrift*, 1900, s. 133.
[3] *Ibid.*, 1902, No. 21.
[4] *American Journal of Medical Sciences*, July, 1913, p. 37.

In other forms of meningitis, associated with a polynuclear pleocytosis (apart from infective cases secondary to bone disease), especially in epidemic cerebro-spinal meningitis, good results have been obtained by injections of antiseptic substances, after withdrawal of a corresponding quantity of cerebro-spinal fluid. For this purpose, a 1 per cent. solution of lysol has been found useful, 10 to 20 cubic centimetres being introduced at each sitting.[1]

Anti-meningococcus serum, prepared from immunised horses, injected in doses of about 30 c.c. repeated on several successive days, has had highly encouraging results in epidemic meningitis.[2]

Other sera are also introduced intra-thecally. Thus in cerebro-spinal syphilitic diseases, including tabes and general paralysis, we may employ the patient's own blood-serum, diluted and sterilised, after a previous intravenous injection of salvarsan or neo-salvarsan. Again, in the acute febrile stage of poliomyelitis anterior acuta, a curative serum can be injected intra-thecally.

In delirium tremens a rapid sedative action can be obtained by the intra-thecal injection of 50 cubic centimetres of a 1 per cent. solution of sodium bromide, after previous withdrawal of an equivalent amount of cerebro-spinal fluid.[3]

In intra-cranial pressure due to other causes, as, for example, in inoperable or inaccessible cerebral tumours, lumbar puncture is sometimes of distinct benefit as a palliative measure, by diminishing urgent pressure and thereby relieving headache, vertigo, and other symptoms. Hitherto, to relieve intra-cranial pressure and to diminish optic neuritis, it has been the custom to trephine the skull as a palliative measure. But lumbar puncture is quicker, simpler, and less dangerous than a major cranial operation. I performed it in three cases of intra-cranial tumour. In all of them the headache and vertigo were greatly relieved for several weeks after the puncture, and an opportunity was afforded of studying the patient's focal symptoms with a view to subsequent removal of the growth. In intra-cranial growths we must be careful not to withdraw too large a quantity of cerebro-spinal fluid, lest sudden diminution of pressure cause a hæmorrhage into the tumour (a result, by the way, which sometimes occurs after a palliative trephining). In fractures of the base of the skull, coma may be quickly relieved by the withdrawal of cerebro-spinal fluid. I saw such a patient, after a carriage accident, in whom lumbar puncture was followed by rapid improvement. The procedure may, if necessary, be repeated several times on successive days.

In cases of coma due to sunstroke, withdrawal of cerebro-spinal

[1] França, *Comptes rendus Soc. de Biologie*, 1917, lxxx., p. 422.
[2] Ker, *Edin. Med. Journal*, October, 1908.
[3] Kramer, *Boston Med. and Surg. Journ.*, October, 1913, p. 646.

fluid often has an almost immediate curative effect. The fluid in such cases is usually under increased pressure and shows a polymorph pleocytosis, indicative of an acute meningeal reaction.

Sometimes the pain of a migrainous attack may be relieved almost immediately by the withdrawal of cerebro-spinal fluid.

Uræmic coma and convulsions, and attacks of puerperal eclampsia, are often relieved in a striking manner by lumbar puncture, and in several instances life has undoubtedly been saved by such means.

For example, McVail[1] records two cases of acute nephritis in which, notwithstanding energetic treatment by purgatives, hot-air baths and pilocarpin to induce free perspiration, coma and convulsions supervened. Lumbar puncture was performed, 20 to 28 c.c. of cerebro-spinal fluid were withdrawn, and within three or four hours the coma passed off, the convulsions ceased, and both patients ultimately made a complete recovery.

Cases like these raise the question as to whether the headache, coma, and convulsions in nephritis are really caused entirely by "uræmic poisoning" of the brain-centres, or whether they may not be largely due to a sudden increase of intra-cranial pressure as part of the general œdema.

Again, in cases of tetanus, it has been shown that the tetanus poison has a selective action on the motor nerve-cells of the spinal cord and brain. Therefore, in addition to removing the tetanus bacilli at the site of inoculation by excision of the original wound, we endeavour to neutralise any free toxin by means of tetanus antitoxin. This is sometimes administered hypodermically or intravenously, but only a fraction of the antitoxin thus injected reaches the nervous system, the main mass being distributed uselessly to other tissues. It is better to administer the antitoxin (with perhaps the addition of stovaine) by means of lumbar puncture. It may be necessary to give a general anæsthetic, to relax the opisthotonos, before performing the spinal puncture.

Strychnine poisoning is also successfully treated by intra-thecal administration of eucaine.

Injection of anæsthetic drugs by thecal puncture—so-called **spinal anæsthesia**—is useful when we desire to perform operations on the lower limbs or trunk without rendering the patient's brain unconscious. Various substances have been successfully employed as spinal anæsthetics, amongst which may be mentioned magnesium sulphate, cocaine, stovaine, and a mixture of novocaine with strychnine.[2] It is desirable,

[1] *Brit. Med. Journ.*, 1903, vol. ii.

[2] The following are examples of anæsthetising solutions:—
1. Stovaine, 5 per cent.; glucose, 5 per cent. in water. Sp. gr.=1023. Dose=1 c.c. (Barker, *Brit. Med. Journ.*, 1908, p. 248.)
2. Stovaine, 4 per cent.; sod. chloride, 0·11 per cent.; suprarenin borate,

if possible, to have a solution which is isotonic with the blood-serum, *i.e.* having the same osmotic tension.

For spinal anæsthesia in operations on the pelvis and lower limbs we generally select the first or second lumbar interspace, whilst Jonnesco prefers "dorso-lumbar" injection between the twelfth thoracic and the first lumbar vertebra, thereby producing analgesia of the whole abdomen and lower limbs. We perform our puncture in the mesial line, so that the roots of both sides may be equally affected. Before injecting the anæsthetising solution, we withdraw a quantity of cerebro-spinal fluid, exceeding in amount the fluid to be introduced.

Spinal anæsthesia is essentially a root anæsthesia, due to paralysis of the posterior roots. On injecting a solution of stovaine in the lumbar region, the earliest objective signs are disappearance of the knee-jerks (usually within one minute), then of the ankle-jerks (within two or three minutes), the superficial reflexes remaining as yet unchanged. Concurrently with the abolition of the deep reflexes there occurs slight analgesia of the perineum and genitals, without loss of tactile sensibility. The analgesia gradually deepens and spreads over the lower limbs, and after four or five minutes the plantar and cremasteric reflexes disappear. Temperature sense becomes lost. Tactile and pressure sense disappear much later and may be preserved throughout. Sense of position is last and least affected. The dartos or scrotal reflex is unaffected. Motor paralysis, due to affection of the anterior roots, supervenes last of all, in five or six minutes, beginning in the feet and soon affecting the whole musculature of the lower limbs. The deep structures also become analgesic. If it is desired to reach the higher roots by a heavy anæsthetising fluid, it is advisable to elevate the pelvis higher than the thorax, to permit the fluid to gravitate towards the thoracic region. In this way the anæsthesia may extend as high as the nipples, or even to the upper limbs. If the injection be made with the patient lying on his side, the heavy anæsthetising solution gravitates to the dependent side and therefore exercises its effects chiefly, and it may be entirely, on the roots of that side. Thus, for example, by laying a patient on his left side and injecting in that posture, Barker[1] was able to amputate

---

0·01 per cent. in water. Sp. gr. = 1005. Dose = 1 c.c. (Bier, quoted by Barker, *Brit. Med. Journ.*, 1907, p. 665.)

3. Stovaine, 1·5 per cent.; cocaine, 0·5 per cent. in water. Dose = 4 c.c. (Chaput, *La Presse Médicale*, 1907, p. 753.)
4. Novocaine, 2 per cent.; suprarenin borate, 0·009 per cent.; NaCl, 0·9 per cent. Sp. gr. = 1014. Dose = 5 c.c. (Braun, *Deutsche med. Wochenschrift*, 1905, s. 1667.)
5. Strychnine sulphate, 5 to 10 cg.; sterilised water, 100 grams. Of this solution 1 c.c. is mixed with 3 to 10 cg. of stovaine, and the mixture is injected (Jonnesco, *Brit. Med. Journal*, 1909, p. 1396.)

[1] *Brit. Med. Journ.*, 1908, p. 246.

the left leg painlessly, without producing sensory or motor impairment of the right lower limb.

After lasting for 45 to 90 minutes, the paralytic phenomena begin to pass off. First motor power returns, then the analgesia fades away, and last of all the reflexes, superficial and deep, reappear.

Spinal anæsthesia by means of stovaine can also be employed, as Jonnesco[1] has shown, at higher levels of the cord if strychnine be added to the stovaine so as to protect the cord from depressing vaso-motor or

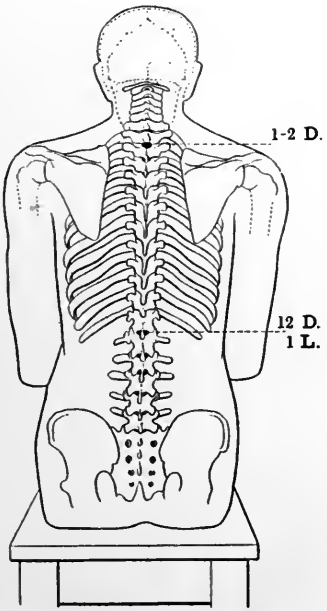

Fig. 235.—Showing sites of "upper dorsal" and of "dorso-lumbar" injections for spinal anæsthesia. (Jonnesco.)

respiratory effects. For operations on the head, neck, and upper limbs Jonnesco recommends an "upper dorsal" puncture, between the first and second dorsal vertebræ. Injections at any higher level are unnecessary, besides being too close to the medulla oblongata for safety. For operations on the abdomen and lower limbs, Jonnesco recommends a "dorso-lumbar" injection between the twelfth dorsal and fifth lumbar vertebræ (see Fig. 235). It should be borne in mind that both in "upper dorsal" and in "dorso-lumbar" punctures the spinal cord lies immediately subjacent to the site of the puncture, and it is therefore important to stop the needle immediately its point has penetrated within the spinal theca, so as to avoid injury to the spinal cord.

In performing an "upper dorsal" injection we first feel for the vertebra prominens (seventh cervical). Then taking the first dorsal spine

[1] *Brit. Med. Journ.*, 1909, p. 1398.

immediately below this (the patient's head being strongly flexed, so as to separate the laminæ), we slowly push in our needle, in the mesial plane, along the upper border of the second dorsal spine. On reaching the dura mater a momentary resistance is felt, and when the needle reaches the arachnoidal space, cerebro-spinal fluid at once begins to trickle. Unless fluid is seen to escape, we cannot be sure that the point of the needle is in the arachnoidal cavity. Sometimes it is useful to make the patient cough, to start the flow. As soon as the fluid begins to escape we attach our injection-syringe and slowly introduce the mixture of stovaine and strychnine. After an upper dorsal injection, if the operation is to be on the head or neck, the patient should be on his back. If the operation is to be on the upper limbs or thorax, he should sit up for two or three minutes before lying down.

For upper dorsal injections Jonnesco recommends relatively smaller amounts of strychnine ($\frac{1}{2}$ mg.) and of stovaine (1 to 3 cg.), whereas in dorso-lumbar injections the doses of strychnine (1 mg.) and of stovaine (4 to 10 cg.) are large.

Spinal anæsthesia is contra-indicated in severe scoliosis, because of the difficulty in accurately penetrating the theca. It is also better avoided in young children and in most cases of hysteria. Even apart from such cases, it should, I believe, be reserved for very special conditions, as, for example, acute abdominal cases, conditions of shock, and severe cardiac or pulmonary diseases, where a general anæsthetic is particularly dangerous. From the patient's point of view, complete unconsciousness is generally preferable to the mental strain of remaining conscious whilst an operation is being performed on his analgesic legs or trunk.

Of the morbid phenomena which sometimes follow spinal anæsthesia, the most frequent is headache; this is often of great severity and may last for days; it is probably due to the altered intra-cranial pressure produced by the addition of the anæsthetising solution, and may generally be relieved by a simple lumbar puncture, withdrawing from 10 to 20 c.c. of fluid. In three-fourths of cases of spinal anæsthesia, according to Schwarz,[1] there is a slight transient albuminuria, lasting for a week or more. Another sequela, fortunately an uncommon one, is ocular palsy, chiefly of one external rectus, but sometimes of some other ocular muscle; such palsy may last for days or weeks, but ultimately clears up.

[1] *Zeitschrift für Chirurgie*, 1907, s. 651.

CHAPTER XXIV

DISORDERS OF SLEEP

"The innocent sleep,
Sleep that knits up the ravelled sleave of care,
The death of each day's life, sore labour's bath,
Balm of hurt minds, great nature's second course,
Chief nourisher in life's feast."

SHAKESPEARE: *Macbeth.*

MOST of us spend about one-third of our life asleep. Nevertheless the physiology of sleep is not yet completely understood. Let us recall the chief phenomena of ordinary healthy sleep. Firstly, there is diminution and then loss of conscious recognition of ordinary stimuli, such as would ordinarily attract our attention, whether these stimuli be derived from the outer world or from within the sleeper's own organism. There is also, as consciousness is becoming blunted, a characteristic and indescribable sense of well-being. Voluntary movements become languid and ultimately cease, and the muscles of the limbs relax. Meanwhile there develops double ptosis or drooping of the eyelids; the pupils contract; the respiratory movements become slower and deeper, the pulse is slowed, the cutaneous vessels dilate to a slight extent and the general temperature of the body falls, whilst many processes of metabolism, such as those of digestion and of certain secretions, are retarded.

Many of these phenomena, *e.g.* the contracted pupils, slow pulse, etc., are evidences of increased activity of the autonomic system.

Various explanations have been offered to account for all these phenomena. But at the outset we should recognise that the process is a complex one, implicating many other organs besides the brain. An animal from which the cerebral hemispheres have been removed still shows regular alternations of sleep and waking.

As regards the condition of the brain during natural sleep, it is generally admitted that it is anæmic. If we observe a patient or an animal that has been trephined, we see that during sleep the volume of the brain is diminished; it sinks in and becomes pale, *i.e.* the cortical vessels are contracted. This vaso-constriction is not confined to the superficial vessels alone; it implicates the whole cerebral circulation, for if we succeed in examining the patient's retinal vessels with an

ophthalmoscope without wakening him, we find that they present a similar vaso-constriction. Cerebral anæmia, then, is one important factor in natural sleep. We are all familiar with the difficulty of doing mental work and the tendency to fall asleep, after a heavy meal. This is doubtless explained to some extent by the occurrence of temporary abdominal hyperæmia together with compensatory cerebral anæmia.

Let us next consider the condition of the nerve-cells during sleep. The activity of some of them, certainly of the cortical cells, is temporarily diminished. Some writers have suggested that this is due to a retraction of the dendrites, by a sort of amœboid movement whereby nerve-cells previously in contact become, as it were, temporarily insulated. But the evidence in support of this theory is far from convincing. In fact, modern histological observation goes to show that nerve-cells are not merely in contact, but that neuro-fibrillæ are continuous from cell to cell throughout the nervous system.

Other writers ascribe the phenomena of sleep to poisoning of the nerve-cells by accumulation of carbon dioxide, or to intoxication by other waste-products of metabolism acting as narcotics. Be this as it may, we must bear in mind, as Claparède[1] has urged, that neither carbon dioxide poisoning nor intoxication is a necessary antecedent to sleep. On the contrary, we usually sleep for the purpose of avoiding auto-intoxication and of preventing exhaustion, not because auto-intoxication or exhaustion has supervened. Healthy sleep is not necessarily a poisoning of certain nerve-centres by toxic by-products. We may feel intensely fatigued without being drowsy, and, conversely, we may feel drowsy without being physically or mentally fatigued. Moreover, there is a regular periodicity whereby a healthy person, whether fatigued or not, has a recurrent appetite for sleep. Sleep has a constructive, anabolic, invigorating effect on the whole body. Part of this effect is doubtless due to physical rest, part perhaps to interruption in the production of toxins arising from muscular contraction, and part to the absence of stimuli which during waking hours excite nervous katabolism.

Some writers have assigned special importance to a particular region of the brain in connection with the function of sleep, and especially to the floor of the third ventricle and the Sylvian aqueduct. In support of this they point out the familiar ptosis and the tendency to divergent strabismus, both of which might be explained as due to paresis of the ocular nuclei. They also recall the well-established fact that tumours in the region of the pituitary body or infundibulum are specially likely to have as an early symptom persistent drowsiness, possibly from subpituitarism. Some of these phenomena could be explained as due to

[1] *Archives de Biologie*, 1905.

cerebral anæmia, the tumour at the base mechanically compressing and narrowing the arteries which form the circle of Willis. This has been demonstrated in several instances.

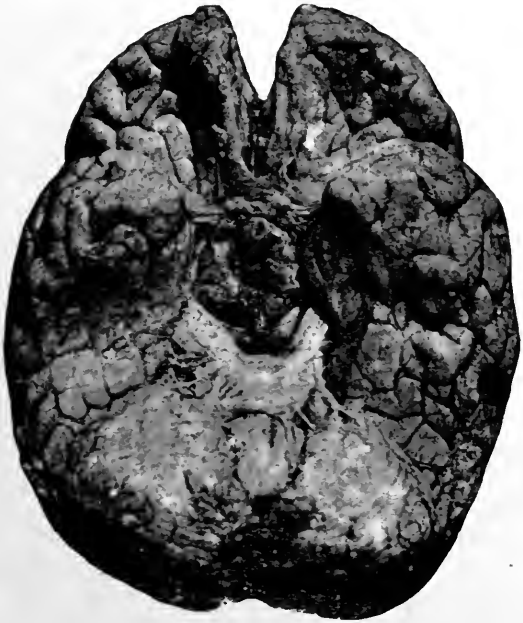

FIG. 236.

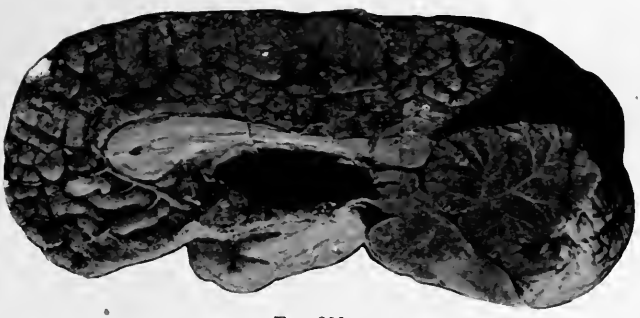

FIG. 236A.

FIGS. 236 AND 236A.—Cystic tumour of pituitary infundibulum, containing colloid material and compressing the third ventricle from below upwards. This patient suffered from paroxysms of overwhelming drowsiness (narcolepsy).

I myself had under my care the case of a large cystic growth of the pituitary infundibulum pressing upwards on the floor of the third ventricle (Figs. 236 and 236A) in a young woman of 26, in whom the chief symptoms were paroxysms of overpowering sleep. She ultimately passed into a stuporose condition and died. No paralytic phenomena occurred during life, nor was there any optic neuritis.[1]

[1] *Review of Neurology and Psychiatry*, 1909, p. 225.

Another case of mine was that of a young man of thirty-four who had intense drowsiness, paroxysmal headaches, and signs of dyspituitarism, including total loss of sexual power. He also had blindness of the right eye and temporal hemianopia of the left, with slight pallor of the right optic disc, signs pathognomonic of a lesion of the optic chiasma. All these phenomena were due to a tumour of the pituitary body. His drowsiness was so intense that he fell asleep if he sat down, and only with difficulty could he be roused for examination.

Another factor in the production of natural sleep is the absence of violent external stimuli such as loud sounds or dazzling light; therefore silence and darkness, by withdrawal of stimuli, conduce to sleep. The pleasing monotony of gently reiterated stimuli often has a similar soothing effect which is quite *sui generis* and is closely analogous to the condition of hypnosis. It cannot be ascribed to cerebral anæmia, to exhaustion, nor to any toxic action.

We recognise different degrees of normal sleep, according to the strength of stimulus necessary to rouse the sleeper to a consciousness of his surroundings. The lightest is that of mere drowsiness, a stage in which the sleeper, though not directing his conscious attention to surrounding objects, can still be easily wakened by moderate stimuli such as ordinary conversation, light touches, etc.

A deeper stage is sleep with dreams, where the sleeper is unconscious of his surroundings, but yet his psychical centres, uncontrolled and deprived of the faculty of comparison with his environment, produce a series of fantastic mental pictures. Under the influence of dreams a sleeper may, if his cortical motor centres are still active whilst the psycho-sensory centres are uncontrolled, perform motor actions, as in the well-known stage of sleep with somnambulism. But in health somnambulism is rare, because ordinarily the cortical motor centres are dulled simultaneously with the sensory.

Still more profound is the stage of deep dreamless sleep. This variety merges into what under pathological conditions we call stupor and ultimately coma. The chief distinguishing point between deep sleep and coma is that a sleeping person can be roused, whereas a comatose patient cannot.

Disorders of Sleep.—We sometimes meet with **pathological drowsiness** or **hypersomnia**. This is most frequently associated with some variety of toxæmia. Perhaps the most common instance is that of an anæmic young woman. Here the drowsiness may be partly toxic, due to absorption of poisons, whether from a loaded intestine, from decaying teeth, or from other sources, but the main element in causation is probably vascular. In such a case the heart is devoid of energy, and the vessels throughout the body are flabby and deficient in tone. Therefore in the erect attitude the vessels of the brain are badly filled,

and if the patient sits down during the day she feels drowsy. But when she lies down at night, the brain now becomes hyperæmic from want of vascular tone, and the result is that she lies awake. This combination of diurnal drowsiness with nocturnal wakefulness is highly characteristic. In treating the condition, besides attacking the anæmia, we often administer digitalis, since, besides being a cardiac tonic, it has also a vaso-constrictor action. If digitalis be combined with iron and with bromide of potassium, the condition usually improves rapidly.

Drowsiness also occurs in other conditions. *Myxœdematous* patients are habitually sleepy and stupid, probably from toxæmia and thyroid insufficiency. So also are many idiots and cretins. After a severe fit of epilepsy it is common for the patient to fall into a deep *post-epileptic* sleep, largely due, no doubt, to toxic products produced by the nervous and muscular systems during the fit. Certain *tumours of the brain*, especially those in the region of the floor of the third ventricle, as we have already seen, are associated with early and persistent drowsiness; so also are some cases of punctured wounds in the same region.[1] Elsewhere in the brain, tumours may also produce drowsiness at a late stage of the disease, probably from increased intra-cranial pressure, though in these cases the condition more nearly approaches coma and ultimately merges into it. The intense drowsiness produced by the combination of exhaustion with extreme cold, as in Arctic travellers, Alpine climbers, or Atlantic airmen who are in danger of being frozen to death, is probably largely due to deficient circulation, and unless vigorous measures be taken to stimulate the heart and the general circulation, sleep passes on to coma and death. The hibernation-sleep of certain animals is largely due to winter-cold, for if such animals be kept in a warm atmosphere throughout the winter, they do not sleep more than in summer time. The delightful drowsiness produced by gazing into a red fire on a winter afternoon is something entirely different. It is probably a mild variety of hypnotic sleep, the continuous red glow acting through the optic nerves by a summation of stimuli. It is not a question of the mere heat of the fire, for unless the blaze be seen, drowsiness is less likely to supervene. A similar summation of stimuli probably explains the well-known church-drowsiness. The soothing monotony of the sermon, combined with the sitting posture of the listener (who thus has the additional excuse of a degree of cerebral anæmia), and lastly the common habit of closing the eyes to avoid visual distractions—all these combine to make church-drowsiness a popular disorder. I do not refer, of course, to wild "revival" meetings, nor to militant political or sensational sermons, where the conditions, both of preacher and of audience, are entirely different.

[1] Knagg, *Lancet*, 1907, p. 1477.

But there are other pathological varieties of sleep to which we must refer. There is the drowsiness of impending *uræmic* or *diabetic coma*, both toxic in origin. There is also that remarkable tropical disease, **sleeping-sickness**, endemic in certain parts of Africa, and associated with the presence of trypanosomes in the blood, glands, and cerebro-spinal fluid. The drowsiness in this malady is doubtless due to some toxin produced by the parasites. In the later stages of the disease a peri-vascular cellular infiltration is found around the cerebral vessels, a variety of chronic meningo-encephalitis, somewhat similar to that which occurs in paralytic dementia, but also affecting the floor of the third ventricle and iter. A lesion of similar localisation is present in the various types of **lethargic encephalitis** (see p. 136) and a toxic affection of this same region probably occurs in *botulism* (p. 137). Both in lethargic encephalitis and in botulism the cranial nerve nuclei in the floor of the iter, especially the oculo-motor nuclei, tend to be affected, producing squint or other ponto-bulbar phenomena.

Ankylostomiasis often produces drowsiness, probably from toxic absorption resulting from the intestinal parasites.

Narcolepsy is a condition in which the patient has sudden paroxysms of sleep in the midst of whatever occupation he may be pursuing at the moment. Most of these cases are hysterical. I remember one such patient who used to fall asleep when playing the piano or during a game of cards (especially if he held a losing hand). He showed numerous other hysterical phenomena, and the diagnosis presented no serious difficulty. Hysterical narcolepsy is also met with in war-time. The attack comes on suddenly, during or after a bombardment. The patient appears to be asleep and cannot be roused. But he resists attempts to separate the eyelids whilst the orbiculares oculorum often show a fine tremor. After a day or two the patient suddenly wakes up.

Other cases of narcolepsy, however, are associated with organic diseases of the pituitary body or in the floor of the third ventricle. Others, again, occur in an otherwise healthy individual independently both of hysteria and of organic brain-lesions. In *congenital narcolepsy* there occur paroxysms of sudden, overwhelming sleep appearing at the age of puberty and recurring for many years afterwards. These attacks are liable to be induced by emotional excitement, particularly if the patient laughs, when his muscles suddenly relax and he falls sound asleep.

The **hypnotic trance** is another condition, analogous in some respects to ordinary sleep, but time does not allow us to discuss it here. Suffice it to say that the phenomena of hypnosis can be induced by repeated monotonous stimuli, visual, auditory or otherwise, aided by suggestion. The patient is thereby made to fall into a sleepy condition, varying in

intensity from mere drowsiness to dreams (the incidents of which are controlled by suggestion), to somnambulism, or to deep dreamless slumber lasting perhaps for many hours. There are also the well-known phenomena of *spontaneous somnambulism*, due to the remaining awake, as it were, of the cortical motor centres when the higher sensory and pyschical centres have lost their power of inhibition. Such a patient gets up and acts his dream.

Nightmares are horrifying dreams associated with a feeling of agonising helplessness, and producing so much distress that they sometimes waken the patient up in a state of dyspnœa. They are generally toxic in origin. Their commonest cause is gastro-intestinal fermentation, certain articles of diet (proverbially a lobster supper) being specially liable to produce bad dreams. In children nightmares ofter recur again and again with the peculiarity that the terrifying hallucination is the same on each occasion. Here again gastro-intestinal fermentation is often a factor. Still more frequently do we find that the child has adenoids, which interfere with respiration and produce a degree of carbon dioxide poisoning. Removal of adenoids and attention to the bowels cure most cases of night-terrors in children. Patients with tropical abscess of the liver, curiously enough, are particularly liable to horrible dreams, so much so that they may be afraid to fall asleep. Here again the condition is doubtless toxic. Nightmare is also a frequent symptom in patients with aortic regurgitation. In them the condition is not toxic, but vascular in origin, due to irregularity in the blood-supply and to pulsation in the cortical capillaries.

In patients suffering from war-neuroses, terrifying dreams are frequently associated with a low blood-pressure, and if this can be restored to normal by suitable treatment, *e.g.* pituitrin, adrenalin, etc., the dreams often lose their element of terror.

Lastly, let us consider the subject of **sleeplessness** or **insomnia**. Cases of insomnia may be divided into two great classes, the extrinsic and the intrinsic.

Extrinsic insomnia includes those cases in which the sleeplessness is secondary to some outside cause, not directly arising in the cerebrum or its blood-vessels. For example, physical pain of any sort, cough, vomiting, frequent micturition, diarrhœa, pruritus, and so on, may keep a patient awake. In all such cases we must treat the primary symptom; when it is relieved, sleep will follow naturally. This group also includes emotional insomnia, which is more often the result of grief than of joy, and more commonly associated with fear or apprehension for the future than with remorse or sorrow for the past. When pleasurable emotion does cause insomnia, it is generally due to anticipation of some happiness in the immediate future.

A man does not usually lie awake because someone is going to leave him a fortune twenty years hence, but he may spend a sleepless night on the eve of his wedding. The treatment of emotional insomnia, apart from assuaging the patient's sorrow (a matter which is often beyond the physician's sphere), is best accomplished by giving some cerebral sedative, such as a mixture of chloral and potassium bromide. The insomnia of extreme joy seldom calls for treatment, but if the patient becomes too excited here again a cerebral sedative may be given.

We are much oftener consulted with regard to the other kind of insomnia, which we may call **intrinsic insomnia**. This is commonly due to vascular, toxic, or nervous faults, or to combinations of all three.

As to *vascular* causes, the brain may be hyperæmic, rendering sleep impossible. Hyperæmic insomnia may be either of the high-tension or of the low-tension type. In high-tension vascular insomnia the patient may be the subject of general arterio-sclerosis or of renal disease; or the condition may accompany a war-neurosis. The hypertension is readily demonstrated by the Riva-Rocci sphygmo-manometer. In such cases the patient complains of difficulty in falling off to sleep. A useful remedy for this is to relax the vessels by some vasodilator such as erythrol tetranitrate, and to give a mercurial aperient such as blue pill or calomel, say two or three times a week. This often brings down the tension in a remarkable way, and induces sleep. Of course we also lay down careful regulations as to diet, etc., in these cases. Low-tension vascular insomnia occurs in anæmic and neurasthenic patients, as already explained, and is characterised by the fact that when the patient sits erect in a chair he becomes drowsy, whereas when he lies down in bed the brain becomes over-filled with blood and the patient cannot get to sleep. In such cases the best remedy is a combination of a cardio-vascular tonic like digitalis with a moderate dose of bromide of potassium. Vascular insomnia, whether of high-tension or of low-tension type, is often associated with cold feet. If the feet can be made warm, the cerebral hyperæmia tends to become alleviated. A cup of hot milk or hot soup, by producing abdominal hyperæmia, often relieves hyperæmic insomnia.

Insomnia is one of the most distressing symptoms of chronic heart-failure. Just when dropping off to sleep the patient suddenly starts awake with a feeling of suffocation, gasping for breath. This is probably due to deficient circulation in the medulla oblongata. We treat this condition by cardiac tonics, together with one of the non-depressant pure hypnotics, or even by morphia, cautiously administered and combined with atropine.

Next we have **toxic insomnia**, which is one of the commonest

varieties met with in practice. Many cases are associated with gastric or intestinal fermentation, and especially with dilatation of the stomach. The symptoms are characteristic. The patient falls asleep, but, after an hour or two, varying according to the degree of gastric dilatation, he wakes up, perhaps after a horrible dream, with palpitation, profuse sweating or gastric uneasiness. He may have a sinking feeling with craving for food, and if he eats a biscuit or some other simple food, the stomach contents are temporarily diluted and for the time he feels relieved. This may mislead him into thinking that his sleeplessness is due to exhaustion from want of food, which is far from the fact. During his waking hours he is often very depressed, hypochondriac, and almost melancholic. When we have a clinical history of this sort, we should carefully examine the abdomen. If we find the physical signs of dilated stomach, we treat the patient accordingly, putting him on a dry dietary, free from starchy foods or green vegetables, and attending carefully to the bowels. Meanwhile we administer gastro-intestinal antiseptics such as carbolic acid, creosote, β-naphthol, or sulpho-carbolate of soda. To give hypnotics in such cases, without correcting the gastric condition, is worse than useless.

Amongst the toxic forms of insomnia we must not omit to refer to the sleeplessness produced by chronic excess in alcohol, culminating sometimes in delirium tremens, also the insomnia of acute fevers. Both in fever and in delirium tremens, sleep can often be induced by a cold pack or cold sponging. Insomnia may result sometimes from excessive tobacco smoking, which produces its effect partly by its action on the nerve-cells, partly by its influence on the circulation. Strong tea or coffee may also act in a similar fashion, keeping a patient awake. Insomnia may occur in secondary or tertiary syphilis, even apart from the familiar nocturnal headache: this variety yields promptly to mercury.

Lastly, there is **primary** or **"nervous" insomnia**, due to over-fatigue, especially from mental over-work. We see many instances amongst busy professional or business men. But in most cases there are several factors involved, not only the toxins of exhaustion, but those of hasty and ill-digested meals, together with a succession of powerful mental stimuli, and the persistent cerebral hyperæmia of the brain-worker.

In every case of primary insomnia, besides correcting any gastric, intestinal, or vascular fault that may be present, we should make it a golden rule to send the patient away for a complete holiday. These are also the cases for the employment of the pure hypnotics, which have a direct sedative action on the psycho-sensory cortex. The name of these drugs is legion, and I do not propose to discuss them exhaustively. Amongst the most reliable is paraldehyde. Its nauseous taste is no

drawback, since it prevents the patient from acquiring a habit for the drug. Of the other hypnotics I need only mention a few, such as chloral hydrate, sulphonal, and veronal. We should never allow a patient *carte blanche* to take a hypnotic drug on his own initiative. Self-drugging with hypnotics is highly dangerous. No hypnotics should ever be taken without the express authority of the physician. Nor should anyone, even though he be a medical man, prescribe hypnotics for himself; he should call in a professional colleague.

Drugs like hyoscine and morphia are our last resort in obstinate insomnia. In severe cases of excited mania or melancholia gr. $\frac{1}{100}$ of hyoscine, hypodermically, or gr. $\frac{1}{3}$ of morphine with gr. $\frac{1}{100}$ of atropine, soothe the patient in a remarkable way. Persistent insomnia in cases of insanity is of serious omen. Most alienist physicians insist on having charts kept of the amount of sleep obtained by each insane patient, since severe insomnia recurring regularly for a month or more in cases of insanity renders the prognosis as to recovery very unfavourable.

CHAPTER XXV

INTRA-CRANIAL TUMOURS

For clinical purposes we include under this heading not only the neoplasms proper (glioma, sarcoma, endothelioma, fibroma, carcinoma, etc.), but also gummatous and tuberculous growths, parasitic and other cysts, aneurisms, and even abscesses. All of these may be regarded as slowly-growing foreign bodies, which sooner or later, according to their situation within the cranial cavity, produce clinical phenomena which render their diagnosis possible.

Progressive cerebral lesions, as a rule, produce their effects not so much by destruction of brain substance, but mainly by interference with the circulation in the affected region of the brain, together with displacement, distortion, and compression of the nerve elements. Only in a few instances (*e.g.* in carcinoma, melanotic sarcoma) are the nerve elements directly destroyed by the tumour cells. The importance of the circulatory element is shown by the fact that paralytic focal symptoms may completely clear up after the evacuation of an abscess or hæmatoma, or after a decompressive operation for tumour. Moderate compression produces local venous engorgement with increased excitability of the brain-tissue; further increase of the abnormal pressure produces local cerebral anæmia, with loss of function and paralytic phenomena.

Two classes of signs and symptoms occur in intra-cranial tumours: firstly, *general symptoms* of increased intra-cranial pressure, independent of the position of the tumour; and secondly, *focal symptoms*, which vary according to the particular part of the brain implicated by the growth. General symptoms enable us to say that there is a tumour somewhere within the skull; in order to locate the growth precisely, we must search for localising symptoms, which are usually, though not necessarily, later in onset. If localising symptoms are absent, focal diagnosis may be impossible.

General Symptoms.—The cardinal phenomena of intracranial tumour are three in number, viz. headache, optic neuritis, and vomiting. To these may be added others, such as mental changes, generalised convulsions, giddiness, slowing of the pulse, etc. The triad syndrome of headache, optic neuritis, and vomiting should always suggest the possible presence of an intra-cranial growth. But before diagnosing

cerebral tumour from these three signs alone, we must be careful to exclude three other conditions, any of which may produce the triad syndrome. These conditions are kidney disease, severe anæmia, and lead-poisoning, all of them easy of recognition if we bear the point in mind.

Headache is the most constant symptom of intra-cranial tumour; it generally appears at some period or other, sooner or later. Its severity is sometimes intense. Usually it is a constant dull pain with paroxysms of agonising intensity. The pain may be diffuse or localised. If localised, its position does not necessarily correspond with the situation of the tumour, except with tumours at or near the surface of the brain, when the pain may sometimes be directly over the growth and accompanied by constant, circumscribed tenderness on percussion or pressure or even by a local alteration of percussion-note. But too much stress should not be laid on the existence of localised pain, unless accompanied by other focal signs. Thus, for example, cerebellar tumours often produce frontal headache, and in one case of my own[1] a right-sided cerebellar growth was accompanied by pain limited to the left frontal region. The headache of intra-cranial tumour is intensified by excitement, by exertion, or by any temporary cerebral hyperæmia.

Optic neuritis or "choked disc," detected with the ophthalmoscope, should be looked for in every case of suspected intra-cranial tumour. But it should be borne in mind that while the presence of optic neuritis is one of the strongest evidences of intra-cranial mischief, no weight should be laid on its absence if other signs point to intra-cranial growth. Even apart from actual neuritis, increased intra-cranial pressure often causes a concentric limitation of the visual field for blue. This may even amount to blue-blindness.[2] Optic neuritis from brain tumour is relatively more frequent in hypermetropic than in myopic eyes,[3] probably because the myopic eyeball more easily allows of rapid escape of effused lymph from the inflamed optic disc. Another point of importance is that intense optic neuritis may coexist with perfect vision. But in time, optic neuritis generally progresses to optic atrophy, with its accompanying blindness. Many patients with intra-cranial tumour have early transient blindness, sometimes momentary, sometimes lasting for a few hours or days at a time, in one or both eyes. Trephining the skull and opening of the dura mater generally relieve optic neuritis, even though the growth be not removed; they also give considerable relief to the headache. The optic neuritis of brain tumours, though generally affecting both eyes, may be unequal on the two sides

[1] *Edin. Hosp. Reports*, 1895. An almost identical case has been recorded by Sachs (*Medical Record*, December 22, 1906).

[2] Cushing, *Johns Hopkins Hosp. Bulletin*, 1909, xx., p. 95.

[3] Gunn, *Brit. Med. Journ.*, 1907, p. 1126.

or it may be even uni-ocular. On the whole, the greater intensity tends to be on the same side as the tumour, especially in frontal and cerebellar tumours, though this rule is not invariable. In cerebellar tumours optic neuritis is specially early in onset.

Vomiting is a less constant phenomenon than headache and optic neuritis, except in tumours of the posterior fossa, in which, from the very outset, it is rarely absent. "Cerebral" vomiting differs from the ordinary vomiting of abdominal disorders. It usually occurs independently of food, and is unassociated with other gastro-intestinal symptoms. Moreover, it is often unpreceded by nausea, and thus has a curious "projectile" character. A change of posture of the head is sometimes enough to induce an attack of cerebral vomiting.

Amongst the other "general" symptoms we must mention *progressive mental dulness.* This is apparently to a large extent the result of increased intra-cranial pressure and of persistent headache. The patient becomes apathetic, dull, and slow in answering questions; he loses interest in his ordinary affairs. Sometimes he becomes overwhelmingly drowsy and finally comatose. In the later stages the sphincters are uncontrolled. Mental changes are particularly early of onset in tumours of the pre-frontal region, altogether independently of the intensity of the headache.

Generalised epileptiform convulsions (as distinguished from Jacksonian attacks) may be produced by tumours in almost any part of the brain, not necessarily in the immediate neighbourhood of the motor areas. Such convulsions probably result mainly from increased intra-cranial pressure, and, as a rule, occur comparatively late in the disease. But they may also, though less commonly, appear as the initial symptom of an intra-cranial growth. In such cases epilepsy is sometimes diagnosed, and until further phenomena (such as optic neuritis or focal signs) develop, the error is unavoidable. More usually general convulsions are a late phenomenon, and there are antecedent physical signs to guide us.

Attacks of giddiness are often complained of in brain tumour. Sometimes these are merely indescribable feelings of confusion; in other cases there is a true vertigo or feeling of uncertainty in equilibration. Vertigo is specially early and severe with tumours of the cerebellum, cerebellar peduncles, and corpora quadrigemina, and in such cases is often associated with the motor phenomenon of a reeling or staggering gait.

Slowing of the *pulse*, permanent or transient, is a valuable corroborative sign of intra-cranial abscess. It may also occur as one of the general symptoms of tumour, especially in the neighbourhood of the medulla oblongata. In other cases, again, we may meet with tachy-

cardia. Therefore the pulse-rate by itself is not of high diagnostic significance, compared with the other signs already mentioned. Slowness of *breathing* and a Cheyne-Stokes type of respiration may occur, but mostly in the latest stages of the disease. Paroxysms of yawning or of hiccup may also be produced by intra-cranial growths, especially those of the posterior fossa.

Localising symptoms are sometimes absent, and a tumour may only be revealed by post-mortem examination. This experience is commoner with temporal tumours than with those occurring elsewhere. In most cases, however, focal symptoms develop, which enable us to

Fig. 237.—Tumour of right cerebral hemisphere in a man of 47. The clinical signs were headache, vomiting, double optic neuritis, progressive mental dulness and ultimately slight paresis of the left face, arm and leg, with absence of the left knee- and ankle-jerk and an inconstant left-sided extensor plantar response.

determine the position of the growth with greater or less precision. In a few cases radiography may reveal an abnormal shadow in the position of the tumour. With superficial tumours local percussion of the skull may occasionally yield an altered note. But in some cases we can only form an approximate idea as to the site of the disease. For example, if a patient with headache, vomiting, and optic neuritis develops a gradually increasing left hemiplegia, all that we are justified in diagnosing is a growth somewhere in the right cerebral hemisphere, probably in the neighbourhood of the motor tract (see Fig. 237). Unless additional signs appear it may be impossible to say more, since such hemiplegia may be produced not only by tumours directly implicating the pyramidal tract, but also by frontal, temporal, or even occipital

tumours compressing the motor path. Again, the occurrence of cranial nerve palsies is always suggestive of a lesion at the base of the brain; but this rule is not invariable. For example, isolated ocular palsy of one external rectus has little or no localising value, since the sixth nerve may be paralysed (whether from traction or from increased intra-cranial pressure) by a growth anywhere within the skull. Further, we may have "false localising signs"[1] from compression or distortion by growths in distant parts of the brain. Thus, for example, a tumour of the frontal lobe may at a later stage produce signs of contra-lateral cerebellar disease, or a cerebellar growth may afterwards be associated

FIG. 238.—Endothelioma of meninges invading *right pre-central gyrus* in its upper third. The positions of the fissures of Rolando are indicated by a series of black beads. The patient had Jacksonian convulsions commencing with a painful spasm of the left foot. There was paresis of the left leg and, to a less extent, of the left arm. The face was unaffected. There was no sensory impairment.

with Jacksonian fits of one limb, suggestive of a lesion of the motor area, but really due to distension of the lateral ventricle of the corresponding side, and so on. Or, again, localising symptoms may be masked or concealed, as in some cases of occipital tumour in which, if the optic neuritis goes on to atrophy and blindness, the hemianopia, which might have led to a correct diagnosis, becomes lost. Localising signs, to be of value, should generally appear early. Absence of focal signs suggests that the tumour is above the tentorium, seeing that sub-tentorial growths almost always produce localising signs early in their course.

[1] Collier, *Brain*, 1904, p. 490.

Bearing the above points in mind, let us now consider the chief localising symptoms of tumours in the various regions of the brain.

Tumours of the Motor Cortex.—The motor area, as we have already seen, comprises the pre-central convolution and the adjacent end of the second frontal gyrus, together with part of the cortex on the mesial surface of the hemisphere. Tumours of the motor region are the easiest of all to recognise clinically. In them, in addition to the general signs of intra-cranial tumour, we usually observe two classes of phenomena, irritative and paralytic.

The *irritative* group consists of Jacksonian fits, commencing in the contra-lateral face, tongue, arm, or leg, as the case may be, according to the part of the motor cortex which happens to be chiefly implicated. In a Jacksonian fit the convulsion, which usually consists of tonic spasm followed by clonic jerks, may be strictly localised to a small group of muscles, or it may spread from them to other muscle-groups, but always in a regular order (as shown in Fig. 3, p. 4). Less commonly the whole of the muscles of the contra-lateral face, arm, and leg are thrown into convulsion simultaneously. Jacksonian convulsions differ from ordinary epilepsy in that the patient usually retains consciousness all the time, and can study his own fit. But if the convulsion spreads across the middle line and becomes bilateral, consciousness becomes lost at or before the moment of crossing.

The *paralytic phenomena*, in tumours of the motor region, consist in weakness of the convulsed muscles during the inter-paroxysmal periods (see Figs. 38 and 38A, p. 71). Such weakness is most marked immediately after a convulsion. There is also temporary atopognosis in the affected limb and loss of the sense of position.

According as the growth is primarily cortical or sub-cortical, convulsions precede muscular weakness or *vice versâ*. A cortical tumour, for example one growing from the meninges, is irritative from the first; a sub-cortical growth is usually indicated by an initial monoplegia, followed later by Jacksonian convulsions. Moreover, in a sub-cortical growth the precise starting-point of the convulsions is less constantly localised to the same muscle-group; thus, for example, a sub-cortical tumour immediately under the arm-area may produce Jacksonian fits, commencing sometimes in the thumb, at other times in the elbow. The extent of a Jacksonian fit also varies with the extent of the tumour. A small superficial tumour will produce a highly localised fit followed by monoplegia of the affected part, whereas a tumour of the same size, situated deeper beneath the cortex, will produce an initial monoplegia, convulsions being weeks or months later in onset. The deeper the growth, the less tendency is there to localised convulsions. Tumours of the pre-central or motor area, if extending

backwards across the Rolandic fissure to the post-central convolution, are usually associated with a distinct sensory aura in the affected limb at the beginning of the motor convulsion, together with a degree of anæsthesia, monoplegic or hemiplegic in distribution. The differences between cortical and sub-cortical types of anæsthesia have already been discussed (pp. 195-196).

Tumours of the Frontal Region.—For clinical purposes this region of the brain-cortex, anterior to the motor area proper, may be sub-divided into two parts: (1) A pre-frontal or higher psychical area, devoid of motor centres. This area, when electrically stimulated, produces no convulsion. (2) A post-frontal area, continuous posteriorly with the pre-central convolution and including the cortical centre for conjugate deviation of the head and eyes towards the opposite side. On the left side it contains, in addition, the cortical motor centres for spoken words.

Pre-frontal Tumours, besides producing the general signs of cerebral tumour, tend to excite mental symptoms specially early, consisting in dulness, failure of memory, tendency to childish jocularity, deficiency of attention, and neglect of the sphincters. These mental symptoms are equally likely to occur with tumours of the right side and of the left.[1] Some pre-frontal tumours, however, produce no mental symptoms at all. **Post-frontal tumours** cause, in addition, local Jacksonian fits, especially attacks beginning with, or consisting entirely in, deviation of the head and eyes to the contra-lateral side. Bianchi[2] has described paroxysmal dilatation and contraction of the contra-lateral pupil—pupillary Jacksonian fits—in some cases of pre-frontal tumour. With left-sided tumours we may have fits commencing with sudden attacks of motor aphasia (though the absence of aphasia does not necessarily exclude a diagnosis of left-sided post-frontal growth). General epileptiform convulsions, and even attacks of petit mal, are not uncommon with frontal tumours, including pre-frontal ones. Tumours beginning on the under or orbital surface of the frontal lobe may also be associated with early and persistent anosmia on the ipso-lateral side, from implication of the olfactory bulb and tract. Difficulty in moving the head and eyes to the contra-lateral side would point to a sub-cortical mid-frontal growth. Frontal tumours, whether pre- or post-frontal, are sometimes associated with a fine vibratory tremor of the ipso-lateral arm, and less markedly of the leg, on holding the limbs outstretched[3] (though this is far from constant), and with loss, or speedy exhaustion, of the contra-lateral superficial reflexes, especially the abdominal and

[1] Beevor, Lettsomian Lectures, 1907.
[2] Trans. XIII. International Congress: Section of Neuro-pathology, p. 239.
[3] Grainger Stewart, *Lancet*, November 3, 1906.

epigastric. If the growth be sufficiently extensive to press backwards on the pyramidal tract, there may be an increase in the contra-lateral deep reflexes, with an extensor plantar reflex in the contra-lateral foot, and even a degree of motor hemi-paresis. Optic neuritis, generally late in onset, tends to be more intense on the side of the tumour, whilst local tenderness and alteration of percussion note are relatively common. This ipso-lateral papillœdema of frontal lobe tumours sometimes progresses to unilateral optic atrophy, this latter occasionally passing

Fig. 239.—Left pre-frontal tumour.

through a stage of retro-bulbar neuritis with its characteristic central scotoma.[1] In some cases, frontal tumours are associated with a reeling gait, like that of cerebellar disease (as in the case shown in Fig. 239). Whether this is due to backward displacement of the brain producing compression of the cerebellum, or to the transmission of abnormal impulses along the crossed fronto-cerebellar path, is at present difficult of decision.

Tumours of the Temporal Lobe are the most difficult of all to localise, especially right-sided tumours. This is because their symptoms are produced chiefly by implication of adjacent parts, and only to a lesser extent by true focal lesions. There are, however, two focal symptoms which are of diagnostic value.

[1] Foster Kennedy, *American Journal of Medical Sciences*, September, 1911.

Firstly, tumours of the tip of the lobe, in the region of the uncinate gyrus, are often associated with sudden attacks commencing with an olfactory or gustatory sensation, the smell being usually an unpleasant one. This aura is followed by a curious "dreamy state," lasting several seconds, during which everything seems to the patient to be unreal or "far away." These *uncinate fits* are occasionally accompanied by smacking movements of the lips. They may pass on directly to a general epileptiform fit.

Secondly, tumours of Heschl's convolution (on the Sylvian surface of the lobe) and of the adjacent first temporal gyrus, if on the left side, may produce slight word-deafness with par-aphasia, etc. (see p. 100).

But many temporal tumours are totally devoid of focal symptoms, and only produce symptoms of pressure on neighbouring parts. Thus pressure on the corona radiata may cause a slight hemiplegia, or, more usually, a facio-brachial monoplegia, with disordered reflexes of the corresponding side. Or tumours of the antero-internal aspect of the lobe may implicate the optic tract, or may extend to the crus cerebri, or to the corpora quadrigemina, producing corresponding symptoms.

Tumours of the Post-central Convolution.—Here the focal symptoms of a cortical growth consist of attacks commencing with a sensory aura either of tingling or of pain in the opposite face, arm, or leg, according to the position of the irritative lesion. If the growth extends across the fissure of Rolando to the pre-central or motor convolution (or even in many cases where the pre-central convolution is not actually invaded, but only compressed), there is, in addition, a motor spasm of the corresponding part. Both in cortical and in sub-cortical tumours of the post-central convolution there is usually anæsthesia, monoplegic or hemiplegic, and of cortical or capsular type as the case may be (see pp. 195-196). Astereognosis in the contra-lateral hand has also been observed.

Figs. 240 and 240A show a glioma of the left post-central gyrus, spreading inwards to the centrum ovale. In this case the initial symptoms were clumsiness, loss of joint sense, and astereognosis of the right hand. Later, Jacksonian convulsions occurred in the right face and hand, and subsequently there was progressive right hemiplegia and hemi-anæsthesia with aphasia.

Tumours of the Supra-marginal and Angular Convolutions.—General symptoms are usually late in onset. The chief focal symptoms are due to affection of the visual paths. In left-sided cases, implicating the angular gyrus, word-blindness may occur; in irritative lesions this is transitory, in destructive or sub-cortical lesions it is permanent. A superficial tumour limited to the angular gyrus may produce "crossed amblyopia" (see p. 39). Thus a lesion of the right angular gyrus

produces concentric contraction of the visual field of the left eye (see Fig. 58, p. 121). Such cases are uncommon, but have been occasionally recorded.[1] More usually the growth dips in so as to affect the underlying optic radiations, and then hemianopia results in the contra-lateral half of both visual fields. Hemi-anæsthesia and hemi-analgesia may be present in addition when the posterior end of the internal capsule is affected; motor hemiplegia is uncommon.

Tumours of the Postero-parietal Lobule are sometimes associated with astereognosis in the contra-lateral hand.[2] In such cases the patient cannot recognise the form and qualities of common objects

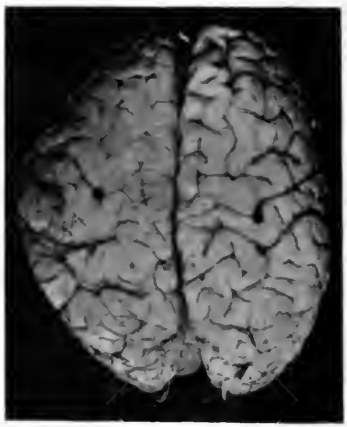

Fig. 240.

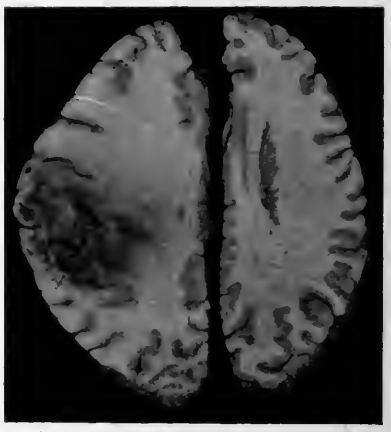

Fig. 240A.

Figs. 240 and 240A.—Diffuse glioma of left post-central cortex and corona radiata.

placed in his hand if his eyes are closed, whereas with the healthy ipso-lateral hand he recognises them at once. But stereognosis is a complex intellectual function, a judgment based on many sensory factors, and astereognosis has also been observed in many other conditions, as in disease of the post-central gyrus, of the optic thalamus, of the posterior spinal nerves and of the peripheral sensory nerves.

Tumours of the Occipital Region.—This area of the brain is associated with the half-vision centre. The cortical half-vision centre is situated mainly on the mesial aspect of the occipital lobe, partly above and partly below the calcarine fissure. The lower quadrant of the half-field is represented above the fissure, *i.e.* in the cuneate lobule, the upper quadrant is below the fissure, *i.e.* in the lingual gyrus. Tumours of this region, therefore, produce as their most constant symptom half-

[1] Beevor, *Lancet*, 1907, p. 719.

[2] *Cf.* a case by Edwards and Cotterill, *Rev. of Neurol. and Psychiatry*, 1911, p. 157.

blindness or hemianopia, which may be complete or incomplete (quadrantic), according as the whole of the cortical centre is affected or only part above or below the calcarine fissure. Wernicke's hemiopic pupillary phenomenon (see p. 127) is absent in hemianopia from occipital lesions. Tumours on the surface produce irritative phenomena, whilst those extending deeper, into the optic radiations, produce paralytic symptoms. The irritative phenomena consist of crude subjective visual hallucinations, such as luminous sparks or flashes of light, in the contra-lateral halves of the visual fields of both eyes, or in that part of the half-field corresponding to the area of cortex affected. Such luminous sensations are usually followed by hemianopia in the same area of the visual field, a hemianopia at first transient, but which may become permanent. Tumours of the cuneate and lingual gyri may also press downwards on the cerebellum, in which case cerebellar phenomena are superadded.

Let us now pass to the consideration of tumours deep within the substance of the brain. These are more difficult to localise than cortical growths.

To distinguish between growths in the **Corona Radiata** and those in the **Internal Capsule** is often difficult, especially when the tumour is a large one. All that it may be possible to state is that the tumour is somewhere in one cerebral hemisphere. But with less extensive growths, producing less complete hemiplegia, the degree of paralysis of different limbs is of diagnostic value. Thus the closer a lesion is situated to the cortex, the greater is the tendency towards a monoplegia. Also if there be a hemiplegia which is complete in the lower limb but incomplete in the upper, and if we find that the hand is more affected than the shoulder, this would point to a capsular lesion rather than a subcortical one, since in the cortex the shoulder centre is the one nearest to that for the lower limb (see Figs. 3 and 7).

Tumours of the Central Ganglia :—Thalamus and Corpus Striatum.—In this region growths may develop without producing enough focal symptoms to render localisation possible. From the close proximity of the optic thalamus and corpus striatum to the motor, sensory, and visual paths in the internal capsule, a slowly progressive hemi-paresis or hemiplegia may occur, accompanied by hemianopia and a degree of hemi-anæsthesia. But if these phenomena be present, say on the right side, and nothing more, beyond the general signs of intra-cranial tumour, all that we can diagnose is a growth somewhere within the left cerebral hemisphere, and probably in its posterior two-thirds. Sometimes, however, we can be more precise. For example, Nothnagel long ago showed that the optic thalamus is a lower reflex centre for the emotional movements of laughing and crying, and cases of thalamic

lesion have been demonstrated in which voluntary movements of the face were preserved, whilst emotional movements were impaired or lost on the contra-lateral side of the face. Further, a small lesion, in the lower and posterior part of the thalamus may cause (probably from affection of the adjacent rubro-spinal path) spontaneous slow rhythmic movements of the contra-lateral limbs, athetoid or choreiform, increased on voluntary exertion. The plantar reflex in these cases remains flexor in type, provided the internal capsule be not involved. Again, the optic thalamus is, as we have already seen, an important station in the general sensory path, and therefore sensory symptoms are sometimes prominent, especially subjective sensations of pain, heat, and cold, in the contra-lateral side of the body, together with a degree of hemi-anæsthesia. Many cases of thalamic tumour, however, run their course without any sensory impairment whatever.

Tumours of the Corpus Callosum have no focal symptoms which can be regarded as pathognomonic. Tumours in the anterior part of this great commissure generally produce early mental symptoms resembling those of paralytic dementia. To these may be superadded unilateral or bilateral hemi-paresis or convulsions (cranial-nerve palsies, as a rule, being absent). But these motor symptoms are probably the result of extension into neighbouring parts, so that to diagnose a callosal growth is always hazardous. Moreover, it is rare for a tumour to be limited to the corpus callosum without extension into one or both hemispheres. Attention has been drawn[1] to the occurrence, without hemiplegia, of left-sided motor apraxia (inability to perform certain movements when there is no actual paralysis of the limb) in callosal lesions (see p. 106).

Marchiafava[2] has described a peculiar degeneration of certain commissural tracts of the corpus callosum in chronic alcoholism.

Tumours of the Corpora Quadrigemina.—The corpora quadrigemina contain important reflex centres. The superior colliculi are chiefly visual in function, and the inferior colliculi chiefly auditory (see pp. 37 and 39). Tumours in this region are localised with comparative ease by the presence of characteristic ocular phenomena. These consist in a paralytic affection of the third nerve nuclei, more or less symmetrically on the two sides. The commonest sign is a combination of bilateral ptosis with weakness of upward and downward movements of the eyes and feebleness of convergence. The pupillary reflex may be sluggish or absent. Less constantly, in unilateral quadrigeminal disease, a degree of deafness has been noted in the ear of the opposite side, the sub-cortical auditory centre being located in the posterior

[1] Wilson, *Brain*, 1908, p. 164; also Lippmann, *Archiv für Psychiatrie*, 1908, xliii.
[2] *Rendic della R. Accad. dei Lincei*, 1910, xiv., series 5, fasc. 3.

corpus quadrigeminum. If the superior cerebellar peduncle, which is in close proximity, be also implicated, we have a corresponding cerebellar asynergia or ataxia and reeling gait, whilst if the adjacent external geniculate body or optic radiations be involved, there is hemianopia.

The **Pineal Body** lies in close apposition to the superior corpora quadrigemina. Certain tumours, especially teratomata, of the pineal gland, occurring in children, are associated with what has been called *macro-genitosomia*, consisting in excessive growth of the body, precocious sexual development, and abnormal growth of the penis and pubic hairs, also with mental and vocal precocity. (These signs are in addition to the ocular phenomena above described.) In this respect they contrast, as we shall presently see, with certain tumours of the pituitary body in which the genital functions may be diminished.

Tumours of the Tegmental Region of the Crus or Pons produce characteristic focal symptoms from implication of the **rubro-spinal tract** (Monakow's bundle), which starts from the red nucleus, runs down in the pons, crosses the middle line and traverses the antero-lateral column on the opposite side of the spinal cord. Lesions in the crural or pontine part of this tract produce a slow rhythmic tremor of the contra-lateral hand and foot, somewhat like that of paralysis agitans, increased by voluntary exertion or excitement and ceasing during sleep. If the lesion be in the **red nucleus** itself, which is transfixed by the fibres of the third nerve, we have, in addition, third-nerve palsy of the ipso-lateral side with tremor of the contra-lateral arm and leg—a condition known as "Benedikt's syndrome." If the growth implicates the sensory tract of the **fillet,** there may be hemi-anæsthesia of the contra-lateral side of the body, but this is less common with tumours than with sudden vascular lesions such as hæmorrhage, etc.

A Tumour of the Crusta or Ventral Region of the Crus Cerebri is easy of recognition, from the characteristic alternate paralysis which is produced. This consists in third-nerve palsy, generally incomplete on the ipso-lateral side, with hemiplegia of the contra-lateral face, arm, and leg—"Weber's syndrome" (see Fig. 94, p. 211). As the tumour increases in size, it tends to cross the middle line and implicate the opposite third nerve as well.

Pituitary Tumours produce diagnostic symptoms in two entirely different ways. Firstly, we may have signs of disordered activity of the pituitary gland itself:—*dys-pituitarism.*

Excessive activity of the gland (*super-pituitarism*), especially of its anterior lobe, influences the growth of the bones throughout the body, producing acromegaly or gigantism (according to whether the epiphyseal cartilages have become ossified or not). But skeletal changes are not

constant. They occur chiefly in cases of adenomatous growth, accompanied by hyper-activity of the anterior lobe of the gland, and not in purely destructive lesions as in the sarcomata. Glycosuria is not uncommon in super-pituitarism.

Fig. 241.—Adiposo-genital dystrophy in a boy of fourteen. He had excessive sugar-tolerance and was able to take 300 grammes of glucose without inducing glycosuria.

Diminished activity (*sub-pituitarism*) of the posterior lobe produces the so-called **adiposo-genital dystrophy** (Fröhlich's syndrome), evidenced by an excessive deposit of fat throughout the body (see Fig. 241), to-

gether with absence of sexual development if the process dates from childhood, or regression from sexual maturity if the disease appears in adult life. Thus in female patients we observe amenorrhœa and sometimes loss of axillary and pubic hair; whilst an adult male patient develops a remarkable tendency to approximate to a female type; the mammary glands enlarge, the testicles diminish in size, the abdomen becomes rounded like a woman's, and the pubic hair becomes restricted in area, accompanied by loss of virility—"pituitary eunuchism."[1] There is also an abnormal sugar-tolerance, so that the patient can take an excessive amount of glucose without showing glycosuria.

Ateleiosis or *pituitary infantilism*, a peculiar variety of arrested growth without adiposity, is due to sub-pituitarism of the anterior lobe. The ateleiotic dwarf has a childish facies, a delicate, soft skin, and thin piping voice. His long bones are small and fine, and their epiphyses are not united. The teeth are incompletely erupted. The pulse is slow and the arterial pressure low. Ateleiosis, as Hastings Gilford has shown, may begin during fœtal life, during infancy or early childhood, or at any time before puberty. The ateleiotic patient retains throughout life the physical characters of his age at the time when his symptoms first developed. If the disease begins in infancy, the fontanelle may remain open for years. If it commences during fœtal life, the testicles remain undescended and the sexual organs rudimentary.

Sub-pituitarism may occur as a primary disease, or it may supervene after a previous stage of super-pituitarism and giant growth. We rarely meet with pure super-pituitarism or pure sub-pituitarism; both types of dys-pituitarism are usually intermingled in varying proportions.

Secondly, and more constantly, in pituitary tumours there are focal symptoms produced by pressure on adjacent parts, notably on the optic chiasma. Bi-temporal hemianopia, with a hemiopic pupil-reaction, results. This may afterwards progress to total blindness of one eye with temporal hemianopia of the other (see p. 122). In pituitary tumours primary optic atrophy is commoner than optic neuritis. A growth in the pituitary gland or in its infundibulum may also press backwards on the third nerves, causing ocular palsies, or it may extend upwards towards the **floor of the third ventricle,** in which case we sometimes note persistent somnolence (see Figs. 236 and 236A), to which may be added polyuria; or it may press upwards against the uncinate lobe, causing uncinate fits, or upon the frontal lobe, producing mental dulness, etc. The diagnosis of pituitary tumour can often be confirmed by radiography, showing deepening of the sella turcica.

[1] Nonne, *Neurologisches Centralblatt*, 1907, s. 735.

Tumours of the Cerebellum and Cerebellar Peduncles.—The anatomical connections of the cerebellum are all-important, and should be carefully borne in mind (see pp. 18 to 23). Of all intracranial tumours, those of the cerebellum are the most frequent. Intracerebellar growths are usually tuberculous or gliomatous, whereas extra-cerebellar growths, commonly situated in the ponto-cerebellar angle of the posterior fossa, if arising from the ventral surface of the cerebellum, are generally gliomata, and if arising from the sheaths of cranial nerves (especially the auditory nerve) they are most commonly fibro-myxomata.

Ataxia, vertigo, a reeling gait uninfluenced by closure of the eyes, nystagmus, and early optic neuritis are the outstanding symptoms common to growths in the region of the cerebellum, but a closer study usually enables us to localise the lesion more exactly.

In cerebellar disease we have to distinguish not only between affections of the vermis and of the lateral lobes, but also between affections of the cerebellar cortex and of the intra-cerebellar nuclei. Many tumours and abscesses implicate cortex and nuclei together, and in such cases we have a combination of cortical and sub-cortical phenomena.

Tumours of the middle lobe or vermis are associated with the typical cerebellar gait. There is also a tendency to fall forwards or backwards, according as the lesion is situated in the anterior or posterior part of the vermis. There is often a tendency for the head to fall backwards or forwards, and not uncommonly the movements of the head and of the facial muscles are curiously slow and clumsy. Asynergia and hypermetria are present in all the limbs, but without unilateral preponderance on either side, until the growth extends into one or other lateral lobe.

Tumours of the cerebellar cortex of the lateral lobe produce unilateral symptoms in the ipso-lateral limbs, consisting in dysdiadocokinesia (see Cerebellar Ataxia, p. 258), hemi-asynergia, and hemihypermetria. On making the patient stand in turn on each foot separately, we find that he tends to stand less securely on the leg of the ipso-lateral side. In walking, he lurches and reels, sometimes towards the side of the lesion, sometimes away from it. In addition we find spontaneous deviation in the ipso-lateral limbs with Bárány's pointing-tests (see p. 22), together with loss of the normal deviation of the ipso-lateral limb on inducing a temporary vestibular nystagmus.

Disease implicating the **sub-cortical or intra-cerebellar nuclei** produces marked unsteadiness of the limbs with a tendency to fall towards the affected side. In cases implicating the fibres of the

middle cerebellar peduncle this may be so marked that, even when lying down, the patient may tend to roll out of bed towards the affected side—so-called *forced rotatory movements*, around the long axis of the body, analogous to those produced by experimental stimulation (see p. 23).

Thus in one case of my own, where there was a large sarcoma within the right lateral lobe, the patient rolled persistently towards his right side, and occasionally fell over the right edge of his bed.

Unfortunately the direction of rotation is not sufficiently constant to be of diagnostic value in determining the side of the lesion, but when the phenomenon occurs, it is a valuable corroborative sign of disease of the middle peduncle.

"Cerebellar catalepsy," and the rare cases of "cerebellar fits," tonic in type, often with opisthotonos, are also indicative of disease of the sub-cortical nuclei.

Nystagmus, which was formerly included amongst the cardinal signs of cerebellar disease, also the occasional *skew-deviation of the eyes*, are probably due, not to pure cerebellar affection, but to disease of the adjacent Deiters' nucleus or its connections. The nystagmus is horizontal in type, its rapid phase occurring on fixing an object situated towards the ipso-lateral side. Together with this, there is often weakness of conjugate movement of the eyes towards the side of the lesion.

The subjective *vertigo*, so frequently present in cases of cerebellar tumour, in which surrounding objects appear as if rotating towards the contra-lateral side, is probably due to affection of the adjacent vestibular nuclei or their connections. So also the occasional curious *attitude of the head* (see Fig. 148, p. 282) is due to vestibular and not to primary cerebellar disease.

The condition of the deep reflexes is inconstant. Pure cerebellar disease, which leaves the long sensory and motor tracts in the brain-stem unaffected, produces neither sensory loss, motor paralysis, nor alteration of reflexes. Sometimes, however, by pressure, or by infiltration, one or both pyramidal tracts may become implicated, in which case may be superadded the characteristic increase of deep reflexes on one or both sides, with extensor plantar responses.

Extra-cerebellar tumours most frequently arise in the **ponto-cerebellar angle,** and, as a rule, are not difficult of recognition. Most of them arise from the auditory nerve, generally near its distal extremity, in the region of the internal auditory meatus, which is commonly widened. Sometimes the tumours are bilateral, as in Fig. 242. The earliest focal symptoms are those of auditory affection, consisting in progressive nerve-deafness, often preceded or accompanied by

tinnitus in the corresponding ear. There is also vestibular affection, with vertigo[1] and impairment of thermic nystagmus and of other vestibular reactions (see p. 130). To these signs is frequently superadded paresis of the adjacent facial nerve—a sign of great value when present. In some cases there is an early stage of facial hemi-spasm. Occipito-frontal headache appears. Later, a vestibular attitude of the head may develop and, with or without this, signs of ipso-lateral

FIG. 242.—Bilateral auditory-nerve tumours (A and B) in *ponto-cerebellar angles*. An unsuccessful attempt was made to remove the larger tumour (B) by operation, hence the laceration of the corresponding lateral lobe of the cerebellum.

cerebellar disease, cortical and nuclear, appear. Further, by extension of the tumour forwards towards the pons, or downwards towards the medulla, other cranial nerves may become affected on the side of the tumour, especially the fifth and sixth nerves. The trigeminal

[1] The direction of subjective rotation may be compared with the apparent rotation of outside objects. In some intra-cerebellar cases the direction of the subjective sense of rotation felt by the patient is the same as that of apparent rotation of external objects, viz. towards the contra-lateral side. In extra-cerebellar cases these two are sometimes opposed, so that the patient may have a subjective sensation of rotation towards the ipso-lateral side. This alleged difference between intra- and extra-cerebellar tumours as regards subjective sense of rotation is doubted by Oppenheim and by other competent observers. It is therefore too uncertain to be conclusive by itself.

nerve may show irritative changes in the form of neuralgic pains, or, more constantly, paralytic changes, usually moderate in degree, evidenced by diminution of sensation in the trigeminal area. One of the earliest phenomena of trigeminal paresis consists in loss of the corneal reflex on the ipso-lateral side. Later on, from affection of the pyramidal tract in the brain-stem, we may have hemiplegic symptoms, generally slight in degree, on one or other side, more commonly in the ipso-lateral limbs, probably due to pressure of the brain-stem against the opposite bony wall of the skull.

Fig. 243.—Sarcoma occupying centre of pons.

Tumours of the Pons.—In this region focal symptoms usually appear early, but the general symptoms, especially optic neuritis, tend to be late in onset. The most characteristic sign of a unilateral pontine lesion is an "alternate" paralysis of the fifth, sixth, or seventh cranial nerve or nucleus on the ipso-lateral side, together with hemiplegia of the contra-lateral arm and leg and an extensor plantar response, or, if the growth be situated in the dorsal region of the pons, there may be hemi-anæsthesia of the contra-lateral side of the body. If the lesion infiltrates the ponto-cerebellar angle, internal to the point of emergence of the auditory nerve, there may be hemi-analgesia and hemi-thermanæsthesia from implication of the fibres for pain and temperature, which at this level are at some little distance from the path for tactile sensation (see Fig. 12, p. 15). According as the growth is primarily intra-pontine or extra-pontine in origin, the affection of cranial nerves will be primarily nuclear or infra-nuclear in type, and the grouping of the symptoms will be slightly different. We have already studied the

differences between a nuclear and an infra-nuclear affection of the sixth and seventh nerves (see pp. 137 and 147). Tumours of the auditory nerve are relatively common, and often bilateral; they ultimately produce signs of extra-cerebellar growth, as we have seen (p. 459).

The clinical picture of alternate paralysis is often masked by the fact that pontine tumours rarely remain confined to one side, but tend to spread bilaterally. In such cases we depend for our diagnosis on the existence of nuclear or infra-nuclear paralysis of the fifth, sixth and seventh nerves, together with signs of implication of the motor or sensory tracts or of the cerebellar peduncles.

Tumours of the Medulla Oblongata.—In this region the chief diagnostic feature is paralysis, unilateral or bilateral, of the lowest cranial nerves and nuclei, from the ninth to the twelfth, producing disorders of articulation, deglutition, etc., together with signs of interruption of the long afferent or efferent tracts coursing through the brain-stem.

Tumours of the Fourth Ventricle may arise either from the ependyma, or from the choroid plexus, or they may be parasitic cysts caused by cysticerci. In purely ventricular growths focal symptoms may be absent. If, however, the lesion extends into the dorsal part of the pons or medulla, or into the cerebellum, corresponding symptoms develop. Glycosuria is relatively common. We have already referred to the peculiar form of vertigo which occurs in cases of free cysticercus in the ventricle (p. 155).

Pathological Diagnosis of Intra-cranial Growths.—In any given case it may be impossible to diagnose with certainty the nature of the growth, since the symptoms depend not on the structure, but on the anatomical position of the tumour. But if there is a history of syphilis, and still more if the Wassermann reaction in the blood-serum is positive, a gumma may be suspected, and the patient should be given the benefit of energetic anti-syphilitic treatment for a time.

Noguchi's luetin reaction in the skin, when a dead culture of several strains of *Treponema pallidum* is injected hypodermically, is an important method of diagnosing latent syphilis. In a syphilitic individual the luetin injection produces a reddish indurated papule or pustule, often surrounded by an inflammatory area and lasting four or five days.

It must not be forgotten, however, that even gummata sometimes resist medicinal treatment, and it may be necessary to remove a cerebral syphiloma by operation. Syphilitic lesions of the central nervous system are also associated with an excess of lymphocytes, together with the presence of globulin and a positive Wassermann reaction, in the cerebro-spinal fluid; a normal fluid would, therefore, be against

a diagnosis of syphiloma. But an excess of lymphocytes occurs not only in tuberculous tumours, but even in true neoplasms. A sudden apoplectiform aggravation of the symptoms is suggestive either of glioma or of aneurism, gliomata being, from their loose texture and high vascularity, particularly liable to spontaneous hæmorrhages. Aneurisms sometimes, and arterio-venous aneurisms more often, may be accompanied by pulsating bruits; these may not only be perceptible by the patient, but can sometimes be auscultated by the physician.

Tuberose sclerosis is a rare congenital disease in which there are curious neoplasms in the brain, and frequently also in other organs, notably the kidneys, heart, and skin. The brain tumours, which are often multiple, consist of an intermingling of "dislocated" nerve-cells with gliomatous overgrowth. Sometimes these give rise to the general signs of intra-cranial pressure—headache, optic neuritis, general convulsions, etc. Local signs and symptoms are rare. The child is usually epileptic and mentally deficient. The chief diagnostic feature is the frequent presence of so-called sebaceous adenomata:—small, closely-set tumours of the skin, disposed symmetrically on the face, chiefly about the forehead, bridge of the nose, naso-labial folds, and chin; sometimes also on the skin of the trunk.

Cerebral abscesses are mostly secondary to local infection. In peace-time, the commonest source of infection is from the middle ear or other accessory air-sinus (frontal, ethmoidal, or sphenoidal). Or they may follow compound fractures of the skull, sometimes after an interval of months, during which the patient appears to be healthy; this is specially common in war-injuries of the brain. Less commonly we find metastatic abscesses without local infection in the head, *e.g.* in pyæmia, ulcerative endocarditis, actinomycosis, and in some cases of bronchiectasis, amœbic abscess of the liver, etc. In amœbic cerebral abscess, the contents of the cavity consist of necrosed brain-tissue, red blood-cells and amœbæ, the latter being most abundant in the abscess wall.

Brain abscesses secondary to otitis media generally follow cases of chronic rather than of acute suppuration of the middle ear, although this rule is not invariable. Their commonest situation is either in the temporal lobe of the cerebrum or in the lateral lobe of the cerebellum. In either of these situations an abscess produces signs of general intra-cranial pressure, such as headache, vomiting, mental dulness, and, later, optic neuritis. The pulse in brain abscess is often abnormally slow (50 to 40 per minute), and the temperature may be normal or subnormal. Once the abscess bursts into the ventricles or into the sub-arachnoid space, producing a fulminating purulent meningitis, the

pulse and temperature at once run up, and the patient dies. A pyæmic temperature, with rigors and acute fever of remittent type, occurs when infective *thrombosis of the lateral sinus* or other venous sinuses occurs (see also pp. 44-45).

A **temporal abscess** is easier to recognise when left-sided, owing to the fact that in right-handed people the left temporal lobe contains centres for word-hearing: hence in a left-sided temporal abscess the patient tends to have par-aphasia and makes mistakes in naming objects (see p. 100). If the abscess be large in size, it may press inwards towards the corona radiata and cause a facio-brachial monoplegia, with perhaps loss of the abdominal reflex upon the hemiplegic side. Further, by pressure backwards towards the angular gyrus, it may produce hemianopia, and in left-sided abscesses, word-blindness. Or from extension downwards, towards the floor of the skull and the ocular nerves, we may have dilatation of the ipsolateral pupil, and ptosis or other impairment of external ocular movements. **Cerebellar abscess** tends to cause vertigo, ataxia of ipsolateral limbs, with spontaneous mispointing on Bárány's pointing-tests, and nystagmus. The patient often lies habitually upon the healthy side of the head, keeping the side of the abscess uppermost. **Frontal abscess** commonly arises as a direct result of infection from the frontal, ethmoidal, or sphenoidal air-sinuses. The focal diagnosis is often difficult, and we must be on the look-out for special mental dulness, deficient control of sphincters, loss of the contra-lateral abdominal reflex, and the presence of an extensor plantar reflex on the contra-lateral side.

Tuberculous growths are specially common in the pons and cerebellum, and the existence of tuberculous disease of the lungs, abdominal viscera, or elsewhere, would tend to suggest a similar cause for the intra-cranial mischief, particularly if the patient be a child or young adult. Calmette's ophthalmo-reaction by inoculating the conjunctiva, or Von Pirquet's cuti-reaction by inoculating the skin with a small dose of tuberculin, are sometimes of value in such cases.

Symptoms of cerebral tumour supervening in a patient who has already had a malignant tumour elsewhere in the body suggest that the cerebral mischief is metastatic in nature. In such cases a curative operation is out of the question, since it is probable that other tumours will be present, besides the one which has been diagnosed.

Finally, we have to bear in mind certain cases of **pseudo-tumour cerebri**, which may be divided into four groups:—

(1) Cases which after showing the classical signs of brain tumour recover completely, or in which an autopsy shows no lesion capable of accounting for the symptoms.

(2) Cases of acute hydrocephalus or **serous meningitis** of the

ventricles (ependymitis), relieved by thecal punctures. Some of these cases are associated with otitis media, in which the focus of suppuration is outside the dura mater, and the toxins, but not the organisms, penetrate the barrier and set up a serous meningitis, in which the cerebro-spinal fluid is sterile and may even be free from pleocytosis. Similar cases arise in the course of general fevers, especially measles, influenza, pneumonia, enteric fever, etc. Others follow head-injuries in which there has been no question of infection of the meninges.[1] Others, again, are due to chronic lead poisoning. Sunstroke can also produce an acute meningeal reaction.

(3) Localised ependymitis of the Sylvian aqueduct, producing blocking of this canal with enormous distension of the ventricles.

(4) Extensive and acute softenings, with headache, choked discs, and hyper-tension of the cerebro-spinal fluid.

As a rule, however, pseudo-tumour is more rapid in its evolution, and the optic and ocular phenomena appear early and soon attain a maximum.

[1] Roemheld, *Neurolog. Centralblatt*, 1916, p. 663.

CHAPTER XXVI

ORGANIC WAR-LESIONS OF THE NERVOUS SYSTEM

THE advisability of considering war-injuries in a special category is not merely because of the dramatic human interest aroused by everything connected with the titanic European struggle. From the medical and scientific point of view, also, there are important differences between the injuries of war and the diseases and accidents of peace.

Firstly, missiles which traverse the tissues produce effects wholly different from those which result from spontaneous morbid processes. They damage indiscriminately anatomical structures which are seldom simultaneously affected in disease. Moreover, when focal lesions similar to the war injuries of healthy brains do occur spontaneously from disease, they are the result of pre-existing morbid processes, which arise either in the nervous tissues themselves, or, more commonly, in the blood-vessels or meninges. Further, war-injuries produce their effects not so often from the mere mechanical damage of the projectile as by the inward penetration of infective organisms. In wounds of the nervous system which are not immediately fatal, the chances of recovery largely depend on whether septic infection has been obviated or not.

Focal lesions from war-injuries in healthy young brains and spinal cords, if aseptic, are equivalent to physiological experiments, and the resulting syndromes are different from those which occur in the course of disease.

Lastly, owing to the healthy condition of the tissues originally damaged, the prospects of recovery after war-lesions of the nervous system are much greater than can be expected after lesions which result from disease.

Brain Wounds

The brain is protected against injuries from without by several lines of defence. Firstly, there is the thick *scalp*, separated by loose connective tissue from the *skull*. This has its pericranium outside, for the nourishment and repair of the outer table. The dense outer table is separated from the dense inner table by the spongy diploe, and sometimes by air-sinuses. Where the diploe is absent and the outer and inner tables are in apposition, as in the temporal and sub-occipital regions, additional protection is afforded by the superjacent temporal and cervical

muscles. Close within the skull is the *dura mater*, tough and strong. This acts as an internal periosteum to the inner table. It is also an important mechanical defence, for, even if the inner table be forced inwards by a blow, the dura may still offer a successful resistance, so that bony débris, effused blood, or infective material may be held up outside it. The dura is split, here and there, to carry between its layers various important venous sinuses. The bony cranium, when fractured by a blow, may either remain depressed at the site of impact, indenting the dura, or it may recoil, leaving an extra-dural hæmorrhage from one of the meningeal vessels which are embedded in the outer part of the dural coat.

The dura mater is the chief barrier against invasion by infective organisms threatening the brain from without. Even when a gap has been made in it, the dura can still make a final effort to prevent infection of the sub-dural and sub-arachnoid space by the formation around the gap, within a few hours, of defensive entanglements or adhesions between the dura and the pia-arachnoid.

The cerebro-spinal dura mater is a completely closed sac, separating the brain and spinal cord from the other tissues of the body. Unlike other encapsuled organs, which can undergo enlargement under the influence of hæmorrhage, inflammation or tumour-formation, the dura mater is absolutely inextensible by any physiological force.

The *sub-dural and sub-arachnoid spaces* form an almost defenceless zone, freely bathed by the cerebro-spinal fluid. If this fluid becomes contaminated, it disseminates infective organisms throughout the brain and thence downwards into the spinal meninges.

Within these various coverings is the soft, helpless *brain-substance*, held together by the *pia mater*, a delicate network of connective tissue, which dips into all the cerebral fissures and sulci, covers the convolutions, furnishes a sheath to all the cranial nerves, and supports in its meshes the arteries, veins, and lymphatics as they enter or leave the brain. It is important to remember that the cerebral arteries and veins, and especially the veins, are very loosely supported in the pia mater, so that meningeal hæmorrhages, whether venous or arterial, on the surface of the brain are liable to spread widely over the cortex. Within the brain-substance, on the other hand, hæmorrhages are less frequently venous than those on the surface, and spread somewhat less easily, owing to the greater resistance offered by the brain-tissue.

The cerebro-spinal fluid fills the cerebral ventricles and bathes the sub-dural and sub-arachnoid spaces, together with the peri-vascular and peri-cellular lymph-spaces. It is collected, here and there, into larger sub-arachnoid cisterns or water cushions, notably in the mesial inter-peduncular space and laterally in the ponto-cerebellar angles.

Wounds of the Head.—These may be produced by various projectiles, such as rifle, revolver, or shrapnel bullets, shrapnel fuses or cases, fragments of high-explosive shells, or bombs. Sword, bayonet, and rifle-butt wounds are relatively rare in modern warfare. With the exception of a very small proportion (chiefly due to rifle bullets), all the wounds thus produced are septic, *i.e.* infected by pyogenic organisms.

Cranial wounds may be divided into various classes:

1. **Tangential or Glancing Wounds,** in which the bullet or metallic fragment does not penetrate the cranial cavity. These constitute the great majority of non-fatal cases. Out of a series of 118 personally observed cases (exclusive of mere scalp wounds), 77, *i.e.* 65 per cent., were tangential, 18 (or 15 per cent.) were through-and-through wounds, and in 23 (or 20 per cent.) the missile remained within the cranium.

Tangential wounds may be subdivided into:

(*a*) *Scalp wounds.* These are generally, but not always, septic. If uncomplicated, scalp wounds generally heal under simple treatment. Every scalp wound, however, should be regarded as a potential brain-wound and carefully examined, lest it lead down to a fracture of the subjacent cranium.

(*b*) *Fractures of the cranium.* These are generally, but not invariably, compound. We may meet with *fissured fracture* of both tables, often radiating for long distances from the site of the blow, and frequently associated with extra-dural hæmorrhage. The extent of a fissured fracture is best determined by radiography. Fissured fractures often extend to the base of the skull, where they may implicate various foramina, producing cranial-nerve palsies. *Punctured fracture*, in which, at the floor of a scalp wound, there is a local depressed fracture of both tables, is less common than a fissured fracture, but is highly dangerous if overlooked, since it is frequently associated with laceration of the dura and with infection of the meninges and of the contused brain-substance. *Gutter fracture* is very common, running in any direction, whether sagittally, transversely, or obliquely, and grooving either the outer table alone, exposing the diploe, or, more commonly, affecting both tables of the skull, and with fissured fractures diverging in V-shaped fashion from both ends of the cranial gap.

Each of the foregoing fractures is liable to be associated with *depressed fracture* of the inner table. This is always more extensive than the fracture of the outer table, indenting and often lacerating the dura mater. There may even be a depressed fracture of the inner table alone, whilst the outer table remains intact.

In all these fractures the chief danger is not that of the fractured bone itself, but that of injury to the brain or its meninges. The sub-

jacent brain-tissue may be contused by the impact, or there may be a superficial cortical hæmorrhage from laceration of the thin-walled surface-veins or from penetration of a tough-walled venous sinus.

In every compound fracture the cardinal point to determine is:—**Has the dura**—the great barrier against intra-cranial infection—**been lacerated?** This is determined by careful inspection and palpation of the wound, often greatly assisted by an X-ray photograph. *A probe should never be used to search for a gap in the dura*, for not only does it tend to make a false track, but it may push infective material inwards towards deeper structures.

So long as the dura is untorn, sub-dural lesions usually remain free from infection and run an aseptic course. If, however, the dura be

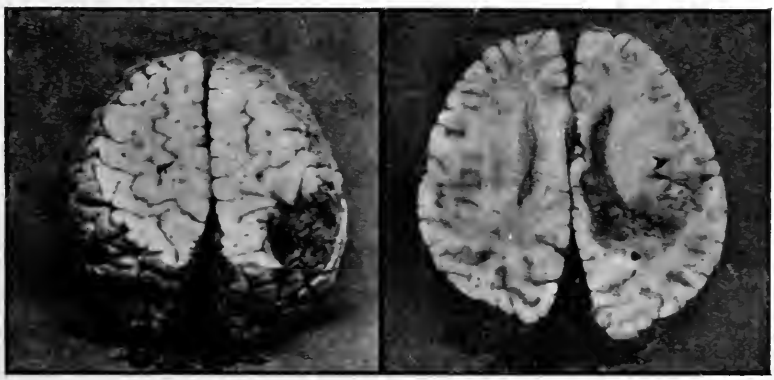

FIG. 244. FIG. 244A.

FIGS. 244 AND 244A.—Brain sections from the case of a patient who was admitted moribund with total left-sided hemiplegia and a cranial gap in the right parietal region. An area of softening extends through the centrum ovale from the site of the tangential wound to just outside the posterior horn of the lateral ventricle. No bullet or metallic fragment was found within the brain. The hæmorrhagic area was most marked near the surface (Fig. 244), the deeper part of the softened area being free from hæmorrhage. Numerous bony splinters were scattered deep into the brain, being most numerous immediately outside the lateral ventricle (Fig. 244A), which was not penetrated.

lacerated in an open wound, the brain-substance is now in direct continuity with a possibly septic outer world.

2. **Penetrating Wounds of the Cranial Cavity.**—These are wounds in which projectiles, bony fragments, and sometimes portions of the patient's scalp or head-gear, become lodged within the dura at varying depths along the wound-track. Should the projectile lacerate a large artery *en route*, fatal cerebral hæmorrhage may result. If a bony splinter reaches the ventricle during the primary injury, the chances of recovery depend on whether it can be extracted before general infection of the ventricles has been set up. A metallic projectile which primarily penetrates the ventricle is generally fatal. A septic track, which comes

to open secondarily into one of the ventricles, is always fatal. Sometimes a shower of bony splinters becomes projected deeply into the brain substance (see Figs. 244 and 244A), whilst the projectile itself glances off or merely indents the cranium. Sometimes the projectile, after traversing the brain, impinges on the opposite side of the skull, where it either produces an elevated fracture or rebounds to some other part of the brain. Metallic or bony fragments within the brain are often multiple. X-rays are of the greatest value in localising them. Here again a probe should not be used for their detection. Gentle palpation with the finger-tip is sometimes permissible, but the area of cortical destruction should not be increased by the crude method of introducing the finger into the brain-substance.

FIG. 245.—Radiogram of occipito-frontal brain-wound, showing gap of entry in right occipital region, with metallic fragment in right frontal lobe. Later, the fragment gravitated back again into the occipital lobe, where it was found *post-mortem*.

Sometimes foreign bodies in the brain wander from their original position to some other part, generally in an occipital direction. This happens chiefly with heavy metallic fragments as the result of gravity.

Thus Fig. 245 shows a radiogram of a foreign body which penetrated through the right occiput and lodged in the right frontal lobe. At the autopsy, however, it was discovered in the right occipital lobe, within an inch of the surface, having gravitated backwards through the softened brain-tissue. The patient had habitually been lying on his back.

3. **Perforating, or In-and-out, Wounds** are those in which the missile has traversed the cranial cavity, entering through one and coming out through another, generally a larger, opening. The edges of the bony apertures are usually extensively comminuted, and from them fissured fractures run in various directions. One fissured fracture usually joins the entry with the exit gap, whilst others diverge from the two apertures. The amount of brain destruction is usually greater than in

the case of penetrating wounds. Hæmorrhage in the bullet-track is most abundant at the points of entry and exit, and tends to diminish in amount in the intervening parts (see Figs. 246 and 246A). Many of these cases are rapidly fatal from shock to the vital centres in the brain-stem. In-and-out wounds by projectiles which traverse the cerebral ventricles, or which pass through the brain-substance beneath the ventricles, are always fatal. A few in-and-out wounds, however, are compatible with survival, *e.g.* wounds through the prefrontal lobes or through the upper region of the cerebral hemispheres above the level of the ventricles.

FIG. 246.

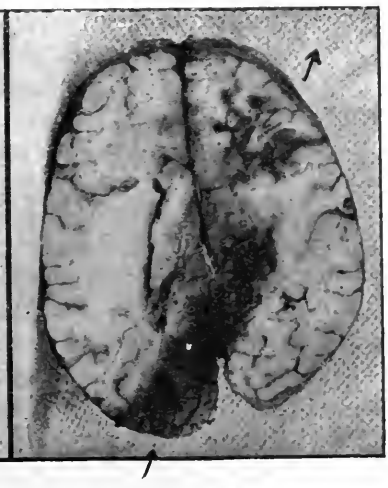

FIG. 246A.

FIGS. 246 AND 246A.—Perforating wound of brain. The point of entry is at the posterior end of the left occipital lobe, one inch from the middle line. The bullet-track crosses the middle line above the level of the corpus callosum, and emerges through the posterior end of the second frontal gyrus on the right side.

The hæmorrhage in the bullet-track is most abundant in the left occipital lobe, diminishing in amount as the track traverses the right cerebral hemisphere. The anterior end of the track consists of disintegrated brain-tissue, free from hæmorrhage, except immediately around the aperture of exit, where there are a few petechial points in the cortex and sub-cortex.

4. Bursting Fractures with Extensive Brain Contusion.

Sometimes a high-velocity bullet at very close range transmits its energy to the cranial contents *en masse*. The whole brain thus explodes, as it were, and blows the roof of the skull off.

Other cases of large cranial gap are the result of glancing wounds from a large missile. Most of these cases are fatal within a few minutes from acute paralysis of the respiratory centres. A few patients survive if adequate drainage can be provided and general intra-cranial infection prevented—a rare and lucky occurrence.

Morbid Anatomy of Brain Wounds.—Except in the case of injuries by high-velocity bullets at very close range, or by large fragments of shell, as a result of which portions of the skull and brain may be blown away, sutures torn apart and the cranial base burst open, the amount of actual destruction of nerve-cells and nerve-fibres produced directly, by the projectile itself, is relatively small. Most of the structural damage which results is caused by hæmorrhage, septic infection, or other secondary event. Moreover, the severity of a cerebral lesion is not necessarily proportional to that of the cranial injury.

War-injuries are usually, in young and healthy brains, free from vascular or degenerative disease. Rarely is a cortical centre completely destroyed, so that in almost every case of survival a certain amount of recovery may be expected.

Cerebral concussion is common. It is due to sudden hyper-acute compression, or squeezing, of the brain, producing momentary cerebral anæmia, and associated with minute peri-vascular hæmorrhages in the cerebral cortex, mid-brain, spinal nerve-roots and spinal cord,[1] at the time of the injury. It is characterised by a frequent, feeble pulse, low blood-pressure, and shallow, irregular respiration, followed, if the patient survives, by a stage of reaction, with headache, flushed face, high blood-pressure, and powerfully-beating heart (see p. 53). Concussion varies in degree in different cases, and is not always proportional to the apparent severity of the blow. Thus in one case a comparatively slight head-injury, without fracture of the skull, may produce severe concussion or other intra-cranial symptoms, whereas another patient may sustain a severe cranial lesion, or even a perforating wound, and yet concussion symptoms may be slight or transient.

Cerebral compression, from intra-cranial hæmorrhage, produces a characteristic and easily-recognised syndrome (see p. 56), which is often preceded by a stage of **cerebral irritation,** during which the patient lies curled up in bed, with all his limbs flexed, burying his head under the bed-clothes owing to photophobia, and resenting any examination, noise or conversation. Meantime he suffers from violent headache, whilst the temperature is raised to 101° or 102° F. The phenomena of cerebral irritation are probably due to a mild, wide-spread œdema, causing obstruction of the cerebral veins, with consequent abnormal excitability of the whole brain.

Meningeal adhesions usually develop within a few hours around any wound in the dura mater. These adhesions are nature's effort to shut off the infected area from the cerebro-spinal lymph system and thus to prevent a diffused meningeal infection. Meningeal adhesions of this sort constitute a barrier which should be treated

[1] See p. 53, footnote.

with the greatest respect, and should not be broken down by the surgeon.

Structural damage of brain tissue is mainly due to the following secondary processes:

1. Contusion or laceration by **hæmorrhage,** which may be superficial or deep. A superficial hæmorrhage, sub-dural or sub-pial, is not necessarily arterial. It is more often due to tearing of cortical veins by a depressed fragment of bone, or to rupture of thin-walled surface-veins near their point of entry into the rigid superior longitudinal sinus. Superficial hæmorrhage, whether arterial or venous, produces signs of cortical lesion, varying with the particular region affected. Thus in the motor cortex we have localised paralysis with muscular rigidity and sometimes Jacksonian fits; in the sensory cortex, anæsthesia of cortical type; in the visual cortex, impairment of vision, sometimes preceded by subjective luminous sensations, and so on. In longitudinal sinus injuries there is diplegia of the lower limbs, with motor or sensory symptoms or both, varying according to the extent of contusion of the mesial edges of the hemispheres. There are also various "silent areas" of the brain which may be severely damaged without producing any obvious focal signs whatever.

A hæmorrhage within the cranium, whatever its situation (extra-dural, sub-dural, intra-cerebral, or intra-ventricular), produces its effects mainly by compression, interfering with the circulation in adjacent parts of the brain. As a hæmatoma increases in size, it first of all compresses the neighbouring veins, producing cyanosis in the adjacent zone of brain-tissue. Such cyanosis is associated with increased excitability. If the hæmatoma continues to grow in size, the brain-substance nearest to it now becomes emptied of its blood. Capillary anæmia of this sort produces paralytic symptoms. Beyond the zone of capillary anæmia there is a zone of venous obstruction. Therefore in the later stage of a large cortical hæmorrhage the hemispherical symptoms are those of anæmia, *i.e.* paralytic phenomena, whilst the bulbar symptoms are those of venous obstruction, viz.:—high blood-pressure, slow pulse, stertorous breathing, and other irritative bulbar phenomena.

Hæmorrhage along a bullet-track is generally more marked near the surface of the brain. It may sometimes extend throughout the track of disintegrated brain-substance, but often the deepest part of the wound is practically free from hæmorrhage.

Severe polar contusions of the brain-substance may occur from a bullet-wound of the head even without traversing the cranial cavity or lacerating the dura mater, as in the case shown in Fig. 247.

In this case the bullet entered the head in the mid-frontal region, half an inch above the nasion. It then traversed the right orbit, producing paralysis of the ocular muscles, and emerged below the right mastoid process, fracturing the lower jaw and paralysing the right facial nerve *en route*.

At the autopsy the dura mater was found intact, but there was a fracture of the cranial base, implicating the cribriform plate and floor of the right middle fossa of the skull. The anterior part of the right temporal lobe was severely contused, and also slightly the orbital surface of the right frontal lobe.

FIG. 247.—Contusion of right temporal lobe, with fracture of cranial base, from extra-dural bullet-wound.

In rare cases a second cerebral hæmorrhage may occur independently of the bullet-wound, thereby complicating the diagnosis, as in the following case (Figs. 248 and 249):—

A patient who had sustained a perforating trans-frontal wound, entering through one temporal fossa and emerging at the other, was admitted with complete left-sided flaccid hemiplegia. The trans-frontal wound was insufficient to account for his symptoms. These were explained, however, at the autopsy, which showed an independent hæmorrhage, the size of a walnut, above and behind the right internal capsule, at a considerable distance from the bullet-track through the frontal lobes.

Sometimes a patient sustains two separate and distinct lesions from the same blow:—one at the original point of impact, the other by *contre-coup* at the opposite pole of the brain. The following is an illustrative example:—

A young Scottish officer, aged 23, sustained a cranial wound from a piece of high-explosive shell which perforated his steel helmet obliquely through its left anterior quadrant and caused a glancing scalp-wound of the left upper pre-frontal region.

He was slightly concussed and temporarily deaf for a few hours, so that he could not hear his own voice, but was neither hemiplegic, aphasic, nor hemi-anæsthetic. The visual fields were not examined at this stage.

The edges of the scalp-wound were at once excised: no fracture of the skull was detected. An X-ray on the fifth day, however, showed a circumscribed, slightly depressed fracture of the cranial vault, just to the left of the middle line.

A fortnight after the injury, headache and drowsiness supervened, without pyrexia. Accordingly, on the nineteenth day, the wound was

FIG. 248. — Transfrontal wound. Entry through right Sylvian point. Exit through left frontal lobe, at posterior end of F_3 gyrus.

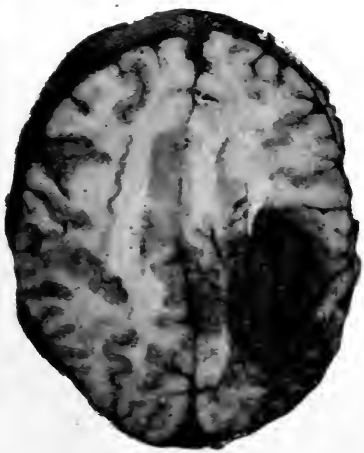

FIG. 249.—Hæmorrhage by "contre-coup" in right centrum ovale, from the case of transfrontal wound shown in Fig. 248.

explored, the depressed area of the skull trephined, and a small collection of blood-clot was evacuated from beneath the hitherto intact dura. After a few days the patient was apparently free from symptoms.

Eight weeks after the original wound, the patient again became drowsy and developed incontinence of both sphincters. The pulse became slow and he was mentally dull. There was neither vomiting nor optic neuritis. Nevertheless, in view of the gradually progressive symptoms, another operation was undertaken ten weeks from the time of the injury. A wide cranioplastic operation was done in the left upper frontal region. Nothing abnormal was found in the left frontal lobe, but an abscess was discovered and evacuated in the right upper frontal region. This last operation was followed by uninterrupted recovery, although a small hernia cerebri, the size of a plum, took some time to subside.

Careful examination, two and a half months after the injury, showed

no signs of focal disease of the frontal lobes. The patient was bright and intelligent, with normal pulse and temperature. There was neither hemiplegia, aphasia, incontinence of sphincters, nor hemi-anæsthesia. The supinator-jerks, knee-jerks, and ankle-jerks were brisk and equal on both sides. Both plantar reflexes were flexor in type. The right abdominal reflex was perhaps a little less brisk than on the left side.

There was, however, complete left-sided homonymous hemianopia, both to moving and to stationary objects, and on asking the patient to bisect a horizontal line drawn on a piece of paper, with either eye open, he constantly made the mistake of going to the left of the mid-point (see p. 119). There was no hemiopic pupil reaction. The patient himself

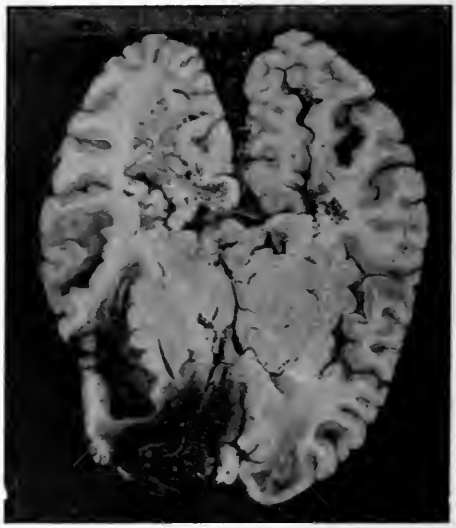

FIG. 250.—Transverse wound of frontal bone causing deep-spread abscess of right frontal lobe, with a second pale green area of purulent encephalitis at tip of left prefrontal region.

volunteered the information that, ever since his original wound, he had been unable to see objects to his left side.

The visual signs in this case clearly pointed to a lesion of the right optic radiation. The absence of any symptoms of implication of the long sensory or motor cerebro-spinal tracts showed that the occipital lesion was not directly continuous with the frontal lesion, but was the result of a second and independent contusion from *contre-coup*.

2. **Acute cerebral softening** or necrosis of brain-tissue occurs along the track of a bullet-wound. It also occurs throughout the area of brain destruction produced by the sudden impact of a projectile, whether the superjacent cranium and dura be lacerated or not. Softening may occur both directly, under the point of impact, and at the opposite pole of the brain, by *contre-coup*. The superficial part of the softened area then becomes infiltrated, to a varying extent, by effused blood, forming a hæmorrhagic softening, whilst the rest of it, especially at the deepest

part from the surface, may remain as a pale area of simple disintegration, free from hæmorrhage. Such a softened area, if infective organisms gain access to it, readily develops into an abscess.

3. **Œdema** of the brain-tissue, around the contused or lacerated area, is a common occurrence, as in other organs, following contusion or laceration. Cerebral œdema is very apt to produce obstruction of the cerebral veins, thereby disturbing, for a time, a wider area of brain-tissue, with a correspondng increase in the extent of the focal signs and symptoms. Fortunately it tends to subside gradually, and with it the brain symptoms correspondingly recede. Cerebral venous obstruction produces irritative phenomena, unlike those of capillary anæmia, which are usually paralytic in character.

Fig. 251.—Bullet-wound of right frontal lobe. The only abnormal sign, on examination of the nervous system, was absence of the left abdominal reflex. Together with this there was incontinence of urine. There was no paralysis, sensory or motor, and the mental functions were unimpaired.

4. **Abscess** (or **suppurative encephalitis**) may develop around the infected track within the brain. Unless successfully evacuated and drained externally, the suppurative process tends to spread inwards, and ultimately, after weeks or even after many months (when the original wound may have healed on the surface), may reach one of the ventricles of the brain (see Fig. 250), producing ventriculitis. Death is then inevitable, sometimes sudden, sometimes after a few days, from infection of the cerebro-spinal fluid. There is sometimes a premonitory stage of slight pyrexia, with reappearance of traces of the former focal signs. The infection, having once reached the ventricles, passes outwards, through the great transverse fissure, to the base of the brain and thence all over the meninges, from base to vertex.

Retained foreign bodies, fragments of bone, metal, head-gear, or scalp-hairs, which have carried infection inwards, are the most frequent cause of brain abscess, but abscess may also occur even when no foreign body is present and when the original brain-injury has seemed to be quite trivial. Suppuration is specially common within or near a cerebral hernia.

5. Diffuse purulent **meningitis** is the cause of death in three-fourths of the fatal cases (apart from immediate fatalities on the field). It is generally more severe at the base of the brain than on the convexity. Sometimes the meningeal infection is an early event, spreading directly from the neighbourhood of the wound in the dura, before there has been time for defensive adhesions to shut off the general sub-arachnoid

space. In other cases infection of the cerebro-spinal fluid and meninges occurs from subsequent operative procedures, which break down protective adhesions, *e.g.* during an attempt to remove a foreign body within. In other cases, again, meningitis is secondary to infection of the cerebral ventricles by direct spread of the septic process, and it is in this way that a large proportion of cerebral abscesses cause death.

Hernia cerebri is a condition in which a bulging mass of brain tissue is prolapsed through a cranial opening (see Figs. 251 and 252). The contents of the hernial swelling are cerebro-spinal fluid and brain-

Fig. 252.—Hernia cerebri of right pre- and post-central region, associated with progressive left hemiplegia.

tissue, in varying proportions in different herniæ. The swelling usually pulsates synchronously with the heart-beats.

Herniation is caused by increased intra-cranial pressure, whether from meningitic changes following a brain-wound or in peace-time from the continued growth of an irremovable intra-cranial growth. Sometimes in brain-tumours a hernia cerebri occurs after a decompressive craniectomy for the relief of intra-cranial pressure. In a healthy brain the mere presence of a gap in the cranium does not cause any prolapse to occur through the gap (see Fig. 253). Hernia cerebri following a brain wound is therefore always a sign of sepsis. In cases that are getting worse, from increasing intra-cranial pressure, the herniated tissues often become œdematous owing to strangulation of the neck of the hernia by the rigid dura and bone. Pulsation then

diminishes and disappears, and the hernia forms a fungus-like mushroom-shaped mass, which may subsequently slough away. As the hernia grows in size, it distorts the subjacent hemisphere by traction. If the lateral ventricle becomes drawn out, it tends to rupture into the infected track, and death is then inevitable. It is remarkable, however, how large an area of cerebral tissue in some cases may be prolapsed into a hernia without producing paralysis or other symptoms. Subsidence of a hernia is a favourable sign, and indicates that the intra-cranial pressure is subsiding.

Transient *optic neuritis* develops in a large proportion of the more severe brain-wounds. It does not necessarily foreshadow a cerebral abscess or a septic meningitis. It comes on within a day or two of the original injury, and is probably caused by serous meningitis or meningo-encephalitis, secondary to the local hæmorrhage or other lesion.

FIG. 253. — Bullet-wound of right frontal lobe, without hernia cerebri. No mental affection. No incontinence of urine. No abnormality of cranial nerves, nor of sensory or motor functions, save for absence of both abdominal reflexes.

Focal Signs of Brain Injuries

(1) **Lesions of the cortical motor areas of the pre-central region** and of the adjacent posterior end of the second frontal gyrus (Fig. 3, p. 4) are the easiest of all to recognise, since destruction of these centres produces monoplegia, facial, brachial, or crural, as the case may be—or, in more extensive lesions, hemiplegia of the contra-lateral side. Superficial lesions such as sub-pial hæmorrhage, or localised meningitis, or a depressed fracture pressing on the cortex, may also cause Jacksonian fits, which commence in the corresponding muscular group. These Jacksonian fits are usually followed by a temporary increase of paralysis in the previously convulsed limb. A localised fit of this sort may either remain limited to one limb, or segment of a limb, or it may spread, so as to affect the muscles of the whole of that side of the body. It may then cross the middle line, becoming bilateral, with unconsciousness and tongue-biting. Even without Jacksonian fits it is not uncommon to have marked tonic rigidity of the paralysed or paretic limb. This is always suggestive of a superficial lesion such as a sub-dural hæmorrhage.

Lesions confined to the upper end of the pre-central gyrus (Fig. 254, p. 480) produce crural monoplegia, those at its lower end cause facial

(Fig. 255) or facio-lingual monoplegia (Figs. 256 and 257), whilst lesions half-way down the pre-central gyrus cause brachial monoplegia. A purely cortical lesion, in order to produce a complete hemiplegia, must extend from the upper to the lower end of the pre-central gyrus. If, however, the lesion is sub-cortical, the more deeply it extends through the centrum ovale towards the internal capsule, the more completely are the converging fibres of the pyramidal tract involved, so that quite a small lesion, if deeply situated in the white matter of the internal capsule, may produce complete hemiplegia. In other words, the more

FIG. 254.—Bullet-wound immediately to left side of middle line, exactly over upper end of pre-central gyrus. Horse-shoe flap, crossing middle line, encloses original wound. The middle line and left Rolandic fissure are also marked on the scalp.

FIG. 255.—Shell-wound in right Rolandic region, causing left facial monoplegia.

superficial the lesion, the greater the tendency to monoplegia; the deeper the lesion, the more likely are we to find hemiplegia, often accompanied by hemi-anæsthesia and even by hemianopia (see pp. 7 and 8).

Tangential wounds of the vertex often cause a bilateral lesion of the upper ends of both pre-central gyri, producing bilateral monoplegia of both legs—crural diplegia.

Left-sided lesions of the pre-central region, when they implicate the motor speech-centre in Broca's convolution, or the sub-cortical fibres connecting it with the other speech-centres, produce motor aphasia, in addition to monoplegia or hemiplegia, as in the following case:—

A soldier was admitted to hospital unable to furnish any account of his previous history. He had a small bullet hole in the scalp, two inches to the left of the middle line and one inch in front of the middle of the

FIG. 256.—Bullet-wound of head, producing pre- and post-Rolandic lesion, with left-sided facio-lingual monoplegia, also loss of joint-sense in left hand, with astereognosis, but without motor weakness of limbs.

FIG. 257. FIG. 257A.

FIGS. 257 AND 257A.—Left-sided facio-lingual monoplegia from the cortical wound shown in Fig. 256. Fig. 257 shows the condition at rest, Fig. 257A the appearances on protruding the tongue.

Rolandic fissure. The patient was unable to utter any sounds, not even "yes" or "no." He was able, however, to understand and execute with ease both written and verbal requests. On trying to write with his left

hand, he made such gross spelling mistakes as to be unintelligible—*e.g.* for "doctor" he wrote "dorocks." There was marked right-sided facio-brachial monoplegia, the upper limb being totally paralysed and flaccid at all joints. The right lower limb was only slightly feeble and dragged a little in walking. The right supinator-jerk was absent, the left present; the knee-jerks and ankle-jerks were normal and equal; the plantar reflexes were both flexor in type; the left abdominal reflex was absent, the right present.

On exploring the bullet-wound, which was apparently about four or five days old, a few fragments of metal were found in the outer table, but there was no depression. A trephine-disc of bone was removed, and on incising the uninjured dura immediately subjacent, a mass of blood-clot was at once extruded from the sub-cortical brain-tissue at that point. Next day, at the first dressing, a further amount of blood-clot also came away.

FIG. 238.—Left-sided post-Rolandic wound of brain, producing profound loss of joint-sense in right fingers and hand, with astereognosis of right hand, and inability to hold objects in it with eyes shut.

Ten days after operation, although still unable to speak, the patient could write simple words to dictation, and could also copy accurately and add up columns of figures, using his left hand. The right upper limb was beginning to regain some power. A month after his operation he began to recover motor speech, the first word he said being "Thursday." Next day he could form short sentences, and within a week was able to speak in normal fashion, although with great deliberation. The monoplegia of the face and arm completely cleared up.

(2) **Lesions of the post-central gyrus** form a most interesting group. Their symptoms are essentially sensory. If the lesion implicates the uppermost or mesial end of the post-central gyrus, the symptoms are confined to the contra-lateral toes and ankle. Proceeding along this gyrus from above downwards, the cortical sensory centres correspond in level with the pre-Rolandic motor centres for the knee, hip, shoulder, elbow, hand, etc., on the other side of the central fissure (see Fig. 3, p. 4).

The clinical signs of a post-central lesion consist in the presence of one or more varieties of sensory loss in the contra-lateral limb. In some cases we observe a degree of blunting of cutaneous sensation to light touches, most marked at the periphery of the limb and fading as we ascend towards its proximal end. One of the chief characteristics of this cortical type of cutaneous deficiency is its untrustworthiness of

response and its excessive tendency to fatigue, so that responses to touches tend to disappear. The compass-test in these cases shows definite widening of the distance at which a pair of blunt compass-points are recognised as separate. Still more striking is the loss of joint-sense in the affected limb or segment of a limb, so that, with the eyes shut, when the patient's joint is passively moved from the flexed to the extended position, or *vice versâ*, he fails to recognise its posture. This loss of joint-sense often produces marked clumsiness of the affected hand or foot, which is aggravated if the patient closes his eyes.

FIG. 259.—**Left facial hemiplegia from a right-sided cortical pre- and post-Rolandic lesion. The left arm was also paralysed, with astereognosis and loss of joint-sense, etc.**

Astereognosis is another characteristic feature of post-central lesions, and is generally, but not always, proportional to the loss of joint-sense. Stereognosis is tested by closing the patient's eyes and then placing some familiar object, *e.g.* a coin, a key, a pair of scissors, or a watch, in his hand. In the case of the foot, we may use for the same purpose a brush, a sponge, a chain, or one's own finger, as the test object, all of these being easily recognised by a normal foot.

(3) **Combined pre- and post-central lesions** are commoner than pure lesions limited to the pre-central or post-central gyrus alone. The symptoms of a combined lesion, which may be unilateral or bilateral, depend upon the level at which the Rolandic fissure is crossed, and also on the proportional involvement of the pre-central or motor and of the

post-central or sensory cortex. Bilateral lesions are usually the result of a glancing wound of the vertex contusing the upper ends of both Rolandic regions and producing a diplegia, generally asymmetrical and with its most profound symptoms in the lower limbs. These lesions are best understood by studying a few illustrative cases:—

Fig. 259 shows a patient in whom there was a punctured depressed fracture, two inches to the right of the middle line and exactly over the Rolandic fissure. There was an irregular hole in the dura, from which were extracted by Lt.-Col. Legg, at an operation six days after the injury, two fragments of inner table, one inside, the other outside the dura mater, together with intra- and extra-dural blood-clot. From the outset the patient had well-marked left-sided facial hemiplegia (Fig. 259), also complete paralysis of the left upper limb, accompanied by some flexor rigidity of the shoulder and elbow. The left lower limb was only slightly weaker than the right. To light cotton-wool touches there was no loss of sensation, although they felt "different" in the left hand and forearm. Pin-pricks were felt equally on both sides. The compass test yielded 3 cm. in the right hand and 10 cm. in the left; in the right foot 2 cm., in the left 11 cm. Joint-sense was lost at all joints of the left upper limb and at the left toes, ankle, and knee. There was astereognosis of the left hand (with coin, chain, and key) and of the left foot (with chain, brush, and sponge). The left plantar reflex was absent, the right was of the normal flexor type. The left abdominal reflex was absent, the right was present. The left biceps-jerk was brisker than the right; the knee-jerks and ankle-jerks were normal and equal on the two sides.

Fig. 260.—Vertical wound, crossing middle line. Pre- and post-central.

Two weeks after the original wound, the facio-brachial monoplegia still persisted, whereas the weakness of the lower limb had disappeared. Ankle clonus, however, was now elicited on the left side. The loss of joint-sense, widened compass test, and astereognosis still persisted in the left upper and lower limbs.

Fig. 260 is another example of a combined pre- and post-central lesion in a young Australian officer. There was a gutter fracture of the vertex, starting just to the left of the middle line in front of the central fissure, extending obliquely backwards and to the right, and crossing the upper end of the right Rolandic fissure. On recovering consciousness a few minutes after the injury, his *left* arm and leg were powerless for about half an hour. The weakness of the arm then cleared up, but the left lower limb remained weak, especially at the toes and ankle, which were completely paralysed. There was also some motor weakness of the *right* foot, which

persisted for a week or two. Four days after being wounded he had a left-sided Jacksonian fit, beginning in the muscles around the left shoulder and spreading to the left face and left lower limb. When examined six days after the injury, his symptoms corresponded accurately with the cortical lesions. Thus the movements of the toes and ankles were feeble on both sides, the paralysis being partial in the right foot and complete in the left. The knee and hip were weak on the left side only. The upper limbs and face were normal and symmetrical. The foregoing phenomena were obviously due to lesion of the upper ends of both pre-central convolutions, more marked on the right side of the cerebrum.

The sensory phenomena, from lesion of the right post-central gyrus, were highly characteristic. Thus the compass test yielded 10 cm. on the left foot as compared with 5 cm. on the right; joint-sense was lost in the left toes and ankle, and there was astereognosis of the left foot only, tested with brush and chain. As the left lower limb regained its motor power, it showed marked ataxia with the heel-knee test, and the patient had great difficulty in walking, more from unsteadiness than from actual motor weakness of the left leg.

FIG. 261.—Radiogram of shrapnel bullet in left occipital lobe. Seen from the front, the bullet appears at the back of the left orbit.

(4) **Lesions of the occipital lobe** may be unilateral or bilateral. Here the most important point to determine is whether the cortical half-vision centre, which is situated mainly on the mesial aspect of the hemisphere (see Figs. 3 and 4), has been damaged. A lesion limited to the posterior pole of one occipital lobe will implicate only the macular half-vision fibres, producing a central hemi-scotoma of the contra-lateral visual half-fields. A bilateral lesion of the posterior poles of both hemispheres will cause a bilateral central scotoma, whilst peripheral vision, whose cortical centre is located farther forwards, along the calcarine fissure, will remain unaffected. Complete unilateral destruction of the half-vision centre of one occipital lobe causes homonymous hemianopia of the contra-lateral halves of both visual fields. If the lesion be limited to the cortex above the calcarine fissure, only the lower quadrant of each half-field is affected—a lower quadrantic hemianopia. If the lesion be confined to the cortex below the calcarine fissure—a much rarer occurrence—an upper quadrantic hemianopia results. Bilateral occipital lesions may cause total blindness, and even in unilateral lesions an initial phase of total blindness, lasting hours or days, is very commonly observed. This clears up later

to hemianopia of one type or another. In a recovering case of hemianopia visual perception of a moving object precedes the power of appreciation of a stationary object. This recovery of vision for a moving object begins first at the peripheral part of the blind half-field.

The commonest war-injury producing hemianopia is not an occipital one, but a lesion in the parietal region of the head, implicating the optic radiations deep within the substance of the temporal lobe.

Occipital lesions, if bilateral, usually produce either cortical blindness or, when the upper lip of both calcarine fissures is damaged, hemianopia inferior. Less severe lesions, implicating only part of the visual cortex of one side, produce, not a complete hemianopia, but a hemianopic defect or scotoma in the visual fields of both eyes.

Fig. 262.—Lesion of left upper occipital region.

In quite a number of cases the hæmorrhage, œdema, etc., around the original brain-wound become partially or wholly absorbed, so that the residual permanent lesion, with its corresponding visual impairment, is much less than would be expected if we examine the patient within a few hours or days after his injury. Thus Fig. 261 is a radiogram of a patient who had a shrapnel bullet entering through the right temporo-parietal region and lodging in the left occipital lobe. The bullet-track thus traversed both occipital lobes. At first he was completely blind. After three weeks, however, he gradually regained perception of light in the left halves of both visual fields, showing that the half-vision centre in the right occipital lobe had not been completely destroyed.

A typical example of a clearing-up lesion of one occipital lobe may here be mentioned. It will be noted that the lesion was on the outer aspect of the lobe, so that the calcarine region was not directly implicated.

Fig. 262 is that of a patient who received a small glancing wound in the upper occipital region, 1½ inches to the left of the middle line, at a level 2½ inches above the external occipital protuberance. The scalp wound was incised horizontally and explored, but no fracture was present in the outer table. Immediately after being hit, this patient noticed that he was unable to see objects on his right side, so that he stumbled against people and things as he walked back to the dressing-station. This hemianopia lasted a week or more. When examined more carefully, twelve days after the injury, there was no limitation in the size of either visual

field, but the visual acuity in the right halves of both fields was markedly diminished. There was no other sign of focal intra-cranial lesion.

Another instance of a similar lesion was that of an officer who sustained a glancing wound, by the fuse of a shell, in the right upper occipital region (Fig. 263), causing a cranial gap whose centre was 1 inch to the right of the middle line and $3\frac{1}{2}$ inches above the level of the external occipital protuberance. The wound was laid open by a crucial incision, and there was left a small gap, through which for several weeks a cerebral hernia protruded and then finally subsided. When examined five days after his original wound, there was marked diminution of visual acuity in the left

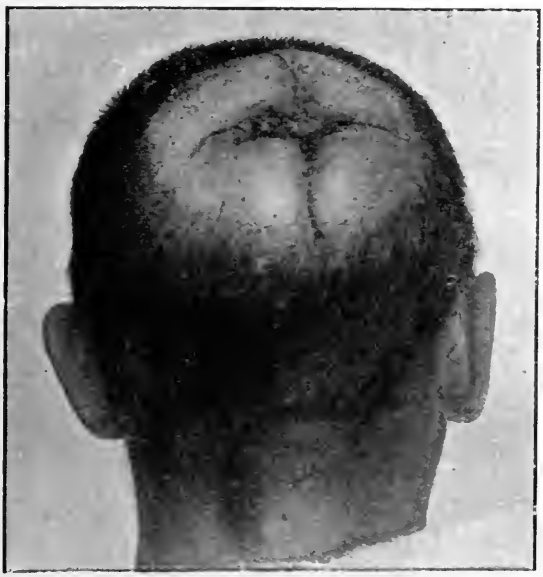

Fig. 263.—Lesion of right upper occipital region.

lower quadrant of both visual fields. The fields themselves were not contracted on either side. The patient also had well-marked astereognosis and loss of joint-sense in the left toes and ankle, with widening of the compass test in the left foot to 10 cm., as compared with 4 cm. in the right. These sensory symptoms pointed to implication of the adjacent parietal cortex, either from œdema or from forward extension of the occipital hæmorrhage. The leg symptoms rapidly cleared up, but for a time the patient still felt momentarily confused when he looked hurriedly towards objects seen in his left lower fields.

(5) **Lesions of the frontal lobes,** unless they implicate the posterior part of the lobe adjacent to the pre-central motor areas, are often conspicuous for the scarcity or absence of focal signs. Lesions of any part of the brain are liable to be followed by sequelæ such as headache, giddiness, excessive fatigue after physical or mental exertion, emotional irritability, diminished power of concentration, etc., but these sequelæ

are specially frequent after injuries of the frontal region. Sometimes frontal lesions are associated with an alteration in the patient's character, the change, unfortunately, being usually for the worse.

Thus one patient sustained a through-and-through transfrontal wound, the bullet entering through one temporal fossa and passing out through the other; the only focal signs were a transient monoplegia of the right face, and loss of the right abdominal reflex, both of which signs cleared up completely within a couple of weeks. Shortly afterwards, during convalescence, he ran away with a friend's wife. Uncharitable observers may perhaps be sceptical as to the traumatic origin of this incident. There was no history of a frontal lesion in the lady.

Another officer, suffering from an abscess in the left frontal lobe, following a perforating bullet-wound, stole some money from the clothes of another patient who died in the same ward, alleging as a pretext, when charged with the offence, that his comrade, being now dead, had no further use for money.

These are but crude examples. Prolonged observations will be necessary, after the war, to establish the frequency, character, and permanence of psychical changes following frontal lesions. Many patients with extensive frontal destruction show no abnormal signs whatever, either physical or mental. It is relatively common, however, for a patient with a frontal wound, in the absence of all other physical or psychical abnormalities, to have prolonged incontinence of urine.

Thus, in the patient shown in Fig. 251, incontinence of urine was the only abnormality that persisted when he passed out of observation six weeks after his injury.

Fractures of the anterior fossa of the skull, besides producing lesions of the orbital surface of the superjacent frontal lobes, may tear across the olfactory nerves at the cribriform plate, causing anosmia. This symptom is difficult to recognise in the early days after the injury. Sometimes leakage of cerebro-spinal fluid from the nose affords a clue, but the patient's mental state is rarely sufficiently alert to permit of accurate testing of the function of smell until some time later, when the acute cerebral symptoms have passed off.

(6) **Lesions of the temporal lobe** are frequently devoid of focal symptoms, since the cortical auditory centre in the superior temporal gyrus, and the cortical olfactory and gustatory centres in the uncinate gyrus, are represented bilaterally, in both temporal lobes. Thus one temporal lobe may be extensively destroyed without producing focal signs. Deep-seated temporal lesions, implicating the subjacent optic radiations, may produce hemianopia in addition to purely "temporal" signs. In certain left-sided lesions, however, as a result of damage to the word-hearing centre on the upper or Sylvian surface of the superior temporal convolution, we have word-deafness. This is exemplified by the following case:—

A young soldier sustained a perforating scalp wound in the left temporal region, the entry being four inches vertically above the external auditory meatus, the exit half an inch above the posterior end of the zygoma (see Fig. 264). A radiogram showed no fracture of the cranium, nor did exploration of the bullet-track reveal any bare bone. Nevertheless the temporal lobe had evidently been contused, for, when examined a week after the injury, he had a moderate degree of sensory aphasia. He spoke slowly and with difficulty, occasionally jumbling his syllables. He could read aloud when shown written messages, but did not execute written requests, whilst with verbal requests he became easily confused. There was no motor or sensory abnormality of the face, tongue, or limbs on either side, and the reflexes, deep and superficial, were normal and equal on the two sides. All his aphasic symptoms gradually cleared up.

Fig. 264.—Tangential wound of left temporal region with transient word-deafness.

(7) **Lesions of the parietal region** of the cortex produce their chief symptoms by affection of the sensory cortex (see p. 195 and Fig. 3, p. 4), and also by affection of the psycho-visual centres which extend a little way into this region from behind, more especially the word-seeing centre in the angular gyrus on the left side.

Cortical lesions of the postero-parietal region, especially of the angular and supra-marginal gyri, produce psycho-visual symptoms such as loss of visual localisation in space, disturbance of the perception of depth and distance, etc. Such a patient, although able to see objects distinctly, cannot tell how far removed they are from himself or from each other. There is also loss of visual attention, so that the patient is incapable of noting two or more visible objects at the same time, and therefore has special difficulty in counting objects.

Lesions towards the *anterior* part of the parietal cortex, *i.e.* the post-central gyrus, are specially associated with loss of topognosis and of joint-sense, and therefore we find astereognosis of the contralateral limb or limbs. Lesions of the *lower* zone of the parietal lobe produce special difficulty in appreciating the intensity of stimuli, *e.g.* the difference between a warm object and a warmer one: whilst lesions towards the *posterior* part of the lobe are associated with loss of recognition of identity and difference in the size, shape, and form

of objects felt. These three groups of functions may be destroyed collectively in different proportions and even independently of one another. In other cases, word-blindness results from a lesion of the left angular gyrus. Lesions situated between these various regions, in a "silent" area of the cortex, may be apparently devoid of symptoms, as in the patient shown in Fig. 265.

This patient sustained a tangential wound in the right upper parietal region. Next day the wound was explored, and a depressed fracture was found beneath the scalp wound. The dotted line indicates the extent of the bony gap resulting from the craniectomy. When examined eleven days after the injury there was no hemianopia; the pupils and cranial nerves were normal. There was no sensory abnormality of the face, trunk, or limbs. Stereognosis was perfect in all the limbs. There was neither weakness, tremor, nor ataxia of the upper or lower limbs, whilst the reflexes, deep and superficial, were normal and equal on the two sides.

Fig. 265.—Wound of right upper parietal region in "silent" area.

(8) **Lesions of the cerebellum** are in close proximity to the vital medullary centres, which may be fatally injured by shock, even without being directly implicated in the destructive lesion. Subtentorial lesions, therefore, are so frequently fatal that in only a small proportion of direct wounds of the cerebellum, chiefly superficial injuries, does the patient survive to show cerebellar symptoms. The following is an example of this sort:—

The patient had a perforating bullet-wound of the skull in the right cerebellar region, entering below the tip of the right mastoid process and emerging immediately to the right of the external occipital protuberance.

When hit, he did not lose consciousness, but "spun round and round" and fell. On being helped to his feet, he could not walk alone, but felt "drunk and giddy." He vomited within an hour of his injury, and had transient deafness of the right ear with paresis of the right side of the face. Five days after the injury, save for slight right-sided facial paresis, upper and lower, together with a trace of unsteadiness in walking, all his symptoms had disappeared. There was neither nystagmus, deafness, ataxia, dysdiadochokinesia nor other cerebellar symptoms.

More severe cerebellar lesions, however, if the patient survives, produce the characteristic phenomena which we have already described (pp. 23 and 258).

Thus in *unilateral lesions* there is ataxia of the ipso-lateral limbs, including asynergia, hypermetria, and dysdiadochokinesia. There is also mis-pointing, and spontaneous deviation of the ipso-lateral upper limb with Bárány's pointing-tests. The gait is unsteady, owing to ataxia of the corresponding lower limb. Together with this there is asthenia and muscular hypotonia of the ipso-lateral limbs, but this muscular flaccidity tends to subside after a few days or weeks. In severe cases articulation may be, for a time, dysarthric. Nystagmus is present in most cases, chiefly when the patient fixes an object on the ipso-lateral side of his visual field. Skew-deviation of the eyes is less

FIG. 266.—Radiogram showing shrapnel bullet in right lateral cerebellar region.

common. Both this and the nystagmus are probably due to implication of Deiters's nucleus or its connections. The knee-jerk on the affected side is sometimes of a characteristic "pendular" type (see p. 321).

Bilateral lesions produce bilateral ataxia, etc., and the disorder of articulation is more marked than in unilateral cases. Also the muscles of the trunk and neck are specially hypotonic, so that the patient has difficulty in standing or even in sitting up unless supported.

As time goes on, after a stationary lesion such as a bullet-wound, a certain amount of compensation tends to occur. Thus the muscular hypotonia rapidly subsides. The ataxia improves more slowly, but may ultimately disappear. The following is an example of a compensated cerebellar wound:—

At the age of twenty-five, a soldier was wounded by a shrapnel-bullet in the Boer War. The entry was an inch behind the right mastoid process, exactly at the level of the external auditory meatus. There was no exit-wound, and a radiogram taken eighteen years later showed the bullet lying in the right sub-occipital region about half an inch from the inner surface of the skull (see Fig. 266). After the injury the patient noticed weakness and unsteadiness of the right lower limb for several months. He was invalided out of the army on a pension, and became a postman in civilian life. Ever afterwards, he noticed that the right leg tired before the left on walking. Fifteen years after his injury he rejoined the army, and had done nearly three years' additional active service when he came under observation, eighteen years after the old wound, suffering from malaria.

On examination, the only abnormality to be detected was complete deafness of the right ear, both to aerial and to bone conduction. There was no nystagmus, no giddiness and no ataxia of upper or lower limbs with the finger-nose, heel-knee, or pointing tests. The knee-jerks and ankle-jerks were brisk and equal, and the plantar reflexes flexor in type. The gait was absolutely normal.

Cranial nerve lesions produced by war injuries do not differ essentially from those in time of peace. As regards their frequency, compared with injuries of peripheral spinal nerves, cranial nerve palsies are less common, despite the fact that the head is more exposed to wounds than any other part of the body. This is because so many wounds which, if the patient had survived, would have shown cranial nerve paralysis are rapidly fatal from injury to the brain.

Sequelæ after Head Injuries.—

Already in peace-time it has been a matter of common knowledge that some head injuries, even those in which evidences of persistent focal lesions are scanty or absent, tend to exhibit permanent *changes in function*, especially intolerance to alcohol, deficiency and slowness of mental concentration, abnormally rapid mental fatigue with undiminished mental acuity, increased emotional irritability, special sensitiveness to changes of weather or to changes of temperature, headache and giddiness on stooping, sudden attacks of causeless vertigo, etc. Most of these symptoms are probably referable to disturbance of the vaso-motor centres. Vasomotor disorders of a more localised distribution are also met with, such as unilateral sweating or unilateral rise of blood-pressure, on the contra-lateral side, after a Rolandic lesion.

In addition to the foregoing, there is a special tendency to the development of *epilepsy*, even in cases where the wounds are soundly healed and free from all suspicion of sepsis. The epileptic fits are liable to supervene upon any physical or mental over-exertion. Such cases of traumatic epilepsy may sometimes be the expression of a previously latent epileptic tendency. They occur not merely in patients in whom the cortical motor areas are directly irritated by foreign

bodies or by inflammatory processes, but also in cases where no direct local irritation can be discovered. Hence the importance of prolonged quietude and of avoiding physical or mental over-exertion in every patient who has sustained a severe head injury.

The possible development of *cerebral abscess* or of a fulminating *purulent meningitis*, many weeks or months after the apparent healing of a brain-wound, has always to be borne in mind.

Other Organic Brain Lesions in War.—It is not to be expected that war should confer on the combatants any immunity from the ordinary organic nervous diseases which are liable to occur amongst peaceful civilians. Thus a soldier with syphilitic or other variety of cardio-vascular disease is liable to the ordinary types of cerebral arterial lesions, such as hæmorrhage, thrombosis, or embolism. Moreover, latent organic diseases such as disseminated sclerosis, tabes, dementia paralytica, and cerebral tumour (as in the case shown in Fig. 237), also maladies like epilepsy and myoclonus, whose morbid anatomy is yet unknown, are not uncommonly precipitated or aggravated by the physical and emotional strain of warfare, or may undergo acute relapses.

Most of the combatants are young active men who, having already passed at least one medical examination, would in peace-time be regarded as selected lives. Chronic cardiac or renal diseases are therefore usually excluded at the outset. Nevertheless, even in such individuals, a certain proportion of organic brain lesions is directly attributable to war conditions.

Perhaps the most dramatic examples are those cases in which, in order to arrest hæmorrhage in deep wounds of the neck, the common or internal carotid artery has to be ligatured. Many of these patients recover without cerebral symptoms; others, however, develop cerebral softening from thrombosis or embolism of the middle cerebral artery, with resulting hemiplegia. Makins[1] considers such cases to be due to arterial embolism, and quotes a series of fourteen cases in which the cerebral symptoms occurred suddenly at intervals varying from one hour to four days after an injury to the carotid artery, whether by a primary wound or after ligation for the purpose of arresting hæmorrhage. The following is an illustrative example of such an accident:—

A healthy young soldier, aged twenty-two, of fine physique, was shot in the right side of the neck during the glorious landing of the Anzac troops at the Dardanelles. The bullet entered through the tip of the right mastoid process and emerged through the right upper lip, carrying away part of the upper jaw. Furious bleeding occurred, which was temporarily arrested on the field by firm plugging. Later in the day it was found

[1] *Lancet*, September 23, 1916, p. 543.

necessary, in order to control the hæmorrhage, to ligature the right common carotid artery. (The scar of the operation-wound can be seen in Fig. 267.) Two days later, on waking up, the patient found himself completely hemiplegic on the left side.

When examined five weeks later, in one of the base hospitals, the left face, arm, and leg were completely paralysed, with flaccidity of the affected limbs. There were also well-marked sensory changes, consisting in slight blunting to cotton-wool touches in the left forearm and left leg below the knee, together with loss of joint-sense at all joints of the left upper and lower limb, and astereognosis of the left hand and foot. The deep reflexes were increased on the paralysed side, with ankle clonus; there was also

Fig. 267.—Showing entry-wound below right mastoid process. The area of anæsthesia of the right side of the face is indicated by dark lines. The scar of operation for ligature of the common carotid is seen along the anterior border of the sterno-mastoid.

absence of the left abdominal reflex, while the left plantar reflex was extensor in type.

Finally, there was an area of localised anæsthesia to all forms of sensation on the right side of the face, mainly in the territory of the second division of the trigeminal nerve, obviously due to injury of that nerve from the fracture of the upper jaw.

Hemiplegia from vascular obstruction may also occur as a result of cardio-vascular disease acquired in war, independently of trauma.

Thus one patient, a lad of twenty-two, who was in hospital at the time, suffering from an attack of malaria, developed complete right-sided hemiplegia and aphasia with absolute suddenness, when turning over in bed. There was no loss of consciousness. The presence of an aortic systolic bruit led us to diagnose a cerebral embolism.

Another patient, aged twenty-one, at the end of a prolonged attack of enteric fever, suddenly discovered himself unable to move the left arm, and there was moderate weakness of the left lower limb, which subsequently became complete. There was no history of venereal disease; the urine was free from abnormal constituents. Two days after the onset of the weakness he was found to have complete flaccid left hemiplegia. A diagnosis of cerebral thrombosis was made, and seemed to be supported by the lowness of the systolic blood-pressure, measuring 118 mm. of mercury. A week after the onset of the hemiplegic attack he began to recover power in the affected muscles. A few days later, signs of obstruction of the right femoral artery developed, with gangrene of the foot and lower part of the leg. The patient died 2½ weeks from the onset of the original hemiplegia. At the autopsy, instead of thrombosis, recent emboli were found, one in the profunda artery of the right thigh, the other in the right middle cerebral artery, with a small area of softening in the right lenticular nucleus. The heart showed recent ulcerative endocarditis of the aortic cusps.

Uræmic convulsions are sometimes met with in patients brought into hospitals or dressing-stations on the field. The medical officer must be careful not to confound such cases either with ordinary epilepsy or with epileptiform fits from gross cerebral lesions.

Cerebro-spinal meningitis, due to one or other variety of meningococcus, may be either sporadic or epidemic. It is usually easy of recognition, and the diagnosis is confirmed by examination of the cerebro-spinal fluid. Sometimes, however, difficulty arises with cases of meningismus, in which with pyrexia we find severe cerebral symptoms such as headache, mental dulness, or even coma, head-retraction, etc. Such cases can only be diagnosed from meningitis by the examination of the cerebro-spinal fluid, which proves to be normal. Patients with meningismus in war-time have, in my experience, most frequently proved to be suffering either from enteric fever or from cerebral malaria, as in Macedonia.

Wounds of the Spinal Cord

The spinal cord, bathed and supported by cerebro-spinal fluid, is enclosed within the dense theca. The space between pia and dura is bridged across by the ligamenta denticulata, at the lateral surfaces of the spinal medulla. It is further protected by the strong, closely knit bones and ligaments of the vertebral column, which in their turn are supported externally by thick masses of muscle. Nevertheless, war injuries of the spinal cord, cauda equina, and spinal meninges are fairly common. Injuries of this sort are most often caused by projectiles; bayonet-wounds and sword-cuts are rare.

Spinal injuries, identical with accidents occurring in civil life amongst miners and others, are also produced in war by the falling

of heavy sandbags upon the vertebral column, or by the collapse of trench walls or buildings under shell or bomb explosions.

Injuries of the spinal cord by bullets differ in some respects from those produced by fracture-dislocations. In bullet injuries the spinal cord may be damaged directly by the penetrating missile, or, more commonly, it may be lacerated or compressed by in-driven fragments of bone. Still more frequently the bullet-track passes through or near to the vertebral column without touching the theca or spinal cord at all, and yet, notwithstanding the absence of any gross vertebral fracture, spinal-cord lesions are produced indirectly by the concussion effects of the high-velocity missile.

Concussion-lesions of the spinal cord vary widely in their severity, ranging from a complete pulping of the cord, with intact dura mater, to a mild, fleeting concussion, revealed by symptoms which are quite transient, and which are therefore often wrongly regarded as psychogenic or hysterical. There can be little doubt that sometimes so-called functional symptoms, immediately following a spinal concussion, are really due to a transient organic molecular change, insufficient to produce the ordinary signs of a gross organic lesion. In doubtful cases, the presence of blood in the cerebro-spinal fluid is in favour of a diagnosis of organic lesion.

The **pathological changes** found in wounds of the spinal cord are of various types. Contrary to what might have been expected, the commonest lesion is not a hæmorrhagic one, but an area or areas of *acute concussion-necrosis*. The spinal cord undergoes sudden softening in one or more consecutive segments, and there is œdematous swelling above and below the necrotic zone.

In a smaller proportion of cases we find a single *large intra-medullary hæmorrhage*, identical with that which occurs in ordinary fracture-dislocations. This hæmorrhage extends upwards and downwards from the primary lesion, chiefly in the grey matter, the posterior horns and their vicinity being more affected than the anterior columns. In other cases *multiple capillary hæmorrhages* are present, here again chiefly, though not exclusively, in the grey matter. In hæmorrhagic lesions of the cord, whether large or small, blood is usually effused outside the cord but within the theca, staining the cerebro-spinal fluid, in which it can be recognised by lumbar puncture. Extra-thecal hæmorrhage may also occur, sometimes of considerable vertical extent.

In another class of cases the cord is *compressed from without* by fragments of bone, by bullets, or still less frequently by massive extra-medullary hæmorrhage. Above and below the compressed area, there are œdema and multiple minute hæmorrhages, chiefly into the grey matter.

Infective *meningo-myelitis* sometimes supervenes. This condition, developing soon after an injury, is produced by organisms which gain access to the meninges, usually through a septic bullet-track. Less commonly it is the terminal result of a deep, sloughing bed-sore, implicating the spinal theca. It is easily recognised by the presence of root-pains, muscular rigidity, and pleocytosis of the cerebro-spinal fluid. Meningo-myelitis which spreads in an upward direction from the level of the original lesion may mislead the observer by causing him to locate the primary lesion too high up. In such cases radiography is of special value, since the question of surgical intervention for the removal of a septic bullet or of a displaced bony fragment should be decided not merely by the level of the anæsthesia, but by the position of the vertebral lesion.

In every spinal injury, the first problem to be solved is whether an organic lesion of the cord is present or not. This is usually easy to determine, although hysterical paraplegia may deceive the unwary, as in the following example:—

A soldier, aged thirty-six, was waiting in a support trench, when a shell landed close by. Its explosion blew him three or four yards along the trench. No wound of the trunk was produced. He was dazed for about half an hour, but not unconscious. On being propped on his feet, he found great difficulty in standing, and on sitting down had difficulty in getting up again. His left lower limb also felt subjectively numb. He was sent to a base hospital as a case of probable contusion of the spinal cord, and the occurrence of precipitancy of micturition after the accident appeared further to support this diagnosis.

When examined eight days after the accident, there was no abnormality save in the lower limbs. The left leg showed slight comparative blunting of sensation to all forms of cutaneous stimulation, from the knee downwards. Joint-sense, however, was unaffected. He was unable to sit up without using his hands, although the abdominal muscles contracted normally. Both lower limbs were slightly feeble, especially the left, but no movement was impossible. The gait was typically functional in type. The patient walked cautiously, pushing the left foot forwards and then dragging the right foot up to it. The knee-jerks were only just present; the ankle-jerks were brisk and equal. The plantar reflexes were of the normal flexor type; the abdominal reflexes were brisk. There was no spinal rigidity or deformity. Under treatment by suggestion, the weakness of the legs rapidly disappeared, the "stocking" anæsthesia cleared up, and the patient became able to walk normally.

Should the signs point to a gross organic lesion of the spinal cord, we have to determine the level of the lesion and to decide whether it is complete or incomplete. In the case of an incomplete lesion we have further to consider whether it is caused by extra-medullary pressure. This may be produced by a bullet, a fragment of shell or indriven bone, or by a large extra-thecal hæmorrhage. In all such cases

the possibility of operation for the relief of such pressure has to be considered.

Wounds of the cervical region of the spinal cord are sometimes associated with an immediate and extraordinary lowering of the body temperature. This hypothermia, which may be as low as 83° F.(28·3°C.) or even 80° F. (26° C.),[1] is lower than any that has been observed to result from ordinary surgical shock, for even in the severest abdominal wounds, or in patients with profound loss of blood, the subnormal temperature rarely falls below 89° F. or 88° F.

The **diagnosis of the level** of a spinal-cord lesion depends on the accurate observation of the various sensory and motor phenomena.

Two varieties of sensory disturbance may be present in spinal-cord lesions—firstly, those due to lesion of the posterior root (or roots) interrupted at the level of the lesion, causing root-anæsthesia or root-hyperæsthesia; and, secondly, the sensory affections resulting from lesion of the sensory tracts within the spinal cord.

A. **Posterior Root Symptoms.**—Figs. 25 and 26 indicate the cutaneous distribution of the various posterior roots. In lesions implicating the posterior roots before they have entered the spinal cord, all forms of cutaneous sensation are affected, and there is total anæsthesia of the affected root-areas. The posterior root-fibres may also be damaged after they have entered the spinal cord, but before they have been regrouped to join the various afferent tracts shown in Fig. 12. In cases of this sort, certain forms of sensation may escape, so that the area of loss to light touches may no longer be co-terminous with that for pain or temperature. Further, the area of cutaneous loss is no longer strictly limited to a definite root-area, but may include parts of several adjacent root-areas. This is better seen when the limbs are affected than with root-lesions of the trunk.

There may also be cutaneous hyperæsthesia in the affected root-area. In a unilateral lesion this hyperæsthesia occurs at the upper margin of the sensory loss, on the same side as the spinal-cord injury. It is probably due to inflammatory reaction or œdema of the affected root-fibres, whether outside or within the spinal cord. It is usually a transient phenomenon, clearing up, as a rule, in a few weeks. In some cases there may also be spontaneous subjective root-pains, either running along the limbs or occurring as girdle-pains around the trunk.

B. **Intra-medullary Sensory Phenomena.**—In a complete transverse lesion all forms of sensation are abolished below the level of the lesion. In cases in which the posterior roots are implicated as well as the spinal cord proper, no difficulty arises in the diagnosis of the level of the injury,

[1] Weil, *Münch. med. Wochensch.*, September 11, 1917, No. 37.

since the "tract anæsthesia" due to interruption of the intra-spinal sensory tracts is continuous with the root anæsthesia.

Sometimes, however, a transverse lesion is entirely intra-medullary, *e.g.* in acute necrosis or hæmorrhage within the spinal cord, and does not implicate the posterior roots which enter at that level. In such a case we no longer have a root-anæsthesia to guide us, but have to deal with sensory loss resulting from interruption of the various intra-spinal tracts. Owing to the obliquity with which the sensory fibres, after entering one side of the spinal cord, cross over to the opposite spino-thalamic tract (requiring several successive segments before their decussation is complete), the upper border of the anæsthesia is lower than if these fibres crossed horizontally. This is best observed in unilateral lesions, in which an apparent discrepancy may seem, at first sight, to exist between the upper level of the motor phenomena on one side of the body and that of the sensory loss on the opposite side. The obliquity of decussation of the sensory fibres is greatest in the cervical region, where five or six segments may be required before the crossing is completed, whereas in the thoracic region the decussation is achieved within a single segment above the level of entry of the posterior root fibres. Unless these facts are borne in mind, if we depend on the upper level of the sensory loss to localise an intra-medullary lesion, we are liable to locate it several segments too low, especially if it be in the cervical region, where thermal sensations apparently cross within three or four segments, painful sensations in about four segments, and tactile sensations still more obliquely.

Thus the upper margin of the analgesia and therm-anæsthesia tends to be slightly higher than that of the tactile loss.

Another mechanism sometimes produces these phenomena. Thus, in cases of hæmatomyelia, in which a gross hæmorrhage implicates indiscriminately grey and white matter at a certain level, it may "tail off" upwards, so as to be confined at its upper limit to the grey matter and central canal. In such cases we have a syringomyelic dissociation of sensation, extending for one or more segments, above the upper margin of the total, or "global" anæsthesia to all forms of stimuli.

The **motor phenomena** are also of great value in localising the level of a spinal-cord lesion. They are of two varieties. Firstly, we have **segmental motor signs,** due to injury of the anterior cornua or anterior roots at the level of the lesion; and, secondly, **pyramidal signs,** due to injury of the antero-lateral columns of the cord.

The segmental innervation of the muscles of the neck, upper and lower limbs, is well known, and is indicated in the tables on p. 35. In the thoracic region of the cord, between the lower end of the cervical

and the upper end of the lumbar enlargement, each segment innervates its corresponding intercostal muscle, together with a portion of the spinal and abdominal muscles at that particular level, the rectus abdominis corresponding to the segments from the 6th to the 10th thoracic, and the obliquus abdominis to the lowest two thoracic segments.

Bearing these facts in mind, it is comparatively easy to identify the particular segment (or segments) of the cord in which there has been a lesion of the anterior cornua or anterior roots, inasmuch as the muscles corresponding to that segment (or segments) undergo atrophic paralysis and, after a week or ten days, show the electrical reactions of degeneration. Thus in lesions affecting the cervical or lumbar enlargements we find certain groups of muscles in the limbs marked out from the others, whereas in lesions of the thoracic region the paralysed intercostal muscles can readily be differentiated from the non-paralysed intercostals higher up, by palpation and sometimes even by inspection. Lesions of the ninth thoracic segment produce paralysis of the lower part of the recti abdominis, whilst the upper halves of the recti remain unaffected; hence, when the patient attempts to sit up, the umbilicus is drawn upwards. Lesions of the 11th thoracic segment spare the recti altogether, but the obliquui abdominis, in the flanks, are paralysed.

Pyramidal motor signs, characteristic of an upper motor neurone lesion, are already familiar, and need not here be discussed in detail. It should be remembered that in all severe traumatic lesions of the spinal cord the paralysed lower limbs are at first flaccid, with absent ankle-jerks and knee-jerks, and absence of plantar response.[1] If the lesion be a complete transverse one, the deep reflexes reappear slowly, after an interval varying from several weeks to a couple of months, muscular tonus is re-established, and together with this the plantar reflexes become extensor in type and the "mass-reflex" (consisting in flexor spasm of the lower limbs with reflex contraction of the bladder and paroxysmal sweating below the level of the lesion) is established. If the lesion be incomplete, the plantar reflexes are extensor from the first, the muscles soon regain their tone, and within two or three weeks rigidity sets in, sometimes accompanied by reflex flexor spasms, whilst the deep reflexes reappear and become exaggerated, giving the typical

[1] It is possible that this disappearance of the deep reflexes is not immediate, but only occurs after an interval of several minutes, for Basil Hughes* records a case of a soldier who was cut in two by a large fragment of high-explosive shell, at the level of the third thoracic vertebra, in whom the knee-jerks, tested immediately afterwards, were found to be brisk, and in whom pinching of the inner side of either thigh produced drawing-up of the corresponding lower limb. Opportunities for such observations are rare, and medical officers possessed of the necessary sang-froid to make them must be rarer still.

* Hughes and Banks, *War Surgery*, 1918, p. 604.

clinical picture of an upper motor neurone lesion. In unilateral lesions the deep reflexes in the ipso-lateral paralysed lower limb are diminished or lost for the first week or two, subsequently proceeding to the stage of exaggeration.

Is the Transverse Lesion Complete or Incomplete?—In complete transverse lesions the plantar reflexes are often absent at first. In some cases feeble plantar reflexes of flexor type can be elicited from the outset. These give place, after several weeks, to the classical Babinski extensor response.

If the lesion be a complete one, with total functional discontinuity of the upper from the lower fragment of the spinal cord, the damage is irreparable, and inasmuch as regeneration of nerve tissues does not occur within the central nervous system, no operation—*e.g.* for the removal of a projectile or of a displaced fragment of bone, if present—is likely to be of any avail.

In cases of transverse lesion, the spinal cord may be anatomically severed, with a gap between the upper and lower segments. More often, however, it is only physiologically interrupted, the nervous tissues at the level of the injury being so disintegrated as to be, from the standpoint of function, non-existent. In both varieties the clinical result, at the outset, is the same; the patient has complete flaccid paraplegia with anæsthesia below the level of the lesion, together with loss of the ankle-jerks and knee-jerks. During the initial period of shock, the plantar reflexes are usually absent or flexor in type, but tend to return later and to assume the extensor type. In other cases, in which a shred of nervous tissue survives, joining the segments above the lesion to those below it, the motor and sensory paralysis is complete, but spasticity develops, and the deep reflexes not only return, but become exaggerated, whilst the plantar reflexes become extensor in type.

In a transverse lesion confined to a single segment of the spinal cord, the muscles corresponding to that segment undergo atrophic paralysis with loss of faradic excitability, as already described, whereas the paralysed muscles corresponding to all the segments lower down usually retain their electrical reactions. In a certain proportion of cases, however, all the paralysed muscles, from the level of the lesion downwards, lose their faradic excitability within a week or ten days after the original injury. This loss of electrical response remains permanent. So far as I was able to judge, in a series of eight such cases with injuries at various levels, from the cervical region downwards, the lesion in each of them was an acute softening, not a severance of the spinal cord by direct injury. The probable explanation is to be sought in molecular changes occurring in all the anterior cornual cells from the level of the lesion downwards.

Let us first consider those cases in which a lesion causes **complete interruption of the spinal cord,** whether directly by the bullet-track or indirectly by concussion necrosis. In a recent series of thirty-four personally observed cases (exclusive of cauda equina lesions), the signs pointed to a complete transverse lesion in seventeen, *i.e.* in one-half of the cases. The following is an example of direct bullet injury:—

A soldier, aged twenty-four, was wounded by a rifle-bullet which entered one inch above the middle of the right clavicle and came out one-and-a half inches above the middle of the left clavicle. He immediately lost power and sensation in the trunk and lower limbs. There was persistent retention of urine, for which the catheter had been used.

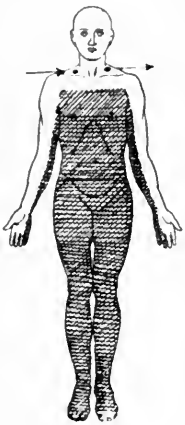

Fig. 268.—Total transverse lesion at level of 8th cervical segment.

When examined, five days after the injury, the patient had complete anæsthesia to all forms of cutaneous stimulation up to the level of the 2nd ribs in front and to the 2nd thoracic spine behind, also along the inner margins of both upper limbs, in the distribution of the 7th and 8th cervical and 1st thoracic segments (see Fig. 268). Vibration sense was lost in the lower limbs and trunk, up to the 3rd thoracic spine, also in the two ulnar fingers of the right hand. Joint-sense was absent in the lower limbs and impaired in the fingers of both hands.

The motor functions of the head, neck, diaphragm, and upper limbs were normal, with the exception of the intrinsic muscles of the hands, which were paralysed. The intercostal and abdominal muscles were paralysed, together with the spinal muscles, and there was total flaccid paraplegia of both lower limbs. The knee-jerks and ankle-jerks were absent, as also were the plantar and abdominal reflexes. All the muscles of the trunk and upper and lower limbs reacted normally to faradism. There was retention of urine with overflow dribbling. The urine was ammoniacal and contained pus. The cerebro-spinal fluid was blood-stained, and on standing yielded a supernatant deep yellow fluid with a gelatinous coagulum. The temperature was moderately raised to 101·4° F. A superficial bed-sore was present over the sacrum.

The patient died sixteen days after the date of injury. At the autopsy the bullet-track was found to have traversed the spinal cord at the level of the 8th cervical segment, the upper and lower fragments of the cord being joined only by a thin strip of tissue in front of the anterior commissure. A small piece of bone was embedded in the inner surface of the theca at the left side, having been carried through from right to left. No hæmorrhage could be seen, by the naked eye, in the substance of the spinal cord above or below the level of the injury, nor was there any hole visible in the spinal theca, although the bullet-track in the spinal cord and the bony fragment within the dura mater showed that it must have been perforated.

The next case is one of acute softening from concussion necrosis:—

An Indian officer, aged thirty-five, was wounded by a bullet whose aperture of entry was one inch to the left of the 9th thoracic spine, the exit

being in the right mid-axillary line, between the 8th and 9th ribs. When examined five days later, in addition to the signs of a right-sided hæmothorax, there was total flaccid paralysis of the lower limbs and of the lower abdominal muscles, the umbilicus being pulled upwards when the patient attempted to sit up. There was anæsthesia of the lower limbs and trunk, to all forms of stimuli, up to a level three inches above the pubes. The knee-jerks and ankle-jerks were absent, also the bulbo-cavernosus, plantar, and abdominal reflexes. There was retention of urine with overflow incontinence. The cerebro-spinal fluid was clear and showed no abnormality on microscopic examination.

The patient died on the twenty-first day after the injury. At the autopsy the spinal theca was uninjured, and no hæmorrhage was present, either inside or outside it. At the level of the 12th thoracic segment the spinal cord was soft and pulpy for a vertical extent of about an inch. After suitable hardening, sections through the softened area showed that the damage was mainly in the posterior region of the cord, implicating both grey and white matter. Microscopic examination showed disintegration of all the nervous elements, with moderate proliferation of small round cells. There was no evidence of hæmorrhage, old or recent.

Incomplete transverse lesions of the spinal cord are sometimes mainly unilateral. Such cases, occurring above the lumbar enlargement, produce the classical Brown-Séquard syndrome, consisting in motor paralysis on the ipso-lateral side, with dissociated anæsthesia on the contra-lateral side, as in the following example:—

The patient, a bandsman, was wounded by a shrapnel-bullet which entered the right side of the neck at the middle of the anterior border of the sterno-mastoid muscle. There was no wound of exit. The bullet crossed the middle line and lodged close behind the outer end of the left clavicle, where it was discovered by radiographic examination three weeks later. When wounded, the patient fell to the ground powerless in all his limbs. In a few minutes he found himself able to move the right arm, and next day he recovered some power in the right leg. There was some delay in micturition, but catheterisation was never required.

When examined six days after the injury, the right pupil was slightly larger than the left. Both pupils reacted normally, and the cranial nerves were otherwise normal.

To cotton-wool touches there was anæsthesia of the feet and ankles up to the junction of the lower and middle thirds of the legs. To pain and temperature there was loss of sensation in the right lower limb and right half of the trunk up to the level of the 3rd rib, extending along the inner side of the right upper limb in the distribution of the 7th and 8th cervical and first thoracic root-areas (see Fig. 269). This analgesia and therm-anæsthesia also extended across the middle line of the trunk in a zone from the 3rd rib to just below the nipple, and along the inner side of the left upper limb in a distribution similar to that on the right side. Joint-sense was normal in the lower and upper limbs, except in the two ulnar digits of the left hand, in which it was deficient. Vibration-sense was lost in the lower limbs and lower part of the trunk, up to the level of the 5th thoracic spine.

The left lower limb was completely paralysed and flaccid. The right lower limb could be voluntarily moved at all joints. The abdominal and

intercostal muscles were paralysed on both sides; the diaphragm moved normally.

In the right upper limb there was paralysis of all the intrinsic hand muscles and of the long flexors and extensors of the fingers and thumb, whilst the movements of the wrist, forearm, elbow, shoulder, and scapula were normal. In the left upper limb there was paralysis of the intrinsic hand muscles and of all the flexors and extensors of the fingers and wrist (except the extensor carpi radialis brevior). The triceps was also paralysed. All the other muscles of the limb were normal.

The head and neck moved normally.

Fig. 269. — Incomplete transverse lesion at level of 8th cervical segment. (Brown-Séquard syndrome.)

The biceps-jerks in the upper limbs were brisk; the triceps-jerks were absent.

In the right lower limb the knee-jerk was brisk, the ankle-jerk feeble. In the left lower limb the knee-jerk and ankle-jerk were absent.

The right plantar reflex was flexor in type; the left, at this stage, was absent. A week later the left plantar reflex was definitely extensor in type.

The abdominal reflexes were absent.

Beyond slight delay in micturition, the sphincters were otherwise normal.

The right side of the head and neck, with the right upper thoracic wall, were noticed to sweat excessively.

Gradual improvement set in. A week later, the right rectus abdominis was observed to have regained voluntary power, whilst the left thigh muscles were also beginning to recover. When the patient passed out of observation six weeks after his injury, the cotton-wool anæsthesia had disappeared, whilst the analgesia and therm-anæsthesia were unchanged. The left lower limb had regained motor power at all joints, but was still considerably feebler than the right. The abdominal muscles contracted on both sides, the right better than the left. The intercostal muscles still remained paralysed. In the right upper limb no individual muscle was now paralysed. In the left upper limb the intrinsic muscles of the hand had recovered. The triceps contracted feebly, also the extensors of the wrist. The only muscles that remained totally paralysed were the long flexors and extensors of the fingers. The knee-jerks were brisk, also the ankle-jerks. There was now left-sided ankle clonus, and both plantar reflexes were now extensor in type.

An incomplete transverse lesion of the spinal cord may involve mainly the mesial or central region of the cord, leaving undamaged the fibres nearer the surface. Inasmuch as those spino-thalamic fibres (conveying sensations of temperature and pain) which correspond to the lowest spinal roots lie nearest the surface of the lateral columns, the result is that the sacral cutaneous root-areas—*i.e.* the region of the genitals, perineum, and "saddle area" of the buttocks and thighs—tend to escape, whilst the root-areas higher up, corresponding to the more mesially situated fibres of the spino-thalamic tract, are alone affected by anæsthesia. The following is an illustrative case:—

The patient, aged twenty, was wounded by a bomb explosion which produced three wounds in his back, all at the level of the 12th thoracic spine, to the left of the middle line. A radiogram showed a bullet 2½ inches to the right of the middle line at the level of the 10th thoracic spine. The patient at once lost all power and sensation in the lower limbs, and for a week had retention of urine requiring catheter. After a few days, sensation began to return in the lower limbs, but they still remained powerless.

When examined four weeks after the injury, there was loss of sensation to cotton-wool touches in the right lower limb, front and back, as high as the groin. To pin-pricks and temperature there was loss of sensation in both lower limbs and in the lower part of the abdomen, whilst an area on the back of the thighs, together with the genitals, retained normal sensation (see Fig. 270). Joint-sense was lost at the toes, ankles, and knees, normal at the hips.

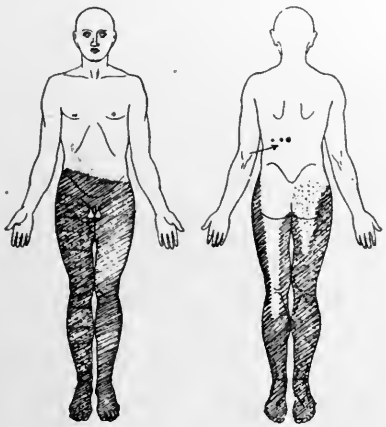

FIG. 270. — Incomplete transverse lesion, with escape of lower sacral root-areas.

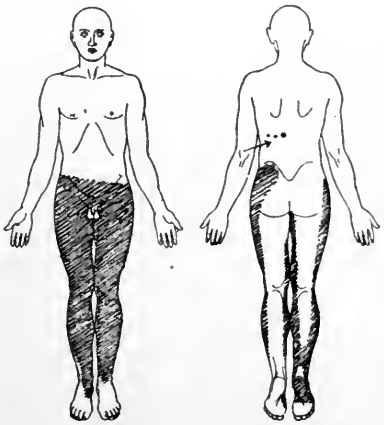

FIG. 271.—The same case as Fig. 270, showing further recovery of sacral root-areas.

The lower abdominal muscles were paralysed, so that the umbilicus was pulled upwards on attempting to sit up. There was total flaccid paralysis of all the muscles of the lower limbs, except of the adductors of both thighs and the left sartorius, which contracted feebly.

The knee-jerks were normal; there was ankle clonus on the left side only; the right ankle-jerk was normal. The plantar reflexes were both extensor in type. The sphincters were normal.

The cerebro-spinal fluid was clear and colourless, containing one lymphocyte per cubic millimetre.

The signs and symptoms gradually improved, so that a month later (see Fig. 271) the area of analgesia and therm-anæsthesia had further receded, and the sensory loss corresponded to the root-areas from the 12th thoracic to the 5th lumbar inclusive, the areas below that level having almost entirely recovered. Together with this, there was a return of motor power in all the muscles of the lower limbs, although the patient was not yet able to walk. There was knee clonus and ankle clonus on both sides, and the plantar reflexes were extensor as before.

Cases like the foregoing, owing to their peculiar area of cutaneous anæsthesia, might readily be confounded with lesions of the upper roots of the cauda equina, but are distinguished by the presence of medullary signs, such as increase of the knee- and ankle-jerks with the presence of clonus, the extensor type of plantar reflexes, and the absence of muscular atrophy.

Much less frequently an incomplete transverse lesion spares the antero-lateral columns and damages mainly the posterior columns. If such a lesion is above the cervical enlargement, the residual signs are those of ataxia of the upper and lower limbs together with loss of joint-sense and vibration-sense (both of which are conducted upwards exclusively in the posterior columns), but without motor paralysis, since the lateral columns are intact. The superficial reflexes remain normal, whilst the deep reflexes are diminished or lost.

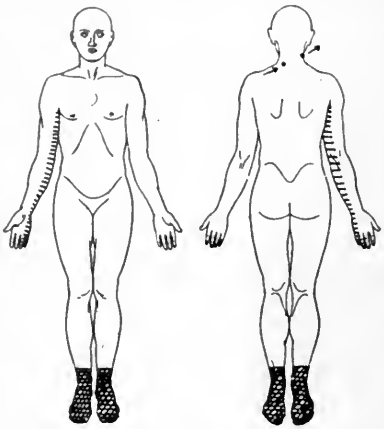

FIG. 272.—Transient lesion of spinal cord in right cervical region. The patient also had trench-feet.

We may also have slight contusion with transient œdema of the spinal cord without anatomical interruption of any of its fibres. In such cases the patient, after an initial stage of total paraplegia, makes a good recovery, as in the following example:—

A young officer, aged twenty-one, had a bullet-wound which entered 1½ inches to the left of the middle line at the level of the 7th cervical spine. The exit was immediately behind the right sterno-mastoid muscle, 1½ inches below the tip of the mastoid process.

When hit, the patient immediately fell forwards, but with the sensation of falling very slowly. He was not unconscious. At first he was unable to move any limb, but within a few minutes he found he could move his head freely. Within a day motor power began to return in all the limbs, except the right upper extremity. There was no sphincter trouble from the outset. When admitted on the second day to a hospital ship, he was found to be suffering also from a mild degree of trench-feet, resulting from exposure to cold and damp after being wounded. Both feet were swollen, especially the right foot, and the right hallux shortly developed a small black necrotic area at the tip of its distal phalanx.

On examination thirteen days after the injury, the pupils and cranial nerves were normal. To cotton-wool touches there was comparative blunting of sensation along the inner side of the right upper limb (see Fig. 272), including 1½ ulnar fingers. To pin-pricks there was no loss in the upper limbs or trunk, but in the feet there was total analgesia up to 3 inches above the ankles, obviously resulting from the trench-feet. Vibration-

sense was everywhere normal. Joint-sense was lost in the right little finger only.

In the right upper limb there was total paralysis of the triceps, extensors of the wrist, fingers and thumb, and of all the intrinsic hand muscles. The supinator longus and latissimus dorsi were paresed; all the other muscles of the limb were normal. The left upper limb, together with the diaphragm, intercostals, spinal and abdominal muscles, and the muscles of the lower limbs, were normal in their movements, save for some paresis of the toes and ankles, especially on the right side. Both feet, especially the right, were œdematous.

The biceps-jerks and triceps-jerks were absent; the knee-jerks and ankle-jerks were brisk. The plantar reflexes were absent; the abdominal reflexes were faint. The sphincters were normal.

To faradism all the muscles of the upper and lower limbs reacted briskly, including the paralysed muscles of the right upper limb.

A week later the cutaneous anæsthesia had cleared up in the right upper limb, although joint-sense was still absent in the little finger. The triceps, supinator longus, and extensors of the wrist all contracted feebly; the extensors of the fingers were still paralysed. The biceps-jerk and triceps-jerk were still absent in the right upper limb, but had reappeared in the left.

Lesions of the **cauda equina** from bullet-wounds tend to be less symmetrical than civilian injuries (see p. 229), but otherwise present no essential difference. Their diagnosis is usually easy.

The commonest war-injury of the cauda is a hæmorrhage compressing its constituent roots. The symptoms, beginning as a complete flaccid paraplegia, usually clear up, asymmetrically, as the hæmorrhage or inflammatory material becomes absorbed. Motor signs are generally more severe and wider-spread than sensory, and bladder troubles are always prominent. The following are illustrative examples:—

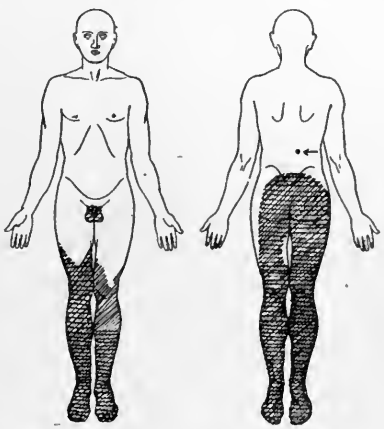

Fig. 273.—Lesion of cauda equina.

The patient, aged twenty-four, was struck by a shrapnel-bullet which entered the back 1½ inches to the right of the middle line at a level between the second and third lumbar spines. He immediately lost power, both motor and sensory, in the legs, and during the first week had intermittent dribbling of urine, which subsequently cleared up, so that he became able to initiate micturition by compression of the abdominal muscles. During the first two days after the injury he had severe pains in the calves of the legs. A radiogram showed the shrapnel-bullet within the body of the second lumbar vertebra.

On examination, two and a half weeks after the injury, there was no

abnormality save in the lower limbs. The abdominal muscles were powerful, and he could sit up without using the upper limbs. To pin-pricks there was total analgesia of the lower limbs, from the level of the third lumbar roots downwards (see Fig. 273), including the genitals. To cotton-wool touches there was anæsthesia in the same area, save in the front of the left thigh and knee. Joint-sense was preserved in the left hip-joint and lost in all other joints of both lower limbs. Vibration-sense was lost in the bones of the lower limbs, except in the left femur. There was total flaccid paralysis of both lower limbs, except in the sartorii, with loss of faradic excitability in all the muscles, save in the sartorii and in the left quadriceps extensor. The knee-jerks and ankle-jerks were absent, also the plantar, bulbo-cavernosus, and superficial anal reflexes. The abdominal reflexes were brisk. There was a healed bed-sore over the sacrum. A few days later, voluntary power returned in the left quadriceps extensor. Apart from this, the patient's condition remained unchanged, when he left for England two weeks afterwards.

The next case is an example of a right-sided cauda equina lesion of much more limited extent: —

Fig. 274. — Limited right-sided cauda equina lesion.

The patient, aged twenty-four, was wounded by a shrapnel-bullet which entered 1½ inches to the right of the fourth lumbar spine. A radiogram showed the bullet lodged between the laminæ of the third and fourth lumbar vertebræ. When hit, both lower limbs immediately became powerless, but within a few minutes he became able to move the left limb. The movements of the right hip and thigh also returned, but the right ankle and toes remained powerless. He had subjective tingling of the right limb from the thigh downwards, which subsequently receded to the right sole. There was retention of urine for the first four days.

On examination three weeks after the injury, there was no loss of cutaneous sensibility to cotton-wool touches, but to pin-pricks there was a small area of analgesia in the sole of the right foot (see Fig. 274). Joint-sense and vibration-sense were everywhere normal.

The movements of the left lower limb were powerful at all joints, also those of the right hip and knee. There was total paralysis of the right peronei, long extensors of the toes, and tibialis anticus, with drop-foot on that side. The right calf muscles and long flexors of the toes were feeble.

The left knee-jerk was brisk, the right absent. Both ankle-jerks were absent. The left plantar reflex was brisk and of normal flexor type; the right was absent. The cremasteric reflexes were brisk and equal. The bulbo-cavernosus reflex was absent. The sphincters were now normal.

To faradism there was diminution of excitability in the calf muscles and anterior tibial group on the right side, but no individual muscle failed to react. It seemed probable, therefore, that those muscles would soon recover. The patient was transferred to England a few days later, and passed out of observation.

Tetanus is met with in military practice much more commonly than in civil life. Although this disease is a general infection, it is

convenient to refer to it here, since its chief symptoms are due to irritation of the brain-stem, especially of the medullary and spinal motor nuclei, by the tetanus toxin.

The tetanus bacillus is anaerobic. It gains entrance through some septic wound, sometimes from a projectile, sometimes from the necrotic variety of "trench-foot," the infection being almost invariably carried by manure-infected dust or soil. It flourishes amongst the sloughing débris in a lacerated wound, where its growth is favoured by the presence of suppurative organisms. The clinical symptoms are produced, not by the tetanus bacillus directly, but by its toxin. This spreads upwards, not by the blood-stream, but from the muscle end-plates at the seat of injury, along the motor nerves, to the motor nuclei of the brain-stem. The motor nuclei governing the muscles in the region of the wound are the earliest to be affected.

In cases which have had a protective injection of tetanus-antitoxin administered shortly after the occurrence of a wound, the clinical course of the disease is profoundly modified. In a large proportion of cases no tetanic symptoms whatever supervene. In others, a partial immunity is produced by the antitoxin, so that the bulbar centres are protected and generalised tetanic symptoms remain absent, but we may have a modified, "post-seric," or **local tetanus.**[1]

Thus in wounds of the head, face, or orbit, we may have a localised *cephalic tetanus*, with tonic spasm of the facial, ocular, mandibular, pharyngeal, or lingual muscles, to which may be superadded painful clonic spasms. This condition may culminate in diaphragmatic spasm, with dyspnœa and even asphyxia. Cephalic tetanus is often accompanied by unilateral paralysis of the facial muscles on the same side as the wound; yet even in such cases the facial spasms may be bilateral. If the patient survives, this unilateral facial paralysis may last for days or weeks, but ultimately clears up.

In wounds of the limbs, in which antitoxin has been given, but not early enough or in sufficiently powerful doses to secure complete immunity, the earliest tetanic phenomena tend to appear in the muscles near the original wound. These muscles develop a persistent tonic rigidity, together with exacerbations of painful spontaneous local clonic twitchings, and increased reflex irritability to gentle tapping. If trismus (or spasm of the jaw-muscles) remains absent, this indicates that the antitoxin has succeeded in preventing the fixation of the poison in the bulbar centres and the prognosis is correspondingly better. If trismus supervenes, the prospect is less favourable.

A third variety of local tetanus is *splanchnic tetanus*, following wounds of the abdominal or thoracic viscera, and even occurring after

[1] Burrows, *Lancet*, January 27, 1917, p. 139.

operations for intestinal diseases, in patients who have swallowed tetanus spores. In such splanchnic cases, which are almost invariably fatal, the spasms are limited to the muscles of deglutition and respiration, the patient dying from respiratory spasm within one or two days after the onset of symptoms.

Tetanus bacilli, after a wound, may remain latent in the tissues for months, or even years, until a subsequent operative intervention, or a fresh traumatism, liberates the spores which have been shut up in the scar-tissues or encysted around some foreign body, and produces a long-delayed local tetanus or even a generalised tetanus-toxæmia.

In **generalised tetanus-toxæmia** all the muscles become poisoned, but the motor nuclei which have the shortest motor nerves are reached earliest by the toxin and thrown into a state of intense excitability. Thus the jaw, facial and cervical muscles, are usually the earliest to show tetanic spasms; later the spinal and abdominal muscles; and last of all the limbs. Occasional exceptions to this rule occur. The time required for the toxin to travel from the end-plates to the motor nuclei constitutes the period of incubation, varying from a day or two to nearly three weeks. The longer the incubation period, the better is the prognosis.

In generalised tetanus-toxæmia, after a premonitory stage of general nervous irritability and change of character, the patient complains of stiffness of the muscles of the neck or jaws. Tonic spasm gradually supervenes in the affected muscles, producing lockjaw or *trismus*, stiffness of the neck, and rigid spasm of the facial muscles (*risus sardonicus*), the angles of the mouth being drawn outwards and the eyebrows raised. Gradually the trunk muscles become affected, producing rigidity of the abdomen and spine. The muscular spasm varies in intensity from time to time. During the frequent paroxysms of increased spasm there may be opisthotonos, head retraction, and aggravation of the facial and mandibular spasm. These paroxysms last from a few seconds to several minutes, and even in the intervals between them the muscles do not completely relax. The slightest stimuli, *e.g.* touching the patient, loud noises, bright light, etc., precipitate the paroxysms. Tetanic muscular cramps are associated with intense pain. There is no anæsthesia nor true motor paralysis. The deep reflexes are increased. The patient sweats profusely. His temperature may be normal throughout; more often there is fever, sometimes of a high degree.

In fatal cases death may be due to respiratory or laryngeal spasm, to heart-failure, or to exhaustion. Sometimes death occurs from heart-failure days after the temperature has become normal and the spasms have ceased. The symptoms, in cases of recovery, may

gradually subside in a week, or the tetanic spasticity may last as long as a couple of months. Patients who survive ten days or a fortnight from the original onset of the spasms generally recover.

The condition has to be distinguished from strychnine poisoning. In tetanus, between the spasms there is not complete relaxation of the affected muscles; they remain tonically contracted, unlike strychnine poisoning, in which there are complete intermissions, and in which there is no muscular rigidity between the spasms. Moreover, in strychnine poisoning the fingers and hands are earliest affected, not the jaws or face.

WOUNDS OF THE PERIPHERAL NERVES

War-lesions of the peripheral nerves are extremely common. For example, Captain Arthur Evans and myself had under our personal observation within a single year exactly 300 cases. Of these:

172 (or 57·3 per cent.) were in the nerves of the upper limbs, inclusive of brachial plexus lesions.

81 (or 27 per cent.) in the lower limbs, inclusive of cauda equina lesions.

42 (or 14 per cent.) were cranial-nerve palsies.

The lesions produced by war-injuries of peripheral nerves are of various kinds.

1. **The nerve may be completely divided** by a missile or by a bayonet or sword wound. In such cases there is immediate and complete loss of function of the nerve, with sensory and motor paralysis in the area of distribution of the fibres below the level of the lesion. The paralysed muscles undergo atrophy. Atrophic changes may also develop in the skin, hair, and nails within the cutaneous distribution of the nerve and the bones of the hand or foot undergo partial decalcification. This can be demonstrated by taking radiograms and comparing the affected with the unaffected limb. The symptoms remain stationary, and show no tendency to improve, despite assiduous treatment.

Sometimes the severed ends of the nerve retract, leaving a gap between the upper and lower segments, which becomes filled up by dense scar-tissue. In the course of a few weeks a bulbous swelling, or false neuroma, forms on the stump of the proximal segment of the divided nerve, whilst the distal segment of the nerve, the part below the level of the lesion, becomes thin and wasted. Partial regeneration of nerve-fibres may subsequently occur in this un-united distal segment, but regeneration of this sort is imperfect, and, so long as the nerve-fibres of the proximal segment have not been united to those of the distal segment by operation, it remains incomplete. Meanwhile the sensory, motor, and trophic phenomena in the paralysed parts remain as before.

The following is an example of total division of the ulnar nerve above the wrist:—

A soldier, aged twenty-one, when disarming a party of German prisoners, was shot by one of them at point-blank range. He sustained a large lacerated wound in the lower third of the left forearm at its ulnar edge. A radiogram showed that about an inch of the ulna was missing close above the head of the bone. The lowest part of the ulna, however, together with the wrist-joint, remained uninjured. Ever since the injury, the patient had noticed weakness and loss of feeling in the hand.

When examined six months later, the original wound of the forearm was soundly healed. There was anæsthesia of one-and-a-half ulnar fingers and of the corresponding portion of the hand, front and back. The area of cotton-wool loss was slightly more extensive than that to pin-pricks or to deep pressure. Joint-sense was lost in the two ulnar fingers.

Fig. 275.—Complete division of the left ulnar nerve above the wrist.

The hand was in the characteristic claw-hand position, with inability to extend the inter-phalangeal joints. The fingers were semi-flexed, most markedly the two ulnar fingers, whilst there was slight hyper-extension of the metacarpo-phalangeal joints (see Fig. 275). The long flexors and extensors of the fingers, however, still contracted voluntarily. Abduction and opposition of the thumb were normal, since the thenar muscles, innervated by the median nerve, were unaffected. The interossei and hypothenar muscles were wasted and paralysed, so that spreading out the fingers was impossible (Fig. 275).

There was a small trophic blister on the dorsum of the little finger, over its proximal inter-phalangeal joint. The hand sweated excessively on the palm, except in the ulnar area, which remained dry.

2. **The nerve may be partially divided.** In such cases the symptoms of paralysis are partial, corresponding to the particular fibres which have been divided. Here also a neuroma forms on the partially divided nerve, at the side corresponding to the severed portion. The distal

fibres, in this case, being attached laterally to the uninjured part of the nerve-trunk, cannot retract. The histological changes, however, consisting of degeneration followed by regeneration, are the same as in a divided nerve.

In cases of partial division, especially of the median and internal popliteal nerves, burning pain (thermalgia) is a common symptom. It is referred to the corresponding area, usually of the palm or sole, and is sometimes of great intensity. Hypertrophic changes in the skin, hair, and nails are not uncommon. Hyperkeratosis, or excessive growth of epithelium, is occasionally a marked feature (see Fig. 277). In some cases there is excessive sweating, and in others excessive dryness, of the area of skin supplied by the partially divided nerve (see p. 291), depending on whether the arteries innervated by the affected nerves are in a state of vaso-dilatation, or later, undergoing narrowing from end-arteritis.

The following is an example of partial division of the median nerve in the lower part of the forearm:—

A sergeant-major, aged thirty-eight, was wounded in the right forearm at a range of about twenty yards. The entry wound was two-and-a half inches above the styloid process of the radius, the exit was three inches above the styloid process of the ulna, both wounds being on the flexor aspect of the forearm. The bones were not fractured.

Ever since the injury, the patient observed deficiency of sensation on the front and back of the thumb, index, and medius, and in the corresponding portion of the palm. He also had difficulty in completely flexing the index and medius.

Four weeks after the injury he began to have severe pain in the thumb and thenar region, also in the index; the pain was constant and burning in character, aggravated by moisture, *e.g.* on washing the hands.

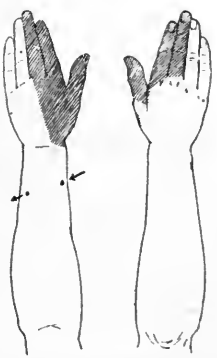

Fig. 276.—Case of incomplete lesion of the median nerve in the lower part of the forearm.

On examination, thirty days after the injury, the scars of the entry and exit wounds were as above described. Deep pressure in the forearm, midway between the wounds, caused a thrill to be felt in the thumb, index, and medius. To pin-pricks and cotton-wool touches there was loss of sensation on the palmar aspect in the thumb, index, and medius, and in the corresponding portion of the palm. On the dorsal aspect there was anæsthesia of the same three digits up to the metacarpo-phalangeal joints (see Fig. 276). Joint-sense was normal in all the digits. There was astereognosis in the anæsthetic fingers, as tested by a chain and a coin; with the two ulnar fingers stereognosis was perfect.

Flexion of all the digits was possible, but distinctly weaker in the index and medius than in the thumb, ring, or little finger. The thumb movements could be freely executed in all directions, although the thenar muscles were flabby. The interossei were normal.

To faradism all the muscles of the forearm and hand reacted briskly.

As an example of hyperkeratosis from a partial nerve lesion the following case of punctured wound of the ulnar nerve may be taken:—

The patient, aged twenty, during a voyage on board a transport in the Mediterranean, was carrying an empty soda-water bottle when the ship suddenly gave a violent roll. He fell, the bottle broke, and a fragment of glass penetrated the palm of his left hand between the thenar eminence and the pisiform bone. Ever since the injury he had been unable to extend the inter-phalangeal joints of the two ulnar fingers, and noticed deficient sensation in the ulnar area of the hand.

Fig. 277.—Hyperkeratosis of palm from partial ulnar nerve lesion.

When examined two months later, there was total anæsthesia to cotton-wool and pin-pricks in the front of one-and-a-half ulnar fingers and the corresponding portion of the palm (see Fig. 278). The dorsum was anæsthetic only over the fifth metacarpal bone (the dorsal cutaneous branch of the nerve having been given off above the level of the lesion). Joint-sense was lost in the little finger.

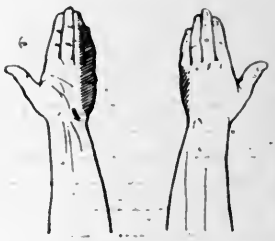

Fig. 278.—Area of anæsthesia in the case of ulnar palsy shown in Fig. 277.

There was a slight claw-hand, the two ulnar fingers being habitually semi-flexed at the inter-phalangeal joints and slightly hyper-extended at the metacarpo-phalangeal joints. There was moderate wasting of all the interossei. The thumb movements were normal. He could feebly spread out the index and little fingers, but not the middle or ring finger. Extension of the inter-phalangeal joints of the fingers was impossible. To faradism the thenar muscles all reacted normally, whereas there was no reaction in the interossei. There was marked hyperkeratosis of the ulnar side of the palm and two ulnar fingers, also extending slightly, in a patchy fashion, along the outer side of the palm (see Fig. 277).

3. **The nerve may be contused,** and thus "physiologically" interrupted, without being anatomically divided. Blood is extravasated within and around the unsevered nerve-sheath, compressing the nerve-fibres within, and causing pain referred to the cutaneous territory of the nerve. In severe contusion the nerve-fibres undergo degeneration, just as if they had been divided by a cutting or lacerating force, and it

may be difficult or impossible on clinical evidence alone to decide whether there is anatomical severance in addition to physiological interruption. Later, as the blood becomes absorbed, a dense fibrous scar may form within and around the nerve, maintaining the irritation and pain. Spontaneous regeneration of the nerve is sometimes impossible. In less severe cases, however, spontaneous recovery occurs within a few days or weeks, without the nerve-fibres having undergone degeneration. The preservation of normal electrical reactions, together with rapid recovery from initial anæsthesia, are indications that the lesion is likely to recover spontaneously.

The following is an illustrative example of contusion of the musculo-spiral nerve:—

The patient, aged twenty-two, was wounded by a bullet which traversed the left upper arm, entering through the middle of the triceps and emerging at the outer side of the biceps about two inches higher up. The bullet-track thus crossed the limb at right angles to the musculo-spiral groove (see Fig. 279). The humerus was not fractured. Drop-wrist immediately supervened, together with a subjective sensation of discomfort referred to the dorsum of the hand at the radial side.

Fig. 279.—Bullet-wound of musculo-spiral nerve, showing entrance and exit wound, together with the resulting drop-wrist. (The dark line crossing the picture above the level of the wound is the shadow of a vertical bar behind the patient.)

On examination seven days after the injury, there was slight comparative blunting to cotton-wool touches and pin-pricks on the radial side of the hand and fingers, too indefinite to be charted. Joint-sense was normal in all the digits. There was drop-wrist, with total paralysis of the extensors of the fingers, wrist, and thumb, also of the supinator longus. All the other muscles of the limb contracted normally. To faradism all the muscles reacted briskly, including the paralysed muscles.

The hand was placed on a dorsiflexion-splint, and within a week the motor paralysis disappeared.

The next case is a still slighter example of contusion of the musculo-spiral:—

A soldier, aged twenty-six, was wounded by a small fragment of shell which entered the left arm an inch above, and half an inch in front of, the external condyle. There was no wound of exit, but the metallic fragment could be felt subcutaneously, half an inch higher up the limb, internal to the inner edge of the biceps.

Immediately after he was wounded the wrist dropped, and this wrist-

drop was still complete when he came under observation eight days later. Ever since the injury he had complained of a constant subjective pain on the dorsal aspect of the metacarpo-phalangeal joint of the index finger, spreading round the web of the thumb to the dorsum of the terminal phalanx of the thumb. This pain was of a scalding character, aggravated by light touches of the part, and also by coughing or sneezing. It was somewhat relieved by warmth. Washing in cold water aggravated the pain.

Five weeks after the injury, no cutaneous anæsthesia or analgesia could be detected on careful testing. The motor paralysis had completely cleared up, and all the muscles reacted normally.

The following is a good example of contusion of the popliteal nerves and vessels, without any external wound whatever:—

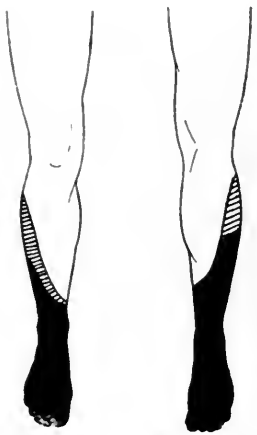

Fig. 280.—Anæsthesia in a case of contusion of the popliteal nerves of the right lower limb, without any external wound.

A gunner, aged twenty-seven, when standing beside his gun, was struck at the back of the right knee by a large, smooth fragment of prematurely exploded shell fired from a howitzer-battery a quarter of a mile to his rear. No cutaneous wound or abrasion was produced. He was knocked down by the blow, and, on trying to get up, found he could not stand. The right leg immediately began to swell from the knee downwards, and he had aching, burning pain in the foot and leg.

When admitted to hospital, eight days later, there was much œdema of the right leg and foot. Nevertheless the posterior tibial artery could be felt pulsating behind the internal malleolus. The œdema lasted for nearly four weeks. When it subsided, the patient found himself unable to dorsiflex the right ankle.

On examination, five weeks after the injury, a mass of deep-seated induration could be felt in the popliteal space behind the head of the right fibula. It was not pulsatile. To cotton-wool touches there was anæsthesia of the right foot and leg, except at its inner side, front and back (see Fig. 280). Pressure pain was not felt in the anæsthetic area. To pin-pricks the area of loss was less extensive than that to cotton-wool. Joint-sense was normal.

The patient could invert, evert, and extend the ankle, but was unable to dorsiflex the ankle or make any voluntary movement of the toes. The knee-jerks and ankle-jerks were brisk and equal. Both plantar reflexes were present, flexor in type, despite the apparent paralysis of the right toes.

To faradism there was no reaction in the peronei, tibialis anticus, or extensors of the right toes. All the other muscles of the leg and foot, including the long flexors of the toes, reacted normally.

Five weeks later, anæsthesia had disappeared from the territory of the internal popliteal, and was now confined to the dorsum and outer side of the foot and leg. Voluntary flexion of the toes had recovered, whilst feeble extension of the toes was just beginning.

4. **The nerve may be "concussed,"** *i.e.* it undergoes a sudden molecular change whereby temporary paralysis occurs, both of its sensory and motor functions. Nevertheless its nerve-fibres are undivided, and within a short time complete restitution of function sets in, sometimes within a few hours, in other cases only after several days.

5. **The nerve may undergo gradual compression,** *e.g.* by a tourniquet, or by displaced bony fragments, or by the formation of callus around a healing fracture. In such cases recovery cannot be expected until the compression is relieved. The area of cutaneous analgesia to pin-pricks is usually more extensive in these cases than the area of cotton-wool loss (see p. 200).

The following is an illustrative example:—

A soldier, aged thirty, was hit in the region of the right shoulder by a bullet which entered two-and-a-quarter inches below the tip of the acromion process. There was no wound of exit, but a metallic fragment could be felt under the skin at the back of the arm, three inches above the olecranon process. The humerus was fractured. The patient's arm dropped powerless at the moment of injury, and the wrist is said to have dropped at the same time.

When examined, two-and-a-half months later, the fracture had become firmly united, and there was a mass of callus easily felt in the region of the musculo-spiral groove. To pin-pricks there was an area of analgesia of the dorsum of the hand and of the 3½ radial digits, except on their terminal phalanges. Joint-sense was everywhere normal. There was paralysis and loss of faradic excitability in the supinator longus and in the extensors of the wrist, thumb, and fingers. All other muscles of the arm, forearm, and hand were normal.

On exposing the musculo-spiral nerve in the upper arm, it was found embedded in bony callus and fibrous tissue. The nerve-trunk had not been divided. At one point, however, there was a well-marked stricture of fibrous tissue, strangling the nerve. The callus was chiselled away, the nerve was freed from its bony groove, the fibrous constriction was dissected off, and a small portion of triceps muscle was fixed between the nerve-trunk and the bone, to prevent future implication by fresh bony callus.

6. **The nerve may be stretched or even ruptured** by a powerful tearing force, applied at a distance from the actual point which gives way. This sort of injury may result from a sudden wrench, as when a soldier is hurled against a stony surface by a shell-explosion, landing on the top of his shoulder and lacerating some of the roots of the brachial plexus. Less frequently similar laceration of nerve-fibres may occur as a result of sudden muscular exertion. The following is an illustrative case:—

A soldier, aged twenty-five, a man of powerful physique, a blacksmith in civil life, was engaged one day in pier-building on the Gallipoli Peninsula, when, during an effort to raise a heavy stone, he felt a sudden pain above the right scapula, and immediately had difficulty in raising his right upper limb above his head. This weakness increased and attained its maximum

within a couple of days. A moderate degree of pain also persisted around the right shoulder region.

When examined a month later, he had isolated paralysis of the right trapezius, except in its uppermost, clavículo-acromial, fibres (which are supplied exclusively by the spinal accessory proper). The middle and lower fibres (innervated by the 3rd and 4th cervical roots, which help to form the sub-trapezial plexus) were completely paralysed and inactive to faradism. All the other muscles of the shoulder-girdle, and the serratus magnus in particular, contracted normally and gave brisk responses to faradism. There was an area of analgesia to pin-pricks at and below the tip of the right shoulder, corresponding to the territory of the 4th cervical nerve.

The scapula showed the typical posture of trapezius paralysis, being displaced outwards and downwards *en masse*, and also rotated, so that its lower angle was tilted inwards. Together with this there was marked

FIG. 281.—Paralysis of third and fourth cervical nerves of right *sub-trapezial plexus*, showing winging of scapula from trapezius palsy. The area of sensory loss at the tip of the shoulder is also indicated.

winging of the scapula on raising the arm horizontally in front of the trunk (see Fig. 281). At the beginning of this movement, if observed from the front, the tip of the right scapula could be seen displaced upwards by the unopposed action of the levator anguli scapulæ, no longer antagonised by the lower fibres of the trapezius.

In this case the lesion is obviously one of the sub-trapezial plexus, of which the 3rd and 4th cervical nerves have become completely paralysed, the spinal accessory proper, or at least those of its fibres which innervate the uppermost fibres of the trapezius, having escaped.

7. **The nerve may become inflamed.** This form of interstitial neuritis is occasionally due to septic infection of the wound. It may also occur, however, without obvious signs of infection, *e.g.* owing to the nerve becoming entangled in callus or scar-tissue. A complication of this sort retards all the processes of repair or regeneration, no

matter how mild the infection may be. In such cases of neuritis, in addition to the signs of a nerve-lesion, whether complete or, more often, incomplete, pain is a specially prominent feature. The pain of traumatic neuritis is usually continuous and intense. It is referred to the sensory distribution of the nerve, usually in the palm or sole, and is accompanied by marked cutaneous hyperæsthesia and by tenderness along the course of the nerve-trunk at and below the site of injury. The pain is of a burning character (thermalgia or causalgia). It is aggravated by dryness and heat, by light cutaneous stimuli, and even by sneezing or coughing, by emotion, or by any sudden movement of the body which causes a temporary rise in blood-pressure. It is somewhat relieved by cold and moist applications, and the patient tends spontaneously to keep his affected hand or foot swathed in moist bandages. Pain of this sort is specially common in wounds of the median and sciatic nerves.

The pain of a traumatic neuritis, in aseptic cases, sets in some ten days or a fortnight after the original wound. In septic neuritis pain may begin earlier than this. It gradually increases in intensity, and for several weeks remains at its maximum. Then it slowly diminishes and spontaneously disappears in the course of months. The natural course of these cases is important to bear in mind, since surgical intervention is unavailing, and relief must be sought from electrical, medicinal, or physical remedies, *e.g.* injection of alcohol into the nerve-trunk above the level of the original injury.

Clinically, these various classes of nerve-lesions are not always clearly marked off, one from the other. Although it is usually easy to say that a particular nerve has not been damaged, it is sometimes difficult, in the case of a paralysed nerve, to decide whether the lesion is an actual severance or only a contusion. Each case must be considered on its own merits.

In every case of motor paralysis from a peripheral nerve-lesion the electrical reactions (at a date not sooner than ten days after the original injury) should be carefully observed. The presence or absence of R.D. will have important significance, both in diagnosis and in prognosis. It is worth remembering that we may sometimes have electrical changes in muscles which are functionally active. In paralysed muscles which have lost their faradic response voluntary power usually reappears earlier than faradic excitability.

Cranial-Nerve Injuries.—Notwithstanding the great frequency of head-wounds, especially in trench warfare, cranial-nerve palsies are relatively less common than injuries of the spinal nerves. For every

case of cranial-nerve paralysis we meet with two cases of lesion of the nerves of the lower limbs and four cases of injury to the brachial plexus and its branches. This is easily understood. Most wounds which traverse the base of the skull are fatal, and only a small proportion of such patients survive to show cranial-nerve paralysis. In those which do survive, the lesion is almost always extra-cranial, *e.g.* from wounds of the orbit, face, mastoid region, or upper part of the neck.

The cranial nerve most frequently injured is the facial. Next in frequency, as seats of single nerve-lesions, come the trigeminal nerve and the spinal accessory. But it is a common occurrence for more than one nerve to be implicated in the same wound.

The symptomatology of individual cranial-nerve palsies is familiar, and has already been discussed in Chapters IX and X. It may be

FIGS. 282 AND 282A.—Radiograms showing bullet in outer wall of left orbit, producing ocular paralysis, proptosis, and chemosis.

useful, however, to mention a few illustrative examples of **multiple cranial-nerve injuries.**

Bullet-wound of orbit, with paralysis of ocular nerves and cavernous sinus syndrome:—

A soldier, aged twenty, was wounded by a rifle-bullet which entered the right side of the face half-an-inch below and internal to the malar eminence. There was no wound of exit. The patient felt nothing wrong until two days later, when the left eyelids swelled up (*i.e.* on the opposite side from the entry wound), so that he could no longer see with that eye.

When examined nine days after the injury, there was still marked œdema of the left upper lid, together with chemosis of the left conjunctiva and some sub-conjunctival hæmorrhage. The left eye was markedly proptosed, and its movements upwards, outwards, and inwards were restricted. Downward movement was good. There was diplopia in all positions of the eyes. The optic discs were normal. The pupils were equal and normal. The right eye was normal in all respects.

Radiograms (Figs. 282 and 282A) showed a bullet in the posterior part of the left orbit, close to its outer wall. It was subsequently successfully extracted through an incision in the temporal fossa, after removal of the outer wall of the orbit.

Combined lesion of trigeminal and facial:—

Fig. 283 shows a trooper who was struck by a fragment of shell, which entered behind the right pinna, immediately in front of the tip of the mastoid process, emerging close behind the right ala nasi.

When examined eight days after the injury, there was some ecchymosis under the right conjunctiva, below and to the outer side of the iris. There was an area of anæsthesia to cotton-wool touches and pin-pricks on the

FIG. 283.—Wound of right upper facial nerve and of right infra-orbital nerve. The arrow indicates the direction of the entry wound. The patient is looking upwards to display a subconjunctival hæmorrhage in the outer part of the right eye.

right cheek, and part of the right upper lip. There was no anæsthesia of the roof of the mouth, upper gum, or inner surface of lip. The masseters and temporals were powerful on both sides. The right facial muscles were distinctly weaker than the left, especially the frontalis muscle. This weakness was well seen when the patient looked upwards and wrinkled the forehead. The lower facial muscles were but slightly affected. All the other cranial nerves were normal. To faradism there was slight diminution of excitability in the right facial muscles.

The next case is one of combined lesion of the facial and of the palatal branch of the vagus:—

This patient, aged nineteen, was wounded by a shrapnel-bullet which entered through the tip of the right mastoid process. He states that the

bullet rolled out of his mouth. He did not become unconscious. His face at once became twisted (see Fig. 284).

When examined nine days after the injury, there was total right-sided facial paralysis, upper and lower, with complete loss of faradic excitability in the affected muscles. Taste was unaffected. Hearing was also intact, both to aerial and bony conduction. On phonation the palate was pulled upwards and to the left, and a shallow exit-wound was seen just to the left side of the base of the uvula. The right pinna projected abnormally from the side of the head, owing to swelling of the tissues around the wound of entrance.

FIG. 284.—Right-sided facial palsy from a bullet-wound entering through the right temporal bone and emerging through the mouth. The right side of the palate was also paralysed.

The following case is one of hypoglossal and cervical sympathetic paralysis, with transient paresis of the facial:—

A soldier, aged twenty-three, was wounded at Suvla by a bullet which entered through the left parotid region, an inch above and in front of the angle of the jaw. There was no exit-wound, but the bullet-track evidently passed downwards and inwards.

When examined ten days later, there was paralysis of the left side of the tongue, which, when protruded, deviated markedly to the left in a characteristic sickle-shaped fashion. There was also weakness of the left face, complete in the lower, partial in the upper muscles. To faradism there was loss of reaction in the whole of the left facial muscles and in the left half of the tongue. The parotid gland in the region of the entry-wound was swollen. The facial weakness rapidly cleared up, but the hypoglossal paralysis persisted, and in a few days it became evident that the cervical sympathetic had been damaged, as evidenced by the presence of pseudo-ptosis, enophthalmos, narrowing of the palpebral fissure, and contraction of the left pupil (see Fig. 285). The parotid swelling still persisted, and it was possible to express saliva through the wound.

Injuries of the Brachial Plexus and of its Branches.—More than half of all the cases of peripheral-nerve injuries in war belong to this group.

The brachial plexus is constituted by the anterior primary divisions of the four lowest cervical roots (the 5th, 6th, 7th, and 8th), together with the 1st thoracic root (see Fig. 286). It is unnecessary here to recapitulate the anatomy of the plexus, the details of which should be familiar to every student of neurology.

From the clinical standpoint, it is convenient to consider brachial plexus injuries in three classes:—

1. *Lesions above the clavicle*, affecting the nerve-trunks (upper, middle, or lower), or the nerve-roots from which these nerve-trunks are derived. In this class of case the signs and symptoms, both motor and sensory, tend to be distributed in a radicular fashion.

2. *Lesions lower down, in the region of the axillary vessels*, where the cords of the brachial plexus (inner, outer, and posterior) surround the axillary artery. In such cases the wound of the plexus commonly damages the great vessels at the same time.

3. *Lesions of the individual nerves* of the limb, after they have left the plexus. Some of these nerves (*e.g.* the median, ulnar, and internal cutaneous) accompany the brachial artery for part of its course; others (*e.g.* the musculo-spiral and circumflex) diverge from the main vessels, and are therefore less likely to be complicated by the occurrence of traumatic aneurisms.

Complete plexus paralysis is rare; partial plexus lesions are common. The following is an example of a wound in which the whole brachial plexus was paralysed, except its oculo-pupillary fibres:—

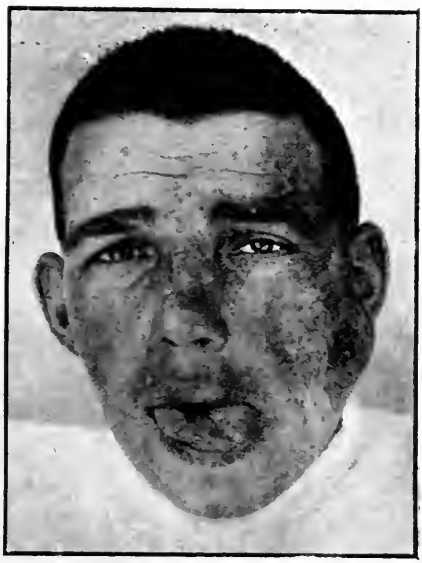

FIG. 285.—Wound of left parotid region, with combined paralysis of left hypoglossal and cervical sympathetic.

A soldier, aged twenty, was wounded by a bullet which entered immediately above the left clavicle, three-and-a-half inches from the middle line. There was no exit-wound. A radiogram showed the bullet lying in the left supra-spinous fossa. Immediately on being hit, the patient lost power in the left upper limb.

When examined two weeks after the injury, no pulsation could be detected in the axillary, brachial, or radial artery on the left side; nevertheless both hands were equally warm. To cotton-wool and pin-pricks there was anæsthesia of the whole of the upper limb, save for a small strip along the inner side of the upper arm, corresponding to the area innervated by the 2nd thoracic root (see Fig. 287). Passive abduction of the shoulder-joint caused pain; all other passive movements were unperceived. Joint-sense and vibration-sense were lost at all parts of the limb, from the shoulder downwards. The limb was flaccid and paralysed at all joints. The pectorals, spinati, latissimus, and all the muscles of the upper arm, forearm, and hand were completely paralysed, and gave no reaction to the faradic battery. The pupils and ocular fissures, however, were equal.

Supra-clavicular lesion of plexus, affecting 5th cervical root:—

A soldier, aged twenty-two, sustained multiple shrapnel-wounds of the head, right shoulder, and right knee. Of the fragments, one entered half an inch to the right of the 7th cervical spine and emerged through the outer pectoral region, two-and-three-quarter inches below the right clavicle. The right upper limb immediately became weak at the shoulder and elbow.

On examination ten days after the injury, there was anæsthesia to pin-pricks and cotton-wool on the outer aspect of the upper limb, in two

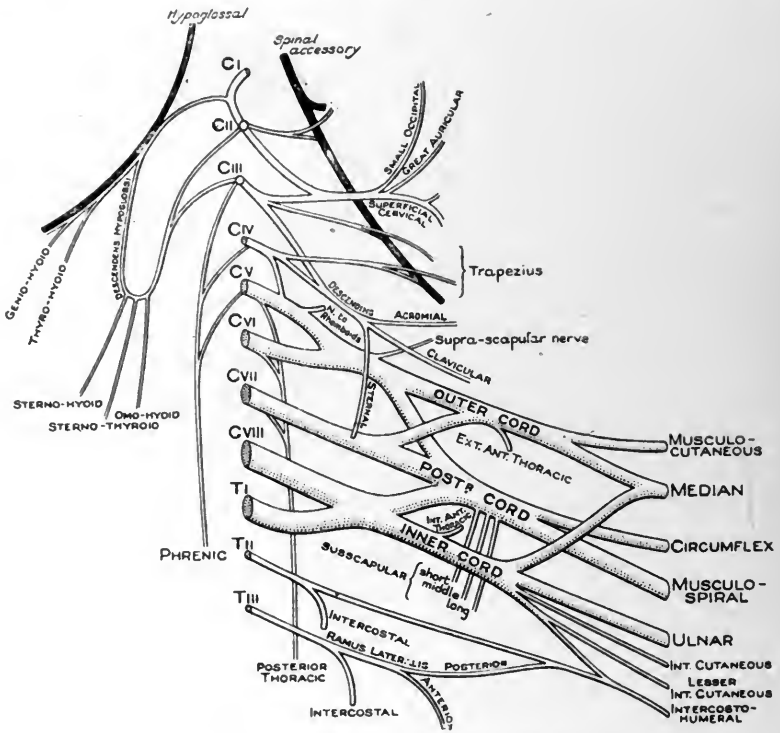

Fig. 286.—Diagram of cervico-brachial plexus.

areas corresponding to part of the territory of the 5th cervical nerve (see Fig. 288). All the muscles of the upper limb were powerful, with the exception of the deltoid, biceps, and supinator longus, which were totally paralysed. Nevertheless the elbow could still be feebly flexed by means of the extensor carpi radialis longior. The patient accomplished this by previously strongly pronating and deviating his wrist to the ulnar side, so as to give the muscle an advantage. To faradism there was loss of reaction in the deltoid and supinator longus, whilst the biceps reacted feebly. All the other muscles of the limb reacted briskly.

A week later the biceps had recovered, and there was now some voluntary contraction in the supinator longus. The deltoid, however, was still paralysed and the anæsthesia was as before.

Supra-clavicular lesion of plexus, affecting 8th cervical and 1st thoracic roots:—

An Australian soldier, aged twenty-five, was wounded by a bullet which entered posteriorly, half an inch to the right side of the middle

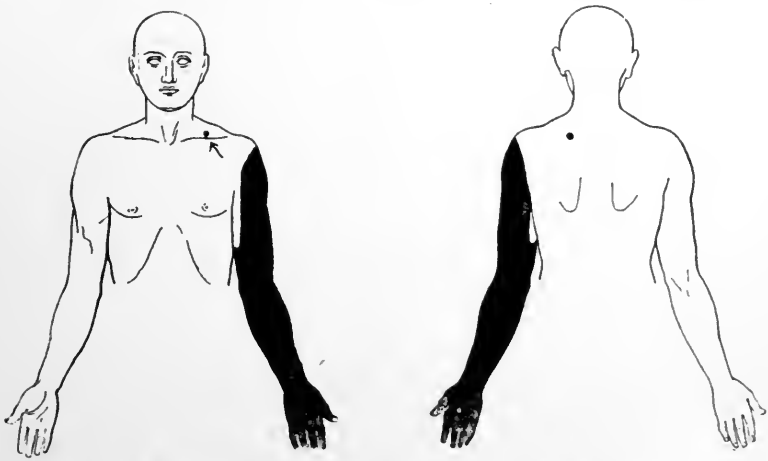

Fig. 287.—Supra-clavicular wound of left brachial plexus.

line, immediately below the tip of the 7th cervical spine, and emerged through the middle of the left sterno-mastoid muscle.

When examined ten days after the injury, there was an area of total

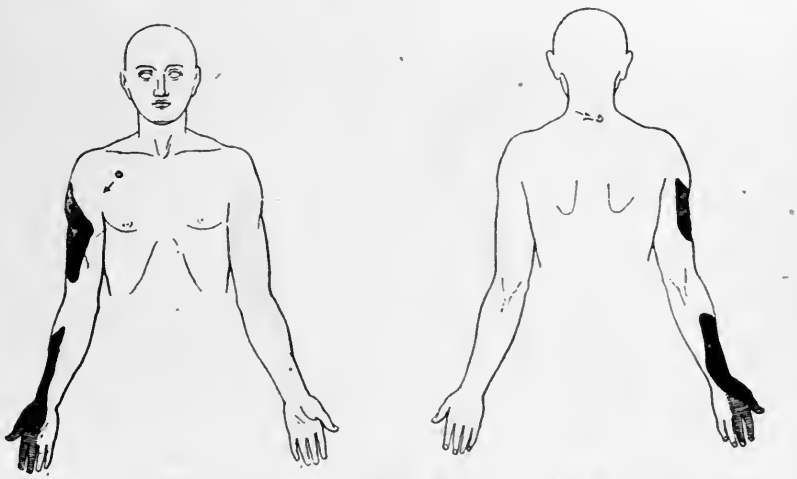

Fig. 288.—Supra-clavicular bullet-wound of brachial plexus, implicating 5th cervical root.

anæsthesia to all forms of cutaneous stimulation along the inner side of the left forearm and hand, including 1½ fingers on the palmar aspect and 2½ fingers on the dorsum (see Fig. 289). All movements of the scapula,

shoulder, elbow, and wrist were normal. The thumb was totally paralysed, also all the intrinsic hand-muscles. Flexion of the fingers was impossible, and extension was impaired, since only the long extensors came into action, unassisted by the interossei. To faradism there was no response in the

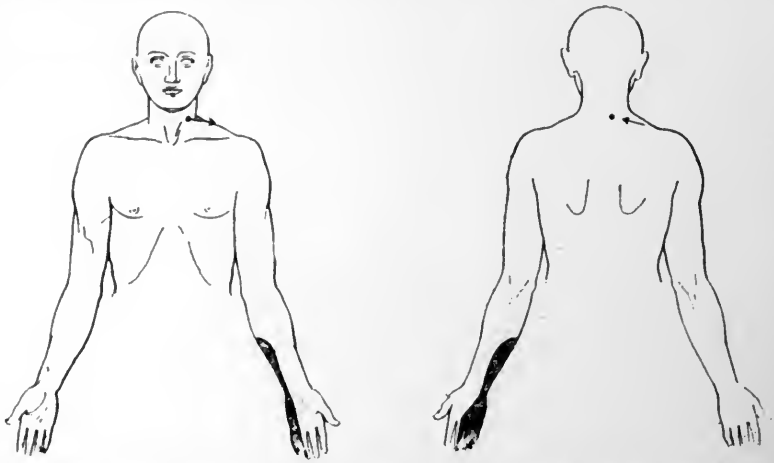

Fig. 289.—Supra-clavicular bullet-wound of left brachial plexus, implicating 8th cervical and 1st thoracic roots.

long flexors of the thumb or fingers, nor in the thenar, hypothenar, or lumbrical muscles, whilst all the other muscles of the forearm, upper-arm and shoulder-girdle reacted normally. There was no difference between the pupils or ocular fissures of the two sides.

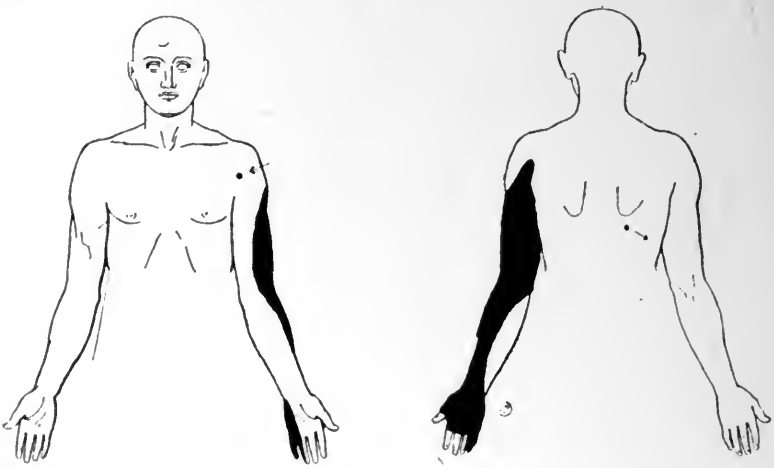

Fig. 290.—Wound of left brachial plexus and of axillary artery.

The following is an example of a brachial plexus lesion in which the axillary artery was wounded as well. The damage to the plexus implicated chiefly its posterior and inner cords. Owing to the develop-

ment of an axillary aneurism, ligation of the axillary artery was subsequently performed. This was followed by a slight increase in the extent of the motor paralysis, together with loss of faradic excitability in nearly all the muscles of the limb—a condition apparently due to ischæmic interstitial myositis (see later, p. 534).

The patient, aged twenty-eight, was wounded by a bullet which entered through the anterior part of the left deltoid and emerged four inches to the right side of the 8th thoracic spine, traversing the left lung *en route*. The left upper limb at once fell powerless to the side. When admitted to hospital in Malta, five days later, there was severe dyspnœa owing to a left-sided hæmothorax, from which 30 ounces of dark fluid blood were removed by aspiration.

Twelve days after the injury the dyspnœa had cleared up, and it was now possible to examine the left upper limb. This showed widespread anæsthesia, chiefly on its extensor aspect, but also in the ulnar distribution of the hand (see Fig. 290). Joint-sense was lost in the little finger; all other joints were normally sensitive. There was paralysis of the deltoid and triceps. The biceps was strong, and the latissimus dorsi contracted well on coughing. There was paralysis of the supinator longus, also of the extensors of the wrist, thumb, and fingers. The long flexors of the wrist, fingers, and thumb were feeble, but not completely paralysed. All the intrinsic muscles of the hand were paralysed. To faradism there was loss of reaction in the paralysed deltoid, triceps, supinator longus, and extensors of the wrist, thumb, and fingers, whilst the paralysed thenar, hypothenar, and interosseal muscles all reacted briskly, as did also the other non-paralysed muscles of the limb.

Fifteen days after the injury, the patient began to complain of aching pain in the limb, from the shoulder to the fingers, and on the nineteenth day a diffuse, tender swelling was found in the upper part of the left axilla, in front of the shoulder-joint. A pulsatile bruit was to be heard over this swelling. Both radial pulses, however, were easily felt, and there was little difference in the blood-pressure in the two brachial arteries, the measurement on the left side being 130/86 as compared with 138/86 upon the healthy side.

On the twenty-first day the axillary artery was exposed by Captain Camps, and an aneurism was found, occupying the third part of the axillary artery. There was an abnormally high bifurcation of the artery above the aneurism, which might perhaps account for the practically normal pulse below the aneurism. The vessel was ligatured above and below the aneurism and the clot turned out. The wound was septic, but with suitable drainage the patient made a steady recovery from the operation.

Eight weeks after the operation, the area of cutaneous anæsthesia was found to be unchanged, and there was loss of joint-sense in the little finger as before. There was now paralysis of the biceps and latissimus dorsi, which prior to the operation had contracted briskly. The paralysis of the deltoid, triceps, extensors of the wrist, fingers, and thumb, and of the intrinsic muscles of the hand, was complete as before, and there was well-marked wasting of the interossei. He could still flex the fingers and thumb. There was a curious change in the electrical faradic reactions. There was now no reaction in any muscle of the upper limb, from the pectoral downwards, except a feeble response in the interossei and thenar muscles and in the long flexors of the fingers. All the paralysed muscles of the upper-arm

and forearm were harder and tougher in consistence than normal, suggesting a condition of ischæmic palsy. The pectoral muscles, although not reacting to faradism, contracted well voluntarily. Both radial pulses could be

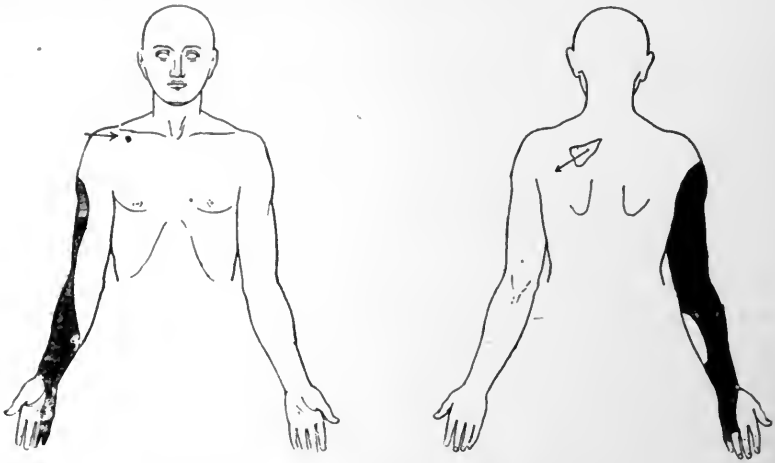

Fig. 291.—Bullet-wound of right brachial plexus.

felt equally well. The blood-pressure in the left brachial artery measured 124/84, as compared with 128/80 on the right side.

Fig. 292.—Bullet-wound of right brachial plexus. Although the biceps is paralysed, the patient can still flex the right elbow by means of the supinator longus.

The next case is one in which the brachial plexus lesion was mainly of the outer cord:—

The patient, an Australian sapper, aged twenty-eight, was wounded by a bullet which entered half an inch below the right clavicle, just internal to the coracoid process. The exit-wound was large and oblique, four inches long, in the left supra-spinous fossa, its upper end being an inch to the left of the 4th thoracic spine. The patient, when hit, felt his arm drop powerless at once, with the sensation as if he had received a blow on the back. There was no hæmoptysis. Within a day or two he found he could move his shoulder, but the hand remained weak and the whole limb remained numb.

When examined ten days after the injury, there was widespread anæsthesia and analgesia from the shoulder downwards, with the exception

of the inner side of the upper-arm and forearm, and the median and radial territories of the hand (see Fig. 291). Joint-sense was lost in all the digits except the thumb; normal at the wrist, elbow, and shoulder. All the scapular and shoulder muscles were powerful, also the triceps and extensors of the wrist, fingers, and thumb. The biceps and brachialis anticus were completely paralysed, but the elbow could still be fully flexed by the unparalysed supinator longus (see Fig. 292). The pronators were paralysed. The supinators were normal. The long flexors of the wrist, thumb, and fingers were paralysed, together with all the intrinsic muscles of the hand. The hand was habitually flexed at the two ulnar fingers, and lightly flexed at the medius and index. To faradism there was loss of reaction in the intrinsic hand-muscles, also in the long flexors of the fingers, thumb, and wrist, and in the pronators. The biceps reacted feebly; the extensors of the wrist and fingers, together with the triceps, deltoid, etc., all reacted briskly.

Injuries of the Cauda Equina.—The chief points of clinical importance in the diagnosis of lesions of the cauda equina and conus medullaris have already been referred to (see pp. 229-231 and Figs. 107 and 108), and it is unnecessary here to recapitulate them. Immediately after the injury, root-pains and paralyses make their appearance, and in almost every case the sphincters are affected. War-lesions of the cauda are generally asymmetrical.

It may be useful to add one or two illustrative examples of partial lesions, in which the damage was limited to a few roots of the cauda.

The following case is one in which the lesion was confined to the left half of the cauda equina, from the 5th lumbar root downwards:—

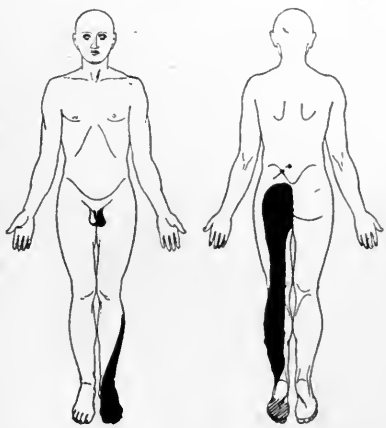

Fig. 293.—Unilateral lesion of cauda equina, with anæsthesia from level of 5th root downwards, on the left side.

The patient, an Australian gunner, aged twenty-five, was wounded by a rifle-bullet which entered half an inch to the left of the 4th lumbar spine. There was no exit-wound, but a radiogram showed the bullet lying, point downwards, to the right of the middle line, between the bodies of the 11th and 12th thoracic vertebræ.

When he was struck, his legs gave way, he "stiffened out" with transient extensor spasm, and was unable to stand or walk. The right lower limb was never paralysed, but the left limb was totally powerless at the start, and he also noticed it to be deficient in sensation. Within three days motor power began to reappear in the left toes. There was some delay in micturition at first, but a catheter was never required.

When examined ten days after the injury, there was loss of sensation to pin-pricks, and to cold and heat, in the left lower limb, including nearly all of its posterior aspect, the dorsum of the foot and outer side of the leg,

also the left side of the genitals. The inner side of the calf escaped, together with part of the sole of the foot. Joint-sense was lost at the left toes and ankle, normal at the knee and hip. Cotton-wool touches could be felt all over the analgesic area (see Fig. 293).

The sensory and motor functions of the right lower limb were normal.

There was marked weakness of the left lower limb in the quadriceps extensor and in the other anterior thigh muscles, also in the calf muscles, peronei, and anterior tibial group. The gluteal and adductor muscles were strong, also the hamstrings.

To faradism there was no reaction in the tibialis anticus nor peronei, the extensors of the toes reacted feebly, whilst all the other muscles of the limb gave a brisk reaction.

The left ankle-jerk was absent, the right was brisk. Both knee-jerks were diminished, especially on the left side. The bulbo-cavernosus reflex was brisk; the plantars were both absent; the abdominal reflexes were present, somewhat brisker on the right side than on the left.

Within a week further improvement had occurred, so that no individual muscles were now paralysed, though the peronei were relatively feebler than the rest, and the patient was still unable to raise the extended limb off the bed against gravity.

The next case illustrates a bilateral lesion of the upper part of the cauda equina, affecting on the right side the roots from the 2nd lumbar to the 1st sacral inclusive, and on the left side, less severely, the 5th lumbar and 1st sacral roots:—

An officer in a Highland regiment, aged thirty-two, took part in a gallant attack on a position, advancing by a succession of rapid rushes. When lying down between two of these rushes, he was shot in the trunk, the bullet entering through the 8th intercostal space on the right side, behind the posterior axillary fold. There was no exit-wound, but a radiogram subsequently showed the rifle-bullet to be lodged in the left hip-joint, with its point directed upwards.

When shot, he had a sensation as if the feet were curling up. He lost power at once in the right lower limb, *i.e.* on the same side as the wound of entry. The left lower limb felt "dead," but was capable of voluntary movement. The sphincters were not affected.

When he was admitted to hospital a week later, there was profuse hæmaturia, apparently of renal origin. Three weeks after the injury, owing to the presence of constant pain in the right loin, together with fulness in the region of the right kidney, Mr. Jocelyn Swan operated in that region and discovered a large collection of clear urine around the lower pole of the kidney, which had been lacerated. A bony spike was also found projecting laterally from the right side of the body of the 3rd lumbar vertebra. The patient made an uninterrupted recovery from this operation, and no further renal trouble occurred.

When examined eleven days after the original wound, there was total anæsthesia and analgesia of the right lower limb, from the 2nd lumbar to the 1st sacral root-areas inclusive. In the left lower limb there was moderate diminution to all forms of sensation in the distribution of the 5th lumbar and 1st sacral root-areas (see Fig. 294). Joint-sense was lost at all joints of the right lower limb from the hip downwards; in the left limb it was lost in the toes only.

There was total flaccid paralysis of the right lower limb at all joints. The left lower limb was feeble at all joints, but no individual movement was impossible. Both ankle-jerks and the right knee-jerk were absent; the left knee-jerk was present. The plantar reflexes were absent. The sphincters were normal.

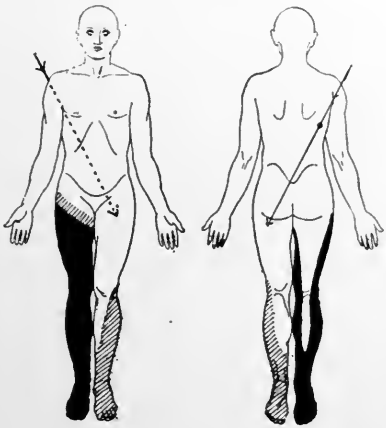

FIG. 294.—Lesion of upper cauda equina. Anæsthesia eleven days after the injury.

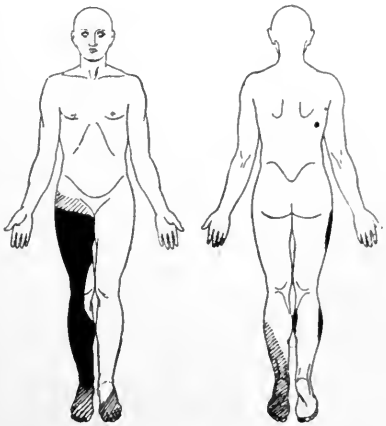

FIG. 294A.—The same case as Fig. 294. Anæsthesia eight months after the injury.

To faradism the right calf muscles reacted normally. There was no reaction in any other muscles of the limb, from the glutei downwards. All the muscles of the left lower limb reacted briskly.

About a month after the original wound, the patient developed inveterate pain in the right thigh, chiefly towards the inner side of the knee, and in the right ankle. This persisted for many months.

Gradual improvement set in, both as regards sensory and motor functions. Eight months after the injury the anæsthesia of the left limb had largely cleared up, although there was still an area of comparative blunting on the outer side of the leg and foot, corresponding to the 5th lumbar root. In the right lower limb the anæsthesia of the 2nd sacral area had receded from the back of the thigh and was no longer absolute in the 1st sacral area (see Fig. 294A). An area of intense cutaneous hyperæsthesia persisted at the inner side of the thigh, corresponding to part of the 3rd lumbar area.

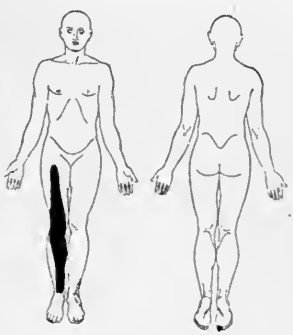

FIG. 294B.—The same case as Figs. 294 and 294A. Four years after the original injury.

Motor power also returned, completely in the left lower limb and partially in the right. The glutei and adductor muscles were the earliest to recover. The muscle which still remained severely paralysed was the right quadriceps extensor. All the other muscles of the right lower limb had recovered voluntary

movement, although the peronei and dorsiflexors of the ankle were relatively weaker than the rest. The right knee-jerk and both ankle-jerks were still absent, also the plantar reflexes.

When re-examined, four years after the original injury, further improvement had occurred. He was now able to walk without a stick. Voluntary extension of the right knee was good, but dorsiflexion of the right ankle was still very feeble and required the aid of an artificial spring in the boot. The left lower limb was powerful at all joints. There was moderate wasting of the right lower limb, best seen in the quadriceps and peroneal group of muscles, but no individual movement was paralysed.

The anæsthesia of the right lower limb had further receded (see Fig. 294B) to an area of the thigh and leg mainly innervated by the 4th and 5th lumbar roots, together with a small area on the plantar surface of the hallux (S_1 root). In the left lower limb there was only a small patch of comparative blunting at the outer side of the ankle. The patient still suffered from almost continuous pain in the back of both thighs, at the outer side of the right knee and ankle, and slightly in the left ankle. The cutaneous hyperæsthesia at the inner side of the right thigh was now much less intense.

The right knee-jerk and both ankle-jerks were still absent; likewise both plantar reflexes.

Lesions of the Lumbo-sacral Plexus and of its Branches.—

Compared with the brachial plexus, the lumbo-sacral plexus is a comparatively simple affair. Its constitution is indicated diagrammatically in Fig. 22 (p. 31). Of the nerve-trunks derived from the plexus, the largest and most important are the sciatic (L_4 and L_5, S_1, S_2, and S_3) and the anterior crural nerve (L_2, L_3, and L_4), either or both of which, especially the sciatic, may be injured from plexus lesions, though less frequently than from direct wounds of the nerve-trunks themselves.

The lumbar portion of the lumbo-sacral plexus, coursing through the substance of the psoas muscle, is more often affected than the sacral part. The symptoms of plexus lesions are grouped somewhat differently from those which result from peripheral lesions.

The following is an illustrative example of a lesion of the 3rd lumbar root:—

A soldier was wounded by a rifle-bullet which entered half an inch below the upper edge of the right iliac crest, five inches from the middle line. There was no exit-wound. A radiogram showed the bullet to be lodged in the right side of the body of the 4th lumbar vertebra. The patient immediately lost power in the right lower limb, and for three days was unable to make any movement in it. Improvement then set in rapidly, beginning at the foot and ankle. Within three weeks he became able to walk with a stick. He complained of occasional pains along the inner side of the right thigh, from groin to knee, also of loss of feeling in the region of the knee.

When examined a month after the injury, there was an area of complete anæsthesia to all forms of stimuli on the front and outer side of the right thigh and along a narrow strip at the inner side of the knee (see Fig. 295).

There was complete paralysis of the right quadriceps extensor, and some weakness of the flexors and adductors of the hip. All the other

muscles of the lower limb were powerful. To faradism there was loss of reaction in the quadriceps, with diminution in the adductor muscles.

The right knee-jerk was absent; the left was brisk. Both ankle-jerks were normal.

The next case is one in which the 5th lumbar root was damaged, its motor fibres being exclusively affected:—

A soldier, aged twenty-one, was wounded by a shrapnel-bullet which entered half an inch to the left of the 5th lumbar spine. There was no wound of exit, but the bullet lodged (as shown by a radiogram) in the lower part of the body of the 2nd lumbar vertebra, in the middle line. The patient was standing at the moment of being hit, and immediately dropped backwards, his legs giving way. The left lower limb was immediately paralysed, whilst the right limb felt slightly weak for a few hours.

Within two days he began to recover power in the left hip and knee, but had not regained power of dorsiflexion of the left ankle. He had a subjective sensation of numbness along the back of the left thigh and at the back and outer side of the left leg. There was never any affection of sphincters.

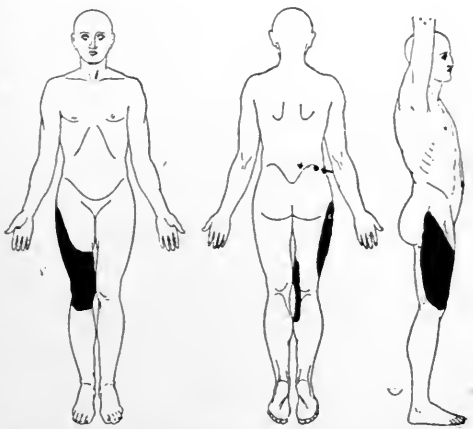

Fig. 295. — Anæsthesia in a case of lesion of the 3rd lumbar root.

On examination two-and-a-half weeks after the injury, there was no loss of sensation to any form of cutaneous or deep stimulation; joint-sense was everywhere normal.

The right lower limb was normal. In the left lower limb the movements of the hip and knee were powerful. Flexion of the toes was also normal. There was paralysis of the anterior tibial and peroneal groups of muscles, so that dorsiflexion and eversion of the ankle were impossible, and he had drop-foot. The knee-jerks and ankle-jerks were brisk and equal. To faradism there was diminution of reaction in the peronei and anterior tibial groups.

In a work like this, space does not permit the full discussion of the symptomatology of **paralysis of the individual nerves of the limbs.** The diagnosis of such lesions is dependent mainly on an accurate knowledge of anatomy. A few main facts, however, may here be mentioned, applicable to peripheral-nerve lesions in general.

Within the peripheral nerves the fibres, whether sensory or motor, are arranged just as definitely with relation to each other as are the fibres in the cervico-brachial or lumbo-sacral plexuses. The nerve-bundles within the peripheral nerves do not run haphazard, but occupy

certain definite relative positions in the internal nerve-plexuses within each nerve-trunk.

Thus, for example, in the ulnar nerve at the bend of the elbow, the fibres destined for the interosseal muscles of the hand lie superficially, whilst those destined for the ulnar half of the flexor profundus and for the adductor pollicis lie deeply, close to the humerus.

Again, in the sciatic nerve, in the gluteal region, not only can we distinguish the internal-popliteal fibres, lying internally, from the external-popliteal fibres externally (indeed, they sometimes constitute two parallel but separate nerves), but the cutaneous fibres of the external saphenous and internal plantar branches, together with the muscular branches for the calf muscles, are situated on the postero-internal aspect, whilst the fibres of the external plantar nerve, together with the muscular branches for the tibialis posticus and the long flexors of the toes, lie externally. Thus a lesion of the outer part of the sciatic trunk, high up, often produces paralysis limited to the external popliteal, whilst a partial lesion, lower down, may produce a paralysis limited to the long flexors of the toes and of the tibialis posticus, accompanied by anæsthesia of the outer part of the sole.

Ischæmic Myositis.—We have already referred to the ordinary variety of ischæmic myositis due to the pressure of tight splints or bandages (see p. 231). In the recent war, however, another type of ischæmic myositis has been occasionally met with, resulting from direct injury of the artery supplying the muscle-group and without the occurrence of any pressure on the muscles themselves. It is often associated with cutaneous anæsthesia, not corresponding to definite nerve-areas. The following is an illustrative example:—

A soldier, aged twenty-two, was wounded in the left upper-arm. The entry-wound was through the middle of the biceps; the exit was at the same level, an inch behind the brachial vessels and nerves.

When admitted to hospital ten days later, there was a considerable swelling in the upper-arm, and no pulse could be felt at the wrist. There was weakness of the wrist and fingers. No splint or bandage was applied to the forearm at any period of the treatment.

On the thirteenth day of injury, secondary hæmorrhage occurred from the wound of exit. The false aneurism was accordingly laid open, the blood-clot was turned out, and the vessels, above and below the aneurism, were ligatured. Uninterrupted recovery took place from this operation.

On the day after the operation, some return of power was observed in the extensors of the wrist and fingers. Improvement steadily continued, but the flexors of the wrist, fingers, and thumb remained permanently paralysed, and gradually the paralysed muscles developed a characteristic hard, doughy consistence. All the other muscles of the upper-arm, forearm, and hand were normal.

Two months after the original injury, the motor disability remained

unchanged. To pin-pricks there was analgesia of the hand from the wrist downwards. To cotton-wool touches, anteriorly there was anæsthesia below a level two inches above the wrist, whilst posteriorly sensation was lost only from the knuckles downwards. Small blisters formed occasionally on the dorsal aspect of the terminal phalanges.

No reaction to faradism or galvanism could be obtained in the paralysed long flexors of the wrist, fingers, or thumb, even under a general anæsthetic, whereas all the other muscles of the limb reacted in normal fashion.

Similar ischæmic palsy is sometimes observed in the lower limb. Thus, after ligature of the femoral artery, paralysis, with doughy hardness and loss of electrical reactions, has occasionally been observed in the anterior-tibial and peroneal groups of muscles, or in other cases in the calf muscles.

We note in such cases that no injury had been inflicted on the nerve-trunks; the condition is therefore circulatory in origin.

After some cases of ligature of the femoral or popliteal artery (but not in all) symptoms of painful **unilateral intermittent claudication** occur (see p. 247), so that the patient, after walking a few yards, has to stop and rest, owing to pain, cramp, and weakness of the muscles in the affected leg. This is because, during the effort of walking, the muscles of the leg call for a temporary increase in the blood-supply, an increase which the affected arterial trunk is unable to provide. Thus a relative local and temporary ischæmia of the muscles occurs.

CHAPTER XXVII

WAR-NEUROSES

THE definition of the term "neurosis" we have already considered in a previous chapter (p. 358).

There is no exclusive "war-neurosis," *i.e.* there is no neurosis in war of which we do not find examples in civil life. Further, war-neuroses are not confined to combatants; they occur during war-time in peaceful civilians, not only among those who are exposed to incidents of war, such as aerial and other bombardments, but even in individuals far removed from such experiences, *e.g.* amongst the home relatives and friends of soldiers at the front, or in timorous conscripts who have never been anywhere near the fighting line, but who suffer from morbid fear of active service:—*machiphobia*, whether at the time of their recruitment or later, when their draft is warned for active service.

Causation of War-Neuroses.—Acute neuroses in war, as in peace, usually arise from a combination of emotional and physical shock. Thus in peace-time we meet with neuroses, identical with those of war, following railway-accidents, earthquakes, lightning-strokes, electric shocks, shipwrecks, and so on.

In the production of war-neuroses the commonest causal factors are the following:—

1. **Emotional Shock.**—All acute emotions are normally accompanied by transient, reflex, chemico-physical reactions of the vegetative nervous system, associated with special activity of internally secreting glands. Emotions and their accompanying normal physical reactions are all independent of volition. The particular emotion, *e.g.* fear or anger, which will be produced, say, by a bursting shell, depends not on the stimulus (which in itself is neither fear-producing nor anger-producing), but upon the patient's nervous architecture and his inherent character, modified by education, by environment, and by discipline. In the physical phenomena of fear, anger, pleasure, surprise, shame, etc., many of their signs are visible to the outside observer. Thus, a person under the emotion of acute fear shows prominent, "starting" eyes, dilated pupils, deficient salivation, so that his tongue "cleaves unto the roof of his mouth," violent action of the heart, pallor, sweating, tremors of the voluntary muscles, and a tendency to involuntary

contraction of the bladder and even of the rectum. He is mentally confused and has difficulty in fixing his attention. These phenomena are essentially neuro-toxic in character, and are associated, at first, with an excess of adrenalin in the blood-stream, as has been shown experimentally in the case of a caged cat with a fierce dog barking close outside the bars. If this adrenal action is prolonged, it may be followed by a phase of exhaustion of the adrenals and other internally secreting glands, producing corresponding physical signs: low blood-pressure, muscular asthenia, etc.

To counteract the temporary excess of adrenalin, the thyroid gland over-acts. Under abnormal conditions this hyper-thyroidism may persist when the transient emotional hyper-adrenalism has passed off.

Amongst the emotional shocks of war, burying by earth is specially terrifying to the soldier; so also is the horrifying sight of his mutilated comrades.

The natural emotion of fear, however, in man, may be modified by other reflexes and instincts, *e.g.* by the cerebral realisation of responsibility and duty, and especially by training and discipline, so that the individual does not yield to his primitive emotion of fear, tending to make him run away, but "carries on" with his duties. This is a higher form of courage than that of an individual who does not feel fear. Without fear there can be no true bravery. The bravest man is not he who never trembles, but he who, trembling, dares to face and to attack a dangerous enemy.

In modifying the primary emotion of fear the herd-instinct is specially important. Our two primary instincts are those of self-preservation and of reproduction (sex-instinct). These two are shared in common by all living things. Later in evolution, as McVicar has put it, a higher instinct develops:—the herd-instinct, with its pride of family, country, or race. In civilised communities this comes to dominate the two primary instincts and gives rise to the social virtues of morality, religion, modesty, discipline, morale, bravery in danger, etc. It can be deliberately trained to a high pitch. In peace-time if the herd-instinct is lost or imperfectly developed, the individual may become antisocial, criminal, vicious, or cowardly, and is dominated by uncontrolled emotional impulses, such as those of fear, surprise, anger, and so on. In war-time the soldier has to meet special assaults upon his instinct of self-preservation. He is therefore carefully trained and drilled, so as to act calmly and correctly in situations of danger which would ordinarily arouse the emotion of fear or the mere instinct of self-preservation. The herd-instinct is thus deliberately developed.[1] If a high degree of discipline be attained, not only do acute emotions

[1] Trotter, *The Herd Instinct in Peace and War.*

produce fewer nervous symptoms, but the primary emotional reactions themselves tend to be less intense. A violent bombardment which shakes the new recruit may not even quicken the pulse of the veteran.

Not only may acute emotions induce certain war-neuroses and psychoses, but frequently the **memory of an acute emotion** may aggravate the symptoms or cause them to relapse.

There is the well-authenticated instance of a party of about a dozen soldiers, convalescent from hysteria, in a military hospital in London, who were taken out to enjoy a melodrama in an adjacent theatre. At one particular moment in the play, a mimic bomb was exploded on the stage. Six of the soldiers had to be carried back to the hospital, whilst another became temporarily aphasic.[1]

The incomplete **repression of a distressing memory** may also aggravate a patient's symptoms or prevent them from clearing up. The soldier tries, by an effort of will, to divert his attention from the memory of some scene of terror, or of horror (terror for his own safety, horror at the sufferings or mutilations of others). Voluntary repression of painful memories is a natural protective mechanism, as natural as the voluntary avoidance of danger or distress in ordinary life. It is a constituent part of a soldier's training, and is useful so long as it helps him successfully to adapt himself to an environment which would ordinarily arouse disturbing emotions. Repression of this sort may vary widely in its degree, from total amnesia at one end of the scale, to a mere reluctance to speak of his war-experiences at the other. But if repression of painful memories of war-incidents be incomplete, so that it fails to adapt the individual to his surroundings, especially if the patient has an inborn neuropathic tendency, then by attempting, ostrich-like, to banish the distressing memory from his mind, instead of allowing it to fade by the natural process of time, he tends to renew, distort, and exaggerate it.

The spontaneous recrudescence of his emotion is particularly liable to occur when he has no other incidents to occupy his attention, or when the control of the waking state is diminished, *i.e.* especially at night. Such a patient, when he ought to be falling asleep, has an attack of acute emotional distress, which prevents him from sleeping. Or if he succeeds in falling asleep, he suffers from terrifying nightmares, which wake him up, palpitating and sweating with fear. He may also develop other symptoms of anxiety-neurosis to which we shall refer presently.

The Freudian pan-sexual dogma, which boldly attributes all neuroses to the repression of a memory of some sexual trauma, has been reduced by war-experience to its proper perspective. In civil

[1] Armstrong-Jones, *Trans. Medical Society of London*, 1917, xl., p. 129.

life this hypothesis doubtless has an element of truth in tracing some neuroses to a sexual emotional trauma, whose original emotional reaction has been "repressed" and thrust back into sub-consciousness. But no reasonable stretch of imagination can induce the common-sense physician to regard a shell-explosion, or other emotional war-incident, as in any way sexual in character. Nevertheless, even in these cases the Freudian enthusiast tries to unearth some juvenile sexual incident as a causal factor. If he fails, even by the most suggestive "analysis," to elicit a juvenile sexual trauma, he falls back on some supposed infantile incident, or, as a last resort (why not?) to an ante-natal, intra-uterine, ancestral, or even atavistic sexual reaction.

To give a homely analogy, the Freudian hypothesis may be compared to the secluded sanitary cubicle which plays a small but useful rôle, in comparison with the other rooms, in an ordinary modern house. Its omission from the architectural plan, it cannot be denied, would be a flaw in the design; but it is not the most important chamber. So with the Freudian sexual hypothesis, which plays an undoubted but limited rôle in the production of neuroses. But the Freudian physician who strives to trace all neuroses to sexual trauma is like a householder who not only uses his sanitary cubicle for a few minutes in the day, but eats, works, lives, sleeps, and also entertains his friends there.

2. **Suggestion** plays a fundamental rôle, especially in the production of war-hysteria. The suggestion may be either from within (auto-suggestion) or from without (hetero-suggestion).

Auto-suggestion may act at two different periods after a violent emotion or a shell-explosion. As the first mental confusion is passing off, the patient may discover that he is perhaps temporarily blind, or deaf, or speechless, or unable to move some part of his body. These symptoms may be due to temporary exhaustion of his visual or auditory apparatus, or to cerebral concussion with its resultant mental confusion. The patient's suggestibility is meanwhile temporarily exaggerated by the violent emotion. The surprise and distress of discovering his new symptoms, together with apprehension as to the possibility of permanent disablement in the future, may give rise to superadded auto-suggestions of a negative character, fixing, intensifying and stereotyping the recent disability, which would otherwise pass off spontaneously. Thus the patient may remain hysterically blind, deaf, mute, or paralysed.

Auto-suggestions of disability, such as blindness, paralysis, etc., sometimes take their origin in the awakening of an old memory of a similar disability which occurred in the patient's former experience. This disability may have been one which had occurred to the soldier personally during his previous civilian life; more often it has been some-

thing which happened to someone else, perhaps to one of his relatives or acquaintances. Thus one soldier, shaken by a shell-explosion, who developed hysterical paraplegia, had in his mind the memory of a sister who had been paralysed in both legs. Another soldier saw a comrade's legs blown off; this made such an impression upon his consciousness that, long afterwards, when he himself was partially buried by a shell-explosion, he developed hysterical paraplegia. Cases of this sort do not supervene immediately after the shell-explosion; there is an interval, generally of hours or even days, after the original shock, during which the patient has time to meditate on his various distressing memories. Such meditation need not be conscious meditation. The patient may do it sub-consciously or may even be trying to repress his painful memory, and the fact is only brought out afterwards by the physician when talking over matters with him. The recalling of the buried memory to the patient's consciousness and the pointing out by the physician of its causal influence usually have a striking effect in helping to remove permanently the paralysis, phobia, obsession, or other hysterical or psychasthenic symptoms.

A second variety of auto-suggestion is that which, at a still later stage, secondarily elaborates the original symptoms, consciously or sub-consciously, so that a chronic, progressive "pension-neurosis" of a hysterical nature is gradually built up, exactly similar to many cases of "compensation-neurosis" in civil life. Every war-pension which is allotted on account of hysterical symptoms, by suggesting to the patient his incapacity for work, acts as a hindrance to complete recovery and favours the development of fresh hysterical phenomena. "A pensioned hysteric is a social parasite."

Hetero-suggestions from other patients sometimes produce or aggravate hysterical symptoms. The grouping together of uncured hysterics has a deleterious influence upon all of them. Each uncured patient forms a focus of baneful suggestion, fixing the attention of the others upon the apparent incurability of his affection. On the other hand, the presence of other patients who are getting well under treatment has a powerful beneficial stimulating effect. Well-meaning but injudicious friends often aggravate hysterical symptoms by hetero-suggestion. Many of the most intractable cases of war-hysteria have developed whilst the patient was on leave. Therefore no hysterical patient should be allowed to return to his own home until all his grosser phenomena have been removed. Amongst the worst offenders, however, in the matter of hetero-suggestion are incautious medical men, who through injudicious questionings often suggest all sorts of fresh symptoms to the patient. Hence the value of isolating the soldier suffering from recent war-neurosis in a special institution, under

skilled neurological care, separated from other patients and from injudicious friends.

There is almost always an interval of several hours or even days (*période de méditation*) between the original emotional shock and the onset of hysterical symptoms. The patient has been slightly confused by his emotional shock, and it is during this stage of "mental dislocation" that he is liable, whether by auto-suggestions, recalling earlier emotional memories, or by hetero-suggestions, derived from comrades, from friends, or from his medical *entourage*, to develop hysterical phenomena. It is a matter of experience that, in the trenches, no matter how intense the emotional shocks may be, often producing violent emotional reactions, *e.g.* tremors, tachycardia, sweating, etc., true hysterical phenomena are conspicuous by their absence. It is only when the patient has passed towards the base, and especially at the base-hospitals, that the familiar pictures of hysteria appear.

3. Physical **concussion** of the nervous system (*commotio cerebri*) as a causal factor is relatively infrequent. In most cases of war-neurosis it is entirely absent. When actual concussion occurs (whether resulting from a local head-injury or from the sudden atmospheric compression and decompression due to the bursting of a high-explosive shell), it produces sudden cerebral anæmia, with microscopic hæmorrhages, etc., followed by œdema of varying degree (see p. 53). Changes are also observed in the cerebro-spinal fluid, consisting in an increase of albumin, slight excess of cellular elements, and even the presence of red corpuscles. Under such circumstances the possibility of molecular cerebral changes cannot be denied, whereby nerve-paths are suddenly dislocated or disharmonised, producing changes in the reactions to stimuli of various sorts. Thus, for example, we may recall the familiar intolerance to alcohol which so commonly follows severe head-injuries, even in peace-time.

But physical shock is not essential for the production of war-neuroses. Many of the severest cases arise under circumstances where there has been no mechanical shock whatsoever, and many of the disorders which at one time used to be attributed to concussion, *e.g.* trembling, tachycardia, tachypnœa, etc., are really manifestations of emotional reactions.

4. **Exhaustion,** from prolonged and excessive physical and mental strain of a campaign, may induce neurasthenia, or even an exhaustion-psychosis of the usual confusional type, just as in civil life. Exhaustion may also lower the resistance of the soldier to other factors, such as suggestion, emotional shock, etc., which are the immediate antecedents of his neurosis. Exhaustion is rarely the sole cause; it is usually combined with insufficient sleep and with some emotional

factor. Simple neurasthenia from exhaustion is commoner amongst officers than amongst men.

5. **Poisoning** by various other toxic agents, apart from the endogenous toxins of exhaustion, causes a certain proportion of neuroses. The commonest starting-point of such toxic neuroses is some antecedent acute fever, *e.g.* malaria, dysentery, enteric fever, etc. The symptoms of the subsequent neurosis are usually of neurasthenic type, but we may also meet with a vegetative neurosis, evidenced by tachycardia, tremors and a relative lymphocytosis of the blood, or we may have an exhaustion-psychosis of the usual confusional type.

Amongst drug-habits, chronic alcoholism, with its familiar symptoms, is sometimes met with, chiefly in the vicinity of base-depots and canteens, and rarely amongst fighting troops. Tobacco-intoxication, on the other hand, is much commoner, especially amongst first-line units; it chiefly affects the younger soldiers. The free issue of a tobacco-ration, as served out in the British Army in war-time, was not an unmixed blessing; many cases of so-called "soldier's heart," with tachycardia and tremors, were due to excessive tobacco-smoking, and such cases rapidly improved when the tobacco was cut off.

Early in the war, we in England were amused to read in an enemy journal an apparently serious article which asserted that the British Navy was manned largely by cordite-eaters, who devoured part of the ammunition which ought to have been expended in naval purposes! Cases of cordite-habit are so rare as to be practically unknown. Almost equally rare are the men suffering from the morphia or the cocaine habits, neither of which can, in any case, be regarded as peculiar to war nor in any way frequent.

Carbonic oxide poisoning was propounded in the early days of the war as a causal factor in neuroses following shell-explosions. But the evidence of prolonged, permanent, toxic action upon nerve-cells by the action of CO gas is very slender. Still more significant is the fact that the patient's wounded comrades, who were usually devoid of all symptoms of neurosis, had been just as much exposed to the noxious fumes as was the soldier who happened to develop a neurosis.

6. **Pain** following a **trauma** of some localised area, reinforced by auto-suggestion, often acts as a causal factor by focussing the patient's attention on that special part. It is specially liable to induce hysterical contractures by perpetuating the original posture assumed by the painful limb.

Disuse of the injured limb is also a factor in such cases. In the first instance the pain of the injury produces immobility. This immobility is intensified by splints or bandages applied to the wounded limb, so that the patient no longer makes any use of the part. After weeks or

months, the wound cicatrises or the fracture heals, and the time comes for the patient to resume voluntary movements. But if passive movements have not been carried out in the meantime, there is sure to be a certain degree of stiffness of the joints and muscles and all the tissues are more sensitive than normal. An energetic patient perseveres and moves his limb, despite the initial discomfort. But the lazy man, the hysteric, or, still oftener, the "perseverating" malingerer, refuses to make the necessary movements and leaves the limb or segment of a limb immobile.

The severity of the original injury bears no relation whatever to that of the hysterical paralysis or contracture which may follow it. On the contrary, it is often the most trivial injuries which are followed by the most dramatic and persistent disabilities.

7. **Heredity.**—A considerable proportion, possibly the majority, of war-neuroses occur in nervous, highly-strung soldiers who are hereditarily disposed to neuroses or psychoses. In war-time whole battalions are exposed to identical physical and emotional shocks, nevertheless only a small proportion of soldiers develop neuroses. Certain neuropathic families and even certain races, *e.g.* the gallant Welshmen, are more prone to functional disorders than their more stolid comrades, especially after minor wounds or injuries.

A previous personal history of functional disorder in pre-war days is sometimes met with. For example, a soldier with hysterical mutism following a shell-explosion (promptly cured by suggestion) gave a history of a similar attack some years before, during his civilian life as a coal-miner, when he was buried in a mining-accident.

Still more commonly a family disposition to neuroses is discovered, when inquired for; but under the stress of service conditions, histories of this sort are often overlooked. A psychopathic or neuropathic tendency may be present in individuals with any grade of mental development, whether normal, supernormal, or subnormal. The inborn factor is of great importance, for it often helps us to solve the following question:—Why is it that under apparently identical conditions of emotional or physical shock, one soldier develops hysteria, another becomes neurasthenic, whilst others show signs of hyperthyroidism, epilepsy or stupor? The explanation is to be found in the patient's individual temperament or predisposition. We are all of us potential neurotics. The particular pattern of neurosis which develops under the searching tests of war is simply the individual reaction of a neuropathically-predisposed individual to emotional trauma or to suggestion.

Two classes of soldiers are singularly exempt from war-neuroses: Firstly, patients who have recently sustained severe physical wounds.

Various explanations have been offered for this fact. It has been suggested that the unlikelihood of immediate return to the fighting-line after such a wound removes the emotional factor of apprehension. Another suggestion is that a wound of the patient's own body produces a much slighter psychical trauma than does the horror of witnessing the sudden death or mutilation of his comrades. Another possibility is that the presence of his own serious wound occupies so completely the patient's field of consciousness that there is no room for subjective phenomena to be superadded by suggestion. But, later on, in hospital, if a wounded limb be kept immobile from pain, or from too long application of splints, hysterical paralyses may become superadded by auto-suggestion. Such hysterical disability may persist long after the original wound has healed. The combination of organic lesions with hysterical palsies must always be borne in mind.

Secondly, prisoners of war do not readily develop the ordinary neuroses. The explanation of this relative immunity may lie, partly in their withdrawal from the emotional strain and apprehension of combatant life, but largely also in the herd-instinct, the pride of country, to which we have already referred. There is, however, one neurosis which is specially characteristic of prisoners of war, the so-called **"barbed-wire psychosis."** Amongst prisoners, the monotony of internment, the limitation and censorship of letters to and from the outer world, the promiscuous herding with other prisoners, the receding hopes of release as each fresh batch of prisoners is added to the crowd, all these factors, after a few months, gradually blunt the emotions of the chronic prisoner and induce a condition of mental apathy. A characteristic type of neurasthenia is the result. The prisoner becomes abnormally irritable and quarrelsome; he sleeps badly; his power of mental concentration becomes diminished, so that he can no longer settle down to regular occupations, and even the amusements of his fellow-prisoners become intolerable to him. Perhaps the most striking feature of all is the failure of memory, especially for pre-war people and places, so that he may forget the names of his relatives or of familiar home-scenes. The whole personality of the patient is thus profoundly changed. Some of the foregoing symptoms, especially the morbid irritability and the insomnia, rapidly clear up when the prisoner is repatriated or transferred to a neutral country; whereas the loss of concentration and the restlessness take much longer to pass off.

Clinical Varieties of War-Neuroses.—Apart from the psychoses (such as confusional insanities, melancholia, mania, hallucinatory and delusional insanities, etc.), the neurologist in war-time has to deal with

numerous clinical varieties of neurosis.[1] Although it is convenient to describe these as if they were distinct entities, it is important to remember that the real entity is not the disease but the diseased individual.

1. **Concussion-Neurosis.**—Following many cases of cerebral concussion a characteristic group of chronic symptoms is produced, which may last for months or even years. The previously concussed patient complains of persistent headache, especially in the day-time. The headache is aggravated by sudden changes of position, and by stooping. Together with this, there is vertigo, mental inertia, failure of memory and deficient mental concentration. His reasoning powers are unimpaired, *i.e.* there is no gross intellectual deficiency. But he is emotional, irritable in temper, and hyperæsthetic to loud sounds and to bright lights. He sleeps badly and may have terrifying nightmares. He often has recurrent outbursts of violent temper and headache, at intervals, perhaps, of three or four weeks. A return to active service invariably induces a relapse of the foregoing symptoms. He is intolerant to alcohol and to other nerve-poisons, so that even a small dose of alcohol, which in the old days did not upset him, now goes to his head and tends to produce intoxication.

To these phenomena may be superadded hysterical tremors of various kinds, coarser than those of hyper-thyroidism, and aggravated by emotion, by loud noises, or by voluntary movements. Such tremors in their primary origin are emotional reactions, not necessarily due to suggestion. In many cases, however, they have become aggravated and stereotyped by superadded auto-suggestion, and persist as hysterical tremors.

Inasmuch as most cases of organic cranial injury are accompanied by cerebral concussion, we are not surprised to meet with symptoms of concussion-neurosis after major head-wounds, just as we do in patients who have been concussed without any obvious external lesion.

2. **Katatonic Stupor or Trance.**—A young soldier, usually of neuropathic heredity, with or without a history of previous concussion or emotional shock, is found to be in a condition of trance. He lies in bed, silent and apathetic, paying no attention to his surroundings. He swallows food when it is given to him, but does not ask for it. If placed on his feet, he remains standing, or after a few minutes may collapse on the floor. If gently led or pushed forwards, he walks in a

[1] All sorts of nervous and mental symptoms developing in unwounded men who have been under shell-fire have been loosely, and often quite erroneously, referred to as "shell-shock." This unfortunate catch-word should be wiped out from the vocabulary of every scientific physician. It has been applied to widely divergent conditions, differing both as regards causation and as regards symptoms. We might as well label malaria, dysentery and plague indifferently as "tropical fever." The term "shell-shock" is altogether bad; it is the refuge of the confused thinker. Moreover, it often exercises a baneful suggestive effect upon the patient.

feeble, shuffling fashion, soon coming to a standstill. If he meets an obstacle, *e.g.* the wall of the room, he remains motionless, facing against it. If a lighted cigarette or match be placed in his hand, he holds the burning object until it burns his fingers. He may make stereotyped rhythmic movements, over and over again, of the jaws, face, or limbs, for hours at a time or mutter the same word and syllable with constant repetition (verbigeration). We often observe rigidity of the proximal joints of the limbs on passive movements (katatonic rigidity).

This condition, which may last from a few hours to several days, is one of katatonic stupor, exactly similar to that which is met with in the dementia præcox (schizophrenia) of civil life.

These soldiers are really cases of latent dementia præcox, in which the stuporous phase has been precipitated by emotional shock, *e.g.* by a shell-explosion.

Other varieties of dementia præcox are met with in varying degrees of intensity. There are numerous types, some with lethargy, others with delusions, negativism, verbigeration, etc. All of these varieties are paralleled in civil practice.

Dementia præcox, whatever its type, is essentially founded upon an inborn inherited predisposition. Inquiries in these cases will often reveal a family history of insanity, alcoholism, or nervous disorders; or some previous psychical symptoms in the patient himself. Naturally, during the enlistment of recruits for war-service, time rarely permits of adequate inquiry into such matters, and it is only after the individual has broken down that the full significance of his inborn predisposition is appreciated. Even the actual diagnosis of dementia præcox is apt to be overlooked in war-time, and the patient is wrongly regarded as suffering from hysteria or some other neurosis, in view of the fact that, when originally admitted to the army, he showed no signs of mental trouble. There is little doubt that, had these individuals never been called upon to bear the emotional strains of war-service, most of them would have lived through the ordinary conditions of peace without a mental breakdown. But, all the time, they were potential dements, in whom the additional and decisive factor was the emotional strain of military service.

3. **Hysteria or Suggestion-Neurosis.**—This is by far the commonest neurosis met with in war-time. It occurs in all its polymorphic types. Its clinical phenomena are essentially the same as in peace. Unlike neurasthenia and anxiety-neurosis, hysteria is relatively commoner in private soldiers than in officers.

We have already, in a previous chapter, discussed the main outlines of this neurosis, especially the patient's abnormal suggestibility, and it is unnecessary to recapitulate these points *in extenso*.

Amongst the sensory phenomena of war-hysteria the "algias" are specially frequent, *i.e.* persistent pains not caused by an organic lesion. Such pains, when occurring in the lower limbs and trunk, tend to produce dramatic limping with hysterical contractures. A few illustrative examples may be mentioned:—

1. *Hysterical Algia and Contracture of Right Upper Limb.*—Two months before coming under observation, the patient, a man of twenty-three, sustained a superficial bullet-wound in the back of the neck, the entry being in the middle line in the suboccipital regions, the exit an inch behind and below the right mastoid process. Ever since he had complained of pain in the right side of his neck, extending all down the right arm, with weakness of the right grasp. A month later, when taking part in an advance up a steep cliff in Gallipoli, he was struck on the head by falling stones, and sustained a scalp-wound in the right frontal region, for which he was sent to hospital.

Fig. 296.
Hysterical Contracture of right upper limb.

On examination there was marked cutaneous hyperæsthesia of the whole right upper limb from fingers to shoulder, extending over the right scapular and pectoral regions. The muscles of the limb were powerful and well-developed, and no voluntary movement was impossible. Every voluntary effort, however, with the right upper limb, and even passive movements, caused pain. The limb was held constantly in a statuesque posture, with elbow and fingers stiffly semi-flexed, as if grasping some phantom object (see Fig. 296). Attempts to elicit the supinator-jerk produced intense emotional reaction.

A fortnight later, the pain and hyperæsthesia of the limb had disappeared, but the elbow and fingers were still semi-flexed. Passive extension of the fingers still caused acute pain all up the limb. There was no muscular atrophy, and all the deep reflexes were normal and equal on the two sides.

2. *Hysterical Acro-paræsthesia, following Wound of Elbow.*—A flying-officer, aged twenty-five, was hit during an aerial duel by a machine-gun bullet, sustaining a tangential wound half an inch above the flexure of the left elbow and slightly in front of the brachial vessels. Ever since the injury, he complained of a constant subjective tingling, painful sensation of pins-and-needles in the index, medius and ring-finger, front and back, and in the corresponding part of the palm. This sensation, which varied in intensity at different times of the day, was aggravated, not only by

light touches, but by the sounds of gun-fire, or of aeroplanes, or, worst of all, by the sound of scratching a match (he heard this sound immediately he landed, after his fight in the air). The movements of the left fingers were excessively feeble.

On examination a month later, there was marked hyperalgesia to touches and pin-pricks on the whole of the left palm and all the digits, back and front, except on the dorsum of each proximal phalanx. There was no cutaneous anæsthesia or analgesia, and joint-sense was normal.

All voluntary movements of the finger, thumb and wrist were feeble and tremulous, but none were impossible. He resisted passive movements of the left wrist and elbow by holding on with his right hand. There was no muscular wasting of the left forearm or hand, nor were there any electrical changes.

Before diagnosing a pain as a hysterical "algia" we must be careful, by physical examination, to exclude the presence of an adequate organic cause for it. Hysterical pains are often erratic in their distribution; they do not tend to follow anatomical areas, nor are they accompanied by tenderness along the nerve-trunks. Moreover, the hysterical patient resists passive movements of his limb, and is liable, during examination, to show emotional dyspnœa or even an outburst of weeping or a hysterical attack. Lastly, the most conclusive proof of a pain having been hysterical is its disappearance under psychotherapeutic suggestion.

Another frequent type of war-hysteria is the characteristic bent back (antialgic spondylosis or camptocormia). This has a sudden onset, usually preceded by pain. There is generally a history of contusion of the back, caused by a shell-explosion. The local pain of this contusion renders extension of the spine, for the moment, painful, and the patient at once assumes a flexed posture of his trunk. But this posture, owing to auto-suggestion, persists long after the original cause has cleared up. In a fully developed case the patient walks with his trunk almost horizontal. But his neck is bent backwards, so that his face is held erect, with fixed expression and wide-open eyes. If told to stand erect, he fails to do so, although he seemingly makes vain and dramatic efforts. During these it will be noticed that all his trunk-muscles, not only the spinal extensors, but also their antagonists, the abdominal muscles, are thrown into spasmodic contraction, so that no improvement occurs in the deformity. If forcible attempts are made to straighten the spine passively, the patient complains of violent lumbo-sacral pain, and becomes acutely emotional, with terror-stricken face, rapid breathing and quickened pulse. Nevertheless, in most cases, the deformity entirely disappears when the patient lies down.

Hysterical aphonia is another frequent type; in this the patient talks in a soft whisper, but with normal articulation. Sometimes we have hysterical mutism, in which the patient is absolutely speechless

and makes no attempt to articulate, even in a whisper. Nevertheless he can communicate his ideas fluently by writing. In this respect the condition differs both from aphasia and from the mutism of katatonic stupor (see p. 64). Often a patient has a transient stage of complete mutism (with or without hysterical deafness), following a shell-explosion, and this clears up partially after a few hours, leaving him merely aphonic but not mute.

The following is an illustrative example of hysterical aphonia:—

A seaman belonging to a landing-party at Cape Helles on the Dardanelles was asleep one night when a shell exploded in his trench and killed the man next to him. He himself, although shaken, remained apparently well, save for some pain in the right knee and across the lumbar region, from slight contusions.

On the second day after this explosion he became "helpless" and had to be carried to the sick bay, where he rapidly became apathetic, listless and mute.

On the third day, when seen by myself, he was no longer mute. He talked in a soft whisper, was mentally intelligent and able to write fluently. There was no deafness. The visual fields were moderately contracted. The pupils and cranial nerves were normal. When told to protrude the tongue, he could not do this in the ordinary way, but pulled it forwards with his fingers. There was no cutaneous anæsthesia or analgesia, and no motor weakness, tremor, or ataxia of the upper or lower limbs. But in walking he limped dramatically with his right leg, using a stick with the left hand. The reflexes, deep and superficial, were normal; the heart was somewhat rapid, 96 per minute.

The absence of organic disease was explained to the patient during the course of the foregoing examination. An hour later, when I saw him once more, he had regained his normal voice, notwithstanding the continuance of heavy shelling at the time, and his limp had disappeared.

Some cases of hysterical mutism clear up, but are followed by a prolonged stage of stammering, lasting for weeks or months. On inquiring into such cases it will be found that whilst some of them are purely hysterical in character, produced by suggestion and removed by counter-suggestion, a considerable proportion of them give a history of stammering in childhood. In other words, the stammer is one of the stigmata of a congenital psychasthenia, and such patients are to be regarded, not as pure hysterics, but as hystero-psychasthenics.

Hysterical blindness (p. 381) and hysterical deafness (p. 152) have already been described, but additional examples may here be given:—

Hysterical Blindness.—A young soldier, aged twenty, was struck on the vertex by a piece of rock during the explosion of a shell. For two days he was totally blind. He then began to see with the right eye, but the left eye remained completely blind, until he came under observation two months later.

On examination, the fundi and media of both eyes were normal. Vision in the right eye was 6/12. The right visual field was normal.

In the left eye there was no perception of light. The prism-test did not induce diplopia. There was a tender spot on the vertex, two inches in front of the bregma.

Both pupils reacted briskly to light, directly and consensually. Although there was apparently no perception of light on the left eye, nevertheless the patient occasionally blinked with the left eye to a finger suddenly shot in, chiefly from the right side (the right eye being meantime covered up). The cranial nerves were otherwise normal; the sensory, motor, and reflex functions were also normal.

The subsequent course of the case is instructive. It was decided to cover the right eye by a strong convex lens (+10 D), so as to encourage vision in

Fig. 297.

Hysterical Anæsthesia of the head and upper part of neck.

the left eye. Further, to increase the disability of the right eye, it was treated by atropine instillations. In spite of his right eye thus being placed *hors de combat*, the patient was observed to read most of the day.

Accordingly, a fortnight after admission, Captain A. D. Griffith proceeded to demonstrate to the patient the functional nature of his disability. To begin with, refraction in the right eye was found normal, the left eye having still no perception of light. By placing a +7 lens in front of the right eye binocular vision was reduced to 6/18. On then covering up the left eye, vision in the right was reduced to 6/60. The fallacy was pointed out to the patient, who agreed that he must have been seeing something with his left eye. Immediately thereafter, not only did perception of light return to the left eye, but also the power of reading. A week later, vision was equal in both eyes, amounting to 6/9.

Hysterical Deafness and Anosmia.—A soldier was blown up into the air

by a shell-explosion, but not rendered unconscious. He immediately became deaf in both ears, previously having had normal hearing. He had no bleeding from the ears, nor any otorrhœa, before or after the explosion. For thirteen days he complained of headache. There was no nausea or vomiting.

When examined, fifteen days after the original explosion, his speech and articulation were normal. He could not smell peppermint nor tobacco with either nostril. The visual fields and visual apparatus were normal. Taste was normal. There was total deafness of both ears, both to aerial and bone-conduction, but thermic nystagmus was normally elicited on irrigation of either ear. He spoke in a normal voice in reply to questions, all of which had to be written down owing to his total deafness. There was total anæsthesia and analgesia of the head and neck down to a guillotine-line at the level of the larynx (see Fig. 297), in which area pins have transfixed the skin of the cheek and forehead.

A fortnight later, the anæsthesia of the head had disappeared, but he still remained totally deaf. The functional nature of his affection was then carefully explained to him, and he was told to keep his eyes fixed on his watch at five o'clock, and to listen at the moment when a signal-gun was due to be fired. This he did, and succeeded in hearing the gun. Immediately his hearing became perfectly normal and remained so. Smell was also found to have returned.

Hysterical vomiting sometimes occurs. It is due to the perpetuation, by auto-suggestion, of vomiting which was originally induced by some organic cause, *e.g.* by the fumes of a gas-shell, by nauseous smells, or by such ordinary causes as gastro-intestinal disorders or vomiting after anæsthetics, so that the hysterical patient continues to vomit several times a day for weeks or months, long after the original causal condition has cleared up.

Hysterical meteorism is a curious abdominal syndrome most frequently met with in soldiers serving as orderlies in military hospitals. It appears to be produced by tonic diaphragmatic spasm. The patient rapidly develops diffuse abdominal distension, sometimes to a grotesque extent, but without vomiting. Sometimes there is constipation. The abdomen is tympanitic as a whole, but here and there we sometimes find areas of local dulness on percussion and sometimes curious resistant lumps on deep palpation, shifting in position from day to day. The abdominal wall is convex and rigid, so much so that the question of surgical intervention, for which the patient announces himself perfectly willing, is nearly always considered. The temperature, however, is normal and the blood-count shows no excess of leucocytes. Most dramatic of all, the administration of a general anæsthetic causes the whole swelling to collapse like a pricked bubble. Sometimes, however, the condition reappears as the patient comes round from the anæsthetic. But cure is promptly effected in all cases by persuasion.

Hysterical tremors are common in war-time. They resemble the emotional tremor of fear, but generally develop a coarser rhythm as

time goes on. They are reinforced by auto-suggestion, and persist long after the original emotion which caused them has passed away. Such tremors are always associated with more or less rigidity of the affected muscles, constituting what Meige has called "fixité trémulante." They can usually be cured if the rigidity be overcome. This we attain by persuasion and re-education, combined with gentle massage and passive movements of the limb. As the muscular spasm relaxes, the tremor clears up.

Hysterical convulsive attacks, of the most dramatic and extravagant type, are also met with in war-time. The original attack is a sudden reaction, in a highly suggestible patient, to some emotional experience. Recurrent attacks are generally replicas of the original seizure. They can easily be induced by emotion, but are commonest in the presence of a sympathetic audience and practically never occur when the patient is alone. Their chief diagnostic features have already been described (p. 384).

Hysterical paralyses and **contractures** may affect the upper or lower limbs. Many of them have their starting-point in some initial local trauma, associated with transient pain. To ease his pain, the patient instinctively assumes some unusual attitude, and by auto-suggestion this posture becomes fixed, long after the original cause of pain has cleared up. As Meige neatly puts it, "l'habitude crée l'aptitude à l'attitude."

4. **Reflex Paralyses.**—This interesting group of paralyses, before the war, used to be confused with hysteria. Now, however, chiefly owing to the observations of Babinski and Froment, we are able to distinguish the condition from hysteria, with which it is sometimes combined. Its clinical phenomena, of which the most notable features are the cutaneous hypothermia and muscular hyper-excitability of the affected limb, have already been described on pp. 392-393, and it is unnecessary to recapitulate them here. The condition, when well marked, is not likely to be overlooked by those who are familiar with the syndrome, but it must not be forgotten that reflex paralyses may coexist either with a hysterical paralysis or with an organic nerve-lesion of the affected limb, as will be seen from the following examples:—

Reflex paralysis of left hand, combined with organic lesion of median nerve. A soldier was wounded by a bullet which traversed the left forearm, entering it in the flexor aspect, between the radius and ulna, half-way between the wrist and elbow, and passing out through the back, half an inch lower down. The wound was septic and took over three months to heal.

When examined, seven months after the injury, there were signs of partial paralysis of the median nerve, consisting in loss of sensation in

three-and-a-half digits, and in a corresponding area of the palm. There was no paralysis of any individual muscle supplied by the median nerve, save one, the abductor pollicis, which did not react to faradism. Joint-sense was normal in all the digits. There were no trophic changes in the skin, hairs or nails.

The whole hand, however, was cold and blue, especially the index and middle finger, and there was increased excitability of the thenar and interossei muscles to direct percussion—muscles which were neither wasted nor paralysed.

Reflex paralysis of left knee, combined with lesion of anterior crural nerve and with hysterical gait. A Welsh soldier, twenty-two years of age, sustained a bullet-wound of the left thigh. The bullet entered through the middle of the quadriceps extensor and was extracted by an incision two inches higher up, and an inch to the inner side.

When examined, eleven months later, he showed a highly dramatic and typically hysterical gait. He avoided resting any weight on the left leg, and performed a curious sudden bending movement of the right hip (like the "dip" of a two-step dance) at each step. There was an area of total cutaneous anæsthesia at the outer side of the knee, reaching to the outer border of the patella, evidently from a lesion of a cutaneous branch of the anterior crural nerve. There was wasting and loss of faradic excitability in the vastus internus muscle. The remainder of the quadriceps, including the rectus and crureus, was normal, so that the patient could extend the knee against gravity and even against moderate resistance. The knee-jerks and ankle-jerks were brisk on both sides.

The left knee, however, was markedly colder than the right and slightly blue. The left crureus was hyper-excitable to direct percussion.

It should be particularly observed that this man's limb was freely movable, so that the phenomena of reflex paralysis cannot be attributed merely to secondary changes occurring in an immobile limb.

5. **Neurasthenia or Exhaustion-Neurosis.**—This is probably the least frequent of the war-neuroses, although the term neurasthenia has been widely, loosely, and often wrongly, used by inaccurate observers.

The onset of neurasthenia is usually gradual. The condition follows prolonged physical or mental exhaustion, *plus* emotional strain, but usually without any sudden or dramatic shock. Neurasthenia may also supervene after fevers or other severe illnesses. Amongst its symptoms (as already described in a previous chapter), the chief is a feeling of excessive fatigue on slight physical or mental effort. The patient is often gloomy, introspective, and disinclined for exertion of any kind. He has marked deficiency of mental concentration. He may also suffer from asthenopia, vague neuralgic pains, gastro-intestinal or vaso-motor atony with low blood-pressure, or from other vegetative symptoms.

Neurasthenia is relatively commoner in officers than in men, probably owing to the officer's greater responsibility, and is usually associated with malnutrition. It is rare to find a fat neurasthenic.

6. **Psychasthenia or Mal-adaptation Neurosis.**—This is essentially a congenital or endogenous neurosis, although its clinical phenomena may be precipitated and aggravated by emotional shock. The psychasthenic patient in war-time shows the same characteristic stigmata as in peace:—tics (especially of the head, face or shoulder-muscles), obsessions, and phobiæ (especially phobiæ of loud sounds, resembling those of shell-fire, or sounds resembling the hum of aeroplanes). It should be remembered that true tics, *e.g.* the "dodging-reflex," in which the patient "ducks" as if under imaginary shell-fire, do not arise by suggestion from without, nor by imitation from other patients, but are originally psycho-motor reactions, of a primitive, infantile kind, for the purpose of relieving some primary discomfort of sorts; these subsequently become stereotyped by constant repetition.

In the diagnosis of psychasthenia a previous history of psychasthenic tendencies in childhood or adolescence is of great importance. Patient inquiry is often required to elicit this. A peace-time tic or obsession, which had perhaps become latent or apparently disappeared, may be lighted up again by the strain of war, and exaggerated in intensity. In other words, war may reveal a latent psychasthenia, but does not cause it.

7. **Anxiety-Neurosis.**—This is characterised by the occurrence of paroxysms of terror and emotional anguish. The patient is usually a man of neuropathic temperament, but not necessarily a coward. On the contrary, he sometimes shows conspicuous courage at critical or dangerous moments. At ordinary times, between his paroxysms, the patient with anxiety-neurosis may be apparently quiet and placid; or he may be preoccupied and mildly depressed, but not continuously so. He sleeps badly, and is disturbed by nightmares in which war-scenes are reproduced. In addition, he is subject to paroxysms of intense terror and emotion, with palpitation, disordered breathing, sweating, tremor, etc. Sometimes these paroxysms occur suddenly and causelessly by day; sometimes they come on at night, when the control of the waking state is diminished, either just as he feels himself dropping off to sleep, or as the climax of a nightmare, waking him up. Anxiety-neurosis, although not confined to officers, affects them more frequently and usually more severely than private soldiers. This is partly due to differences in previous training and education between officers and men, and partly to the greater responsibility of officers.

Alcoholic patients are more prone than others to this neurosis, but alcohol is only an aggravating, not an essential factor. The essential element in its causation is the recollection of a previous emotional shock, which the patient (often upon medical advice) has been vainly

trying to repress by an effort of will, shutting it deliberately out of his attention.

Patients suffering from anxiety-neurosis are often markedly benefited by patient investigation of their mental content. After obtaining a careful history as to the starting-point and development of the neurosis, we then interpose re-educative suggestions, encouraging the patient to face his unpleasant memory courageously, instead of running away from it, *i.e.* to recognise it as an unpleasant memory and nothing more. Of course, he must not allow himself to go to the opposite extreme of morbid brooding over his original emotion, so as to exaggerate or distort its significance. When this has occurred, relief is best attained by the patient confiding his trouble to a kindly adviser. Insomnia must also be carefully treated. Return of natural sleep and recovery of body-weight are two of the best signs of convalescence.

8. **Fright-Neurosis, Vegetative-Neurosis or Dys-Thyroidism.**—This occurs chiefly in young soldiers of sympathetico-tonic type, in whom the sympathetic fibres are specially sensitive to adrenalin, unlike their autonomic or vago-tonic comrades, who react specially to cholin (see p. 339).

The emotion of fear normally liberates an excess of adrenalin into the blood-stream. In some individuals severe emotional shock may induce temporary mental confusion, amounting almost to stupor, but never to unconsciousness as in cerebral concussion. Some of these are instances of latent dementia præcox with katatonic stupor, which we have already studied. Others again are simply examples of intense temporary mental confusion, during which the individual is not fully aware of what he is doing. He may remain inactive, trembling with fear. Or he may perform senseless automatic actions. Thus, I remember one man at Gallipoli who during a specially intense bombardment stripped his clothes off and ran round and round, unclothed, in the "no-man's land" between the opposing trenches. The stage of transient mental confusion, however, may be only slight in degree. It is quickly followed by a stage of compensatory hyper-activity of the thyroid and other chromophile glands, during which the characteristic facies of fear or apprehension occurs, with prominent eyes, fine tremor of the limbs, rapid heart, etc. In a normal individual these phenomena are also transient. But in abnormal conditions the symptoms may become chronic, although they rarely persist in a complete form. Thus the oculo-pupillary signs may subside, partially or entirely, whilst the fulness of the thyroid gland may be rudimentary or absent. The most persistent symptom is chronic rapidity of the pulse. Such cases, with persistent tachycardia, constitute an important variety of "soldier's heart." One of the most constant diagnostic physical signs of dys-

thyroidism is the relative lymphocytosis of the blood, so that the proportion of lymphocytes may rise to 40, 50, or even 60 per cent. In about half of these cases the systolic blood-pressure is abnormally high, suggesting a persistent excessive activity of the suprarenal bodies: super-adrenalism.

Fig. 298 is that of a young soldier, aged twenty, who, after exposure to continuous shell-fire for six weeks on the Gallipoli Peninsula, developed a hysterical gait, together with palpitation of the heart.

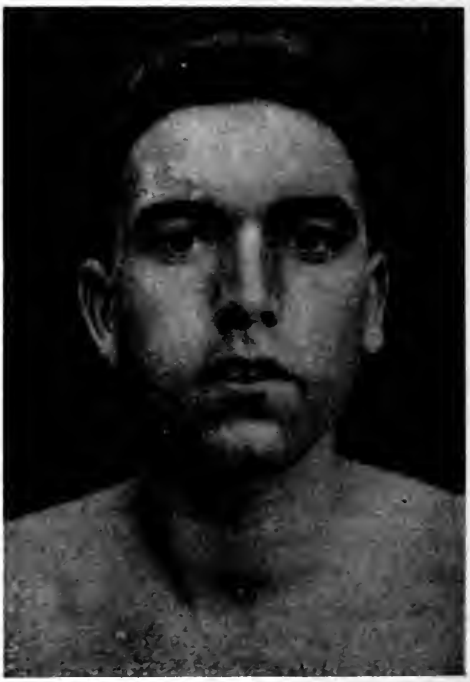

FIG. 298.

Hyperthyroidism and hyper-adrenalism resulting from emotional shock.

On examination, two months later, he showed distinct fulness of the thyroid gland, fine tremor of the outstretched hands, and a rapid pulse of 160 per minute. The left palpebral fissure was slightly wider than the right, and the left eye projected a little. There was also some delay in the descent of both upper lids. The leucocyte count showed 44 per cent. of lymphocytes and 56 per cent. of polymorphs. The systolic blood-pressure measured no less than 194 mm. of Hg; in a month this fell to 150 mm.

9. **Epilepsy.**—This, of course, is not a psychogenic neurosis, and at first sight it may seem illogical to refer to it when discussing war-neuroses. But epilepsy sometimes appears, for the first time, after the strain of a prolonged campaign, less commonly after an emotional shock. In both instances, the patient was already a latent epileptic,

and the majority of war-epileptics, when carefully inquired into, give a history of epileptiform attacks, major or minor, in pre-war days.

Sometimes epilepsy follows an organic injury of the brain. This is not merely after lesions in the neighbourhood of the motor cortex, but from injuries anywhere in the brain. In traumatic epilepsy the epileptic attacks may first appear after a long interval, perhaps many months, when the original brain-injury has long since healed. Hence the importance, in every case of brain-injury, of prolonged rest and sedative treatment, so as to counteract any possible epileptic tendency in the future.

10. **Combinations of the foregoing syndromes** occur in innumerable varieties of intermediate and mixed cases. Thus, for example, a patient with cerebral concussion may either recover completely in a few hours or days, or he may develop symptoms of concussion-neurosis as above described. Superadded to this, by auto-suggestion or by suggestion from without (whether from injudicious friends or from medical officers), he may develop hysteria. Similarly a patient suffering from fright, or from neurasthenia, or from some local organic lesion, may have hysterical symptoms superadded; and so on. In every case it is of the utmost importance to analyse the symptoms with scrupulous care, so as to recognise the different factors involved.

Moreover, war-neuroses are not synonymous with shamming or malingering, the characteristics of which we have already considered (p. 359).

Finally, the presence of hysterical phenomena is not necessarily associated with actions of cowardice in danger. On the contrary, we occasionally meet with instances of hysteria in soldiers who have behaved with conspicuous gallantry.

Thus, for example, a left-handed Irishman at Gallipoli, during an encounter with the enemy, bayoneted ten or twelve men single-handed. He sustained numerous bayonet-wounds himself in the combat, all on the right side of his trunk or limbs, for which he was admitted to hospital.

On examination a few days later, he was found to have right-sided hemi-anæsthesia of the trunk and limbs, of typically hysterical character, together with a hysterical spasm of the right thumb, where one of his wounds was situated. Under curative suggestions, both sensory and motor paralyses completely disappeared. This man was recommended by his commanding officer for the Victoria Cross.

INDEX

Abadie's sign of tabes, 190, 200
Abdomen, wall of, motor points (Erb's diagram), 402
Abdominal distension, hysterical, 551
— reflex, significance of absence, 314
— sympathetic, diseases of, pigmentary changes, cutaneous, 350
— — — visceral disorders of, 349
Abductor palsy of larynx, 161, 162
Aboulia, 364
Abscesses of brain, 463, 477
— — aphasia from, 98
— — cerebro-spinal fluid in, 422, 424
— — fits due to cortical, 71
— — headache due to, 168
— — meningitis, and differential diagnosis, 61
Absinthe poisoning, coma and convulsions from, 69
"Acetone" breath, 62
Achilles-jerk, 321
Achromatopsia, 120
Acromegaly, 121, 289, 455
— transient, in pregnancy, 25
Acro-paræsthesia, 351
— hysterical, following wound of elbow, 547
Active muscle sensation, 186
Addison's disease, 350
Adductor foot reflex, 316
— paralysis of larynx, 162
Adhesions, meningeal, in brain wounds, 472
Adiposis dolorosa (Dercum's disease), 288
Adiposo-genital dystrophy, 456
Adrenalin excess in blood-stream, 537
Aerial conduction, 151
Aërophagy, 395
"Affekt-epilepsie" in pyschasthenia, 70
Afferent impulses, 2, 13 *et seq.*
— — path of, 12, 13, 15
Ageusia, 140
Agnosia, 105
Agoraphoria, 366
Agraphia, 97, 103
Aichmophobia, 366
Air-swallowing, 395
Akinesia algera, 185
Albinism, nystagmus in, 131
Albumin, excess in cerebro-spinal fluid, 418
Albuminuria, orthostatic, 349
Albuminuric retinitis, diagnostic significance, 70
Alcohol, intolerance to, after concussion, 541, 545
Alcoholism, amblyopia of, 120
— articulation in, 110
— ataxia, 260
— coma and convulsions, 61, 69
— facial paralysis in, 149
— factor in nervous diseases, 49
— gait in, 281
— insomnia in, 441
— men and women, effects in, 49
— neuritis from, 49
— — multiple, 201, 227
— paralysis. *See* Neuritis
— Quinquaud's sign, 81
— toxic vertigo, 155
— tremor, 81
Alexia, 101
Algia, hysterical, 547
Algid type of malaria, 350
Allocheiria, 188, 191, 383
"Allongement croisé, phénomène d'," 215
Alopecia, localised, 302
— universal, 303
Alternate paralysis, 204, 212, 461
Amaurosis, 381. *See also* Blindness, hysterical
Amaurotic family idiocy, 123
Amblyopia, crossed, 39, 120, 121
— — in hysteria, 381, 382
— — in tumours, 451
— tobacco, 120
— traumatic, 382
Ambulatory automatism, 69, 386
Ammonium sulphate test for globulin, 418
Amnesia, retrograde, 54
Amœbic brain abscess, 463
Amyotonia congenita, 274
Amyotrophic lateral sclerosis, 78, 109, 216, 220, 323
Amyotrophy, neurotic, progressive, 221
Anæmia, cerebral, causing sleep, 433, 435
— — causing vertigo, 154
— — due to hæmatoma, 473
— — headache of, 168, 170
— — mydriasis in, 124
— — optic neuritis, 122
— — primary thrombosis of, sinuses in, 59
— — tinnitus in, 153
Anæsthesia, 193
— auto-exploration of sensibility, 189
— cortical, 190
— crossed, 14
— cutaneous, 33, 35, 200, 223, 482

Anæsthesia, dissociated, 191, 193, 258
— dolorosa, 174, 182
— hemi-anæsthesia. *See that title*
— hysterical, 193, 375-380
— — diagrams, 376-380
— — mode of disappearance, 380
— leprous, 201
— mapping of areas, 187, 202
— in multiple neuritis, 201
— para-anæsthesia, 191, 197
— in peripheral neuritis, 183
— — palsies, 200
— spinal, after-effect of, 432
— — contra-indications to, 432
— — mode of inducing, 429-432
— of spinal lesions, 196
— — — incomplete, 198
— tabetic, 198
— tactile, 191
— thermo, 191, 198
— in tubercula dolorosa, 183
— universal, of hysteria, 193, 194
Anæsthetics, delayed poisoning by, 63
— spinal, examples of solutions, 430 *note*
Anal reflex, internal, 329, 332
— reflexes, superficial, 313, 317
Analgesia, 191, 199
— in tabes, 191, 199
Anarthria, articulative, 97, 104
Aneurisms, intra-cranial, 152, 463
— pulsating sounds with, 152, 463
Angina pectoris, 176, 349
Angio-neuroses, 48, 350-357
Angio-spastic hemiplegia, 248
Anidrosis, localised, 345, 355
Anisocoria, 124
Ankle-clonus, 214, 278, 324
— inhibition of, 214
—.spurious, 214, 325, 394
Ankle-jerk, 321, 324
Ankylostomiasis, 438
Anorexia nervosa, 287, 395
Anosmia, 47, 74, 116, 142
— hysterical, 550
— with brain tumours, 488
Anterior cornua, cells of, 2, 27, 78
— — deep reflexes, loss of, 323
— — lesions, 78, 217-221
— — motor palsy in, 217, 219
— — — tract through, 2, 27
— — posture in muscular paralysis from, 262
— crural paralysis, 224-226
— nerve roots. *See* Spinal Nerves, Roots
— polio-myelitis (infantile paralysis), 218-220
— — acute, 218
— — chronic, 219
— — loss of deep reflexes in, 323
— transverse gyrus of Heschl, 39, 96, 451
Anthropophobia, 366
Antrum of Highmore, empyema of, 116
Anuria, hysterical, 397
Anxiety-neurosis, 554
Aphasia, 95 *et seq.*
Aphasia, auditory, 96, 99, 451
— cortical centres involved in, 96, 97, 102
— dysarthria distinct from, 107
— functional or temporary, 98
— hysterical, 104
— lachrymosity in, 49
— Marie's views, 97, 104
— motor, 96, 97, 102, 103, 449
— scheme for investigation of, 98
— sensory, 96, 97, 100-102
— sub-cortical, 99
— — motor, 103
— total, 104
— visual, 96, 101
Aphemia, 97
Aphonia, hysterical, 113, 161, 371, 398, 548
Apoplexy, diagnosis of, 63, 418
— delayed traumatic, 57
Appendicitis, pseudo-, 396
Apraxia, 105
— in callosal tumour, 454
— in relation to corpus callosum, 106
— mode of testing for, 105
Arachnoidal sac, 414
Argyll-Robertson phenomenon, 126
Arithmomania, 366
Arm, cerebral paralysis of, 5
— sensory fibres from, 16
Arsenical poisoning, cutaneous affections, 299
— — multiple neuritis due to, 228
Arteria fossæ Sylvii, 42
Arteries at base of brain, 42
— cerebellar, 43
— cerebral, 41, 42
— — thrombosis of, and coma, 59
— — diseases of, 56
— of spinal cord, 43
Arthritic muscular wasting, 237
Arthropathies, 305-311
Articulation, disorders of, 107-115
— — alcoholic, 110
— — ataxic, 109
— — in acute cerebellar lesions, 109
— — in bulbar palsy, 109
— — in chorea, 112
— — deaf-mutes, 113
— — in disseminated sclerosis, 109
— — in facial palsy, 108
— — in Friedreich's ataxia, 110
— — functional cortical disturbance, 112
— — in general paralysis of insane, 110
— — hysterical, 113, 372
— — idioglossia, 115
— — infra-nuclear and nuclear affections of, 108
— — lalling and lisping, 114
— — in laryngeal tabes, 110
— — in paralysis agitans, 111
— — — of palate, 108
— — stammering, 112, 372
— — supra-nuclear affections of, 110
— — tests of, 107
— — tics of, 113
— distinguished from speech, 107

Asphyxial convulsions, 69, 73
Associated movements, 85, 208
Astasia-abasia, 278, 390, 398
Astereognosis, 190
— in lesions of parietal lobe, 483
— with brain tumour, 451, 452
Asthenia, cerebellar, 23
— in neurasthenia, 362
Asthenic bulbar paralysis (myasthenia gravis), 109, 244
Asthenopia in neurasthenia, 362
Asthma, dyspnœa of, 351
Astigmatism, headache of, 170
Asynergia, 258, 455, 458
Ataxia, 252
— alcoholic, 260
— articulative, 109
— cerebellar, 256, 258
— in disseminated sclerosis, 254, 260
— Friedreich's, 110, 256
— gait in, 279
— hereditary cerebellar, 258
— olivo-ponto-cerebellar, 258
— tabetic, 254
— vestibular, 255
Ateleiosis, 457
Athetosis, 48, 85, 86, 260
— figures of case, 86
— bilateral, 111
Atonia, cerebellar, 24
Atopognosis, 188
Atrophy, acute yellow, coma of, 64
— muscular, 203, 236
— — arthritic, 237
— — in hysteria, 239, 392
— optic, 123
— progressive, 219
— Werding-Hoffmann type, 220
Auditives and visuals, 98
Auditory aphasia, 96, 99, 104
— — of brain tumour, 451
— — cortical and sub-cortical, 103
— centre, 39, 96, 97
— gyrus (Flechsig's), 39, 96
— nerve, affections of, and tests, 151
— path, 39
— tumours of, 460
— word centre, 96
Aura preceding epilepsy, 66
Auriculo-ventricular muscle-bundle of Kent and His, 74
Auto-exploration of cutaneous sensation, 189
Automatic movements, conjugate, 86, 276
Automatism, 3
— ambulatory, 69
— hysterical, 386
— post-epileptic, 68
Autonomic nervous system, 336
— — — lesions of, 349, 350
— — — relation to drugs and glands, 338
— — — vagal fibres of, 158, 159, 336, 338
Auto-suggestion in war-neuroses, 539
Avellis's syndrome, 159
Babinski's combined flexion of hip and trunk, 206
— extensor plantar reflex, 315, 316
Bacillus botulinus, 137
Back, "bent," type of war hysteria, 548
Bárány's pointing tests, 22, 255
— thermic nystagmus, 130
"Barbed-wire" psychosis, 544
Basilar artery, 41
Bastian's law, 326
Bechterew-Mendel reflex, 326
Bedsores, 48, 231, 295
— absence of, in hysteria, 397
Bell, nerve of, 227
Bell's paralysis, 145
Benedikt's syndrome, 83, 212, 455
Beri-beri, 228
Biceps muscle, atrophy from anterior cornual lesion, 263
— — innervation of, 35
— — reflex, 318
Biernacki's sign in tabes, 199
Bikeles's sign in brachial neuritis, 178
— — in meningitis, 60
Birth convulsions, 73
Bisection test in hemianopia, 119
Bi-temporal hemianopia, 121
Bladder, disorders due to lesions of cord or cauda equina, 331, 332
— dribbling from, 330
— in hysteria, 394
— innervation of, 331, 332
— reflex, 329, 330
— — centres for contraction, 329, 330
Blanching of hair, 302
"Bleeding diseases," cerebral hæmorrhage in, 56
Blepharo-spasm, 92, 383, 386
Blindness in amaurotic family idiocy, 123
— hysterical, 382, 549
— lesions causing, 485
— quinine, 120
Blood-pressure in coma, 55
— effect of pituitary secretion in, 25
Blood-vessels, angio-neurosis affecting, 350-357
Blue-blindness, 120, 444
Blue œdema, hysterical, 397
Bones, brittleness in disease, 305
— convulsions following injury of cranial, 72
— sensory fibres from, 15
— trophic changes in, 303-305
Botulism, 137, 438
Brachial neuralgia, 178
— neuritis, 178
— paraplegia, 204
— plexus, lesions of, 344
— — axillary, 523, 526, 527
— — peripheral, 522
— — supra-clavicular, 525, 526
— — wounds of, 522
Brain, abscess of, 72, 98, 169, 424, 464, 477
— anæmia of, 154, 433
— anatomy and physiology, 1-45
— arterial supply, 41-43

Brain, bullet-wounds of, 473
— circulation in, arterial, 41
— — venous, 44
— concussion of, 53, 541
— — headache after, 171
— cortex, histology of, 4
— foreign bodies in, 470
— hæmorrhage. *See under* Hæmorrhage, cerebral
— hyperæmia of, 154
— injuries, focal signs of, 479-495
— — cerebellar, 490
— — frontal, 487
— — occipital, 485
— — organic lesions, 493
— — parietal, 489
— — post-central, 482
— — pre-central, 479
— — pre- and post-central, 483
— — temporal, 488
— lesions, palsies due to, 5-8
— — sequelæ after, 492
— localisation of function, 4-9
— membranes, innervation, 167
— motor areas, localisation of, 4
— protective coverings of, 466, 467
— sensory tracts in, *facing* 15
— softening, traumatic, 476
— traumatic hæmorrhage with "compression," 56
— tumours. *See under* Tumours, intracranial
— wounds of, 466-495
— — pathological results: abscess, 477; hæmorrhage, 473; hernia cerebri, 478; meningitis, 477; œdema, 477; optic neuritis, 479; protective coverings of, 466, 469; softening, 476
Breathing in cerebral concussion, 53
— in hæmorrhage, 55
— in diabetic coma, 63
— in hysterical trance, 64
"Breites Bein," Heilbronner's, 268
Brissaud's reflex, 315
Broca, cortical centre of, 43, 98, 104
Brown-Séquard paralysis, 9, 17, 191, 197, 212, 504
— — diagram of symptoms of, 17
Brudzinski's sign of cerebral meningitis, 60
Bulbar palsy, 109
— — articulation in, 109
— — lachrymosity in, 49
— — mixed electrical reactions in, 411
— — pseudo-, 111, 212
— — tongue tremors in, 78
— — unilateral syndrome, 257
— paralysis (glosso-labial laryngeal paralysis), 78, 109
— phenomena in Ménière's disease, 156
Bulbo-cavernosus reflex, 317
Bullet-wounds of the brain, 473
Bursting fractures with extensive brain contusion, 471

Cadaveric reaction, 408
Caisson disease, 181
Calcarine fissure, 38
— — lesions of, 122, 453
Calmette's ophthalmo-reaction, 464
Camptocormia, 270, 548
Capsule, internal, 5, 7, 210
Carbonic oxide poisoning, 542
Carcinoma of brain, 444
— coma of, 63
Caries (dental), headache due to, 163
— neuralgia due to, 173
— spinal, root pains with, 182
Carotid artery, hemiplegia following ligature of, 493-495
Carpo-metacarpal reflex, 318
Case-taking, method of, 46-52
Catalepsy, 68, 385
— cerebellar, 24, 459
Cataract as cause of nyctalopia, 118
— and tetany, 76
Catheterisation, rigor following, 77
Cauda equina, injuries of, 529
— — lesions of, 229-231, 507, 529
— — — anal anæsthesia from, 332
— — — bladder trouble in, 331
— — — bulbo-cavernosus reflex, loss of, 317
— — — bullet-wounds, 230, 507, 529
— — — gait in, 282
— — — motor paralysis due to, 229
— — — recto-perineal pain in, 182, 231
— — relations with vertebral column (diagram), 414
Caudate nucleus (diagrams), 6, 7
Causalgia, 183, 356, 519
Cavernous sinus, thrombosis of, 45
Cells, nerve, physiology of, 1
Cenæsthopathy, 337
Central scotomata, 119
— — for colours in tobacco amblyopia, 119, 120
— — in migraine (transient), 119
— — in retro-bulbar neuritis, 123
Cephalalgia, 168
Cerebellar atonia, 24
— catalepsy, 24, 459
— fits, 76
— gait, 259
— hypotonia, 24
Cerebellum, anatomy and physiology of, 18
— arterial supply, 43
— ascending tracts in connection with, 29
— ataxia or asynergia, 23, 257, 258, 458
— cerebello-fugal fibres of, 20, 21
— cerebello-petal fibres of, 20
— connections of (diagram), 21
— cortex, low excitability of, 21
— — motor centres in, 22
— destruction, results of, 23
— equilibrium, co-ordinating centre for, 21 153
— indirect action on spinal cord, 21
— intoxication of, 110, 260
— lesions of, and disorders of articulation, 109
— — ataxia due to, 253, 258, 259

Cerebellum, lesions of, attitude in (fig.), 282, 459
— — bilateral, 491
— — dysarthria in, 110
— — dys-diadocho-kinesia, 259, 458
— — fits due to, 76, 459
— — forced rotatory movements, 459
— — gait in, 281
— — hypotonia in, 24, 274
— — knee-jerks in, 321
— — motor effects of, 21, 22
— — nystagmus in, 113
— — skew deviation of eyes from, 136, 459
— — unilateral, 490
— — vertigo in, 153, 155
— lobes of, 18
— nuclei within, 19
— peduncles of, 20, 153
— pointing tests in lesions of, 22, 259
— section through (diagram), 19
— stimulation of, results of, 23
— tracts leading to and from, 19
— tumours of, 155, 171, 282, 458, 459
— wounds of, 490, 491
Cerebral arteries, posterior, 41
— — thrombosis of, and coma, 59
— artery, anterior, 41
— — middle, 42
— ataxia, 260
— irritation, 54, 472
— localisation, 4
— meningitis, coma from, 60
— sinuses, thrombosis of, 45, 59
— *See also under* Abscesses, Brain, Hæmorrhage *and* Tumours
Cerebro-spinal fluid, 48, 413-432, 467
— — bacteria in, 422
— — cells of, 417, 423
— — in cerebro-spinal syphilis, 425-427
— — chemical characters, 418
— — coagulation, massive, in, 419
— — colloidal gold-reaction of, 420, 421
— — cytology of, 423
— — lymphocytosis in, 69, 175, 250, 295, 423
— — microscopic examination of, 422
— — parasites in, 423
— — permanganate reaction of, 420
— — physical characters, 417
— — pleocytosis in, 423
— — in polio-encephalitis, 73
— — in polio-myelitis, 424
— — pressure of, 416
— — puncturing for. *See* Thecal puncture
— — source of, 413
— — tumour cells in, 423
— — Wassermann reaction in, 419
— — xanthochromia of, 419
Cerebrum, sensory tracts of (diagram), 14
Cervical plexus, 29, 30
— region of cord, lesions in, 125, 204, 212
— — — muscular localisation of, 35
— sympathetic, course and distribution, 123, 139, 163, 340
Cervical sympathetic, in diagnosis, 48
— — excision of, 347
— — lesions of, 341, 349
— — oculo-pupillary fibres, course of, 340
— — paralysis of, from brachial plexus rupture, 344
— — — from tumour, 342
— — — symptoms of, 341
— — stimulation of, 343, 348
— — — clinical, 347
— — sweat fibres supplied by, 346
Cervico-brachial plexus and its branches, 29
Charcot's "grand hystérie," 384
— "migraine ophthalmoplégique," 138
— tabetic joints, 306
Charcot and Marie's progressive neuritic amyotrophy, 221
Chemosis, 45
Chloral poisoning, tremor in, 81
Chloroma, cerebro-spinal fluid in, 424
Chorda tympani, 140, 144, 147, 150
Chorea, 84
— articulative defects in, 112
— ataxia in, 260
— bedsores in, 295
— gait in, 285
— Huntington's, 85
— hyoscine, 85
— rheumatic, 84
— tic distinct from, 89
Choroid artery, anterior, 41
— gland, 413
Chvostek's sign in tetany, 75
Cigarette smoking, toxic effects of, 81
Ciliary ganglion, 124, 136
— — degeneration, 136
— — (diagram), 126
— muscle, innervation of, 124
— — (diagram), 126
Cilio-spinal centre (diagram), 340
— reflex, 48, 327, 343
"Circle of Willis," 41
Circumflex nerve, 30
Circumvallate papillæ, 141
"Claudication intermittente," arterial, 181, 185, 247, 354
— cerebral, 248
— spinal, 248
— unilateral and intermittent, 535
Claustrophobia, 366
Clavus hystericus, 171
"Claw-hand," 265
Clonus, 324-327
— inhibition of, 324
— pseudo-, 325, 394
Cocaine, injection by thecal puncture, 429
— ocular phenomena produced by, 125, 343
— tremor due to, 81
Coccygodynia, 178
Cochlear fibres, auditory nerve, 39, 40, 150
— and vestibular nerve connections (diagram), 40
Coffee and tea poisoning, tremors in, 81

Cold sensibility, tests for, 187
Colitis, muco-membranous, 349
Colour-blindness, 118
Colour vision, tests for, 118
Coma, 52-64
— from acute encephalitis, 59
— of acute yellow atrophy, 64
— of alcoholic intoxication, 61
— bladder trouble in, 331
— carcinomatosum, 63
— from cerebral concussion, 53
— — hæmorrhage, 55
— — meningitis, 60
— from chronic subdural hæmorrhage, 57
— diabetic, 62, 438
— — ocular tension in, 63
— diagnosis and causation, 53
— hysterical trance and, 64
— malarial, 63
— of opium poisoning, 61
— of pontine hæmorrhage, 59
— post-epileptic, 62
— and sleep, 436
— in Stokes-Adams syndrome, 62
— in sunstroke, 63
— in thrombosis of cerebral arteries, 59
— — — sinuses, 59
— toxæmic, 61
— from traumatic cerebral compression, 56
— uræmic, 62, 438
"Coma-vigil" of typhus, 64
Combined flexion of hip and trunk, 206
Comminuted fractures of cranium, 470
Commotio cerebri, 541
"Compensation-neurosis," 540
Compression, cerebral, 56, 472
— — headache after, 171
— of peripheral nerves, 517
Concussion of brain, 53, 472
— of nervous system, 541
— of peripheral nerves, 517
Concussion-lesions of spinal cord, 496
Concussion-neurosis, 545
Condenser discharges in electrical reactions, 409
Conditional reflexes, 333
Congenital ptosis, 138
Conjugate automatic movements, 86, 276
— — — in diplegia, 85, 86, 276
— — — in hemiplegia, 85, 86, 276
— deviation, 7, 135, 449
Conjunctival anæsthesia in fifth nerve paralysis, 141
— conjunctival reflex. *See* Reflexes, corneal
— nerve supply, 139, 140
Consciousness, double, 364, 385
Consonants, articulation of, 110, 114
Constipation, occipital headache of, 170
— spastic, 349
— toxic vertigo from, 155
Contracture of upper limb, hysterical, 547
Contractures, hysterical, 393, 552
— organic, 208, 267-269, 327
Contre-coup, 476
Contusion, cerebral, 53
Conus medullaris, lesions of, 230
Convulsions, 65-76
— generalised epileptiform, with cerebral tumours, 443
— infantile, 72
— from lead poisoning, 69
— strychnine, 74
— uræmic, 70
— *See also* Fits and Epilepsy
Convulsive attacks, hysterical, 552
Coprolalia, 89
Coprophobia, 366
Cordite-habit, 542
Corneal reflex. *See* Reflexes
Corona radiata, 5
Corpora dentata, 19
— quadrigemina, 11, 37, 39, 124, 454
Corpus callosum, relation to apraxia (diagram), 106
— — tumours of, 454
— striatum, 10
Cortex cerebri, arterial supply of, 42, 43
— — diagrams of, 4
— — lesions, 5
— — — anæsthesia due to, 195
— — — fits in, 71
— — — motor inco-ordination in, 260
— — — — palsy from, 5, 210
— — venous supply of, 44
Cortical anæsthesia, 190. *See* Anæsthesia
— cells in sleep, 434
— centres,
— — auditory, 39, 97
— — half vision, 37, 38, 452, 453
— — of hunger and thirst, 41
— — micturition, 330
— — motor, 4-8
— — — lesions of, 479
— — olfactory, 36
— — psycho-visual, 39
— — sensory, 5, 16, 196
— — — recognition of spatial relation, 16
— — of speech, 96, 97
— — (diagram), 96, 97
— — — maldevelopment, 114
— — of taste, 39
— — of vision, 37
— — of writing, 96
— localisation, 4
— word-deafness, 99, 100
Cortico-spinal motor neurone lesions. *See* Motor paralyses
— tract (diagram), 11
Cough, hysterical, 397
Craft palsies and cramps, 248
Cramp, 250
Cranial bones, headache from affections of, 168
— cavity, penetrating and perforating wounds of, 469, 470
— nerves, 116
— — abducens (sixth), 123
— — — — lesions of, 8, 124

Cranial nerves, abducens (sixth), paralysis of, 8, 45, 134, 137, 447, 461
— — auditory (eighth), 150-157
— — — — cochlear division, 39, 150
— — — — diagrams of, 117, 118
— — — — vestibular division, 150
— — facial (seventh), 144-150
— — — — lesions at different levels, 144-150
— — — — motor root, 144-150
— — — — secretory and taste fibres, course of, 39, 144, 147, 150
— — — — sensory root of, 39, 150
— — — — wounds of, 521, 522
— — glosso-pharyngeal (ninth), 39, 140, 157
— — — — course of taste fibres (diagram), 140
— — hypoglossal (twelfth), 163, 164
— — — — paralysis of, 163, 164
— — — — unilateral, 108, 522
— — nervus intermedius of Wrisberg, 39, 150
— — oculo-motorius, 123
— — — paralysis of, 83, 131, 211, 457, 520
— — olfactory (first), 36, 116
— — optic (second), 37, 117
— — patheticus (fourth), 123
— — — — paralysis of, 45, 133
— — recurrent laryngeal, paralysis of, 108, 160, 161
— — short ciliary nerves, 125
— — spinal accessory (eleventh), 161
— — — — paralysis, 162, 163
— — trigeminal (fifth), 139
— — — — cutaneous supply to head (diagram), 139
— — — — distribution of, 139, 141
— — — — incidence of rodent ulcers over, 296
— — — — lingual branch, 140
— — — — ophthalmic division, lesion of, 341
— — — — pains in region of, 173
— — — — paralysis of, 141, 142, 521
— — — — sensory root of, 14, 39
— — — — sweat areas corresponding with distribution of, 356
— — — — taste fibres, course of, 140
— — vagus or pneumogastric (tenth), 158
— — — — autonomic fibres of, 158, 336
— — — — paralysis of, 159, 521
— — vidian nerve, 139
— — wounds of, 492, 519-522
Cranio-cerebral topography, 3
Cranium, fractures of: bursting, 471; comminuted, 470; compound, 468; depressed, 468; fissured, 468, 470; gutter, 468; punctured, 468, 470
Cremasteric reflex, 313, 317
Crimes in post-epileptic automatism, 69
Crossed amblyopia, 39, 120, 121
— — in hysteria, 120
— — in tumours, 451
— anæsthesia, 14
Crossed amblyopia, hemi-anæsthesia, 15, 196
— paralysis, 8, 48, 204, 462
Crus cerebri, lesions of, 8, 83, 211, 455
— — — motor palsy due to, 211
— — — tegmental region, 83
Cuneate lobule, visual half-centres in, lesions, 122
Curtain movement of pharynx, in glosso-pharyngeal paralysis, 158
Cutaneo-gastric reflex, 327
Cutaneous areas of peripheral nerves, 32
— — of posterior roots, 33
— sensibility, 13, 187-190
— — loss of. *See* Anæsthesia
— — recovery of, 227
— — tests for, 187
Cyanosis, local, in anterior polio-myelitis, 355
— — in erythromelalgia, 352
— — in Raynaud's disease, 351
— of brain-tissue, 473
Cysticercus in fourth ventricle, diagnosis, 155
Cyto-diagnosis of cerebro-spinal fluid, 423-427

Dartos reflex, 327, 332
Deaf-mutism, 113
— in children, 113
— as war-neurosis, 114
Deafness, *facing* 147, 151, 156, 475
— due to drugs, 153
— hysterical, 152, 550
Decerebrate rigidity, 86
— — posture in, 86
Decompression paraplegia, 181
Decubitus, acute, 295
Deep sensibility, 12
Defæcation, 230, 312, 332
"Defensive" reflexes, 215
Deformities, gait in, 286
Degeneration, ascending, 28
— descending, 27, 28
— progressive lenticular, 84
— reactions of, 409
— of spinal cord combined, 254, 326
— Wallerian, 29
Deiters' nucleus, 19, 21
— — focal lesion of, 157
Delayed traumatic apoplexy, 57
Delirium, 48
— tremens, 49, 81
Deltoid, atrophy of, 218, 223
— paralysis from anterior cornual lesion, 262
— — from lesion of circumflex, 30
Dementia, bedsores in, 296
— paralytica. *See* General paralysis
— præcox, 546
Depressed fractures of cranium, 468
Dercum's disease (Adiposis dolorosa), 288
Dermatomes, 30
Dermographism, 133, 355
— in hysteria, 397, 398
Diabetes, bilateral, tic douloureux in, 173

Diabetes, breath in, 62
— coma of, 62
— insipidus, 349
— multiple neuritis due to, 228, 293
— optic neuritis in, 123
— perforating ulcers in, 293
Diadocho-kinesia, 259, 458
Diagnosis, anatomical and pathological, 50
Diaphragm, myoclonus of, 78
Diarrhœa, hysterical, 396
— paroxysmal, of Addison's disease, 350
— verborum, 371
Dilator pupillæ, 125, 139, 342
Diphtheria, neuritis after, 127, 228
Diplegia, 85, 204, 212, 276
— atonic-atasic type of, 277
— causes of, 5
— conjugate automatic movements in, 85, 86
— definition of, 204
— spastic, 276, 279
Diplococcus intra-cellularis, 422
Diplopia, 129, 134
— false image, position of, 129, 134
— gait with, 281
— monocular (hysterical), 383
— ocular vertigo with, 155
— tests for, 128, 129
Dipsomania, 365. *See also* Alcoholism
Disseminated sclerosis, absence of abdominal reflexes in, 314
— — ataxia in, 254, 260
— — clonus in, 325
— — emotional state in, 49
— — erythromelalgia a symptom in, 352
— — motor paraplegia due to, 304
— — nystagmus in, 131
— — optic atrophy in, 123, 126
— — staccato speech in, 110
— — transient paralysis in, 251
— — vertigo in, 155
— — in war, 493
Dissociated anæsthesia, 191
Disuse of injured limbs, 237, 392, 542
Dorsal longitudinal bundle, 11
Double consciousness, 365, 385
Dreams, distressing, 554
Drop-foot and drop-wrist in peripheral neuritis, 201, 227
Drowsiness, 47, 436-438
— hypnotic, 438
— pathological, 436-438
Drug-habits, 365, 542
Ductless glands, hyperactivity of, 537, 555
Dura mater, function of, 467
Dysæsthesiæ, 167, 197
Dysarthria, 107, 110. *See also* Articulation, disorders of
Dysbasia angiò-sclerotica, 247
Dysdiadocho-kinesia, 259, 458
Dysphagia, hysterical, 395
Dyspituitarism, 455
Dysthyroidism, 555
Dystrophy, muscular. *See* Myopathy
— myotonic, 246
Ear, auditory fibres of, 39
— disorders, gait in, 281
— — herpes of external auditory canal, 144, 150, 294
— — otitis media. *See that title*
— — tinnitus from, 144
— — vertigo from, 154, 156
— inner, afferent impulses from semicircular canals, 153
Echolalia, 89
Ectopia pupillæ, 125
Electricity, abnormal reactions, 408-412
— condenser reactions, 409
— faradic reactions, 405
— galvanic reactions, 405
— polar reactions, 406
— reactions of degeneration, 409
Electro-diagnosis, 400-412
Electro-prognosis, 411, 412
Elephantiasis nervorum, 298
Embolism, cerebral, 41, 43, 98
Emotion, acute, memory of, 538
Emotional shock, 536
Encephalitis, acute, 59
— lethargic, 137, 438
— suppurative, 477
Encephalomalacia, 169
Endarteritis, progressive local, following nerve injuries, 309
Enophthalmos, 48, 342, 344, 345
Enteric fever, absence of abdominal reflexes in, 314
— — "coma-vigil" of, 64
— — headache of, 170
Enuresis, 331
Eosinophilia of cerebro-spinal fluid, 155
Epicritic cutaneous sensibility, 13
— — — loss of, 200
— — — recovery of, 226
— — — test of, 187
Epigastric reflex, 313
Epilepsy, 66 *et seq.*
— bilateral, excision of cervical sympathetic for, 347
— chronic posture and gait in, 285
— distinguished from hysteria, 66 *et seq.*; and Ménière's disease, 157
— gait in, 285
— Jacksonian, 65, 70-72, 195, 447-449
— lymphocytosis following, 68
— major or "grand mal," 68
— masked or larval, 69
— minor or "petit mal," 68, 250
— post-epileptic automatism, 68
— — coma, 62
— — sleep, 437
— premonitory symptoms, 66
— sudden falling, 250
— in war, 556
Epileptiform fits, 66, 70, 73
— — in alcoholics, 69
— — aphasia following, 98
— — in asphyxia, 69
— — in cerebellar disease, 76, 459
— — cerebral, classification of, 65
— — deep reflexes, abolition of, 324

Epileptiform fits, distinguished from hysterical fits, 66
— — in general paralysis of insane, 70
— — headache following, 170
— — head-injuries, sequelæ of, 492
— — infantile, 72
— — in intra-cranial tumours, 70, 445
— — Jacksonian. *See* Epilepsy
— — myoclonus allied with, 78
— — in psychasthenia, 70
— — sensory, 71
— — in Stokes-Adams syndrome, 62, 73
— — toxic, 72
— — vertigo, an aura of, 155
Epistaxis, 44, 169
Equilibrium, afferent fibres for, 17
— centre for, 21, 153
— nerve of, 150
Erb's juvenile atrophic myopathy, 236, 237, 238, 241, 242
— motor points, 401-407
— tetany, sign in, 75
Ereutophobia, 366
Ergotism, tetany from, 76
Erythromelalgia, 48, 181, 185, 352
Eulenburg's disease (Paramyotonia congenita), 246
Eunuchism, pituitary, 457
Eustachian tube, obstruction causing vertigo, 153
Exhaustion, neurasthenia induced by, 541
Exhaustion-neurosis, 553
Exophthalmic goitre, alopecia in, 303
— — blood-changes in, 348
— — cramp in, 250
— — cutaneous pigmentation in, 350
— — dermographism, 355
— — von Graefe's sign, 348
— — intestinal symptoms, 349
— — Moebius's sign, 133
— — stimulation of sympathetic, symptoms due to, 348
— — tremor in, 81
— — tremulous respiration, 81
Exophthalmos, 48, 222, 347
Eye, muscles of—
— innervation of, 132
— paralysis of, 39, 45, 84, 128-138, 210, 455
Eyebrow in third nerve paralysis and hysterical ptosis, 132
Eyes, "conjugate deviation" of, 7, 86, 135, 276, 449. *See also under* Optic, Pupils, *and* Vision

Facial anæsthesia, lesions causing, 14, 140
— hemi-atrophy, progressive, 142, 304
— hemi-spasm, 91, 92, 147, 460
— motor points, Erb's diagram, 401
— muscles, innervation of, 144-149
— palsy, 145-150
— — articulative difficulty in, 110
— — auditory nerve disease accompanying, 151
— — contracture secondary to, 146
Facial palsy, lesion of sixth nucleus associated with, 137, 147
Facio-scapulo-humeral myopathy, 109, 233, 236, 237
Fæces, incontinence of, 332
Fallopian aqueduct, 140, 144, 147
Family amaurotic idiocy, 123
— gangrene, 353
— history in nervous disease, 46
— periodic paralysis, 249, 323, 353, 408
— progressive hypertrophic neuritis, 222
Faradic electricity, 400 *et seq.*
— reactions, 405
Fatigue, temporary ataxia due to, 260
— tremor of muscular, 81
Fear, acute, 536
Fevers, bladder trouble in, 331
Fibrillary movements, 49, 78
Fillet, 39
— degeneration, 29
— superior decussation of, 16
Fissured fractures of cranium, 468, 470
Fissures, calcarine, 37
— lesions, 113, 425
— parieto-occipital,
— Rolandic, 4, 14
— Sylvian, 3, 4, 20, 39
Fits, 65-76
— alcoholic and absinthe poisoning causing, 69
— asphyxial, 69
— cerebellar, 65, 76, 459
— cerebral, 65
— classification of, 65
— cortical lesions and, 70-72
— epileptiform. *See* Epileptiform
— hysterical. *See* Hysteria
— infantile, 72
— Jacksonian. *See under* Jacksonian
— scheme of investigation, 66
— strychnine causing, 74
— in sub-cortical tumours, 70, 72
Flaccid paralysis, 28, 208, 217-230, 388
Flechsig's auditory gyrus, 39
Focal signs of brain injuries, 479-535
"Folie de pourquoi," 366
Footprints in case of right hemiplegia, 277
Foramen of Key and Retzius, 416
— lacerum, lesion of, 165
— of Magendie, 416
Forced rotatory movements, 459
Fore-arm sign of Leri, 394
Foreign bodies, abscess due to, 477
— — in the brain, 470
Formatio reticularis, lesions of, 14
Formication, 47
Fractures of cranium, varieties of, 468
— depressed, fits due to, 72
Fragilitas ossium, 305
Freud's theory of hysteria, and other psychoneuroses, 367, 538
Friedreich's ataxia, 110, 256
— — articulation in, 110
— — deep reflexes, loss of, 256, 323
— — gait in, 281
— — Marie's ataxia compared with, 258

Friedreich's ataxia, nystagmus in, 131
— — paramyoclonus multiplex, 78, 80
— — sensory changes in, 256
— — spontaneous movements in, 88
— — tabes distinguished from, 256
Fright-neurosis, 555
Fröhlich's syndrome, 456
Frog-like myopathic gait, 283
Frontal lobes, lesions of, 487
Frost-bite contrasted with trench foot, 354
Functional and organic disease, boundary-line between, 50, 358, 398
— — — combined, 51
Fundus, ocular, pathological conditions of, 122, 123

Gait, 275-286
— ataxic, 253, 279
— cerebellar, 247, 259, 281
— in chorea, 285
— of chronic epilepsy, 285
— in cysticercus of fourth ventricle, 155
— in deformities, 286
— frog-like, myopathic, 283
— in hemiplegia, 276
— high-stepping, 282
— hysterical, 278, 390-393
— in lacunar hemiplegia, 277
— of paralysis agitans, 284
— in peripheral neuritis, 282
— reeling or titubating, 281
— "scissor," 276
— side (Flankengang), 278
— spastic, 276
— testing, mode of, 275
Galvanic electricity, 400
— reactions, 405
— vertigo, 154
Ganglion. *See* Ciliary, Gasserian, Geniculate, etc.
Gangrene, family, 353
— symmetrical, of Raynaud's disease, 296, 351
Gasserian ganglion, 125, 126, 140, 143, 340
— inflammation, 294
General paralysis of insane, Argyll-Robertson phenomena in, 124, 126
— — — articulation of, 110
— — — cerebral hæmorrhage in, 56
— — — cerebro-spinal fluid in, 421-426
— — — deep reflexes, loss of, 322
— — — epileptiform fits in, 70
— — — hemiplegia in, 250
— — — pachymeningitis hæmorrhagica in, 58
— — — pupils in, 124, 126
— — — tremors, spontaneous, in, 88, 110
— — — in war, 493
Geniculate ganglion, *facing* 140, 144, 147, 150
— — inflammation of, 144, 150, 294
Genital reflex, 327
Genu recurvatum, 271, 273
Giddiness, 134, 147, 153 *et seq.*, 169, 428, 445. *See also* Vertigo
Gigantism, 289, 455
Girdle-pains of tabes, 174
Glaucoma, symptoms of, 120, 168
— excision of cervical sympathetic for, 346
Gliomata, 463
Globulin in cerebro-spinal fluid, tests for, 418
Globus hystericus, 68, 74, 384, 395
— pallidus, 10
Glosso-labial hemi-spasm, 270, 389
Glossy skin, 48, 292
Gluteal reflex, 313
Glycosuria, 155, 291, 349, 456, 462
Gold reaction, colloidal, 420-422
Goldflam's sign of intermittent claudication, 247
Gordon's paradoxical flexor reflex, 316
Gowers' tract, fibres of, 14
Grasset and Gaussel's test, 206
Graves' disease. *See* Exophthalmic Goitre
Gumma, intra-cranial, 174, 462
— fits from, 71
— headache due to, 169, 171
— neuralgia due to, 174
Gustatory path, 39, 140
Gutter fractures of cranium, 468
Gyrus, angular, arterial supply, 43
— — cortical lesion, 120, 451
— — visual word centre, 38, *facing* 96, 102
— auditory (Flechsig's), 39
— Heschl's, 39, 96
— — tumours of, 451
— lingual, 39
— post-central, lesions of, 482, 483
— pre-central, lesions, 479
— uncinate, lesions of—
— — fits due to, 72, 451
— — olfactory centre, 36
— — disorders of, 116
— — tumours of, 451

Habit-spasm, 89, 92, 386, 398
Hæmatoma, results of, 473
Hæmatomyelia, from wounds, 496
Hæmoglobinuria, paroxysmal, 352
Hæmophilia, cerebral hæmorrhage in, 56
Hæmorrhage, cerebral, aphasia from, 98
— — artery of (diagram), 42
— — at birth, 73
— — blood-pressure in, 56
— — cerebro-spinal fluid in, 417
— — in children, 56
— — coma in, 35
— — contusion by, 473
— — by *conte-coup*, 474, 476
— — extra-dural, 56
— — fits due to, 72
— — in general paralysis of insane, 56
— — headache preceding, 169
— — Ménière's disease distinguished from, 157
— — laceration by, 473
— — spontaneous, 55, 56

Hæmorrhage, cerebral, sub-arachnoid, cerebro-spinal fluid in, 416
— — subdural, chronic, 57
— — traumatic, 473
— — trophic changes in nails, 303
— — vertigo from, 154
— chronic subdural, 57
— pontine, 59
Hair, blanching of, 142, 302
— falling of, 302, 303
— in progressive facial atrophy, 142
— trophic changes, 300-302
Half-vision centres, 38, 39, 452, 453
Hallucinations, auditory, 152
— olfactory, 116
— pain, hysterical hallucinations of, 372
— visual, 72, 453
Hand, deformities of, 265, 266
Haphalgesia, 383
Harman's chart showing movements of ocular muscles and position of false image in paralysis, 128
Head, injuries of, coma in, 53, 56
— — sequelæ after, 492
— wounds of, 468-471
Headaches, 168
— angio-neurotic, 171
— clavus hystericus, 171
— concussion following cerebral, 171
— of congestive glaucoma, 168
— due to tumours of brain, 443, 444
— gastric, 170
— of gross intra-cranial disease, 154, 169
— hysterical, 171, 372
— local causes (extra- and intra-cranial), 168, 169
— in Ménière's disease, 156
— migrainous, 172
— neurasthenic, 170
— post-epileptic, 170
— reflex, 170
— in sunstroke, 170
— toxic, 170
— unilateral, 171
Head-rolling, 83
Hearing. *See under* Auditory
Heart, "soldier's," 542
Heat sensibility, tests for, 187
Heine-Medin disease. *See* Infantile spinal paralysis
Helicoid visual fields in hystero-neurasthenia, 382
Hemeralopia, 118
Hemi-achromatopsia, 120
Hemi-anæsthesia, 191-194
— crossed, 9, 18, 191, 193, 196, 197
— hysterical, segmental type, 193, 379-381
— organic, 191-194
— — cortical and sub-cortical, 195, 449
— — lesions causing (diagram), 15, 17, 196, 454
— — sub-thalamic, 196
— — thalamic, 83, 195, 454
Hemianopia, bisection test in, 119
— bi-temporal, in pituitary tumours, 457
Hemianopia, definition and cause, 120-122
— diagrams, 38, 121
— homonymous, 121
— horizontal, superior and inferior, 38
— inferior, 38
— lesions producing, 8, 38, 120-123, 453, 485
— quadrantic, 38, 122
— varieties of, 119, 120, 121
— Wernicke's pupillary reaction in, 127, 453
Hemiataxia in lesions of optic thalamus, 260
Hemiatrophy, facial, 142, 302
Hemicrania, hysterical, 373, *See also* Migraine
Hemi-hyperæsthesia, hysterical, 373
— thalamic, 192
Hemi-hypertrophy, facial, 290, 291, 303 (fig.), 304
Hemiopic pupillary reaction, 127, 453
Hemi-paraplegia, 48
Hemiplegia, 204
— alternate, 205
— angio-spastic, 248
— aphasia in, 98, 110
— apraxia in, 105, 106
— articulation after, 110
— ataxia associated with, 260
— athetosis following, 85
— — (fig.), 86
— bed-sores in, 295
— bilateral, 111, 204
— bone changes in, 305
— capsular lesion causing, 7, 8
— chronic, 304-307
— combined flexion of hip and trunk, 206 (fig.), 207
— conjugate automatic movements in, 86
— crossed, 205, 461
— definition and forms of, 204
— dolorosa, 167
— double, 204
— gait in, 276-278
— in general paralysis, 250
— Grasset and Gaussel's sign of, 206
— with hæmorrhages under finger-nails, 299
— headache preceding, 169
— in head injuries, 57
— hysterical (functional), 206, 269, 278
— — absence of plantar reflexes, 317
— — anosmia in, 116
— — Leri's forearm sign in, 394
— infantile, 267, 304 (fig.)
— ipso-lateral, 120
— joint affections in, chronic, 309
— lacunar, 59, 277
— left, showing combined flexion of hip and trunk (photo), 207
— lesions causing, diagnosis, 59, 83, 418, 446
— ligature of carotid artery followed by, 493-495
— loss of certain reflexes in, 317
— muscular wasting in, 237

Hemiplegia, pandiculation in, 87
— posture in, 266
— synkinesia in, 87
— thrombosis causing, in war, 494
— transient, 248, 250
— tumours causing, 446 *et seq.*
— visual fields in cases of (diagram), 381
Hemi-spasm, 91
Herd-instinct, development of, 537
Hereditary ataxia, Friedreich's, 88, 256
— Marie's, 258
Heredity, effect on war-neuroses, 543
Hernia cerebri, 478
Herpes, facial, 144, 150, 294
— zoster, 175, 294, 300
— — anæsthesia following, 201
— — and varicella, 175
Heschl's gyrus, 39, 96
— — tumours of, 451
Hiccough in intra-cranial disease, 446
High-velocity bullets, effect of, 471
Hippus, 126
Holmgren's test for colour vision, 118
Hughlings-Jackson's syndrome, 165
Hunger, cortical centre for, 41
Hunger-pains, 337
Huntington's chorea, 85
Hydrarthrosis, intermittent, 355
Hydrocephalic cry, 60
Hydrocephalus, acute, 464
Hydrophobia, 74
— hysterical, 74
Hyoscine chorea, 85
Hyperacousis, 147
Hyperæmia, cerebral, 153, 154, 169, 171
Hyperæsthesia, 191, 192
— hysterical, areas of, 185, 192, 372, 374
— mapping out areas of, 188
Hyperalgesia, 193, 373
Hyperidrosis, localised, 356
Hyperkeratosis, 514
Hyper-metria, cerebellar, 259
Hypermetropia, headache from, 170
Hyper-pyrexia, 56, 59, 170
Hypersomnia, 436
Hyper-thyroidism, 303
Hypertrichosis, 300
Hypertrophic progressive neuritis, 222, 257
Hypertrophy of muscles, 203
Hypnotic suggestion, 64, 438
— trance, 64, 438
Hypo-æsthesia, 191
Hypoglossal nerve. *See* Cranial nerves
— nucleus, 144, 164
Hypothermia, local, in traumatic reflex palsies, 241
— general, in wounds of cervical cord, 478
Hypo-thyroidism, 303
Hypotonia, cerebellar, 24, 274
— of muscles, 272-274
— — tabetic (diagrams of cases), 272-274
Hysteria, 366-399
— age and sex, effect of, 65, 398
— allocheiria in, 188, 191, 383
— alternating personality, 364, 385
Hysteria, ambulatory automatism, 386
— anæsthesia. *See* Anæsthesia
— ankle-clonus, spurious, in, 207, 325, 394
— anosmia, 550
— aphasia and, 104
— articulation in, 113, 372
— ataxia in, 261
— bio-chemical changes underlying, 50
— bladder troubles in, 394
— blindness, 549
— Charcot's "grand hystérie," 67, 384
— in children, 390, 398
— combination with organic disease, 51
— concentric contraction of visual field, 120, 382
— contractures in, 268-271, 547
— cough in, 397
— crossed amblyopia in, 39, 121
— deafness in, 152, 550
— dermographism in, 397, 398
— fits in, 65, 383, 552
— — classification, 65
— — catalepsy, 68, 385
— — distinguished from epileptic fits, 66, 384
— following electric shocks, 387, 388
— Freud's views on, 367
— gait in, 278, 390-393
— glosso-labial hemispasm, 270-389
— hemiplegia distinguished from organic, 206, 269
—hydrophobia simulated by, 74
— hyperæsthetic areas in, 185, 192, 372, 374
— inhibition deficient in, 369
— joint-pains in, 310, 373
— major, 65, 68, 384
— meteorism, 551
— minor, 65, 68
— monoplegia, gait in, 281
— motor phenomena, 383-395
— muscular wasting in, 239
— narcolepsy, 438
— neurotonic reaction in, 408
— organic disease distinguished from, 50, 359, 397
— pains in, 185, 372, 547, 549
— paræsthesia in, 383
— paralysis. *See* Paralysis. hysterical
— paraplegia simulating injury of spinal cord, 497
— physical symptoms, 369-372
— plantar reflex in, diagnosis of, 316
— post-epileptic, 68, 384
— postures in, 268-270
— psycho-analysis in, 367
— ptosis, 132, 133
— reflexes in, 67, 316, 317, 394
— sensory symptoms, 372-383
— shock-amblyopia and, 382
— skin affections in, 397
— spasms in, 92-94
— speech defects in, 371, 372
— spinal curvature in, 270
— — pains in, 373
— suggestion in the production of, 539

Hysteria, suggestion-neurosis, 546
— trance of, 64, 385
— transient paralysis in, 251
— tremors in, 551
— — following shell-explosion, 93
— vaso-motor phenomena in, 395
— visceral phenomena in, 395
— vomiting in, 395, 551
— war-neurosis and, 547
Hysterofrenic and hysterogenic areas, 192 374

Idiocy, amaurotic family, 123
Idioglossia, 115
Idiopathic muscular atrophy, 232
Immobility of limbs, hysterical, 543
Imperious acts, 366
Incontinence of urine, periodic reflex, 330
Inco-ordination (ataxia), 252
— articulative, 110
— cerebellar, 23, 256, 257, 458, 459
— due to fatigue, 260
— hysterical, 261
— from lesions of rubro-spinal tract, 260
— in new-born child, 252
— post-febrile, 260
— pre-and-post hemiplegic, 260
— in progressive hypertrophic neuritis, 257
— sensory origin of, 254
— tests for, 252
— toxic, 260
Infant, new-born, movements of, 3
Infantile convulsions, 72
— spinal paralysis (acute anterior poliomyelitis), 218-220, 304
— — — cerebro-spinal fluid in, 219
— — — lesions causing, 36, 218, 219
— — — loss of deep reflexes in, 323
— — — trophic changes in bones in, 304
Infantilism, 457
Infundibulum, tumour of, 435
Inguinal region, hysterical tender spots in, 374
Inion, 4
Injuries, spinal symptoms of, 17, 18
Insanity, toxic varieties of, 49
Insomnia, 439-442
— alcoholic, 441
— drugs, use of, in, 442
— emotional, 458
— extrinsic, 439
— and insanity, 442
— intrinsic, 440
— primary or nervous, 441
— toxic, 440
— vascular causes, 440
Instincts, primary, 537
Intermittent arterial claudication, 181, 185, 247, 354
— — — Goldflam's sign in, 247
— cerebral claudication, 248
— hydrarthrosis, 356
— spinal claudication, 248
Internal capsule, anatomy, 5, 7 (diagram), 8
Internal capsule, auditory fibres of, 39
— — lesions of, 7, 8, 134, 193, 210
— — motor fibres, 5
— — sensory fibres, 5-7
— — tactile fibres, 14
— — visual fibres, 8, 37
— secretions, temporary excess due to emotions, 537, 555
Interosseal attitude (diagrams), 285, 286
Intervertebral ganglion (ganglion cell of posterior root), 28, 294
Intestinal rumblings, hysterical, 396
Intra-cranial hæmorrhage, 54-58, 473
— pressure, 57, 70, 169, 478
— — lumbar puncture in relief of, 428
Intra-medullary sensory phenomena, 498
Inversion of radial reflex, 322
Involuntary movements, 77-94
— — associated, 85
— — athetotic, 85, 86
— — choreic, 84
— — myokymia, 77
— — reflex spasms, 90
— — rigors, 77
— — shivering, 77
— — in tabes, 88
— — tremors, 80
Ipso-lateral hemiplegia, 210
— pyramidal tract, 10
Irritation, cerebral, 54, 472
Ischæmic myositis, 232, 534
— — from injuries of arteries, 534
— paralysis, 231
Itching sensation, tests for, 187

Jackson's syndrome, 165
Jacksonian fits, 65, 70, 72, 195, 446-449, 479
— — pupillary, 449
Jaw reflex, 318
"Jaw-winking," 138
Jendrassik's reinforcement of knee-jerk, 319, 320
Jews, amaurotic family idiocy amongst, 123
Joint sense, 186, 189, 253
— — tests for, 189
Joints, hysterical pains in, 310, 373
— trophic changes in, 303-309
Jung's word-association method in psychoanalysis, 368

Katatonic rigidity, 546
— stupor, 545
Keratitis, bacillus of, 142
— neuro-paralytic, 142
Kernig's sign of cerebral meningitis, 60, 295, 425
Kidney disease, arterio-sclerosis of, chronic, vertigo in, 154
— — cerebral hæmorrhage in, 56
— — floating kidney, 177
— — uræmic convulsions of, 70, 429
Kinæsthetic sense, 186, 190
— — test for, 190
Kleptomania, 365

Knee-clonus, 325
Knee-jerk, 318-321
— cerebellar, 321
Korsakow's psychosis, 49

Labyrinth, disease of, 150, 151, 152, 156, 157
— vertigo of, 156, 157
Labyrinthitis, 130
Lachrymal secretion, paralysis, 142
Lactation, tetany during, 76
Lacunar hemiplegia, 59, 277
Lalling, 114
Landouzy-Déjèrine type of myopathy, 109, 233, 237, 239
Landry's paralysis, 217, 228, 323, 422
Lange's colloidal gold reaction, 420, 421
Laryngismus stridulus, 72, 75
Larynx, ataxy of, 110
— innervation, 158-161
— myoclonus of, 78
— paralysis, 159-161
Lasègne's sign of sciatic neuritis, 180
— symptom of hysterical anæsthesia, 389
Lateral sinus. *See* Sinus
Laudanum poisoning, 61
Laufenauer's method of reinforcing knee-jerk, 320
Laugh, spastic, 84
Lead poisoning, convulsions in, 69
— — lymphocytosis of cerebro-spinal fluid, 424
— —optic neuritis in, 123
— — palsy in, 201, 228
— — — absence of sensory changes in, 201, 216
— — tremor in, 81
— — visceral symptoms, 349
Leg, sensory fibres from, 16
Lenticular degeneration, progressive, 84
— — hepatic cirrhosis with, 84
— — tremors in, 84
— — zone, lesions of, 104
Lenticulo-striate artery, 42
Leprosy, arthropathies in, 309
— leucoderma in, 297
— maculo-anæsthetic type, 201, 297
— neuritis of, 201, 293
Lepto-meningitis, localised, compared with spinal tumours, 214
Leri's forearm sign, 394
Lethargic encephalitis, 438
Leucocytosis of cerebro-spinal fluid, 423-427
Leucoderma, 297
Leukæmia, 56
— cerebro-spinal fluid in, 424
Levator palpebræ superioris, innervation
— — of, 123
— — (diagram), 340
— — paralysis of, 131, 138, 145, 342
Light reflex. *See under* Reflexes
Limbs, individual nerves of, paralysis of, 353
Limp, intermittent, 535. *See also* Claudication
Lipo-dystrophy, descending, progressive, 300, 301
Lips, paralysis of, 164
Lisping, 114
Localisation, cerebral, 3-8
Lock-jaw. *See* Tetanus
Locomotor ataxia. *See* Tabes
Longitudinal sinus, superior, thrombosis of, 44
Lordosis (with figs.), 236
Luetin reaction, 462
Lumbago, 177, 231
Lumbar puncture. *See* Thecal puncture
Lumbo-abdominal neuralgia, 177
Lumbo-sacral cord, disease symptoms in, 174, 175
— — muscular localisation in, 35
— plexus and its branches, 30, 31
— — wounds of, 532
Lymphocytosis of cerebro-spinal fluid, 70, 175, 250, 295, 423-427
— — — diagnostic significance, 426
Lyssa, 74

Machiphobia, 536
Macrogenitosomia, 455
Macropsia, 383
Main d'accoucheur, 75
— *de prédicateur*, 265
— *de singe*, 265
— *en griffe*, 265
Mal-adaptation neurosis, 554
Malarial coma, 63
Malingering, 359
— Mannkoff's sign in, 373
Mammary neuralgia, 175, 373
Mannkoff's sign of real hyperæsthesia, 373
"*Marche à petits pas*," 59
Marie's hereditary cerebellar ataxia, 258
— views on aphasia, 97, 104
Masked epilepsy, 69
Mass-reflex, 331
Mastodynia, 175
Mayer's thumb reflex, 314
Meckel's ganglion, 140
Median nerve, wounds of, 513
Medulla, auditory fibres, 39
— cranial nerves (diagram), 117
— lesions of, 8, 9, 196, 212, 257, 341, 462
— Ménière's disease implicated in, 156
— pupil-dilating centre in, 341
— respiratory centre in, 3
— sensory tracts of (diagram), 6, 14
— stimulation of nuclei in, 1
Melancholic anergia distinguished from psychasthenia, 364
Memory, distressing, repression of, 538
— loss of, 49, 54
— post-epileptic loss of, 68
Ménière's disease (labyrinthir evertigo), 156
Meningeal adhesions in brain wounds, 472
Meninges, cerebral, convulsions from hæmorrhage into, 73
— pain, sensitiveness to, 167
— spinal, diseases of, 196
— — root pains of, 174, 175, 196

Meningism, 425, 495
Meningitis, basal, 61, 149, 174
— in brain wounds, 477
— cerebro-spinal fluid in, 61, 417-424
— and coma, 60
— diagnosis from brain abscess, 422
— fits due to, 60
— fluid pressure in, 416
— headache in, 171
— lepto-, circumscribed spinal, 214
— lumbar puncture for, 427, 428
— meningo-coccal, 350, 422, 425, 495
— reflexes in, 314, 323
— septic cerebro-spinal, 296, 419, 422
— serous, 464
— spinal, root pains in, 182
— syphilitic basal, 149, 174
— tuberculous, 419, 422, 424
Meningo-myelitis, infective, 497
Menstrual periods, headaches during, 170
Meralgia paræsthetica, 181
Mercury poisoning, tremor of, 81
Metameric and root distribution of sensory and motor fibres, 30
Meteorism, 349, 355
— hysterical, 551
Micropsia, 383
Micturition, 330
— centres for, 329, 330
— in hysteria, 394, 397
Middle ear, disease of, 148, 150, 156
— — innervation, 139
Migraine, 172
— ophthalmoplégique, 138, 172
Millard-Gubler syndrome, 9, 212
Miner's nystagmus, 131
Mixed electrical reactions, 411
Moebius's sign in exophthalmic goitre, 133
Moles, hairy, 301
Molluscum fibrosum, 299
Monakow's bundle (rubro-spinal), 11
— — lesions of, 260, 323, 455
"Monkey hand," 265
Monocular diplopia, 383
Monophobia, 366
Monoplegia, 5, 204, 479
— hysterical, 387, 388
— — gait in, 281
Morphœa, 297
Morvan's disease, 198, 293
Motor areas, localisation of, 5
— agraphia, 97
— aphasia, 96, 97, 102, 103, 449
— centres in cerebellar cortex, 22
— cortex, lesions of, 5, 448, 479-482
— nerves, fibrillary tremors in paralysis of, 78
— — regeneration of fibres, 227
— neurones, upper and lower, 27, 208
— paralyses, 202-251
— — functional or organic, 205
— — lower neurone type, 28, 217-243
— — — — — distinction between anterior corneal and nerve root lesions, 217, 218
Motor paralyses, lower neurone type, distinguished from upper neurone type, 208
— — — — — Landry's paralysis, 217, 228, 323
— — — — — level of lesion, diagnosis of, 217
— — — — — from multiple peripheral lesions, 223, 227
— — — — — muscles, lesions within, 231
— — — — — plantar reflex in, 208
— — — — — postures in, 262
— — — — — sensory phenomena, 208
— — recurrent and transient, 244-251
— — — Eulenburg's disease, 246
— — — family periodic paralysis, 249
— — — in general paralysis of insane, 250
— — — in hysteria, 251
— — — intermittent arterial claudication, 247
— — — spinal claudication, 248
— — — in minor epilepsy, 250
— — — myasthenia gravis, 244
— — — myotonia atrophica, 246
— — — congenita, 245
— — — myotonic dystrophy, 246
— — — occupation neuroses, 248
— — — sign of disseminated sclerosis, 251
— — — in tabes, 250
— — — in tetany, 250
— — — Thomsen's disease, 245
— — upper neurone type, 28, 202-216
— — — — — bilateral, 212
— — — — — distinguished from lower neurone type, 208
— — — — — exaggeration of deep reflexes in, 324
— — — — — flexed and extended types of, 266, 267
— — — — — level of lesion, diagnosis of, 210
— — — — — postures in, 265
— — — — — unilateral, 210-212
— phenomena of spinal cord lesion, 499
— points, 405
— — (diagrams), 401-407
— signs, pyramidal, of spinal injury, 500
— tracts, subcortico-spinal, 10
Mucuna pruriens, 187
Müller, non-striated muscle of, paralysis, 340
Mumps, lymphocytosis of cerebro-spinal fluid in, 424
Muscles, atrophy of, 203
— — causation, 28, 217, 219, 287
— — fibrillary tremors in, 219
— — in hemiplegic arthritis, 310
— — in hysteria, 387
— — in neuritis, 222
— — peroneal type (Tooth's), 221
— — progressive (chronic anterior poliomyelitis), 78, 219, 323, 411
— — — hypertrophic neuritis, 222

Muscles, dystrophy of. *See* Myopathy
— electrical reactions, 402-408
— fatigue-paralysis in myasthenia gravis, 109
— hypertrophy of, 203
— hypotonia, 24, 254, 272-274
— motor points, Erb's diagrams, 401-407
— non-striated involuntary reflexes of, 312, 327
— pseudo-hypertrophy of, 203
— sensation, active, 189, 190
— sensibility to pressure, 190
— sensory fibres from, 15
— testing, in motor paralysis, 203
Muscle-spindles, 28
Muscular analgesia in tabes, 190
— cramp, 250
— dystrophy, 232
— hyper-excitability in reflex paralysis, 91
— localisation in cervical enlargement, 35
— — in lumbo-sacral cord, 35
"Muscular sense" definition, 190
Musculo-spiral nerve, paralysis of, 51, 264, 266, 515
Mutism, hysterical, 113, 371, 543, 549
Myalgia, 175
Myasthenia gravis, 109, 118, 131, 244, 408
Myasthenic reaction, 245, 408
Mydriasis, 124, 125
Myelitis, 51, 216, 263, 295
Myelo-malacia, due to wounds, 496, 502
Myoclonus, 78
— epilepticus (Unverricht's), 78
— nystagmus, 79
Myoidema, 204
Myokymia, 77
Myopathy, atrophic type, 217, 232-236
— atrophy of nuclear origin distinguished from, 232
— Erb's juvenile type, 236, 237, 238, 241, 242
— facio-scapulo-humeral type, 109, 149, 237, 239
— gait and posture in, 282, 283
— pseudo-hypertrophic type, 233-235
Myosis, 124, 339
Myositis, 134, 190, 232
— acute, 231
— ischæmic, 231, 534
Myotomes, 30
Myotonia atrophica, 246
Myotonic dystrophy, 246
— congenita (Thomsen's disease), 245, 274
— reaction, 246, 408
Mythomania, 49
Myxœdema and drowsiness, 437

Nævi, cutaneous, 298
Nails, trophic changes in, 303
Narcolepsy, 64, 435, 438
Narcosis, traumatic, 54
Nasal crises, 117
— hemianopia, 121
Nausea. *See under* Vomiting
Neck, motor points (Erb's diagram), 401
Necrosis of brain-tissue, 476
Neo-striate system, 10
Nephritis, optic neuritis in, 123
— uræmic, fits in, 62, 70, 429
Nerve-deafness, 151
Nerve plexus. *See* Plexuses
— roots. *See* Spinal Nerves
Nerves. *See under* Cranial, Motor, Peripheral, Spinal; *also names of particular nerves*
— of limbs, individual, paralysis of, 533
— olfactory, connections of, 37
Nervous system, anatomy and physiology of, 1-45
— — organic, war-lesions of, 466-535
— — scheme for routine examination of, 47-49
Nervus terminalis, 116
Neuralgia, blanching of hair in, 302
— brachial, 178
— coccygodynia, 178
— hyperæsthesia in, 193
— mammary, 175, 373
— meralgia paræsthetica, 181
— phrenic, 176
— post-herpetic, 294
— sciatic, 178, 317
— tender points, 173, 178
— trigeminal, 193
Neurasthenia, causes and diagnosis, 362-364
— deep reflexes exaggerated in, 364
— distinguished from hysteria, 364
— headaches associated with, 170
— induced by exhaustion, 541
— mydriasis in, 124
— toxic, 362
— traumatic, 362
— tremors in, 81, 363
— war-neurosis, 553
Neuritis, alcoholic, 50, 193
— — (figure of case), 228
— arsenical, 299, 303
— diabetic, perforating ulcers in, 293
— glossy skin in, 293
— lead, 228
— leprous, anæsthesia of, 201
— — perforating ulcers in, 293
— — loss of deep reflexes in, 323
— multiple or peripheral, 50, 200, 201, 227, 303, 320, 326, 519
— — anæsthesia of, 201
— — gait in, 282
— optic. *See under* Optic
— post-diphtheritic, 108, 127, 163
— progressive hypertrophic, 222, 257
— retro-bulbar, 123
— sciatic, 178
— — following wounds, 518
Neuro-fibromata, 183, 298
Neuroma, plexiform, 298
Neuro-mimesis, 389
Neurones, cerebello-dentate, 29
— cortico-bulbar, 108, 110
— dentato-thalamic, 29

Neurones, lower motor (spino-muscular), 27
— — — — lesions of, 28, 208. *See also* Motor Paralysis, Lower Neurone type
— sensory lesions of, 28
— spino-cerebellar, 29
— thalamo-cortical, 29
— upper motor (cortico-spinal), 27
— — — — lesions of, 28, 210. *See also* Motor Paralysis, Upper Neurone type
Neuroses, 358-399
— hysteria, 366-399
— neurasthenia, 362-364
— occupation, 248
— psychasthenia, 364-366
— war, 536-557
"Neurotonic" reaction, 408
Nicotine poisoning, tremors in, 81. *See also* Tobacco
Night-blindness, 118
Nightmares, 439, 554
Noguchi's test for globulin, 418
Nuclear ophthalmoplegia, 136
Nuclei, ambiguus, 158
— auditory, 39, 151
— bulbar, 109
— caudate, 5, 42
— cerebellar, 19, 20, 21
— cuneate, 14, 15
— Deiters', 19, 20, 21
— — lesions of, 157
— dentate, 19, 20
— emboliformes, 19, 20
— fastigii, 20
— globosi, 19, 20
— glosso-pharyngeal, 150
— gracile, 14, 15
— hypoglossal, 144, 164
— lenticular, 5
— lesions of, 83, 111
— medullary, 13, 108
— ocular, 19, 23, 83, 124
— red (diagram), 19
— — lesions of, 83, 137, 212, 260, 455
— roof, 19
— sixth cranial nerve, 8, 137
— vestibular, 40
Nyctalopia, 118
Nystagmus, 129-131
— cerebellar, 23, 131
— in disseminated sclerosis, 131
— facial, 88
— fistular, 130
— in Friedreich's ataxia, 131, 256
— labyrinthine or vestibular, 130, 131
— miner's, 131
— myoclonus, 79, 131
— optic, 135
— pendular, 129
— reflex (optic vestibular), 135
— rhythmic, 129
— thermic, 130
— vestibular, 130, 136

Obsessions of psychasthenia, 365, 554
Occipital region, lesions of, 485
Occipital region, tumours of, 452
Occupation neuroses, 90, 248, 260
Ocular headaches, 168
— paralysis. *See* Paralysis, ocular
— symptoms in Raynaud's disease, 352
— vertigo, 155
Oculo-cardiac reflex, 328
Oculo-motor (third) nerve. *See under* Cranial nerves
Oculo-pupillary fibres of cervical sympathetic, 340
— — (diagram), 340,
— — paralysis of, 341, 343, 344
Œdema, acute angio-neurotic, 354
— blue, hysterical, 397
— cerebral, traumatic, 477
— spinal, traumatic, 506, 507
Œsophagus, hysterical spasm of, 395
Olfactory nerves, 116
— — connections of, 37
— path, 36
Olivary body, 14, 20
Olivo-ponto-cerebellar atrophy, 258
Ophthalmoplegia, nuclear (internal, external, total), 136
Opisthotonus, 67, 459, 510
Opium poisoning, coma from, 61
Oppenheim's reflex, 316
Optic atrophy, 120, 123, 124, 126, 127, 457
— chiasma, course of visual fibres in, 37
— — diagrams of, 38, 122
— — lesions at or behind, 121-123, 127, 457
— — visual fibres in (diagram), 122
— nerve, 37, 117
— neuritis, 122
— — in brain wounds, 479
— — in diagnosis of coma, 58, 61
— — headaches with, diagnosis, 168
— — of intra-cranial tumour, 444
— — lumbar puncture to relieve, 428
— radiation, 37
— thalamus, centres for pleasure and pain in, 16
— — — for visceral sensations, 16
— — lesions of, 83, 167, 195, 210, 453
— — — hemiataxia in, 260
— — micturition centres in, 330
— — reflex centre of emotion, 453
— — sensory fibres of, 16, 454
— — — — redistribution of, 16
— — visual fibres in, 37
Orbicularis oculi (palpebrarum), homologous with branchial arch of fish, 139
— — innervation, 138
Orbital muscle of Müller, 340
— — — (diagram), 340
Organic and functional disease, boundary-line between, 50
Orthostatic albuminuria, 349
Osseous sense, 190
Otic ganglion, 144
— — (diagram), 140
Otitis media, 151

Otitis media, vertigo from, 156
Ovarian disease, headache from, 169
"Ovarian tenderness," 374

Pachymeningitis interna hæmorrhagica, 53
— — — spinal, 216
Pain, 166
— course of, fibres subserving, 14
— headache, 168
— herpetic, 175
— hysterical, 185, 372
— in limbs, 178
— — bilateral, 181
— loss of sense of, 18, 200, 201
— paroxysmal, spontaneous, 182, 185
— persistent, not caused by organic lesion, 547
— reflected, 175
— root, 174, 182
— tests for sense of, 187
— following trauma, 542
— in trigeminal area, 173
— in trunk, 174
Palatal reflex, 331
Palate, soft, hemi-atrophy, 142
— — innervation, 140, 158
— — paralysis of, bilateral, 108
— — unilateral, 158, 165
— — — reflex movement, 313
Pallæsthesia, 190
Pallidal motor path, 11
— system, 10
Palsies. *See* Paralysis.
Pandiculation, 87
Para-anæsthesia, 191, 197
Paracousis Willisii, 151
Paræsthesia, 191, 193
— hysterical, 383
Paradoxical flexor reflex, 316
— pupillary reaction, 127
Paragraphia, 101
Paralysis, acute ascending, 228
— alcoholic, 149, 201, 223
— alternate. *See* Crossed
— of anterior crural nerve, 224
— Bell's, 145
— Brown-Séquard, 9, 191, 197, 213
— bulbar. *See that title*
— of cervical sympathetic, 341-346
— cranial nerves, 116-165
— crossed, 8, 51, 204, 211, 461
— facial, 108, 144-149, 212
— — bilateral, 149, 150
— family periodic, 249, 232, 353, 408
— fifth nerve, 139-143
— of fourth nerve, 133
— glosso-labio-laryngeal, *See* Bulbar palsy
— glosso-pharyngeal, 157, 158
— hypoglossal, 120, 163-165
— hysterical, 251, 268-271, 386-393, 552
— — figures, 269, 270, 278, 281, 370, 371, 377-380, 387-390
— — muscular wasting in, 239
— of individual nerves, 533
Paralysis, infantile, 218, 286, 304
— ischæmic, 231, 232
— Landry's, 217, 228, 323
— laryngeal, organic and functional (diagram), 159, 160
— lead, 201
— of musculo-spiral nerve, 51
— motor. *See* Motor paralysis
— — and sensory combined, 213, 223
— multiple, 165
— musculo-spiral, 264
— myasthenia gravis. *See that title*
— ocular, 128
— — infra-nuclear, 137
— — from lesions of individual nerves, 131, 133-140
— — nuclear lesions, 137
— — rheumatic, 134
— — supra-nuclear, 134
— oculo-motor, 131, 132
— palatal, 95, 108, 158, 159
— peripheral motor nerve lesions, electro-prognosis of, 411
— post-diphtheritic, 95, 108, 149
— pseudo-bulbar, 111
— of recurrent laryngeal nerve, 160
— reflex, 239, 392, 552
— of sixth nerve, 134
— spastic, "flexed," and "extended," types, 266
— tumours in cerebral, 448
— ulnar, 223, 224
Paralysis agitans, acute, in lethargic encephalitis, 137
— — articulative difficulties in, 111
— — diagrams of cases, 82, 235, 286
— — juvenile type of, 82
— — Parkinsonian mask, 112, 285
— — pathology of, 10
— — posture and gait in, 284
— — rigidity of, 82
— — tremors of, 81, 82
— — in war, 493
Paramyoclonus multiplex (Friedreich's), 78, 80
Paramyotonia congenita (Eulengberg's disease), 246
Paraphasia, 100
Paraplegia, 204
— bed-sores in, 235
— brachial and crural, 204
— chronic, trophic changes in nails, 303
— decompression, 181
— dolorosa, 182
— gait in, 281
— hysterical, 269, 278, 370, 371
— simulating wounds of spinal cord, 497
— spastic, 51, 210, 213, 255, 276
— — flexed and extended types of, 266-267
Para-sympathetic fibres, 334
Parathyroids, tetany from extirpation of, 75
Paresis, 204
Parietal region, lesions of, 489
Parkinsonian mask, 112, 285

Parosmia, 116
— paroxysmal, 117
Penetrating wounds of head, 469
Penis, analgesia of, in tabes, 200
"Pension-neurosis," 540
Perforating ulcers, 292
— wounds of head, 470
Pericarditis, reflected pain in, 175
Perineuritis, 179
Periodic paralysis, family, 249, 323, 353, 408
Periostitis of skull, 168
Peripheral nerves, compression of, 200
— — cutaneous areas of, 32
— — lesions of, anæsthesia, 200
— — — ataxia, 254
— — — mixed, 223-226
— — — motor paralysis, 205, 223, 411
— — paths of sensation, 13
— — wounds of, 533
— — — compression, 517
— — — concussion, 517
— — — contusion, 514
— — — division, complete, 511
— — — — incomplete, 512
— — — frequency in different nerves, 511
— — — inflammation, 518
— — — rupture, 517
— neuritis. *See* Neuritis, multiple
Peritonitis, 190, 349
Permanganate test for meningitis, 420
Peroneal muscular atrophy, 221
Personality, alternating, 364, 394
Persuasion, 366
"Petit-mal," 68, 250
Petrous ganglion (diagram), *facing* 140
Pharyngeal reflex, 313
Pharynx, innervation of, 157
— paralysis, 158
Phlebogenic sciatica, 180
Phobiæ, 366, 554
Phrenic neuralgia, 176
Pia mater, function of, 467
Pill-rolling tremor, 285
Pineal body, anatomy and physiology, 25
— — pathology of, 25, 26
— — precocious puberty, with tumours of, 26, 455
— — tumours of, 455
Pithiatism, 366
Pituitary body, acromegaly with, 25
— — anatomy and physiology, 24
— — enlargement in pregnancy, 25
— — Fröhlich's syndrome with, 456
— — lesions of, 25, 455-457
— — secretion of, 25
— — sugar metabolism in, 25
— — tumours of, 121, 289, 291, 435, 455-457
— — — with hemianopia, 121
"Planchette," sub-conscious phenomena of, 385
Plantar reflex, 2, 28, 208, 215, 314-316
— — Babinski's phenomenon, 315
— — in hysteria, 317, 394
Pleasure and pain, centres for, 16, 192
Pleurodynia, 175
Plexiform neuroma, 298
Plexus, brachial, wounds of, 344, 345, 522
— — symptoms in division of posterior roots, 254
— cervical, 29
— lumbo-sacral, 31
— — wounds of, 532
— pre-vertebral, 336
— solar, disorders associated with, 327, 328
Pneumonia, loss of deep reflexes in, 323
Pointing tests, Bárány's, 22, 255
Poisoning, neuroses caused by, 542
Polar reactions of muscles, 406, 407
Polio-encephalitis, superior, 73
— inferior, 73, 137, 438
Poliomyelitis, acute. *See* Infantile paralysis
— chronic anterior, 78, 219, 323
Polyæsthesia, 191
Polyopia, monocular, 383
Polyuria, hysterical, 397
Pons, arterial supply, 42
— cranial nerves (diagram), 117
— facial nerve, origin in, 144
— hæmorrhage, 59, 124
— lesions of, 8, 51, 83, 147, 196, 198, 212
— — in tegmental region, 83
— nuclei, 109, 134
— sensory fibres in, course of, 15
— tumours of, 455
— — (fig.), 461
Ponto-cerebellar angle, lesions of, 198
— — tumours in, 400
Ponto-spinal tracts, 11
Popliteal nerve, external, paralysis of, 264, 282, 576
— — paralysis of, gait in, 282
Portio intermedia, 150
"Port-wine stains," 298
Post-central gyrus, lesions of, 482
— region, wounds of, 483
Post-diphtheritic paralysis, 95, 108, 149
Post-epileptic automatism, 68
— coma, 62
— lymphocytosis, 68
Posterior columns, lesions of, 13-17, 196, 254, 279, 323, 327
— fossa, tumours of, 169, 323
— nerve roots. *See* Spinal nerve roots
— roots, symptoms of injury, 498
Postures, 262-275
— cerebellar, 273
— erect and at rest, 262
— in functional disease, 268-271
— in organic disease, 262, 263, 265-267
Pot-belly, 234, 283
Preacher's hand, 265
Pre-central region, wounds of, 479-482
Pre- and post-central region, wounds of, 483-485
Pregnancy, pseudo-, 396
— tetany in, 76

Pre-hemiplegic ataxia, 260
Pre-pyramidal tract, 11
Pressure, blood, in coma, 54
— intra-cranial, 70, 169, 418, 427, 428
— — lumbar puncture in relief of, 427, 428
— intra-thecal, 416, 417
— labyrinthine, 157
"Pressure-pain," 12
Pressure-sense, 187, 190
Prisoners of war, neuroses amongst, 544
Probe, risk of use of, 469
Progressive hypertrophic neuritis, 222, 257
— muscular atrophy, 78, 219, 220, 411
— neuritic amyotrophy (Charcot and Marie), 221-222
Projectiles, nature of wound produced by, 470, 472
"Pronation phenomenon" in hemiplegia, 208
Pronator-jerk, 322
Proprio-ceptive sense-organs, 189
Proptosis, 45, 347
Protopathic cutaneous sensibility, 12
— — — loss of, 200
— — — recovery of, 226
Pseudo-angina, 176, 395
Pseudo-appendicitis, 396
Pseudo-athetosis in tabes, 88
Pseudo-bulbar paralysis, 111, 213
Pseudo-hæmatemesis, 397
Pseudo-hæmoptysis, 397
Pseudo-hypertrophy, 233-235
— muscular, 203
"Pseudo-memories," 49
Pseudo-myopia, hysterical, 383
Pseudo-pregnancy, 396
Pseudo-ptosis, 342, 343, 344
— hysterical, 133, 390
Pseudo-sciatica, hysterical, 180
Pseudo-sclerosis, 84, 261
Pseudo-tumor cerebri, 464
Psychalgia, 372
Psychasthenia, 70, 364-366, 554
— imperious acts in, 366
— obsessions in, 365
— phobiæ of, 366
— stigmata of, 364
Psychic epilepsy, 69
Psycho-analysis, 538
— — in hysteria, 367
— — Jung's word-association method, 368
Psycho-galvanic reaction in neurasthenia, 363
Psychosis, "barbed-wire," 544
Pterygoid muscle, external, action in congenital ptosis, 139
— — paralysis of, 141
Ptosis, 131, 390
— bilateral, 454
— congenital, 138
— hysterical, 132, 133, 390
— pseudo-. *See* Pseudo-ptosis *above*
Puerperal eclampsia, 70, 429
Punctured fractures of cranium, 468, 470
Pupillary reflex. *See under* Reflex, light
Pupillary unrest, 126
Pupils, 124
— Argyll-Robertson phenomenon in, 124, 126
— contraction, in affecting cervical sympathetic, 339-341
— — in opium poisoning, 61
— — in pontine hæmorrhage, 59
— dilatation of, 55, 125, 132
— dilating fibres, 126, 340
— — — course of (diagram), 126
— examination of, 124
— inequality of, 55, 125, 348
— irregularity in shape, 125
— Jacksonian fits of, 449
— light reflex. *See* Reflexes
— motor innervation of, 124
— painful stimulation of neck, reaction to, 127
— paradoxical reaction, 127
— psychical dilatation, 127
— reaction to accommodation, 127
— size of, variations in, 125
Purulent meningitis, 422
Pyramidal cells, 4, 5
— motor signs of spinal cord-lesions, 560
— tract, course of, 5, 11, 27
— — (diagram), 6
— — lesions of, 9
— — — gait in, 276-278
— — — motor paralysis due to, 210, 212
— — — reflexes affected by, 326

Quadrantic hemianopia, 38, 122, 487
Quinine blindness, 120
Quinquaud's sign of chronic alcoholism, 81

Rabies, 74
Raccourcisseurs, phénomène des, 215
Radial jerk, 318, 322
Radiculitis, 174
Railway spine, 362
Rami communicantes, 334, 341
Raynaud's disease, 185, 296, 351
Reactions, condenser, 409
— of degeneration, 23, 203, 208, 409
— electrical, abnormalities of, 408
— faradic, 405
— galvanic, 405
von Recklinghausen's disease, 299
Rectal reflex, 327
Recti muscles of eye, 123, 128-130
Recurrent and transient motor paralyses, 244-251
— laryngeal palsy, 160
— utterances, 102
Red nucleus, connections, 11, 20
— — lesions of, 83, 138, 212, 260, 455
Reeling or titubating gait, 253, 281
"Referred pains," 337
Reflected pains of visceral diseases, 175
Reflex arc, 2
— convulsions, 72
— cutaneo-gastric, 328
— paralyses, 552
— — following traumata, 239, 240, 392

Reflex spasms, 90, 91
— spinal, 2
Reflexes, 312-333
— abdominal, 314
— adductor of foot, 316
— anal, internal, 329, 332
— — superficial, 313, 317
— Babinski's extensor plantar reflex, 315
— Bechterew and Mendel's, 326
— bladder, 329-330
— Brissaud's, 315
— bulbo-cavernosus, 313, 317
— carpo-metacarpal, 318
— cilio-spinal, 48, 327, 343
— conditional, 3, 333
— corneal, 66, 146, 313
— cortical and spinal, 315
— cremasteric, 313, 317
— cutaneo-gastric, 328
— dartos, 327, 332
— deep or tendon, 318-327
— — — in ataxic conditions, 253
— — — after epileptiform fits, 67, 71
— — — exaggerated, 17, 324-327
— — — loss of, 322
— — — in upper and lower neurone paralyses, 28, 205
— defensive, 215
— effect of spinal injuries on, 17, 214, 501-507
— epigastric, 313
— extensor, plantar, 315
— flexor, plantar, 314
— genital, 327
— gluteal, 313
— in hysteria, 68, 394-395
— jaw, 318
— knee, 318
— light, 2, 125, 327
— — in hysteria, 67, 394
— — loss of, 126
— — path of, 126
— — — (diagram), 126
— "mark-time," 215
— "mass," 324, 330
— of non-striated muscles, 327
— oculo-cardiac, 328
— in opium poisoning, 61
— Oppenheim's, 316
— organic motor, 327
— palatal, 313
— paradoxical flexor, 316
— pharyngeal, 313
— plantar, 2, 28, 56, 61, 207, 215, 314-316
— pronator, 318, 322
— pupillary light, 125-127, 327
— — — mode of testing, 125
— radial, 318, 322
— — inversion of, 322
— rectal, 327
— scapular, 313
— scapulo-humeral, 318
— scrotal, 329, 332
— sexual, 3, 327, 329
— of spinal automatism, 215
— in spinal cord lesions, 501
Reflexes, superficial or skin, 312-318
— thumb, 314
— triceps, 322
— uterine, 327
— vomiting, 3
Renal disease. *See under* Kidney *and* Nephritis
Repression of distressing memories, 538
Restiform body, 20, 39
Retention of urine, 330
Retina, 37, 38, 122, 123
— œdema, diagnostic significance, 57
Retinitis pigmentosa, 118
Retro-bulbar neuritis, 123
Retrograde amnesia, 54
Retro-quadrigeminal hemianopia, light reflex in, 127
Rheumatic myositis of external ocular muscles, 134
Rhythmic movements, stereotyped, 546
Rickets, convulsions and tetany due to, 72, 75
Right-handedness, 39
Rigidity, decerebrate, 86
Rigors, 77
Rinne's test for hearing, 151
Risus sardonicus, 510
Rodent ulcers, 296
Rolando, fissure of, 3
Romberg's sign in tabes, 253
Roof nuclei, 19
Root areas (diagrams), 32, 34
— — posterior, 33, 34
— lesions, 30, 111, 218, 229
Root-pains, 174, 175, 182
Rosenbach's sign of hemiplegia, 56
Rossolimo's toe phenomenon, 326
Rotatory movements, cerebellar lesions and, 23
— — in intra-cerebellar growths, 459
Round-worms, convulsions due to, 72
Rubro-spinal tract, 11, 83, 137, 260
— — loss of function, 323, 455
Rupophobia, 366

Sacral pain, 178
— plexus, 31
— segments, lesions, 317
Sacro-coccygeal root-areas (diagram), 34
Salicyl-sulphonic acid test for protein in cerebro-spinal fluid, 418
Saliva, irregularity of flow of, 146
Saltatory spasms, 94
Scalp wounds, 468
Scapular reflex, 313
Scapulo-humeral reflex, 318
Schizophrenia, 546
Sciatic nerve, paralysis of, 226
— — lesions, 534
— neuralgia, 178
— neuritis, 178
Sciatica, 178
— pseudo-hysterical, 178, 180
— radicular, 180
— varicose or phlebogenic, 180
Scissor gait, 276

Scleroderma, 296
Sclerosis, amyotrophic lateral, 78, 216, 220, 323
— disseminated. *See* disseminated sclerosis
— multiplex dolorosa, 175
— postero-lateral, 281
— primary lateral, 216
— pseudo-, 261
— tuberose, 463
Sclerotomes, 30
Scotoma, central, 119, 123
— of migraine, 119, 172
Scotomata, central, bilateral, 485
— — for red and green in tobacco amblyopia, 119
Scrotal reflex, 329, 332
Sea-sickness, 339
"Seelenhähmung," Nothnagel's, 389
Segmental signs in spinal cord lesions, 499, 500
Segmentation of spinal cord (diagrams), 33-36
Self-preservation, instinct of, 537
Semicircular canals, disease of, 156
Senile tremor, 82
Sensation, clinical investigation of, 186, 187
— cutaneous, 186
— delayed, 188
— joint, 186
— muscle, active, 186
— paths of, 13-17
— return after mixed nerve paralysis, 226
— vibration, 186
Senses, special, paths of, 36
Sensibility, kinds of, 12, 13
Sensory cortex, 16
— fibres, position of, 5-7
— fits, 71
— paths, 12
— phenomena, intra-medullary, 498
Sequelæ of head injuries, 492
Serratus magnus, paralysis of, 227
Sex-instinct, 537
Sexual hypothesis of Freud, 538
— reflex, 3, 327, 329
Shell-shock, hysteria due to, 540
Shivering, 77
Shock amblyopia, 382
— emotional, 536
Shoemaker's tetany, 76
Side gait (Flankengang), 278
Sight. *See* Vision
Singing, cortical centre for, 103
Sinus, cavernous, thrombosis of, 45
— inferior longitudinal, 44
— lateral, thrombosis of, 44, 464
— superior, longitudinal, thrombosis of, 44
— — injuries of, 473
Sinuses, cerebral, thrombosis of, in coma, 59
Skew deviation of eyes, 136, 459
Skin, areas of peripheral nerves, 32
— glossy, 292
Skin, hysterical affections, 397
— pigmentary changes, 297-300, 350
— sensibility of, 12-14, 187-189
— — loss of, 200
— — recovery of, 226
— trophic changes, 291-303
Sleep, disorders of, 433-442, 554
— pathological, 436-438
— physiology of, 433-436
Sleeping sickness, 438
— — parasites in cerebro-spinal fluid, 423
Sleeplessness. *See* Insomnia
Smell, disorders of, 72, 116, 117, 142, 488
— — hysterical, 374, 381
— olfactory path, 36
— tests for sense of, 116
Smile, spastic, 84
Sneezing in parosmia, 117
Snellen's types, 117
Softening, cerebral, traumatic, 476
— spinal, traumatic, 496
Somnambulism, 385, 436, 439
Spasm, habit, 89
— hysterical, 94, 387, 391
— reflex, 90
— saltatory, 94
— *See also* Tics
Spasmophilia, 72, 75
Spasmus nutans, 83
Spastic paralysis, 266-268
— — extended type, 266, 327
— — flexed type, 266, 327
— smile or laugh, 84
Spasticity, 28, 208, 215, 216
Special senses, paths of, 36
Speech, articulation distinguished from, 107
— auditory, origin of, 97
— cortical centres for, 96-99
— hysterical affections, 371
— loss of, aphasia. *See that title*
— — articulation, defects. *See* Articulation
— — causes, classification of, 95
Sphincter ani externus, 35, 313, 317
— — internus, 327, 332
Spina bifida occulta, 293, 300
Spinal accessory nerve, 162
— anæsthesia, 429-432
— — after-effects of, 432
— — contra-indications to, 432
— automatism, reflexes of, 215
— cord, arterial supply, 43
— — cervical region, lesions in, 123, 174, 204, 212, 498, 502, 504, 506
— — — — muscular localisation in, 35
— — Clarke's column, 17
— — combined degeneration of, 254, 327
— — compression, 197, 123, 216
— — concussion of, 496
— — course and distribution of terminal arteries (diagram), 44
— — diagnosis of level of lesion, 498
— — endogenous tracts, 17
— — lateral columns, 10, 14
— — lesions of, anæsthesia in, 196, 197

Spinal cord, lesions of, bladder trouble due to, 330
— — — complete and incomplete, 196-197, 213, 501-507
— — — hemi-section of, 9, 17, 191, 197, 212, 504
— — — motor paralysis and, 212
— — — posterior roots and columns of, 13-17, 254
— — — in pyramidal tract. *See* Pyramidal tract
— — — rectal incontinence, 331
— — — root-pains due to, 182, 498
— — — symptoms of, 498, 499
— — — trans-section of, complete, 196, 212, 326, 501-503
— — — unilateral. *See* Hemi-section of
— — — lumbo-sacral region. *See* Lumbo-sacral cord
— — — malignant growths in, 213, 216, 423
— — paths of sensation, 13
— — poterior columns, 13-17, 191, 254, 279, 323, 327
— — — relations to vertebral column (diagram), 414
— — — root irritation from diseases of, 182, 213
— — — segments (diagrams), 31-33
— — — sensory paths of (diagram), 14
— — — subacute combined degeneration, 254, 327
— — — tracts of, 9-16
— — — tumours of, intra- and extra-medullary, diagnosis between, 213, 216
— — — cerebro-spinal fluid in, 419
— — — vaso-motor centre, disease of, 352
— — — wounds of, 495-511
— — — — complete and incomplete, 501, 503
— — — — diagnosis of level, 498, 501, 507
— — — — pathological results of compression, 496
— — — — — hæmorrhage, 496
— — — — — meningo-myelitis, 497
— — — — — necrosis, 496, 502
— — — — — œdema, 506
— — — — signs and symptoms of motor pyramidal, 500
— — — — — segmental, 499
— — — — — sensory, intramedullary, 498
— — — — — root signs, 498
— curvature, hysterical, 270
— nerves, anterior roots, 2, 27
— — — lesions of, 30-35, 217, 218
— — — mixed motor and sensory paralysis due to, 223
— — — motor paralysis due to, 30-35
— — — posterior roots, cutaneous areas, 32-36
— — — — distribution, 30-36
— — — — inflammation of ganglia, 204
— — — — irritation, 174, 182, 192, 197, 254
— — — — lesions of, 254, 323
— — — — sensory paths through, 13
Spinal nerves, posterior roots, symptoms of injury, 498
— reflex, 2, 3
Spine, hysterical, 373
Spino-muscular motor neurone lesions. *See* Motor paralyses
Spino-thalamic tract, 14
Spondylosis, campto-cormic or anti-algic, 270, 548
Squint, 128
Stammering, 112
— hysterical, 372
— psychasthenic, 365
Staso-baso-phobia, 278, 391
Stellwag's sign of exophthalmic goitre, 347
Stereognostic perception, 190, 452
Sterno-mastoid, paralysis of, 161, 162
Stiff neck, 231
Stokes-Adams syndrome, 62, 73
Stomach, dilatation of, 76, 159, 349
— hysterical rumblings in, 396
— reflected pains of, 176
— reflex contraction of, 328
Stovaine as spinal anæsthetic, 429
Strio-spinal motor system, 11
Striümpell's tibialis phenomenon, 208
Strychnine poisoning, 74, 324, 429, 511
Stupor, 53
— katatonic, 64, 545
— and sleep, 436
Sub-arachnoid spaces, 467
Sub-cortical aphasia, 99, 101
— — — motor, 103
— cerebral tumours, 72
Subcortico-spinal tracts, 10, 11
Sub-dural hæmorrhage, chronic, 57, 58
— spaces, 467
Sub-pinealism, 26
Sub-pituitarism, 290, 456, 457
Sub-thalamic hæmianæsthesia. *See* Hemianæsthesia
Sub-trapezial plexus, paralysis of, 165, 518
Sugar tolerance in pituitary disease, 25
Suggestion, 366, 369
— neurosis, 366, 546
— in war-hysteria, 539
Suggestions, hetero-, 540
Sunstroke and coma, 63, 170
— headache in, 170
— treatment of, 428
Super-pinealism, 26
Super-pituitarism, 290, 455
Supinator jerk, 322
— longus, paralysis of, 30
Supra-renal bodies, 339
— — acute disease of, 349
Sweating, abnormalities of, due to nerve-disorder, 343-346, 355-357
— centre for, 356
— cervical sympathetic connected with, 336, 339, 342, 346, 350, 351
— of hysteria, 397
— in Ménière's disease, 156
— in spinal cord lesions, 357
Sylvian fissure, 3, 42, 96

Sylvian fissure, arteries of, 42
— — landmarks of, 3
Symmetrical gangrene, 351
Sympathetic nervous system, anatomy of, 1, 334
— — — lesions of, 341, 349
— — — relation to drugs and ductless glands, 338
— — — thoracico-abdominal diseases of, 349
Sympathetico-tonus, 339, 555
Synæsthesalgia, 184, 400
Syncope distinguished from "petit-mal," 68
Synkinesia, 87, 88, 208
— in chronic hemiplegia, 87
— as family stigma, 88
— imitative, 87
— physiological, in children, 87
Syphilis, cerebro-spinal fluid in diagnosis of, 420, 425-427
— diagnosis of, 462
— epilepsy secondary to, 70
— irregularity of pupils in, 70, 125
— meningitis of, 174
— palatal perforation from, 108
— third nerve palsy from, 132
Syringobulbia, 198
Syringomyelia, 78, 198, 216
— arthropathy (diagrams), 199, 216, 306, 307
— claw hand in, 265
— dissociated anæsthesia in, 191, 198, 216
— fibrillary tremors, 78
— loss of deep reflexes in, 323
— muscular wasting, 198, 220
— ocular symptoms, 125
— pain from, 167
— perforating ulcers in, 293
— spontaneous fractures in, 305
— thermo-anæsthesia and analgesia (diagrams), 198, 199, 306
— trophic changes in joints, 216, 306, 307

Tabes, anæsthesia of, 198, 199
— — (diagram), 199
— ankle-jerks, 321
— anosmia, 116
— Argyll-Robertson phenomenon, 124, 126
— arthropathy, diagnosis of cases, 305, 306
— ataxia in, 253, 254, 279
— bulbo-cavernosus reflex, loss in, 335
— cerebro-spinal fluid in diagnosis of, 425, 426
— crises in, 177, 349
— delayed sensation in, 188
— gait in, 271
— girdle pains in, 175
— hyperæsthetic areas in, 182, 192, 198
— — — (diagram), 199
— hypotonia in, 273, 274
— involuntary movements in, 88, 305 (fig.)
Tabes, joint and kinæsthetic sense, loss of, 190
— laryngeal, 110
— lightning pains of, 182, 193
— light reflex, loss of, 126, 327
— muscular and tendinous analgesia, 191, 199
— myosis, 125
— nasal, crisis in, 117
— optic atrophy, primary, 123
— perforating ulcers in, 292, 294
— pseudo-athetosis in, 88
— pupils, irregularity of, 125
— reflexes, 126, 317, 323, 327
— Romberg's sign in, 253
— skin traction sense, loss of, 189
— spontaneous fractures in, 305
— squint in, 124
— sudden falling in, 250
— transient paralysis in, 250
— trophic changes, 292, 303
— vibration sense, loss of, 191
Tachycardia, 536, 541, 542, 555
Tachypnœa, hysterical, 396
Tactile sense, 12, 13, 15, 16
— — loss of, 18, 191
— — tests for, 187
Talipes equino-varus, 221
Tangential wounds of head, 468
Taste, cortical centre for, 39
— course of fibres serving, 39, 140, 150, 157
— — — — (diagrams), *facing* 140, 147
— disorders of, 140, 141, 147, 150, 158
— — hysterical, 374, 381, 383
— in fifth nerve palsy, 141
— tests for sense of, 140
Tear secretion, paralysis of, 142
Tecto-spinal tract, 11
Tegmental lesions, 83, 455
Temperature in cerebral hæmorrhage, 56
— sense, fibres serving, 14, 15, 17
— tests for, 187
Temporal lobe, disease of, 39, 41, 72, 450, 464
— region, lesions of, 488
Tendons, sensibility to pressure, 190
Tetanus, 74, 429, 508
— general and localised, 509, 510
Tetany, 74-76, 250
— and cataract, 76
— Chvostek's sign in, 75
— endemic, of shoemakers, 76
— epidemic, from ergotism, 76
— Erb's sign in, 75
— from extirpation of parathyroids, 75
— Trousseau's sign in, 75
Tethelin, 25
Thalamic syndrome, 16, 167, 192, 195, 210, 453–454
— — pleasure and pain in, 192
Thalamo-cortical pathway, 5
Thecal puncture, 414
— — therapeutic uses of, 427-432
Thermalgia, 183, 197, 356, 519
Thermic nystagmus, 130

Thermo-anæsthesia, 191
Thigh, motor points, Erb's diagrams, 405, 407
Thirst, cortical centre for, 41
Thomsen's disease (Myotonia congenita), 245, 408
Thoracic nerves, lesions of, producing ocular symptoms, 341
Thrombosis of cavernous sinus, 45
— cerebral, 41, 44, 59, 98, 101, 154, 169, 418
— spinal, 43, 51
Thumb reflex, 314
— sign in ulnar paralysis, 224
Thyroid gland, over-action of, 537, 555
Thyroidism, dys-, 555
"Tibialis phenomenon," 208
Tic douloureux, 91, 173
Tics, 89, 113
— distinguished from chorea, 89
— psychasthenic, 366, 554
Tinnitus, 152, 157, 169
Tobacco amblyopia, 120, 123
— intoxication, 542
Tongue, ataxy of, 110
— biting, in epilepsy, 67
— hemi-atrophy, 142, 159
— innervation, 140, 157
— paralysis, 108, 163-165
— taste fibres to, 140, 147, 157
Tonic innervation, 209
— rigidity, 12
Tonus, muscular, 15, 86, 227, 254
Tooth's peroneal muscular atrophy, 221
Torcular Herophili, 44
Torticollis, fixed or congenital, 262
— labyrinthine, 90
— neuralgic, 90
— professional, 90
— spasmodic, 89
Touch. *See* Tactile sense
Toxic neuroses, 542
— vertigo, 155
Toxicophobia, 366
Training, effect on conduct, 537
Trance, hysterical, 64, 385
— hypnotic, 64
— katatonic, 64
— from war-shock, 545
Transient paralysis in, 244 *et seq.*
Traumatic cerebral compression, 56, 472
— narcosis, 54
Tremors, 80-84
— in children, 83
— emotional excitement and, 81
— — reaction, 536, 541, 542
— exophthalmic goitre and, 81
— fatigue causing, 81
— hysterical, 545, 551
— — following shell-explosion, 93
— intention, 259
— in lesions of tegmental region, 83
— neurasthenia and, 81
— of paralysis agitans, 81
— in progressive lenticular degeneration, 84
Tremors, Quinquaud's sign in alcoholism, 81
— senile, 82
— toxic, 81
— in tumours of frontal lobe, 84
Trench-feet, 284, 354
Triceps-jerk, 318, 322
Trichiniasis, 231, 423
Tricho-anæsthesia, 187
Trigeminal nerve. *See* Cranial nerves
— neuralgia, 173, 174
Trismus, 510
Trömner's finger-phenomenon, 326
Tropho-neuroses, 287-311
— bones and joints, 303
— generalised trophic disorders, 287
— skin and its appendages, 291
Trousseau's sign in tetany, 75
Trypanosome of sleeping sickness, 423
Tubercles of choroid, 123
Tubercula dolorosa, 183
Tuberculin, Calmette's and von Pirquet's reactions, 464
Tuberculous growths in brain, 464
— meningitis, 169, 419, 422, 424, 427
Tuberose sclerosis, 463
Tumours, abdominal phantom, 396
— diagnosis of, 51, 443
— — pathological, 462
— intra-cranial, 72, 123, 155, 169, 171, 435, 443 *et seq.*, 455
— — attitude of head, 282
— — blue-blindness in, 120, 444
— — central ganglia, 453
— — cerebellum, 151, 155, 171, 258, 282
— — — ataxia in, 258
— — — attitude of head with, 282, 459, 460
— — — cortical, 458
— — — fits due to, 65, 76, 459
— — — extra- and intra-cerebellar, 458-459
— — — lateral lobe, 459
— — — middle lobe, 458
— — — skew deviation with, 459
— — coma in, 61
— — corona radiata, 453
— — corpora quadrigemina, 454
— — corpus callosum, 454
— — crusta of crus cerebri, 455
— — diagnosis of pathological, 462
— — drowsiness in, 437
— — epileptic fits from, 70, 445
— — fourth ventricle, 462
— — frontal region, 449
— — — anosmia in, 449
— — — tremor in, 84
— — giddiness in, 445
— — headache in, 169, 171, 443, 444
— — hemianopia from, 8, 120, 453
— — hernia cerebri after craniectomy, 478
— — of infundibulum, 435
— — internal capsule, 453
— — Jacksonian fits in, 447, 448, 449
— — lumbar puncture for inoperable, 428

Tumours, intra-cranial, medulla oblongata, 462
— — mental dulness in, 445
— — of mid-brain, 125, 434, 454, 455
— — modes of producing symptoms, 443
— — motor cortex, 448
— — occipital lobe (case of), 8
— — — region, 452
— — optic neuritis, 123, 443, 444
— — pineal body, 454
— — pituitary, 121, 288, 435, 455-457
— — pons, 461
— — ponto-cerebellar, 459
— — post-central convolution, 451
— — postero-parietal lobule, 452
— — pre-central, 447 (fig.), 448
— — pre-frontal, 449, 450
— — slowness of breathing, 446
— — — of pulse, 445
— — supra-marginal and angular convolutions, 451
— — tegmental region of crus or pons, 455
— — temporal lobe, 450
— — vermis, 458
— — vomiting in, 445
— — in war, 493
— pelvic, 161
— of spinal cord, 213
— — — differential diagnosis, 213, 214, 419
— — — meningeal, 174, 181, 182
Tuning-fork tests for hearing, 151
Typhus, "coma-vigil" of, 64

Ulcers, perforating, 292
— rodent, 296
Ulnar paralysis, 223, 224, 512, 514, 534
— spasm, 93
Uncinate gyrus. *See under* Gyrus
— fits, 71, 451
Unilateral bulbar syndrome, 257
Unverricht's family myoclonus, 78, 79
Uræmia, coma of, 62, 429, 438
— convulsions, 70, 72, 495
— Jacksonian fits in, 72
Urine in alcoholic poisoning, 61
— diabetic, 63
— dribbling of, 330, 332
— hysterical incontinence and retention, 394
— — suppression, 397
— reflex incontinence, 330
— retention of, 330
— in uræmic coma, 62
Urticaria scripta, 355, 397
— — (illus.), 133, 398
Uterine disease, headache from, 169
— reflex, 327

Vago-tonus, 339
Varicella and herpes zoster, 175
Varicose sciatica, 180
Vascular causes of insomnia, 440
Vaso-constriction in sleep, 433, 434
Vaso-neuroses, 350-357, 395-397
Vaso-vagal attacks, 350
Vegetative nervous system, 334-357
Vegetative-neurosis, 555
Veins, intra-cranial, 44, 45
Ventral longitudinal bundle, 11
Ventricles, cerebral wounds of, 469, 470
Verbigeration, 546
Vermis, 18, 22, 23
— tumours of, 458
Verrucosis, congenital, 297
Vertebral arteries, 41, 43
Vertigo, causes of, 153, 154
— galvanic, 154
— labyrinthine, 156
— ocular, 155
— toxic, 155
Vesical reflex, 327
Vestibular ataxia, 255
— attitude of head, 282, 459, 460
— nerve, central connections of, 40
— — lesions, 135, 150
— — tests for integrity, 130
— nystagmus, 139
— path, 40
Vestibulo-spinal tract, 11, 19, 21
Vibrant electricity, 400
Vibration sense, 12, 18, 186, 191
Vidian nerve, 140
Visceral disease, reflected pains in, 175
— phenomena of hysteria, 395-397
Vision, colour tests for, 118
— fibres of, path of, 37-39
— field of, concentric contraction of, 120, 452
— — hyperæsthesia, 374
— — hysterical, 381-383
— — — blindness, 382-383
— — measurement, 119
— — in myasthenia, 120, 245
— lesions producing loss of, 485
Visual acuity, tests for, 117
— aphasia, 96, 101
— — centres for, 38, 102
— — cortical and subcortical, 101
— — (diagrams), 96, 97, 102
— cortex, 29-32, 37-39, 451
— fibres in optic chiasma, 122
— fields, concentric contraction of, 120
— hallucinations, 72, 453
— word-centre, 97, 101, 451
Visuals and auditives, 98, 100
Vocal word-centre, 96
Von Graefe's sign in exophthalmic goitre, 348
V. Volkmann's ischæmic paralysis, 231, 232
Vomiting, 3, 147, 150, 154, 155, 156, 169, 172
— cerebral, 445
— hysterical, 395-396, 551
— reflex, 3
Vorbei-zeigen, 22, 255

Walking. *See* Gait
Wallerian degeneration, 27, 29
War-lesions, organic, of nervous system, 466-535

War neuroses, 536-557
— — causation of concussion, 541
— — clinical varieties; anxiety neurosis, 554
— — — concussion neurosis, 545
— — — epilepsy, 556
— — — fright neurosis, 555
— — — hysteria or suggestion, 546
— — — katatonic stupor, 545
— — — neurasthenia or exhaustion, 553
— — — psychasthenia, 554
— — — reflex paralyses, 552
— — deaf-mutism, 114
— — emotional shock in, 536
— — exhaustion, 541
— — heredity, 543
— — mutism, 64
— — pain, 542
— — poisoning, 542
— — suggestion, 539
— trance, 64
Wassermann reaction, 419, 462
Weber's law, 190
— syndrome, 8, 211, 455
— test for hearing, 151
Werdnig-Hoffman type of progressive muscular atrophy, 220
Werner's "memoria technica" for false images, 128, 129
Wernicke's hemiopic pupillary reaction, 127, 453
— zone, disintegration of, 104
Whitlows, painless, 198, 293
"Willis, circle of," 41
Witches, 378
Word-blindness. *See* Visual aphasia
Word-centre, auditory, 96
— (diagram), 97, 102
— visual, 96, 98
— vocal, 96
Word-deafness. *See* Auditory aphasia
Word-swallowing, 89
Wounds of brain, 466-495
— of head, bursting fractures, 471
— — penetrating, 470
— — perforating or in-and-out, 450
— — tangential or glancing, 468
— of peripheral nerves, 511-522
— of spinal cord, 495-508
Wrisberg, nervus intermedius of, 144, 150
Wrist reflex, 318
Writer's cramp, 249, 260
Writing, motor centre for, 97

Xanthochromia of cerebro-spinal fluid, 419
X-rays in neurology, 400
— in tumours, 446

Yawning, automatic extensor movements in, 87
— in intra-cranial disease, 446
Yohimbine poisoning, 408

Zacharias, instance of motor aphasia, 103
Zigzag test in hysterical anæsthesia, 380

8-24-61

BILLING AND SONS, LTD., PRINTERS, GUILDFORD, ENGLAND

Date Due

PRINTED IN U.S.A. CAT. NO. 24 161

UC SOUTHERN REGIONAL LIBRARY FACILITY
A 000 510 453

WL141
S849d
1920

Stewart.
The diagnosis of nervous diseases

DATE | ISSUED TO

WL141
S849d
1920

Stewart.
The diagnosis of nervous diseases

CALIFORNIA COLLEGE OF MEDICINE LIBRARY
UNIVERSITY OF CALIFORNIA, IRVINE
IRVINE, CALIFORNIA 92664

PRINTED IN U.S.A.